Update in the management of allergic fungal sinusitis

Osama Marglani, MD, FRCSC.

ABSTRACT

على مدى العقود ال 3 الماضية تم تعريف إلتهاب الجيوب الأنفية التحسسية الفطرية AFS باعتبارها شكلاً إكلينيكياً متميزاً ومنفرداً من مرضي التهاب الأنف والجيوب المزمن. وإلى الآن لم يفهم تماماً المسببات المرضية والتاريخ الطبيعي للمرض بشكل كامل، كما أن العلاج المناسب لAFS هي أيضا مثيرة للجدل. تشمل علاج AFS مزيج من جراحة الجيوب الأنفية بالمنظار الضوئي والعلاج الطبي في صورة الستيرويدات قبل وبعد العملية الجراحية والستيرويدات الموضعية، والعلاج المناعي للحساسية. أن هناك حاجة ماسه إلى المتابعة والتنسيق بين الجراح والمريض لنتائج أفضل. وعلى الرغم من العلاج الطبي والجراحي المكثف، فما زالت معدلات الفشل عالية. الهدف من هذا المقال هو استعراض المؤلفات والبيانات حول مختلف خيارات العلاج الجراحي وغير الجراحي لل AFS الحالية.

Over the last 3 decades, allergic fungal sinusitis (AFS) has been defined as a clinically and pathologically distinct form of chronic rhinosinusitis. The etiology, pathogenesis, and natural history of the disease has not been fully understood, and the appropriate treatment for AFS is also controversial. The management of AFS includes a combination of functional endoscopic sinus surgery and medical treatment in the form of pre- and post-operative systemic steroids, local steroids, and allergic immunotherapy. Close follow-up and coordination between the surgeon and physician is needed for optimum outcome. Despite aggressive medical and surgical treatment, high recurrence rates have been reported. In this review, we study the current literature and data regarding various surgical and non-surgical treatment options for AFS.

Saudi Med J 2014; Vol. 35 (8): 791-795

From the Department of Otolaryngology, Head & Neck Surgery, College of Medicine, Umm Al-Qura University, and King Abdullah Medical City, Makkah, Kingdom of Saudi Arabia.

Address correspondence and reprint request to: Dr. Osama Marglani, Department of Otolaryngology, Head & Neck Surgery, College of Medicine, Umm Al-Qura University, and King Abdullah Medical City, Makkah, Kingdom of Saudi Arabia. E-mail: marglani1@yahoo.com

Allergic fungal sinusitis (AFS) is a non-invasive form of fungal sinusitis. It was recognized as allergic aspergillosis of the paranasal sinuses by Millar et al[1] in 1981. In 1983, Katzenstein et al,[2] were the first to describe it as a newly recognized form of allergic sinusitis. Once considered as a rare disorder, it has been reported with increased frequency all over the world in the last 2 decades. The incidence of AFS shows regional variations ranging from 7-25%[3] of all chronic rhinosinusitis patients undergoing surgical treatment. The incidence in the Saudi population is reported as 14%[4] in the regional studies among patients with chronic rhinosinusitis. The aim of this article is to provide a review of various treatment modalities and their role in the management of AFS.

Allergic fungal sinusitis is a noninvasive form of fungal rhinosinusitis resulting from an IgE-mediated type I hypersensitivity reaction, and a type III reaction to fungal antigens in atopic individuals. The pathophysiology of AFS has not yet been fully understood, according to Manning et al[5] there are several factors leading to development of AFS, they described a self perpetuating cycle, it starts when an atopic host is exposed to a fungal antigen providing the antigen stimulus, this leads to an IgE mediated (type I hypersensitivity) reaction and type III reaction causing tissue inflammation. This edema along with other anatomical risk factors such as septal deviation or turbinate hypertrophy leads to obstruction of sinuses, fungal antigens get trapped into the mucosa providing an ideal environment for the fungal proliferation and more antigenic exposure, this cycle continues. It also leads to collection of allergic mucin. The histological characteristics and radiological signs of allergic mucin are unique for AFS. Grossly allergic fungal mucin is thick, tenacious, and highly viscous, and often described as having a peanut butter appearance.

The accumulation of allergic fungal mucin leads to heterogeneous areas of signal intensity within paranasal sinuses on CT scans, although these findings are not specific for AFS. The areas of high attenuation are seen because of collection of heavy metals (iron, manganese) along with calcium crystals in the inspissated mucin

OPEN ACCESS

characteristically seen only on CT scan. On MRI, the area of allergic mucin appears as signal void (hypointense) on T2 images. Expansion, remodeling, or thinning of involved sinus walls is caused by the expansile nature of the accumulating mucin, this also leads to the bony erosions seen on CT scan. The bone resorption is presumably caused by cytokines present in the allergic mucin. The presentation of the disease is usually subtle with symptoms lasting from months to years. Patients often tend to be young, immunocompetent, and atopic, presenting to their physician with symptoms typical of chronic rhinosinusitis. Nasal obstruction, hyposmia, or anosmia is common. The disease may present with symptoms of bony erosions and orbital involvement especially in children. Other symptoms include headache, facial fullness, and pressure sensation, purulent nasal discharge and asthma, or hypereactive airway disease. Patients presenting to tertiary rhinology centers often give a history of multiple surgical procedures, excellent response to oral corticosteroids (OCS) with minimal response to oral antibiotics. Uni- or bilateral nasal polyps are almost ubiquitous in this patient population.[6,7]

The recognition of this common clinical condition continues to pose a diagnostic and therapeutic dilemma for treating physicians. Once a diagnosis of AFRS has been established, patients are enrolled into a committed long-term treatment program considered critical to successful management. The first step in treatment is complete and meticulous sinus surgery with complete extirpation of fungal debris from all sinus cavities followed by a dedicated medical-surgical postoperative follow-up with commitment from both the surgeon and the patient. Very high recurrence rates have been reported in different series ranging from 35-75%.[8]

Different criteria have been proposed for the diagnosis of allergic fungal sinusitis, out of which Bent and Kuhn criteria[9] are widely accepted. In 1994, the Bent and Kuhn[9] published specific diagnostic criteria based on a case series of 15 patients, it included 5 criteria: 1) type I IgE-mediated hypersensitivity, 2) nasal polyposis 3) characteristic CT findings, 4) eosinophilic mucin, and 5) positive fungal smear or culture. These criteria are controversial and various modifications have been proposed, but they are still accepted for diagnosis. Ponikau et al[10] reported that in 96% patients with chronic rhinosinusitis, fungal culture may be positive if carried out correctly, they described the method of extraction of fungus from the mucus and allergic mucin. Kuhn and Swain[11] stated that AFS is not only difficult to diagnose, but it is one of the most complicated conditions for rhinologists to manage. For the comprehensive management endoscopic sinus, surgery is always used with long term medical treatment, which includes a combination of oral and nasal steroids, immunotherapy, antifungal therapy, and the therapy; is directed to limit the inflammatory process.[11] Despite aggressive treatment, this disease often recurs frustrating the physician and patient alike.

Surgery for AFRS. Historically, surgical treatment options for AFRS included radical surgeries such as nasalization namely, radical ethmoidectomy with middle turbinate resection as was described by Ankowski et al.[12] Radical removal of the mucosa with external approaches has resulted in very high recurrence rates in the past. Nowadays, a strategy has evolved to incorporate almost exclusively endoscopic tissue-sparing techniques described as conservative, but complete. The introduction of image-guided surgery (IGS) has also allowed precise anatomical localization of landmarks,

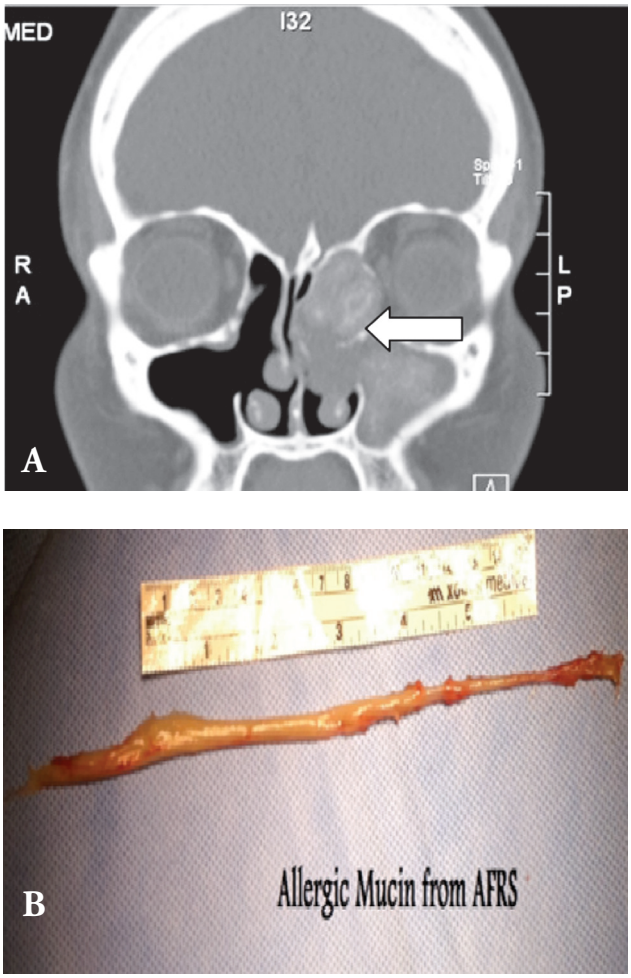

Figure 1 - Photograph showing **A**) computerized tomography scan showing the allergic fungal rhinosinusitis (AFRS) and **B**) allergic mucin isolated from sinuses

which are either eroded by the AFRS itself (**Figure 2**), or by previous surgery. The aim of the surgical treatment is to widen the natural ostia of sinuses to allow for more effective natural drainage pathways, complete removal of fungal debris and allergic mucin, also allowing the wider access for topical medications to reach the sinuses, and postoperative follow-up examination.

Steroid therapy. The most effective medical treatment of AFS is oral corticosteroids (OCS), having arisen directly from the success of this strategy for allergic bronchopulmonary aspergillosis (ABPA). Bent and Kuhn[9] noted that there was almost universal recurrence in patients not treated with OCS. Oral corticosteroids provide control of the disease by a strong anti-inflammatory and immunomodulatory effect against the inciting fungal hyphae, it inhibits both type I and type III hypersensitivity reactions.

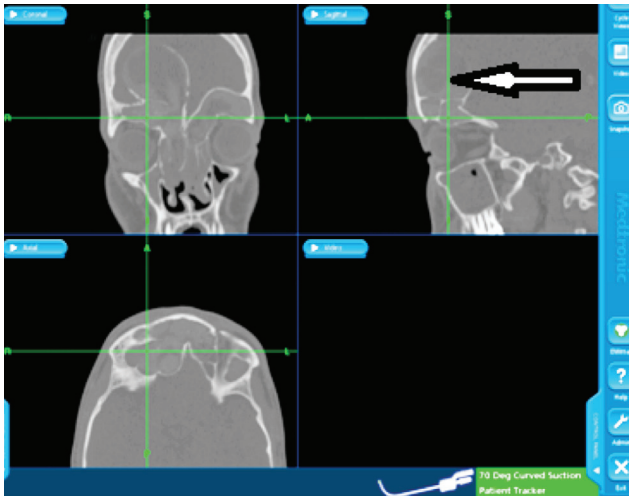

Figure 2 - The utilization of an image guided system on a patient with allergic fungal sinusitis with intracranial extension (arrow) and erosion of the posterior table of the frontal sinus seen on coronal and axial sections on navigation.

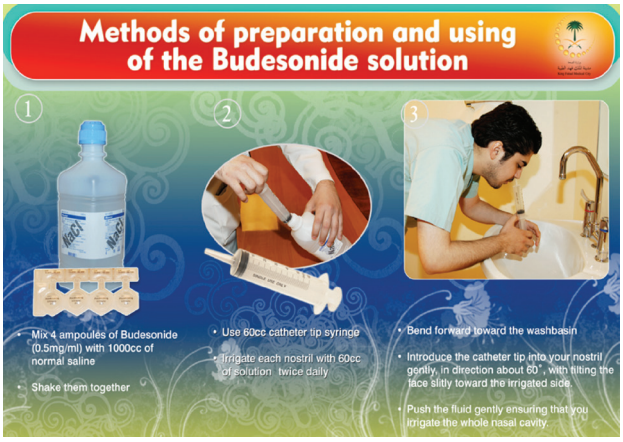

Figure 3 - English version of the Pulmicort saline irrigation brochure for patients.

There are no prospective trials assessing administered doses and treatment durations of OCS; however, it is reasonable to assume that the most effective treatment is one that controls the disease with the lowest dose for the shortest period of time. Kupferberg et al[13] suggested that the mucosal stage and length of treatment is dose dependent. They found that if the oral steroid dose was tapered too quickly there would be a deterioration of mucosal staging and treatment outcome. Kupferberg et al[13] proposed a mucosal staging system, which included Stage 0: no edema or allergic mucin, Stage I: mucosal edema with/without allergic mucin, Stage II: polypoidal mucosa with/without allergic mucin, and Stage IV: nasal polyps with fungal debris.

Kuhn and Javer[14] demonstrated an improvement in mucosal stage and IgE levels postoperatively while patients were on OCS. Their treatment protocol was initially designed to keep patients at endoscopic stage 0 for 4 months before stopping the OCS. This duration was later extended to 6 months after significant recurrence occurred with the 4-month treatment. Prospective randomized controlled trials have revealed the role of OCS in preventing early recurrences. Prolonged treatment with systemic steroids leads to both acute and long-term toxicities; therefore, systemic steroids are best confined to perioperative periods and should be used as short bursts to suppress recurrent disease.

Antifungal therapy. Antifungal therapy has provided mixed results for AFRS patients. Convincing data of their effectiveness in AFRS is still lacking. Chan and Javer[15] demonstrated that oral itraconazole stabilized or improved mucosal stage, the mucosa in most patients reached stage 0 postoperatively, in approximately 50% of patients and provided a viable treatment adjunct for AFRS patients. It has been argued that the effectiveness of itraconazole may not be due to reduced fungal burden, but rather due to anti-inflammatory properties and inhibition of prednisolone metabolism. Systemic antifungals have the potential for severe side effects and in a series we published previously, we noted a reversible elevation of liver enzymes in 19% of patients with a reversible chemical hepatitis in 6% of patients. Several investigators[15,16] have published their experience with topical amphotericin B. Ponikau et al[17] as well as Richetti et al[18] felt that topical amphoterecin B was beneficial in reducing recurrence rates and stabilizing the disease, but no control groups were used in their studies. Weschta et al[19] undertook a double-blinded, placebo-controlled study and showed that topical

amphoterecin B had no beneficial effect over saline irrigations and in fact the amphoterecin B group had a worse symptom score. Bent and Kuhn[20] studied the in vitro susceptibility of fungi commonly encountered in AFRS patients and determined that the minimum inhibitory concentration can be achieved with topical antifungal agents.[16] Rains and Mineck[21] suggested the use of itraconazole, short-burst, low-dose oral corticosteroids, topical corticosteroids, and endoscopic sinus surgery as a safe and clinical effective regimen in the treatment of AFRS.[18] Despite the purported fungal cause of AFRS, antifungal therapies need further studies to establish their efficacy before widely accepted.

Topical steroids. Topical corticosteroids are also utilized as standard treatment for AFRS. They play an important role in the long-term management of AFRS. They are expected to be most effective in the postoperative period as there is more distribution of medication over sinus mucosa through widened ostia. Correct administration of the nasal sprays cannot be overemphasized to improve efficacy. Advantages include minimal absorption and side effects, but no controlled studies have been carried out to determine their efficacy in AFRS (**Figure 3**).

Nasal steroids play a role in the management of patients with allergic rhinitis and to a lesser extent in chronic rhinosinusitis (CRS).[22] The problem with the nasal spray is the delivery of inadequate doses in the paranasal sinuses, using a budesonide solution in concentrated doses solves this problem by delivering the required dose in the sinus cavities. Budesonide has minimal systemic side effects as it has an extensive first pass metabolism of systemically absorbed drug (80-90%) it also causes dose related suppression of cortisol levels in plasma.[23,24] Budesonide has a less suppressive effect on the HPA axis than other corticosteroids on a microgram to microgram basis.[25] Several studies have shown budesonide to be a safe medication for the treatment of inflammatory airway disorders with minimal adverse systemic side effects.[25,26] Budesonide is also the only corticosteroid with pregnancy Category B rating (both in intranasal and inhaled formulations).[27]

Immunotherapy. The toxic effects of steroids have led to research of non-steroidal treatment alternatives. Immunotherapy is another treatment modality that has potential as an effective treatment option, there are various clinical trials in the literature proving the efficacy of immunotherapy on a long term basis, such as the notable study by Mabry et al.[28] In that study the immunotherapy was given to 9 patients of AFS with Bipolaris antigen, the patients in the immunotherapy group had a decrease in poly recurrence, nasal crusting, and decreased allergic mucin with no adverse reactions with no recurrences on a long term basis. Folker et al[29] conducted a study by comparing 11 patients receiving immunotherapy for at least one year with the control group; the study group showed statistically significant improvement in endoscopic scores and chronic sinusitis survey scores.

Table 1 - Allergic fungal rhinosinusitis treatment options for comprehensive management and long-term disease control.

Surgical	Medical
Functional endoscopic sinus surgery (with image guided system)	Costicosteroids Topical and systemic Immunotherapy Anti-fungal Topical and systemic

The efficacy of postoperative immunotherapy for the control of this study is well established, but non-availability and high cost are the limiting factors.

Other emerging therapies. There have been a few therapeutic modalities that were described in the literature; however, they are still emerging in clinical trials. These include antilukotrienes,[31] with a case report on AFRS in 2000, and Manuka honey (throat spray specially formulated mixture).[32,33] The antibacterial and antifungal properties of Manuka honey in the literature are well documented, but local use of Manuka honey as a spray mixture (honey saline combination) has limited benefit in selected patients. It does not show a global benefit in endoscopic disease score, but studies have reported that specific patients with AFS did show significant positive responses. Further research is needed to identify those patients that benefit from Manuka honey local sprays.

In conclusion, the treatment of AFRS is based on rational principles, reports of successful treatment approaches in the literature, and the clinical experience of the clinician who deals with the disease. For comprehensive management and long-term disease control the combination of medical, surgical, and immunological treatment is required (**Table 1**). The exact combination continues to be debated strongly. High-level evidence is lacking on the optimal management of allergic fungal sinusitis. Our experience, and that of others, suggests that removal of fungal debris, establishment of sinus aeration surgically with tissue sparing and postoperative intranasal corticosteroid treatment and immunotherapy are the place to start. However, with this approach, the disease reactivates in some patients and often is associated with ongoing symptoms and the need for further sinus surgeries. Other modalities have been discussed and deserve more research.

References

1. Millar JW, Johnston A, Lamb D. Allergic aspergillosis of the maxillary sinuses. ***Thorax*** 1981; 36: 710.
2. Katzenstein AL, Sale SR, Greenberger PA. Allergic Aspergillus sinusitis: a newly recognized form of sinusitis. ***J Allergy Clin Immunol*** 1983; 72: 89-93.
3. Ferguson BJ, Barnes L, Bernstein JM, Brown D, Clark CE 3rd, Cook PR, et al. Geographical variation in allergic fungal sinusitis. ***Otolaryngol Clin North Am*** 2000; 33: 441-449.
4. Al-Swiahb JN, Al-Dousary SH. Bone erosions associated with allergic fungal sinusitis. ***Saudi Med J*** 2011; 32: 417-419.
5. Manning SC, Holman M. Further evidence for allergic pathophysiology in allergic fungal sinusitis. ***Laryngoscope*** 1998; 108: 1485-1496.
6. Gourley DS, Whisman BA, Jorgensen NL, Martin ME, Reid MJ. Allergic Bipolaris sinusitis: clinical and immunopathologic characteristics. ***J Allergy Clin Immunol*** 1990; 85: 583-591.
7. Schubert MS. Allergic fungal sinusitis. ***Otolaryngol Clin North Am*** 2004; 37: 301-326.
8. Schubert MS, Goetz DW. Evaluation and treatment of allergic fungal sinusitis. II. Treatment and follow-up. ***J Allergy Clin Immunol*** 1998; 102: 395-402.
9. Bent J, Kuhn FA. Diagnosis of allergic fungal sinusitis. ***Otolaryngol Head Neck Surg*** 1994; 111: 580-588.
10. Ponikau JU, Sherris DA, Kern EB, Homburger HA, Frigas E, Gaffey TA, et al. The diagnosis and incidence of allergic fungal sinusitis. ***Mayo Clin Proc*** 1999; 74: 877-884.
11. Kuhn FA, Swain R. Allergic fungal sinusitis: diagnosis and treatment. ***Curr Opin Otolaryngol Head Neck Surg*** 2003; 11: 1-5.
12. Ankowski R, Pigret D, Decroocq F. Comparison of functional results after ethmoidectomy and nasalization for diffuse and severe nasal polyposis. ***Acta Otolaryngol*** 1997; 117: 601-608.
13. Kupferberg SB, Bent JP, Kuhn FA. Prognosis for allergic fungal sinusitis. ***Otolaryngol Head Neck Surg*** 1997; 117: 35-41.
14. Kuhn FA, Javer AR. Allergic fungal rhinosinusitis: perioperative management, prevention of recurrence, and role of steroids and antifungal agents. ***Otolaryngol Clin N Am*** 2000; 33: 161-171.
15. Chan KO, Javer AR. Effectiveness of Itraconazole in the management of refractory allergic fungal rhinosinusitis. ***J Otolaryngol Head Neck Surg*** 2008; 37: 870-874.
16. Rains BM 3rd, Mineck CW. Treatment of allergic fungal sinusitis with high-dose itraconazole. ***Am J Rhinol*** 2003; 17: 1-8. same as REF 21
17. Ponikau JU, Sherris DA, Kita H, Kern EB. Intranasal antifungal treatment in 51 patients with chronic rhinosinusitis. ***J Allergy Clin Immunol*** 2002; 110: 862-866.
18. Ricchetti A, Landis BN, Maffioli A, Giger R, Zeng C, Lacroix JS. Effect of anti-fungal nasal lavage with amphotericin B on nasal polyposis. ***J Laryngol Otol*** 2002; 116: 261-263.
19. Weschta M, Rimek D, Formanek M, Polzehl D, Podbielski A, Riechelmann H. Topical antifungal treatment of chronic rhinosinusitis with nasal polyps: a randomized, double-blind clinical trial. ***J Allergy Clin Immunol*** 2004; 113: 1122-1128.
20. Bent JP 3rd, Kuhn FA. Antifungal activity against allergic fungal sinusitis organisms. ***Laryngoscope*** 1996; 106: 1331-1334.
21. Seiberling K1, Wormald PJ. The role of itraconazole in recalcitrant fungal sinusitis. ***Am J Rhinol Allergy*** 2009; 23: 303-306.
22. Lavigne F, Cameron L, Renzi PM, Planet JF, Christodoulopoulos P, Lamkioued B, et al. Intrasinus administration of topical budesonide to allergic patients with chronic rhinosinusitis following surgery. ***Laryngoscope*** 2002; 112: 858-864.
23. Bhalla RK, Payton K, Wright ED. Safety of budesonide in saline sinonasal irrigations in the management of chronic rhinosinusitis with polyposis: lack of significant adrenal suppression. ***J Otolaryngol Head Neck Surg*** 2008; 37: 821-825.
24. Scott MB, Skoner DP. Short-term and long-term safety of budesonide inhalation suspension in infants and young children with persistent asthma. ***J Allergy Clin Immunol*** 1999; 104: S200-S209.
25. Aaronson D, Kaiser H, Dockhorn R, Findlay S, Korenblat P, Thorsson L, et al. Effects of budesonide by means of the Turbuhaler on the hypothalamic-pituitary-adrenal axis in asthmatic subjects: a dose-response study. ***J Allergy Clin Immunol*** 1998; 101: 312-319.
26. Hvizdos KM, Jarvis B. Budesonide inhalation suspension: a review of its use in infants, children, adults with inflammatory respiratory disorders. ***Drugs*** 2000; 60: 1141-1178.
27. Herman H. Once-daily administration of intranasal corticosteroids for allergic rhinitis: a comparative review of efficacy, safety, patient preference and cost. ***Am J Rhinol*** 2007; 21: 70-79.
28. Mabry RL, Mabry CS. Allergic fungal sinusitis the role of immunotherapy. ***Otolaryngol Clin North Am*** 2000; 33: 433-440.
29. Folker RJ, Marple BF, Mabry RL, Mabry CS. Treatment of allergic fungal sinusitis: A comparison trial of postoperative immunotherapy with specific fungal antigens. ***Laryngoscope*** 1998; 108: 1623-1627.
30. Greenhaw B, deShazo RD, Arnold J, Wright L. Fungal immunotherapy in patients with allergic fungal sinusitis. ***Ann Allergy Asthma Immunol*** 2011; 107: 432-436.
31. Schubert MS. Antileukotriene therapy for allergic fungal sinusitis. ***J Allergy Clin Immunol*** 2001; 108: 466-467.
32. Thamboo A, Thamboo A, Philpott C, Javer A, Clark A. Single-blind study of manuka honey in allergic fungal rhinosinusitis. ***J Otolaryngol Head Neck Surg*** 2011; 40: 238-243.
33. Wong D, Alandejani T, Javer AR. Evaluation of Manuka honey in the management of allergic fungal rhinosinusitis. ***J Otolaryngol Head Neck Surg*** 2011; 40: E19-E21.
34. Kuhn FA, Javer AR. Allergic fungal sinusitis: a four-year follow-up. ***Am J Rhinol*** 2000; 14: 149-156.
35. Schubert MS, Goetz DW. Evaluation and treatment of allergic fungal sinusitis. II: Treatment and follow-up. ***J Allergy Clin Immunol*** 1998; 102: 395-402.
36. Bent JP 3rd, Kuhn FA. Allergic fungal sinusitis/polyposis. ***Allergy Asthma Proc*** 1996; 17: 259-268.
37. Bassichis BA, Marple BF, Mabry RL, Newcomer MT, Schwade ND. Use of immunotherapy in previously treated patients with allergic fungal sinusitis. ***Otolaryngol Head Neck Surg*** 2001; 125: 487-490.
38. Jankowski R, Bodino C. Evolution of symptoms associated to nasal polyposis following oral steroid treatment and nasalization of the ethmoid-radical ethmoidectomy is functional surgery for NPS. ***Rhinology*** 2003; 41: 211-219.
39. Greenhaw B, deShazo RD, Arnold J, Wright L. Fungal immunotherapy in patients with allergic fungal sinusitis. ***Ann Allergy Asthma Immunol*** 2011; 107: 432-436.