Ann Allergy Asthma Immunol 113 (2014) 347–385

Contents lists available at ScienceDirect

Practice Parameter

# Diagnosis and management of rhinosinusitis: a practice parameter update

Anju T. Peters, MD; Sheldon Spector, MD; Joy Hsu, MD; Daniel L. Hamilos, MD; Fuad M. Baroody, MD; Rakesh K. Chandra, MD; Leslie C. Grammer, MD; David W. Kennedy, MD; Noam A. Cohen, MD, PhD; Michael A. Kaliner, MD; Ellen R. Wald, MD; Achilles Karagianis, MD; and Raymond G. Slavin, MD
**Chief Editors:** Anju T. Peters, MD; Sheldon Spector, MD

This parameter was developed by the Joint Task Force on Practice Parameters, representing the American Academy of Allergy, Asthma and Immunology, the American College of Allergy, Asthma and Immunology, and the Joint Council of Allergy, Asthma and Immunology.

**Disclaimer:** The American Academy of Allergy, Asthma and Immunology (AAAAI) and the American College of Allergy, Asthma and Immunology (ACAAI) have jointly accepted responsibility for establishing the "Diagnosis and Management of Rhinosinusitis: A Practice Parameter Update." This is a complete and comprehensive document at the current time. The medical environment is a changing environment, and not all recommendations will be appropriate for all patients. Because this document incorporated the efforts of many participants, no single individual, including those who served on the Joint Task force, is authorized to provide an official AAAAI or ACAAI interpretation of these practice parameters. Any request for information about or an interpretation of these practice parameters by the AAAAI or ACAAI should be directed to the Executive Offices of the AAAAI, the ACAAI, and the Joint Council of Allergy, Asthma and Immunology (JCAAI). These parameters are not designed for use by pharmaceutical companies in drug promotion.

**Reprints:** Reprints are not available, but published parameters may be downloaded at the JCAAI Web site: http://www.jcaai.org or at http://www.allergyparameters.org.

**Disclosures:** The following is a summary of interests disclosed on Work Group members' Conflict of Interest Disclosure Statements (not including information concerning family member interests). Completed Conflict of Interest Disclosure Statements are available upon request. Conflicts of interest disclosure statements for the Joint Taskforce (JTF) are available on its Web site. Dr Peters is a consultant for Baxter. Dr Spector has received research grants from AstraZeneca, GSK, Merck, Novartis, BI, Genentech, TEVA, Sanofi Aventis, Amgen, Cephalon, Johnson & Johnson, and Cytos; has consulted for Novartis and BI; has received honorarium from AstraZeneca and Merck; and served as speaker for AstraZeneca. Dr Baroody is a consultant for Johnson & Johnson and served as speaker for Merck. Dr Cohen is a consultant and speaker for Acclarent (J&J). Dr Hamilos received a research grant from Merck and is a consultant for Merck and Sanofi. Dr Kaliner is a speaker and consultant for Meda, Genentech, Mylan, Sanofi, and McNeil. Dr Kennedy has received royalties from Medtronic-Xomed; served on the medical advisory boards of Merck, Sinuwave, and IntersectEnt; is a partner in AcceptEnt; and is medical director of EntEntCare. The other Working Group members have nothing to disclose. The JTF recognizes that experts in a field are likely to have interests that could come into conflict with development a completely unbiased and objective practice parameter. To take advantage of that expertise, a process has been developed to prevent potential conflicts from influencing the final document in a negative way. At the workgroup level, members who have a potential conflict of interest do not participate in discussions concerning topics related to the potential conflict or, if they do write a section on that topic, the workgroup completely rewrites it without their involvement to remove potential bias. In addition, the entire document is reviewed by the JTF and any apparent bias is removed at that level. Finally, the practice parameter is sent for review by invited reviewers and by anyone with an interest in the topic by posting the document on the web sites of the ACAAI and the AAAAI.

**Contributors:** The JTF has made a concerted effort to acknowledge all contributors to this parameter. If any contributors have been excluded inadvertently, the JTF will ensure that appropriate recognition of such contributions is made subsequently. **Workgroup Chair:** Anju T. Peters, MD, Associate Professor of Medicine, Division of Allergy-Immunology, Northwestern University Feinberg School of Medicine, Chicago, Illinois. **Joint Taskforce Liaison:** Sheldon L. Spector, MD, Clinical Professor of Medicine, UCLA School of Medicine, Los Angeles, California. **Joint Task Force Members:** David I. Bernstein, MD, Professor of Clinical Medicine and Environmental Health, Division of Allergy/Immunology, University of Cincinnati College of Medicine, Cincinnati, Ohio; Joann Blessing-Moore, MD, Adjunct Clinical Associate Professor of Medicine and Pediatrics, Department of Immunology, Stanford University Medical Center, Palo Alto, California; David A. Khan, MD, Associate Professor of Internal Medicine, University of Texas Southwestern Medical Center, Dallas, Texas; David M. Lang, MD, Head, Allergy/Immunology Section, Division of Medicine, Director, Allergy and Immunology Fellowship Training Program, Cleveland Clinic Foundation, Cleveland, Ohio; Richard A. Nicklas, MD, Clinical Professor of Medicine, George Washington Medical Center, Washington, DC; John Oppenheimer, MD, Department of Internal Medicine, New Jersey Medical School, Pulmonary and Allergy Associates, Morristown, New Jersey; Jay M. Portnoy, MD, Chief, Section of Allergy, Asthma & Immunology, The Children's Mercy Hospital, Professor of Pediatrics, University of Missouri-Kansas City School of Medicine, Kansas City, Missouri; Christopher C. Randolph, Clinical Professor of Pediatrics, Yale Affiliated Hospitals, Center for Allergy, Asthma, & Immunology, Waterbury, Connecticut; Diane E. Schuller, MD, Professor of Pediatrics, Pennsylvania State University Milton S. Hershey Medical College, Hershey, Pennsylvania; Sheldon L. Spector, MD, Clinical Professor of Medicine, UCLA School of Medicine, Los Angeles, California; Stephen A. Tilles, MD, Clinical Assistant Professor of Medicine, University of Washington School of Medicine, Redmond, Washington; Dana Wallace, MD, Assistant Clinical Professor of Medicine, Nova Southeastern University College of Osteopathic Medicine, Davie, Florida. **Parameter Workgroup Members (alphabetical order):** Fuad M. Baroody, MD, Section of Otolaryngology-Head and Neck Surgery, The University of Chicago Medicine and the Pritzker School of Medicine, Chicago, Illinois; Rakesh K. Chandra, MD, Department of Otolaryngology Head and Neck Surgery, Northwestern University Feinberg School of Medicine, Chicago, Illinois; Noam A. Cohen, MD, PhD, Department of Otorhinolaryngology, Head and Neck Surgery, University of Pennsylvania, Philadelphia, Pennsylvania; Leslie C. Grammer, MD, Professor of Medicine, Division of Allergy-Immunology, Northwestern University Feinberg School of Medicine, Chicago, Illinois; Daniel L. Hamilos, MD, Division of Rheumatology, Allergy & Immunology, Massachusetts General Hospital, Boston, Massachusetts; Joy Hsu, MD, Allergy-Immunology Fellow, Division of Allergy-Immunology, Northwestern University Feinberg School of Medicine, Chicago, Illinois; Michael A. Kaliner, MD, George Washington University School of Medicine, Washington, DC, and the Institute for Asthma and Allergy, Chevy Chase, Maryland; David W. Kennedy, MD, Department of Otorhinolaryngology, Head and Neck Surgery, Perelman School of Medicine, University of Pennsylvania, Philadelphia, Pennsylvania; Raymond G. Slavin, MD, Division of Pediatric Allergy & Immunology, Saint Louis University, St. Louis, Missouri; Ellen R. Wald, MD, University of Wisconsin School of Medicine and Public Health, Madison, Wisconsin.

http://dx.doi.org/10.1016/j.anai.2014.07.025
1081-1206/© 2014 American College of Allergy, Asthma & Immunology. Published by Elsevier Inc. All rights reserved.

**Members of the Joint Taskforce on Practice Parameters:** David Bernstein, MD; Joann Blessing-Moore, MD; David Khan, MD; David Lang, MD; Richard Nicklas, MD; John Oppenheimer, MD; Jay Portnoy, MD; Christopher Randolph, MD; Diane Schuller, MD; Sheldon Spector, MD; Stephen A Tilles, MD; Dana Wallace, MD
**Practice Parameter Workgroup:** Anju T. Peters, MD; Sheldon Spector, MD; Joy Hsu, MD; Daniel L. Hamilos, MD; Fuad M. Baroody, MD; Rakesh K. Chandra, MD; Noam A. Cohen, MD, PhD; Leslie C. Grammer, MD; Michael A. Kaliner, MD; David W. Kennedy, MD; Achilles Karagianis, MD; Ellen R. Wald, MD; Raymond G. Slavin, MD

## Classification of recommendations and evidence

*Recommendation rating scale*

| Statement | Definition | Implication |
|---|---|---|
| Strong recommendation (StrRec) | A strong recommendation means the benefits of the recommended approach clearly exceed the harms (or that the harms clearly exceed the benefits in the case of a strong negative recommendation) and that the quality of the supporting evidence is excellent (Grade A or B)*. In some clearly identified circumstances, strong recommendations may be made based on lesser evidence when high-quality evidence is impossible to obtain and the anticipated benefits strongly outweigh the harms. | Clinicians should follow a strong recommendation unless a clear and compelling rationale for an alternative approach is present. |
| Recommendation (Rec) | A recommendation means the benefits exceed the harms (or that the harms clearly exceed the benefits in the case of a negative recommendation), but the quality of evidence is not as strong (Grade B or C)*. In some clearly identified circumstances, recommendations may be made based on lesser evidence when high-quality evidence is impossible to obtain and the anticipated benefits outweigh the harms. | Clinicians also should generally follow a recommendation but should remain alert to new information and sensitive to patient preferences. |
| Option (Opt) | An option means that the quality of evidence that exists is suspect (Grade D)* or that well-done studies (Grade A, B, or C)* show little clear advantage to one approach vs another. | Clinicians should be flexible in their decision making regarding appropriate practice, although they may set bounds on alternatives; patient preference should have a substantial influencing role. |
| No recommendation (NoRec) | No recommendation means there is a lack of pertinent evidence (Grade D)* and an unclear balance between benefits and harms. | Clinicians should feel little constraint in their decision making and be alert to new published evidence that clarifies the balance of benefit vs harm; patient preference should have a substantial influencing role. |

*Category of evidence*

- Ia Evidence from meta-analysis of randomized controlled trials
- Ib Evidence from at least 1 randomized controlled trial
- IIa Evidence from at least 1 controlled study without randomization
- IIb Evidence from at least 1 other type of quasi-experimental study
- III Evidence from nonexperimental descriptive studies, such as comparative studies
- IV Evidence from expert committee reports or opinions or clinical experience of respected authorities or both

*Strength of recommendation**

- A Directly based on category I evidence
- B Directly based on category II evidence or extrapolated recommendation from category I evidence
- C Directly based on category III evidence or extrapolated recommendation from category I or II evidence
- D Directly based on category IV evidence or extrapolated recommendation from category I, II, or III evidence
- LB Laboratory based
- NR Not rated

## How this practice parameter was developed

*The Joint Taskforce on Practice Parameters*

The Joint Taskforce (JTF) on Practice Parameters is a 13-member taskforce consisting of 6 representatives assigned by the American Academy of Allergy, Asthma and Immunology, 6 by the American College of Allergy, Asthma and Immunology, and 1 by the Joint Council of Allergy and Immunology. This taskforce oversees the development of practice parameters; selects the workgroup chair(s); and reviews drafts of the parameters for accuracy, practicality, clarity, and broad utility of the recommendations for clinical practice.

*Diagnosis and Management of Rhinosinusitis Practice Parameter Workgroup*

The Diagnosis and Management of Rhinosinusitis: A Practice Parameter Update workgroup was commissioned by the JTF to develop practice parameters that address Rhinosinusitis. The chair (Anju T. Peters, MD) invited workgroup members to participate in the parameter development who are considered experts in the field. Workgroup members have been vetted for financial conflicts of interest by the JTF and their conflicts of interest have been listed in this document and are posted on the JTF Web site at http://www.allergyparameters.org. Where a potential conflict of interest is present, the potentially conflicted workgroup member was excluded from discussing relevant issues.

The charge to the workgroup was to use a systematic literature review in conjunction with consensus expert opinion and workgroup-identified supplementary documents to develop a practice parameter that provides a comprehensive approach for rhinosinusitis based on the current state of the science.

*Protocol for finding evidence*

A search of the medical literature was performed by searching PubMed and Google Scholar. References identified as being relevant

were searched for additional references and these also were searched for citable references. In addition, members of the workgroup were asked for references that were missed by this initial search. Although the ideal type of reference would consist of a randomized, double-blinded, placebo-controlled study, some topics addressed in this practice parameter are represented by very few such studies. In consequence, it was necessary to use observational studies, basic laboratory reports, and regulatory requirements to develop a document that addresses some of the issues included in this practice parameter.

## Abbreviations

| | |
|---|---|
| A-P | anterior-posterior |
| ABRS | acute bacterial rhinosinusitis |
| AERD | aspirin exacerbated respiratory disease |
| AFRS | allergic fungal rhinosinusitis |
| AOM | acute otitis media |
| AR | allergic rhinitis |
| ARS | acute rhinosinusitis |
| CF | cystic fibrosis |
| CT | computed tomography |
| CRS | chronic rhinosinusitis |
| CRSsNP | chronic rhinosinusitis without nasal polyps |
| CRSwNP | chronic rhinosinusitis with nasal polyps |
| FDA | Food and Drug Administration |
| FESS | functional endoscopic sinus surgery |
| $FEV_1$ | forced expiratory volume in 1 second |
| GERD | gastroesophageal reflux disease |
| Ig | immunoglobulin |
| INS | intranasal corticosteroids |
| IL | interleukin |
| mm $H_2O$ | millimeters of water |
| MP | methylprednisolone |
| MRI | magnetic resonance imaging |
| NAR | nonallergic rhinitis |
| nNO | nasal nitric oxide |
| PCD | primary ciliary dyskinesia |
| PID | primary immunodeficiency |
| QOL | quality of life |
| RARS | recurrent acute rhinosinusitis |
| RCT | randomized controlled trial |
| URI | upper respiratory infection |

## Preface

Rhinosinusitis is one of the most commonly diagnosed diseases in the United States. Analysis of the Centers for Disease Control and Prevention–sponsored 2010 US National Health Interview Survey data suggested that 13% of adults were diagnosed with rhinosinusitis in the 12 months before the survey.[1] Chronic rhinosinusitis (CRS) alone extracts an overall direct annual health care cost of $8 billion.[2] Acute bacterial rhinosinusitis (ABRS) is believed to cost more than $3 billion dollars annually.[3] A recent analysis of data from National Ambulatory Medical Care Survey and National Hospital Ambulatory Medical Care Survey from 2006 to 2010 showed that rhinosinusitis accounted for more outpatient antibiotic prescriptions than any other diagnosis.[4] Adverse consequences of excessive antibiotic use can include allergic reactions, high costs, and bacterial resistance. In addition to health care dollars spent directly to treat rhinosinusitis, people with rhinosinusitis have significantly decreased quality of life (QOL), missed schooldays or workdays, and decreased productivity at school and/or work.[5] Rhinosinusitis affects QOL in some symptom domains more than other chronic diseases, such as chronic obstructive pulmonary disease, angina, and back pain.[6]

The term *rhinosinusitis* is used interchangeably with the term *sinusitis* in this document. *Rhinosinusitis* is the preferred term because inflammation of the sinus cavities is almost always accompanied by inflammation of the nasal cavities.

Because of the importance of rhinosinusitis, the JTF on Practice Parameters, representing the American Academy of Allergy, Asthma, and Immunology, the American College of Allergy, Asthma, and Immunology, and the Joint Council of Allergy, Asthma and Immunology, developed the first set of "Parameters for the Diagnosis and Management of Sinusitis," which was published in 1998 and then updated in 2005.[7,8] Much has happened since then with respect to new concepts in diagnosis and management and new insights into pathogenesis. For these reasons, it was decided that a revision and update was indicated.

Four documents comprise this present practice parameter on rhinosinusitis: (1) an executive summary that reviews, in narrative format, the key clinical issues considered in the parameter documents; (2) management algorithms with narrative annotations designed to assist clinical decision making; (3) a document listing only numbered summary statements that is intended to promote rapid review and identification of material comprehensively discussed in the final document; and (4) the complete guidelines document, which is organized so that the numbered key summary statements precede relevant supporting text and citations of evidence-based publications. This format provides a ready reference for any physician who evaluates and treats a patient with suspected rhinosinusitis. In particular, the algorithms and their accompanying annotations are designed to present a global and useful approach to diagnosis and management. Clinical decision points are clearly shown, and each of these proceeds stepwise to logical implementation strategies. If further justification is required at any step in the algorithms, the evidence-based guidelines text can and should be consulted. In addition, guidance about appropriate referral of refractory cases, because of treatment failure or for further investigation of possible associated conditions, is provided.

The great majority of patients with rhinosinusitis seek care from their primary care physician. Various subspecialists (allergists and otolaryngologists) also see patients with rhinosinusitis, especially patients who are more difficult to treat. It is incumbent on all physicians treating rhinosinusitis to be knowledgeable concerning the latest information on pathophysiology, diagnosis, and management, especially in light of the rapidity with which infective organisms are able to change their character.

This practice parameter includes anatomic, allergic, immunologic, and physiologic considerations, as well as clinical diagnosis, differential diagnosis, diagnostic testing, and treatment. Predisposing factors, such as allergy, upper respiratory infections (URIs), anatomic abnormalities, ciliary dyskinesia, cystic fibrosis (CF), immune deficiencies, and environmental factors, will be addressed. Medical and surgical therapies will be discussed. This document highlights differences in management of the various types of rhinosinusitis, including acute and chronic and CRS with nasal polyps (CRSwNP) and CRS without nasal polyps (CRSsNP).

An initial draft of parameters was prepared by a workgroup of experts in the field who carefully reviewed the current medical literature. Then, this material underwent extensive peer review, revision, and annotation by external reviewers and by the JTF on Practice Parameters for Allergy and Immunology, a national panel of allergist-immunologists appointed by its cosponsoring organizations: the American Academy of Allergy, Asthma and Immunology; the American College of Allergy, Asthma and Immunology; and the Joint Council of Allergy, Asthma and Immunology. The parameters were reviewed and approved by the cosponsoring organizations and thereby represent an evidence-based, broadly accepted consensus opinion.

The JTF is grateful for the cosponsoring organizations' financial support and encouragement. The JTF especially thank the many individuals who have donated substantial time and effort in producing this document that is intended to improve the quality of care of many millions of patients with rhinosinusitis.

## List of summary statements

Summary Statement 1: Apprise clinicians that the most commonly used rhinosinusitis classification is as follows. (NR)

a. Acute rhinosinusitis: symptoms for shorter than 12 weeks consisting of some or all of the following: persistent symptoms of an URI, purulent rhinorrhea, postnasal drainage, anosmia, nasal congestion, facial pain, headache, fever, cough, and purulent discharge.
b. Recurrent ARS (RARS): at least 3 episodes of ABRS in a year.
c. Chronic rhinosinusitis: symptoms for 12 weeks or longer of varying severity consisting of the same symptoms as seen in ARS. In CRS, there should be abnormal findings at endoscopy or on a sinus computed tomographic (CT) scan. CRS can be classified further as CRS with nasal polyps (wNP) or CRS without nasal polyps (sNP).

Summary Statement 2: Be aware that a tumor or an infection of the sphenoid sinus may involve adjacent structures such as the optic nerve, cavernous sinus, and carotid artery. (Rec, C)

Summary Statement 3: Suspect ABRS in patients in whom a URI persists beyond 10 days and/or show worsening after initial improvement. A history of persistent purulent rhinorrhea, postnasal drainage, and facial pain correlates with increased likelihood of bacterial disease. (Rec, A)

Summary Statement 4: Perform a CT scan when imaging of the sinuses is indicated. It is required before surgical intervention or when complications of rhinosinusitis are suspected. (StrRec, A)

Summary Statement 5: Radiographic imaging is recommended in a patient with unilateral CRS to exclude a tumor or anatomic defect or foreign body. (Rec, C)

Summary Statement 6: Perform magnetic resonance imaging (MRI) if soft tissue resolution is required, such as with a suspected tumor or in patients with complications. If a CT scan visualizes a soft tissue mass, then the patient should be referred to an ear, nose, and throat physician. (Rec, B)

Summary Statement 7: Perform an evaluation for specific IgE antibodies to airborne allergens in patients with RARS or CRS. (Rec, B)

Summary Statement 8: Physicians should recognize that nonallergic rhinitis can accompany and is in the differential of CRS. (Rec, C)

Summary Statement 9: Evaluate patients for an immune deficiency if CRS is resistant to usual medical and/or surgical therapy. (Rec, B)

Summary Statement 10: As part of an immunodeficiency evaluation, check quantitative immunoglobulins (IgG, IgA and IgM), specific antibody responses (eg, after tetanus toxoid and pneumococcal vaccine), and, if necessary, complement function and T-cell numbers (enumeration of T-cell number by flow cytometry) and function. (Rec, B)

Summary Statement 11: Evaluate patients for gastroesophageal reflux disease (GERD) if they have appropriate symptoms, realizing that it probably coexists with rather than explains the etiology of rhinosinusitis. (Opt, C)

Summary Statement 12: Be aware that a subgroup of patients with CRSwNP has allergic fungal rhinosinusitis (AFRS), which is a distinct entity associated with eosinophilic mucin and type I hypersensitivity to fungi. (Rec, B)

Summary Statement 13: Treat AFRS with a combination of surgery and systemic and/or topical corticosteroids for optimal disease control. (Rec, B)

Summary Statement 14: Consider systemic or topical antifungals as a useful adjunctive treatment for AFRS. (Rec, C)

Summary Statement 15: Consider an evaluation for CF in any patient with CRS at an early age or in any child with nasal polyps, especially if *Pseudomonas aeruginosa* is cultured from the sinuses. (Rec, B)

Summary Statement 16: Consider adjunctive use of topical therapies, including dornase alfa and/or antibiotic solutions in addition to endoscopic sinus surgery in patients with CF and CRS. (Rec, B)

Summary Statement 17: Suspect primary ciliary dyskinesia in children with recurrent otitis media, rhinosinusitis, and pneumonia with bronchiectasis, especially if situs inversus is present. (Rec, B)

Summary Statement 18: When evaluating a patient with rhinosinusitis, clinicians should look for the presence of otitis media. The converse also is true. (Rec, C)

Summary Statement 19: Treat rhinosinusitis vigorously in patients with asthma because medical and surgical management of rhinosinusitis results in objective and subjective improvement of asthma. (Rec, C)

Summary Statement 20: Treat for ABRS if symptoms last longer than 10 days or with recrudescence of symptoms after progressive improvement. (Rec, B)

Summary Statement 21: To avoid resistance and potential adverse effects from antibiotics, the workgroup recommends evaluation of $\beta$-lactam allergy by penicillin skin testing and/or graded oral challenge if $\beta$-lactam is the most appropriate antibiotic for ABRS. (Rec, B)

Summary Statement 22: Use intranasal steroids for treatment of ARS as monotherapy or with antibiotics. (Rec, B)

Summary Statement 23: Clinicians should use systemic antibiotics for acute exacerbations of CRS. However, in some patients, this may not be necessary. (Rec, C)

Summary Statement 24: Consider a 3- to 6-week course of topical antibiotics for CRS. (Rec, C)

Summary Statement 25: Consider the use of systemic antibiotics plus a short course of oral steroids in the treatment of CRS. Greater benefit with antibiotics has been reported in CRSsNP than in CRSwNP. (Rec, A)

Summary Statement 26: Consider a short course of oral steroids for the treatment of CRSsNP. (Rec, C)

Summary Statement 27: Use short-term treatment with oral steroids in CRSwNP because it decreases nasal polyp size and symptoms. (StrRec, A)

Summary Statement 28: Use intranasal corticosteroid (INS; sprays and aerosols) for the treatment of CRSwNP and CRSsNP. (StrRec, A)

Summary Statement 29: Use nasal saline irrigation as an adjunctive treatment for the therapy of CRS. (Rec, A)

Summary Statement 30: Consider antihistamines for treatment of symptoms associated with ARS in patients with coexistent CRS. (Opt, D)

Summary Statement 31: Neither oral nor topical decongestants are beneficial for maintenance treatment of CRS. (Opt, D)

Summary Statement 32: Consider aspirin desensitization followed by aspirin therapy in patients with aspirin-exacerbated respiratory disease (AERD) that is refractory to other medical therapy. (Rec, C)

Summary Statement 33: Realize that neither topical antifungals (sprays and irrigations) nor systemic terbinafine are beneficial in the treatment of CRS. (Rec, A)

Summary Statement 34: Clinicians should be apprised that, although not approved for commercial use, anti–interleukin (IL)-5 monoclonal antibody (reslizumab or mepolizumab) has demonstrated benefit in the treatment of CRSwNP. (Rec, B)

Summary Statement 35: Consider anti-IgE (omalizumab) for treatment of nasal polyps. (Rec, C)

Summary Statement 36: Consider antral puncture and irrigation in the management of acute ethmomaxillary rhinosinusitis refractory to medical therapy or for ABRS in an immunosuppressed patient in whom early identification of pathogenic organisms is paramount. (Rec, D)

Summary Statement 37: Consider ostial dilatation with a balloon in a small sub-segment of patients with medically unresponsive ARS, primarily those with early or localized disease. (Rec, D)

Summary Statement 38: Endoscopic surgical intervention may be required in ABRS to provide drainage when there is a significant risk of intracranial complication or in a patient with visual compromise or periorbital or intraorbital abscess. (Rec, C)

Summary Statement 39: Consider endoscopic surgical intervention as an adjunct to medical treatment in patients with CRS that is poorly responsive to medical therapy. (Rec, C)

Summary Statement 40: Realize that ARS in children is a self-limited process in most cases and treatment with antibiotics seems to accelerate resolution. (Rec, A)

Summary Statement 41: Use an INS as a potentially useful adjunct to antibiotics in the treatment of ABRS in children. (StrRec, A)

Summary Statement 42: Realize that ancillary therapy in the form of nasal irrigations, antihistamines, decongestants, or mucolytics has not been shown to be helpful in the treatment of ARS in children. (Opt, D)

Summary Statement 43: Realize that there are limited data to justify the use of oral antibiotics for the treatment of CRS in children. (Opt, C)

Summary Statement 44: Consider use of antibiotic therapy in acute exacerbations of CRS in children. (Rec, C)

Summary Statement 45: Use INS in the treatment of CRS in children. (Rec, C)

Summary Statement 46: Realize that surgery is used much less frequently in the management of CRS in children compared with adults and that the mainstay of therapy is medical. (Rec, C)

Summary Statement 47: Consider adenoidectomy with or without maxillary sinus irrigation as the first-line surgical therapy in children with CRS. (Rec, C)

## Executive summary

Rhinosinusitis, defined as inflammation of at least 1 paranasal sinus, is characterized as acute when lasting shorter than 12 weeks and chronic when lasting at least 12 weeks. RARS consists of at least 3 episodes of ABRS per year. CRS is further subdivided into CRSwNP and CRSsNP. Viral URIs frequently precede subsequent bacterial infection of the sinuses by *Streptococcus pneumoniae*, *Haemophilus influenzae*, and *Moraxella catarrhalis*, the most frequent bacterial causes of ABRS. Other important organisms also can be found in CRS, such as *Staphylococcus aureus*, *P aeruginosa*, and certain anaerobes.

### *ABRS and RARS*

Acute bacterial rhinosinusitis is diagnosed in patients with URIs persisting longer than 10 to 14 days. Prominent symptoms of ABRS include nasal congestion, purulent rhinorrhea, facial-dental pain, postnasal drainage, headache, and cough. Patients may have sinus tenderness on palpation, mucosal erythema, and discolored nasal and oropharyngeal secretions. Fever may or may not be present. ABRS is mostly a clinical diagnosis and radiologic confirmation is not essential except in complicated cases. Patients with RARS are asymptomatic or have mild rhinitis symptoms between episodes of acute infections.

The primary therapy for ABRS is antibiotics. The choice is based on predicted efficacy, cost, and side effects. A 10- to 14-day course is generally adequate for acute disease, although shorter courses may be adequate with some antibiotics. If there is no improvement in 3 to 5 days, then an alternative antibiotic should be considered.

Concern has been raised about the overdiagnosis of ABRS and RARS and unnecessary treatment with antibiotics. Appropriate criteria for the use of antibiotics are symptoms of rhinosinusitis for 10 to 14 days, symptoms of a cold that improve and then worsen over a 7- to 10-day period, or severe symptoms of acute sinus infection, including fever with purulent nasal discharge, facial pain or tenderness, and periorbital swelling. To use the most appropriate antibiotic in patients with RARS, sinus secretions can be obtained for culture in adults by an aspiration of the maxillary sinus or an endoscopically directed culture from the middle meatus.

There is both clinical and experimental evidence that allergic rhinitis (AR) might predispose to ABRS or RARS. In young adults with ABRS, there is a reported incidence of AR ranging from 25% to 31%.[9,10]

### *Chronic rhinosinusitis*

Chronic rhinosinusitis symptoms are similar to ABRS symptoms but may be even more subtle. Pain is much less a feature of CRS compared with ABRS, whereas nasal congestion and hyposmia or anosmia are prominent in CRSwNP and CRSsNP but more common in CRSwNP. The constellation of symptoms, including chronic congestion, facial pressure, purulent post nasal drip, throat clearing, coughing, and anosmia or hyposmia, should raise the question that the patient may have CRS.

There is an overlap in these symptoms with those of perennial rhinitis, and endoscopy or an imaging procedure is necessary to confirm the diagnosis. Imaging techniques can provide confirmatory evidence of CRS when symptoms are vague, physical findings are equivocal, or clinical disease persists despite optimal medical therapy. The imaging technique of choice is CT scanning because it can depicts abnormalities in the ostiomeatal complex and the sinus cavities.

Evaluation of CRS or RARS might include aeroallergen testing, sinus cultures, and tests for immunodeficiency, cystic fibrosis, or ciliary dysfunction. Several factors associated with rhinosinusitis should be considered. Probably the most common is viral URTIs, which usually precede ABRS and may contribute to CRS. AR and/or nonallergic rhinitis (NAR) are closely associated with ABRS and CRS. Up to 30% to 80% of patients with CRS have been documented to have AR.[11–13] NAR was found in 26% of patients with CRS.[13] Tests for immunodeficiency, including quantitative immunoglobulin measurement, functional antibody tests, and human immunodeficiency virus testing, might be useful if congenital or acquired immunodeficiency is suspected in cases of CRS. Quantitative sweat chloride testing and genetic testing for diagnosis of CF and/or primary ciliary dyskinesia should be considered in children with nasal polyps and/or sinonasal colonization with *Pseudomonas* spp.

Asthma, GERD, and otitis media are often comorbid diseases associated with CRS. Although no direct causal factor between CRS and asthma has been found, some studies in children and adults suggest that medical management and/or surgical management of CRS often results in objective and subjective improvement of asthma.

The role of antibiotics in CRS is controversial. For CRS associated with suspected bacterial infection, a longer duration of therapy beyond the usual 10 to 14 days is suggested; the choice of appropriate antibiotic therapy may need to consider the possible presence of anaerobic pathogens. Concurrent oral steroids have been shown to be of benefit, especially in CRSwNP.

Because CRS is an inflammatory disease, INSs are indicated for treatment. Other adjunctive therapy, such as intranasal antihistamines, decongestants, saline irrigation, mucolytics, and expectorants, might provide symptomatic benefit in select cases. The use of immunoglobulin replacement therapy is indicated only in patients

with proven functional impairment of humoral immunity. The beneficial effects of aspirin desensitization in patients with AERD have been well described. Medically resistant CRS might respond to appropriate sinonasal surgery.

Consultation with a specialist should be sought regarding CRS or RARS when (1) there is a need to investigate a possible allergic or immunologic risk factor, (2) disease is refractory to the usual treatment, (3) disease is recurrent, (4) disease is associated with unusual opportunistic infections, or (5) disease significantly affects performance and QOL. Consultation also is appropriate when concomitant conditions are present that complicate assessment or treatment, including chronic otitis media, asthma, nasal polyps, recurrent pneumonia, recurrent or chronic bronchitis, severe headaches, immunodeficiency, aspirin sensitivity, allergic fungal disease, granulomas, and multiple antibiotic sensitivities.

*Algorithm for ARS (Fig 1)*

*Annotations to algorithm*

1. Symptoms suggestive of ARS
   - Prominent symptoms include nasal congestion, purulent rhinorrhea, postnasal drainage, facial or dental pain, headache, throat clearing, and cough.
   - Any patient with orbital swelling or pain, swelling of the forehead, and/or diplopia should be urgently evaluated.

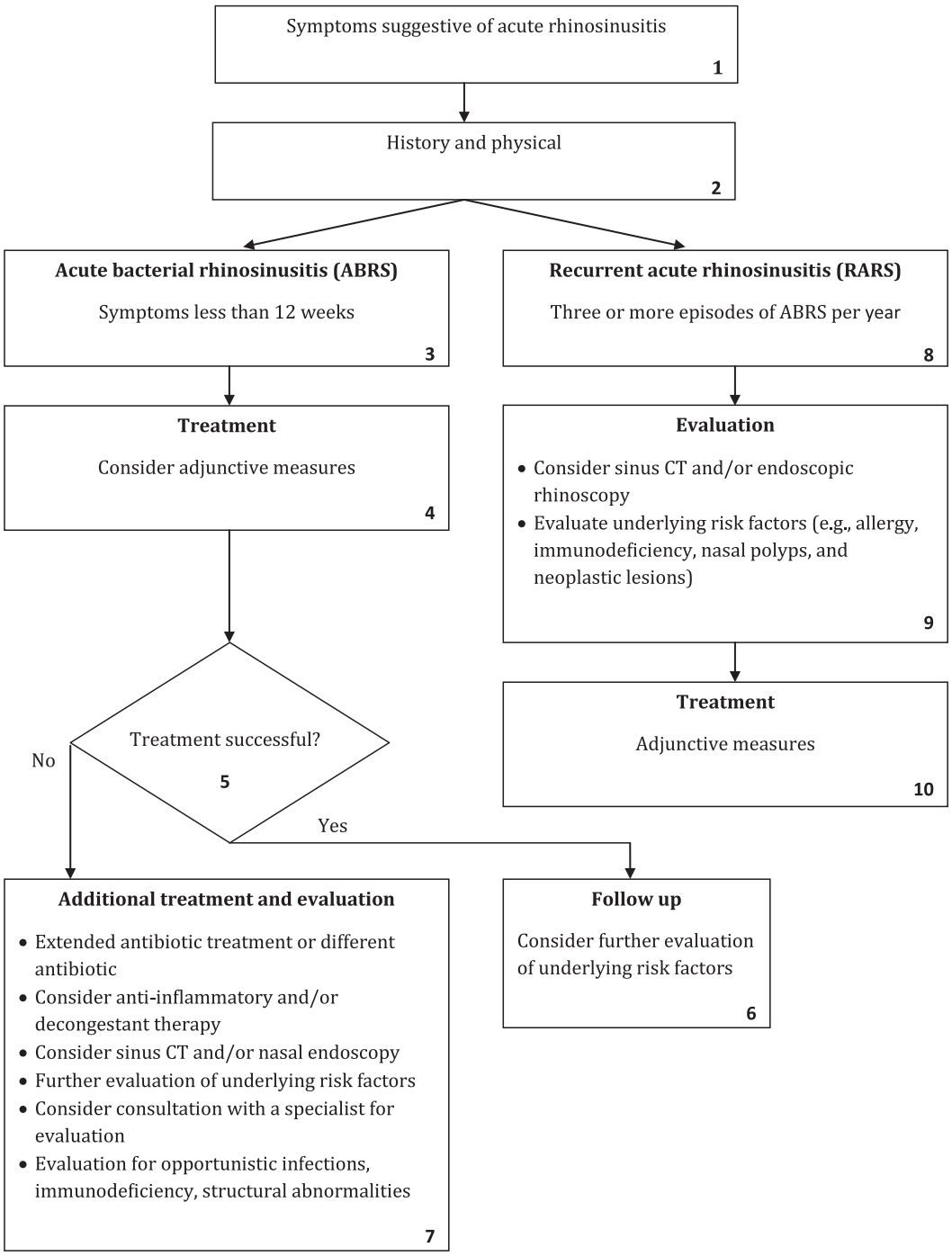


**Figure 1.** Algorithm for acute bacterial rhinosinusitis (ABRS) and recurrent acute rhinosinusitis (RARS).

- Children also might exhibit increased irritability and vomiting occurring in association with gagging on draining mucus and/or prolonged cough.
- Less frequent symptoms associated with ARS include fever, nausea, malaise, irritability, fatigue, halitosis, hyposmia, and sore throat.

2. History and physical
   - Review medical history for diagnosis of ARS and underlying risk factors.
   - General examination includes an evaluation for signs of upper airway and sinus inflammation associated with nasal mucosal edema and purulent secretions. Typical clinical signs may include tenderness overlying the sinuses, dark circles beneath the eyes, and/or periorbital edema. Pharyngeal erythema, lymphoid hyperplasia, and purulent material in the posterior pharynx also are frequently observed.
   - Nasal examination in patients with ARS might show mucosal erythema and purulent secretions. Nasal polyps might contribute to nasal congestion. ARS may initiate or worsen asthma and bronchial hyperresponsiveness. Accordingly, chest auscultation and other objective measurements of airflow obstruction, such as office spirometry, should be considered in any patient with possible rhinosinusitis and cough.
3. Acute bacterial rhinosinusitis
   - Acute bacterial rhinosinusitis is defined as symptoms and signs for less than 12 weeks. The diagnosis of ARS is based primarily on the clinical history, the physical examination, and possibly other ancillary evaluations, including endoscopy or radiographic imaging. In most instances the diagnosis is made presumptively, and treatment is initiated.
   - Patients with obvious ABRS should be carefully reviewed for any possible evidence of complicating factors, including the presence of facial swelling, erythema over an involved sinus, visual changes, abnormal extraocular movements, proptosis, periorbital inflammation, any suggestion of intracranial involvement, or central nervous system involvement manifested as abnormal neurologic signs.
4. Treatment of ABRS
   - Empiric treatment with an antibiotic approved by the Food and Drug Administration (FDA) should be started once the diagnosis is made. Empiric therapy is administered for 7 to 14 days. FDA-approved antibiotics include amoxicillin, amoxicillin-clavulanate, cefaclor, cefprozil, cefuroxime, cefdinir, cefixime, azithromycin, levofloxacin, trimethoprim-sulfamethoxazole, doxycycline, and clindamycin. Fluoroquinolones and doxycycline should be avoided in children. Detailed treatment recommendations are noted in the treatment sections for adults and children. Nasal steroids may be of benefit, especially in allergic individuals.
   - The following comfort measures might be helpful: adequate rest, adequate hydration, analgesics as needed, warm facial packs, steamy showers, and sleeping with the head of the bed elevated. Prevention measures might include appropriate treatment of AR and viral URTIs and avoidance of adverse environmental factors, such as relevant allergens, cigarette smoke, pollution, or barotrauma. Patients should be instructed to follow up if symptoms worsen (eg, especially with headache or high fever) or if symptoms have not improved within 3 to 5 days of treatment (see Annotation 10).
5. Treatment successful?
   a. Complete response (see Annotation 6)
   - Patient is improved symptomatically to near normal.

   b. Partial response
   - Patient is symptomatically improved but not back to normal at the end of the first course of antibiotics.

   c. Poor response
   - Patient has little or no symptomatic improvement after the first course of antibiotic therapy.
6. Follow-up
   - No further evaluation for resolved uncomplicated rhinosinusitis. Consider further evaluation of underlying risk factors.
7. Additional treatment and evaluation
   - For partial response, continue antibiotic treatment for another 10 to 14 days or consider a different antibiotic.
   - For poor response, which worsens after 3 to 5 days, consider broadening the microbial coverage provided by the antibiotic or switch to a different antimicrobial that covers resistant bacteria.
   - Rhinosinusitis that fails to improve after 21 to 28 days of initial antibiotic treatment might be caused by pathogens not adequately covered by prior antibiotics, nasal polyps, tumor, or noncompliance.
   - Reinforce the comfort and prevention measures outlined in Annotation 4. Consider a sinus CT scan if not already done.
   - Underlying risk factors should be evaluated in a more detailed manner.
   - Consider consultation with an allergist-immunologist for treatment of underlying allergic factors and evaluation of unusual pathogens and immunodeficiency. For structural abnormalities, consultation should be sought with an otolaryngologist.
8. Recurrent ARS: Repeated episodes of acute rhinosinusitis typically at least 3 times per year.
9. Patients with RARS should have objective evidence of disease by anterior nasal examination, nasal endoscopy, or sinus CT scan. They should be evaluated for underlying inflammation, allergy, immunodeficiency, and anatomic abnormalities. Culture of the drainage is appropriate.
10. Treatment:
    - Recurrent ARS: Treat for ABRS (see Annotation 4).

*Algorithm for CRSsNP (Fig 2)*

*Annotations to algorithm*

1. Chronic rhinosinusitis
   - Signs and symptoms compatible with rhinosinusitis persisting at least 12 weeks.
2. Evaluation
   - History and physical examination should categorize patients as having CRSsNP or CRSwNP. General examination includes an evaluation for signs of upper airway and sinus inflammation. Typical clinical signs may include tenderness overlying the sinuses, dark circles beneath the eyes, and/or periorbital edema. Pharyngeal erythema, lymphoid hyperplasia, and purulent material in the posterior pharynx also are frequently observed. Nasal examination in patients with rhinosinusitis might show mucosal erythema, edema, and purulent secretions. Ear examination in patients with suspected rhinosinusitis may show middle ear effusions.
   - Evaluation should include coronal sinus CT scan to clarify the extent of disease and specific location or locations of obstruction. The CT scan ideally should be performed 4 to 6 weeks after initiation of medical therapy.
3. Treatment
   - See treatment section for CRS.
4. Treatment successful?
   - See Annotations 5 and 6.
5. Follow-up
   - Patients benefit from continued individualized medical therapy, including, when indicated, allergy management.
6. Additional treatment and evaluation
   - Consider evaluation by otolaryngologist.

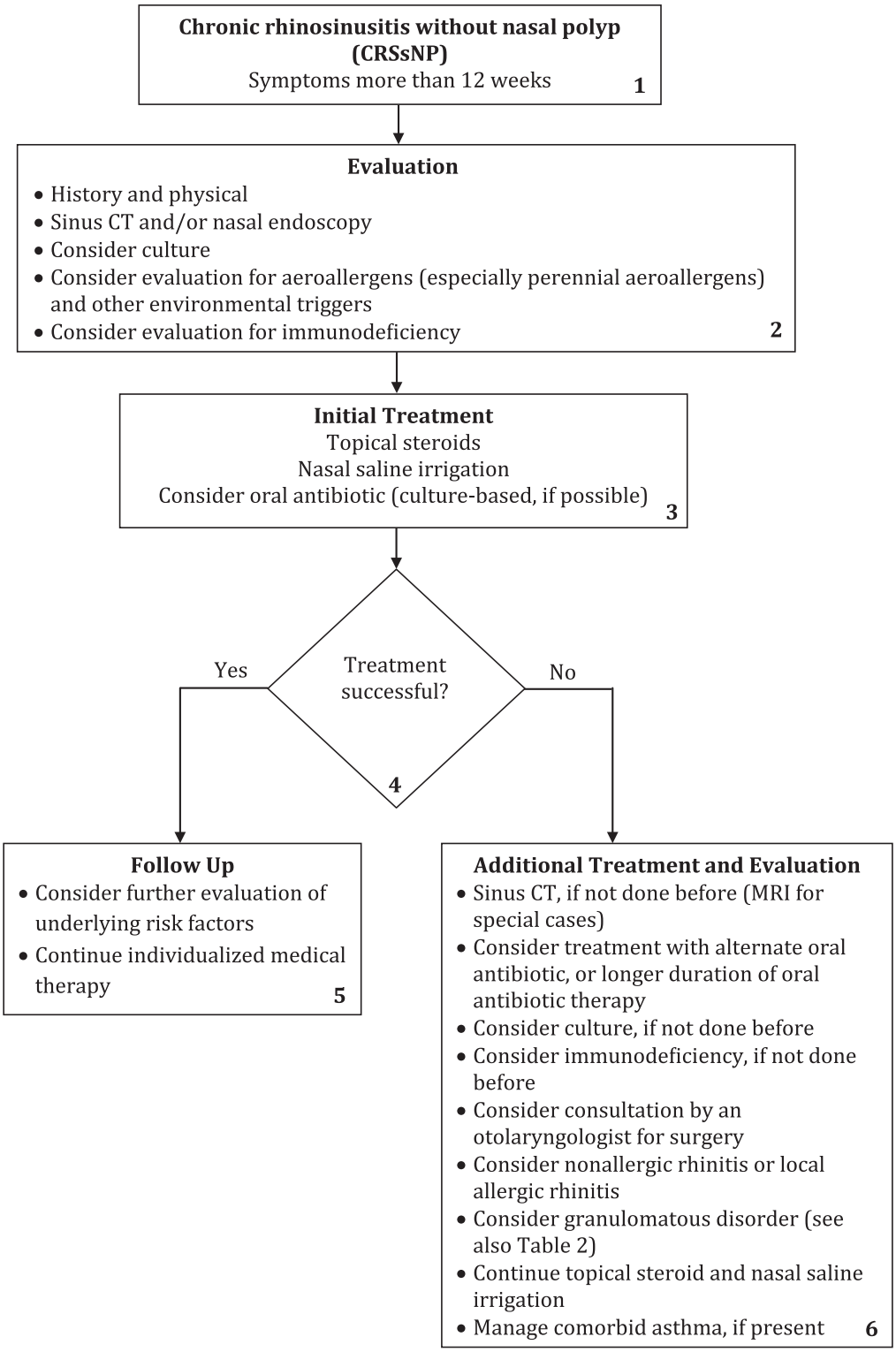


**Figure 2.** Algorithm for chronic rhinosinusitis without nasal polyp (CRSsNP).

- Manage asthma as necessary.
- Consider evaluation for AFRS, opportunistic infections, and immunodeficiency.

7. Treatment successful?
   a. Yes: see Annotation 6.
   - Continue individualized medical therapy, including, when indicated, allergy management.

   b. No: see Annotations 5 and 6.

*Algorithm for CRSwNP (Fig 3)*

*Annotations to algorithm*

1. Chronic rhinosinusitis (CRSwNP)
   - Signs and symptoms compatible with rhinosinusitis persisting at least 12 weeks.
   - Evidence of nasal polyps by direct examination, endoscopy, or sinus CT scan.

2. Evaluation
   - Nasal examination in patients with rhinosinusitis may show mucosal erythema, edema, and purulent secretions in addition to polyps. Evaluation should include coronal sinus CT scan to clarify the extent of disease and specific location or locations of obstruction. The CT scan should ideally be performed 4 to 6 weeks after initiation of medical therapy.
   - Nasal polyps are relatively uncommon in children, and their presence should prompt evaluation for possible CF.
3. Treatment
   - See treatment section.
4. Treatment successful?
   - See Annotations 5 and 6.
5. Follow-up
   - Patients benefit from continued individualized medical therapy, including, when indicated, allergy management.
6. Additional treatment and evaluation
   - Consider evaluation by otolaryngologist.
   - Manage asthma as necessary.
   - For AERD, consider aspirin desensitization.
   - Consider evaluation for AFRS, opportunistic infections, and immunodeficiency.

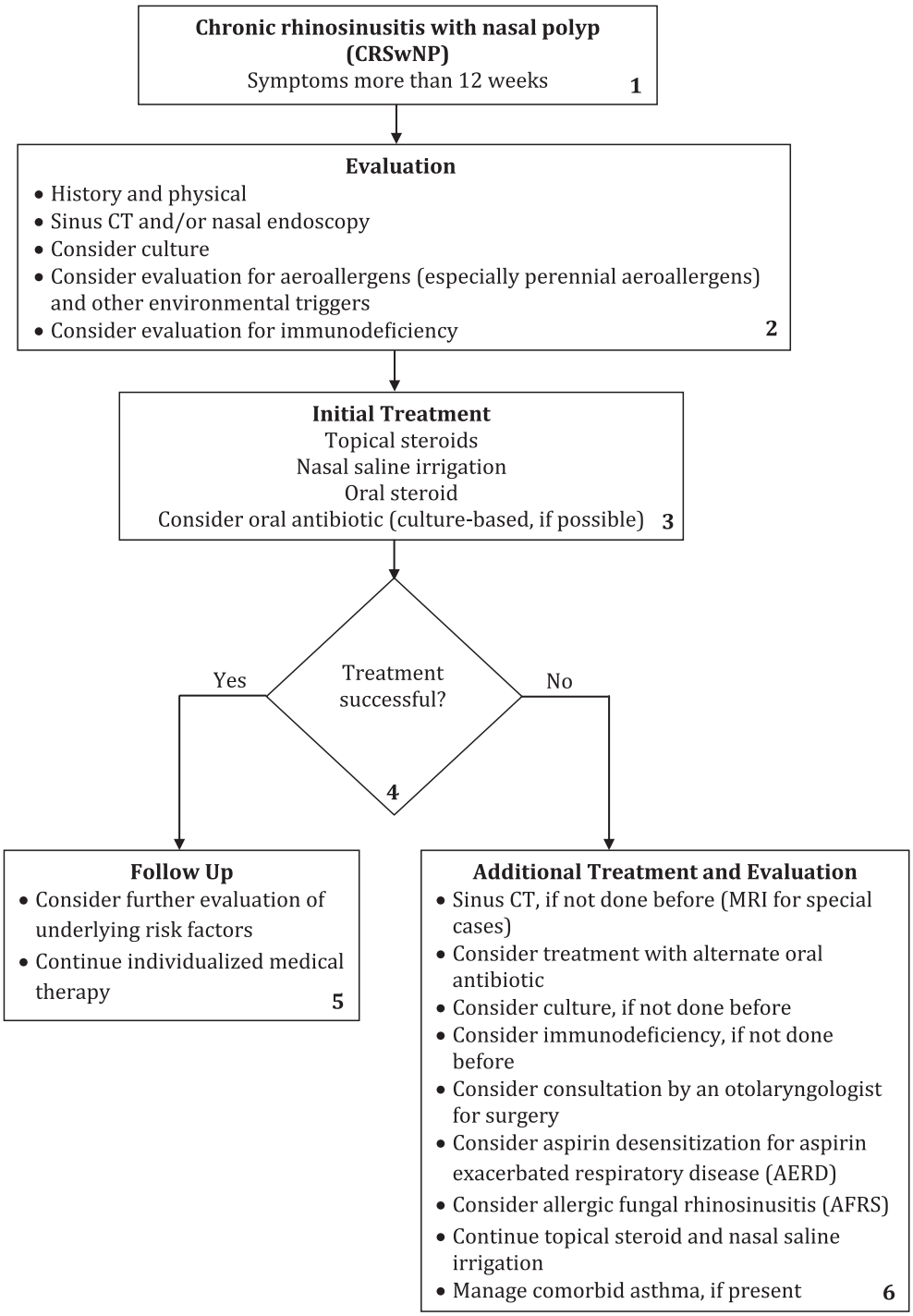


**Figure 3.** Algorithm for chronic rhinosinusitis with nasal polyp (CRSwNP).

**Table 1**
Symptoms of rhinosinusitis

| Disease | Duration | Symptoms[a] |
|---|---|---|
| Acute bacterial rhinosinusitis (ABRS) | >10 days but <12 weeks | anterior or posterior purulent drainage associated with ≥1 of the following: nasal congestion or blockage, facial pain, fever, headache, dental pain, cough, throat clearing, sore throat |
| Recurrent acute rhinosinusitis (RARS) | ≥3 episodes/year each lasting ≥7 days | same as acute but asymptomatic between episodes |
| Chronic rhinosinusitis without nasal polyps (CRSwNP) | >12 weeks | nasal obstruction or blockage, facial pressure or pain, anterior or posterior purulent nasal drainage are dominant; other symptoms can include hyposmia or anosmia, headache, halitosis, fatigue, dental pain, cough, throat clearing, ear pain, pressure, or fullness |
| Chronic rhinosinusitis with nasal polyps (CRSsNP) | >12 weeks | hyposmia or anosmia, headache, halitosis, fatigue, dental pain, cough, throat clearing, ear pain, pressure or fullness; symptoms may be vague and nasal congestion and hyposmia or anosmia predominate |

## Complete guidelines and references

### *Definitions*

*Summary statements*

Summary Statement 1: Clinicians should be apprised that the most commonly used rhinosinusitis classification is as follows: (NR)

a. Acute rhinosinusitis: symptoms for shorter than 12 weeks consisting of some or all of the following: persistent symptoms of a URI, purulent rhinorrhea, postnasal drainage, anosmia, nasal congestion, facial pain, headache, fever, cough, and purulent discharge.
b. Recurrent ARS: at least 3 episodes of ABRS in a year.
c. Chronic rhinosinusitis: symptoms for at least 12 weeks of varying severity consisting of the same symptoms as seen in ARS. In CRS there should be abnormal findings at endoscopy or on a sinus CT scan. CRS can be classified further as CRSwNP or CRSsNP.

It is accepted that the proper term for the syndrome is *rhinosinusitis* rather than *sinusitis* for the following reasons[14–16]: rhinitis typically precedes sinusitis; sinusitis without rhinitis is rare; the mucosa of the nose and sinuses are contiguous; and symptoms of nasal obstruction and nasal discharge are prominent in sinusitis. Rhinitis associated with sinusitis can be allergic, bacterial, viral, or nonallergic. Rhinosinusitis is classified as acute, chronic, or recurrent. It should be emphasized that this classification is entirely arbitrary but is the classification term accepted by most. In ARS, symptoms are present for shorter than 12 weeks. Symptoms consist of some or all of the following: persistent symptoms of a URI, purulent rhinorrhea, postnasal drainage, anosmia, nasal congestion, facial pain, headache, fever, throat clearing and cough. RARS is defined as at least 3 episodes of ABRS per year. Individuals may be asymptomatic between episodes.

Chronic rhinosinusitis is defined as persistent sinus inflammation for longer than 12 weeks. An operational definition of CRS is persistent inflammation documented with imaging techniques at least 4 weeks after initiation of appropriate medical therapy in the absence of an intervening acute episode.[17] In contrast to ABRS, the role of bacterial infection in CRS is less certain.[18]

The symptom-based definition of CRS has been brought into question. In 1 study, more than 50% of patients with a strong history suggestive of CRS had a normal CT scan.[19] It is still debated whether a CT scan also provides the definitive diagnosis of this disorder. CRS is divided into CRSwNP and CRSsNP. CRSsNP is thought to be primarily infectious; however, underlying inflammation may play a role. CRSsNP may be associated with a significant influx of neutrophils. CRSwNP is marked by a preponderance of eosinophils and mixed mononuclear cells, with a relative paucity of neutrophils, although literature from Asian countries suggests that some nasal polyps may be associated with neutrophilic inflammation.[20] CRSwNP may associated with asthma and aspirin sensitivity and this constellation of findings has been classified as AERD.[21] In some recalcitrant cases of CRSwNP, there may be marked inflammation due to IgE-mediated hypersensitivity to fungal antigens.[22] This entity is called *allergic fungal rhinosinusitis*. CRSsNP also is frequently associated with asthma and rhinitis.

## Anatomic considerations

Summary Statement 2: Be aware that a tumor or an infection of the sphenoid sinus may involve adjacent structures, such as the optic nerve, cavernous sinus, and carotid artery. (Rec, C)

### *Development*

The maxillary sinus is the first to begin significant pneumatization from birth to 12 months. The floor of the maxillary sinus reaches the level of the floor of the nose by approximately 12 years of age. Rudimentary ethmoid sinuses are present at birth and reach adult size at 12 to 14 years of age.[23] Development of the frontal and sphenoid sinuses begins later than that of the ethmoid sinuses, and complete pneumatization is not achieved until mid to late adolescence.[24] Although the degree of pneumatization of all sinuses is highly variable, the variability in pneumatization of the frontal and sphenoid sinuses is greater than that of the ethmoid and maxillary sinuses.[25] One or both frontal sinuses are hypoplastic or completely absent in about 15% of the population, and the sphenoid sinus is rudimentary (conchal or presellar pneumatization) in 26% of

**Table 2**
Differential diagnosis of chronic rhinosinusitis

| |
|---|
| Allergic rhinitis: seasonal or perennial |
| Nonallergic rhinitis: nonallergic rhinopathy, vasomotor rhinitis, nonallergic rhinitis with nasal eosinophilia syndrome |
| Mixed rhinitis (allergic and nonallergic components) |
| Rhinitis medicamentosa: decongestants, antihypertensives (eg, $\beta$-blockers), birth control pills |
| Rhinitis or congestion secondary to pregnancy, hypothyroidism, Horner syndrome, granulomatosis with polyangiitis (aka Wegener granulomatosis), midline granuloma, periapical abscess |
| Anatomic abnormalities causing rhinitis and/or congestion: foreign body, nasal septal deviation, enlarged tonsils and adenoids, concha bullosa and other middle turbinate abnormalities, paradoxical curvature of middle turbinate, Haller cells |
| Migraines and facial pain syndromes |

patients. There is evidence to suggest that rhinosinusitis in childhood might inhibit sinus development.[26] This is further supported by a study by Woodworth et al[27] showing that individuals homozygous for the ⊿F508 mutation in CF transmembrane conductance regulator gene (*CFTR*) have a greater incidence of hypoplastic or underdeveloped sinuses. Because of their later development, frontal or sphenoid disease is uncommon in childhood.

*Anatomy*

The anterior ethmoid, frontal, and maxillary sinuses drain into the middle meatus through a relatively convoluted and narrow drainage pathway (ostiomeatal complex) rather than by simple ostia. The ethmoid sinuses consist of a honeycomb of cells lying medial to the orbital structures and varying from 4 to 17 air cells in number. They also might pneumatize to a variable extent above (supraorbital) or below (infraorbital) the orbit. The ethmoid sinus is divided into an anterior group of cells (draining through the ostiomeatal complex into the middle meatus) and a posterior group of cells (draining into the superior meatus).[28] The maxillary sinus lies between the teeth and the orbit on both sides and drains into the middle meatus through a channel in its supra-medial aspect. The paired frontal sinuses arise from the region of the anterior ethmoid and extend superiorly into the forehead. Valveless veins that pass through the posterior wall of the frontal sinus might allow the spread of frontal sinus infection intracranially, particularly in acute infection. The sphenoid sinuses also are paired and lie posterior and slightly inferior to the posterior ethmoid cells. They drain by separate relatively large ostia into the sphenoethmoidal recess on either side of the nasal septum posteriorly. The optic nerve courses over the sphenoid sinus laterally and superiorly. The carotid artery indents the sinus laterally, and the sphenoid sinus has an intimate relation with the cavernous sinus and the dura of the anterior and middle cranial fossa.

The anatomic arrangement of the sinuses makes the frontal, anterior ethmoid, and maxillary sinuses dependent on the ostiomeatal complex for their ventilation and mucociliary clearance. Significant obstruction of this complex can predispose to the development of rhinosinusitis. Because ethmoid anatomy is extremely variable and dependent, to some extent, on the position of the nasal septum, there is a potential for anatomic variations to cause ostiomeatal obstruction. There is an ongoing debate about the importance of anatomic variations in predisposing to CRS, acting by redirection of airflow or by direct compression.[29,30]

In some situations, the ethmoid cells might pneumatize into the head of the middle turbinate (a variation known as *concha bullosa*) and extreme middle turbinate aeration; greatly enlarging the turbinate might narrow the ostiomeatal complex enough to predispose toward rhinosinusitis. The location of the anterior ethmoid sinuses and middle meatus makes the ostiomeatal complex particularly at risk from environmental exposures, and this region is typically the first and the most frequently involved region in CRS. Indeed, low-grade edema and inflammation can persist within this region, resulting in intermittent episodes of inflammation in the dependent sinuses. When such edema does not respond to medical therapy, endoscopic surgical intervention might be required.

*Sinus physiology*

The sinus cavities are filled with air, with classic, pseudostratified, ciliated columnar epithelia interspersed with goblet cells. The cilia sweep mucus toward the ostial opening. Obstruction of the ostia can lead to mucous impaction and decrease oxygenation in the sinus cavities. This in turn might lead to further complications (discussed later). There is limited gas exchange in the sinuses when there is ostial obstruction, and with obstruction, oxygen concentrations can decrease to close to 0%. The development of this anaerobic condition is seen only with purulent secretions and not with nonpurulent secretions. The growth of bacteria within an impacted sinus cavity is facilitated by this anaerobic environment.

When there is obstruction of the ostia, the air pressure within the sinus cavity can decrease, which in turn causes pain and the sensation of pressure, particularly in the frontal region.[31] This pressure decrease can range from 20 to 30 mm $H_2O$, with the lowest pressure being 266 mm $H_2O$. Transudation into the cavity starts when the pressure is lower than 20 to 30 mm $H_2O$ below 0 mm $H_2O$. This decrease in pressure is preceded by a transient pressure increase caused by an increase in carbon dioxide, whereas the decrease in pressure is principally caused by oxygen usage and absorption.[32] However, in acute purulent sinusitis, the pressure sometimes can be as high as 100 mm $H_2O$.[33] Purulent secretions have a low oxygen content, and the pain patients perceive might be due to a combination of inflammation of the mucosa and pressure from intra-sinus secretions pressing on the inside walls of the sinus.

During deep sea diving, the change in sinus pressure can be very high, causing transudation, bleeding, and edema, especially when pressures exceed 350 to 500 mm $H_2O$. During flying, there is usually less change in pressure than during diving. When there is obstruction of the ostia, changes in sinus pressure similar to those of diving can occur with flying, which is why pilots are not permitted to fly when they have a cold.

Multiple investigations have highlighted a possible role for sinonasal bacterial biofilms in the persistence of recalcitrant CRS.[34–38] Sinonasal biofilms consist of complex organized microbial communities of bacteria and fungus, which anchor to the mucosal surfaces or exist within the mucus layer. Biofilms are characterized morphologically by the formation of microbial towers composed of layers of embedded, live bacteria with intervening water channels, and a "mortar" composed of a bacterially extruded exo-polymeric matrix (protein and nucleic acid).[39] Biofilms allow for the evasion of host defenses, decreased susceptibility to antibiotic therapy, and deliberate release of planktonic bacteria, resulting in implantation and population of new anatomic locations, thereby causing nascent acute infections in the host.[40,41] Recently, a genetic predisposition for the development of sinonasal biofilms has been described implicating a novel component of upper respiratory innate defense, the bitter taste receptor T2R38.[42,43] Substantial effort continues to be invested in developing anti-biofilm interventions for patients with CRS.

## Microbiology

Summary Statement 3: Suspect ABRS in patients in whom a URTI persists beyond 10 days and/or show worsening after initial improvement. A history of persistent purulent rhinorrhea, postnasal drainage, and facial pain correlates with an increased likelihood of bacterial disease. (Rec, A)

*Bacterial rhinosinusitis*

To determine the microbiology of sinus infections involving the maxillary sinus, the best measurement, or reference standard, is to perform an aspirate of the maxillary sinus.[44,45] Ideally, the nasal mucosa would be sterilized in the area beneath the inferior turbinate through which the trocar will be passed to insure that contamination is eliminated or decreased. Alternatively, the maxillary sinus can be accessed through puncture of the anterior wall, which is approached transorally through the canine fossa. Quantitative cultures should be performed or at least a Gram stain should be prepared to estimate the density of infection. Infection is documented when a bacterial species is recovered in a density of at least $10^3$ to $10^4$ cfu/mL.

Recently, there has been enthusiasm for obtaining cultures of the middle meatus endoscopically as a surrogate for cultures

obtained from sinus aspirates. Although some studies in adults have suggested good correlation between the pathogenic organisms isolated in the middle meatus and those in the maxillary sinus (when interpretation is confined to the 3 common microorganisms, *S pneumoniae*, *Helicobacter influenzae,* and *M catarrhalis*), further verification of this approach is warranted. The correlation between endoscopic middle meatal culture and maxillary sinus puncture was only 78% in pediatric patients with rhinosinusitis.[46] In healthy children, the middle meatus is colonized with the same bacterial species that are commonly recovered from children with sinus infections.[47] Accordingly, the recovery of such organisms in a symptomatic child cannot confirm the presence of infection. The bacterial species recovered from the middle meatal samples of healthy adults are coagulase-negative staphylococci, *Corynebacterium* species, *S aureus,* and *Propionobacterium acnes*.[48]

### *Acute bacterial rhinosinusitis*

The microbiology of paranasal sinus infections can be anticipated according to the age of the patient, clinical presentation, and immunocompetence of the host.[49–52] In ABRS, viral URIs frequently precede bacterial superinfection by *S pneumoniae*, *H influenzae*, and *M catarrhalis*.[49–51] Pneumococcal conjugate vaccine (PCV13) was licensed in 2010. It is probable that the relative prevalence of *S pneumoniae* as a cause of ABRS is decreased and that *H influenzae* is increased since then. *Moraxella catarrhalis* and *H influenzae* can produce $\beta$-lactamase and thereby be resistant to amoxicillin. The prevalence of *S pneumoniae* is stable; approximately 10% of respiratory isolates of *S pneumoniae* will be intermediate or highly resistant to penicillin.[53–58] In children and adults with ABRS, the role of *S aureus* as a pathogen is controversial.[44]

### *Chronic rhinosinusitis*

Assessing the microbiology of CRS has been particularly difficult. Aspirates are frequently performed immediately after or during a course of antimicrobials that has failed to eliminate the patient's symptoms. Furthermore, sterilization of the mucosa and quantitation of isolates are infrequently performed. The frequent recovery of coagulase-negative staphylococci (*Staphylococcus epidermidis*), viridans streptococci, and diphtheroids are good examples of the dilemma. A large multicenter study assessing bacteriologic findings in adults with chronic bacterial maxillary rhinosinusitis was reported in 2002.[52] The most commonly isolated anaerobes were *Prevotella* species (31%), anaerobic streptococci (22%), and *Fusobacterium* species (16%). The aerobes most frequently recovered included *Streptococcus* species (21%), *H influenzae* (16%), *P aeruginosa* (16%), *S aureus* (10%), and *M catarrhalis* (10%). In a study looking at acute exacerbations of CRS, there were a larger percentage of anaerobic organisms and organisms similar to those recovered from patients with CRS at baseline. In addition to anaerobic bacteria, aerobic bacteria found in ABRS were recovered during acute exacerbations of CRS.[59] Recently, there has been an increase in the recovery of *S aureus*, especially methicillin-resistant *S aureus* from patients with ARS and CRS.[60] It has been suggested that staphylococcal enterotoxin acting as a superantigen might trigger an enhanced immune response, resulting in nasal polyp formation and CRS.[61]

One of the best studies of children with CRS was reported recently by Hsin et al.[46] They evaluated 165 children 4 to 16 years old with 12 weeks of purulent nasal drainage and nasal congestion. A maxillary sinus puncture was performed after disinfection with iodine or alcohol. There were 3 potential limitations: (1) no test of sterility after "sterilizing" the nose; (2) no quantitation of the bacteria recovered; and (3) no restriction on the interval from antibiotic therapy to maxillary sinus puncture. The most commonly identified bacteria were $\alpha$-hemolytic streptococcus (20.8%), *H influenzae* (19.5%), *S pneumoniae* (14.0%), *S epidermidis* (13.0%), and *S aureus* (9.3%). Anaerobes were recovered from 8.0% of all isolates. The predominance of *S epidermidis*, $\alpha$-hemolytic streptococci, and other normal respiratory flora indicates that many isolates obtained from patients with CRS may represent contamination from the nasal cavity.

Few studies have examined microbiology in CRSwNP. Brook and Frazier[62] recovered bacterial growth from 96% of aspirates that were obtained from 48 inflamed maxillary sinuses from patients with CRSwNP. Polymicrobial aerobic and anaerobic flora were recovered from most aspirates.

In contrast to community-acquired rhinosinusitis, the usual pathogens in nosocomial rhinosinusitis are gram-negative enteric species (eg, *P aeruginosa*, *Klebsiella pneumoniae*, *Enterobacter* species, *Proteus mirabilis*, and *Serratia marcescens*) and gram-positive cocci (occasionally streptococci and staphylococci).[63,64]

Traditional culture based assessment of the nasal and sinus mucosa has typically shown bacteria that grow easily under laboratory conditions. Recently, the microbiome of the nasal and sinus cavities has been assessed using molecular approaches. Using comparative microbiome profiling, Abreu et al[65] found decreased bacterial diversity in patients with CRS compared with healthy controls. Specific lactic acid bacteria were depleted and *Corynebacterium tuberculostearicum* was increased. They confirmed the pathogenic role of *C tuberculostearicum* in a murine rhinosinusitis model. In addition, *Lactobacillus sakei* was shown to be a potentially protective species against *C tuberculostearicum*–induced sinusitis in a mouse model.

Another study assessed the bacterial flora of the sinus cavity using conventional culture, molecular diagnostics, and fluorescence in situ hybridization.[66] They detected microbes in all samples including controls using molecular techniques compared with 73% of patients with CRS and 33% of controls who had positive conventional cultures. Seventy-nine percent of patients with CRS and 50% of controls had polymicrobial growth detected using the molecular diagnostics. Patients with CRS had significantly greater bacterial genomes per sample than controls. *Staphylococcus aureus* was the most commonly detected organism in patients with CRS and was more abundant in patients with CRS compared with controls. Similar results were obtained by Feazel et al[67] who reported that patients with CRS had a significantly different microbial community compared with controls and had an abundance of *S aureus*.

### *Fungal rhinosinusitis*

Fungal rhinosinusitis can take 1 of 3 forms: AFRS, fungus ball, or fulminant invasive fungal sinusitis. AFRS and fungus ball are considered noninvasive forms of sinus infections. Classic AFRS invariably occurs in immunocompetent patients with asthma and nasal polyps. AFRS is presented later in the document. A fungus ball typically occurs in the maxillary or sphenoid sinuses and is usually unilateral.[68] The symptoms of sinus infection are chronic and might lead to nasal obstruction and headache. Although pressure necrosis can occur as the mass impinges on surrounding structures, invasion is rare. The principal way in which this entity is distinguished from AFRS is by histologic examination, which shows dense accumulations of hyphae in concentric layers forming a fungus ball.[69] Eosinophilic mucin is not present. Surgical removal is indicated.

Invasive fungal sinusitis typically presents as an aggressive, fulminant, disseminated disease that is usually observed in immunocompromised patients, diabetics, those with leukemia or solid malignancies who are febrile and neutropenic (most of whom will have received broad-spectrum antimicrobial therapy), patients receiving high-dose oral steroid therapy (eg, patients with connective tissue disease or transplant recipients), and patients with severe impairment of cell-mediated immunity (transplant recipients or persons with congenital or acquired T-cell immunodeficiencies). Common clinical signs include fever, headache,

epistaxis, and mental status changes. The patient might have insensate nasal ulcers. This symptom complex was formerly called *mucormycosis*, although aspergillus is often implicated.[68] Aggressive debridement and systemic antifungal therapy is warranted.[70,71] Depending on the particular fungus involved and the site of infection, this may be a life-threatening event.

## Clinical diagnosis

### *History*

The diagnosis of rhinosinusitis is based on a combination of clinical history, physical examination, imaging studies, and/or laboratory tests. Symptoms of rhinosinusitis are presented in Table 1. ABRS is suspected in patients whose URI has persisted beyond 7 to 10 days or is worsening after initial improvement.[72] Symptoms lasting 5 to 10 days are the most difficult to assess because they may reflect an ongoing viral URTI or the beginning of a bacterial infection. Prominent symptoms in adults include nasal congestion, obstruction, anterior and/or posterior purulent rhinorrhea, and facial pain or pressure.[2–6] Although all these symptoms are nonspecific,[73–75] a history of persistent purulent rhinorrhea and facial pain appear to have some correlation with increased likelihood of bacterial disease.[73] Symptoms of ABRS are similar in children but often also include increased irritability, even more prolonged cough, and vomiting that occurs in association with gagging on mucus.[45]

The symptoms of CRS can be similar to those of ABRS or be more subtle.[7,76,77] The patient might sense only a mild increase in a subset of symptoms (eg, congestion or fatigue). Rather than expressing concern about a new problem, such a patient might simply complain that the usual medications for rhinitis are not effective. It is possible that headache attributed to CRS could be a migraine equivalent or atypical facial pain.[77–79]

In contrast to ABRS, CRS cannot be diagnosed by symptoms alone. The differential diagnosis for CRS is presented in Table 2. The 5 expert panels cited previously outline diagnostic parameters for CRS that combine symptoms assessments with objective findings of some type such as from CT or endoscopy.[80] CRS can be subdivided into CRSsNP and CRSwNP. Patients with CRSsNP generally present with periodic exacerbations associated with increased facial pain or pressure and increased drainage anteriorly and/or posteriorly. Fever is absent or low grade and fatigue is a common complaint. Some will have superimposed episodes of ABRS symptoms that respond to antibiotics but they often have persistence of some ongoing sinonasal symptoms between episodes. This ongoing symptom complex distinguishes CRS from RARS, in which the patient is asymptomatic between ABRS episodes. Patients with CRSwNP complain of marked nasal congestion, vague facial or sinus fullness, postnasal drainage, and anosmia or hyposmia.[17] An accurate history has implications for appropriate initial therapy and long-term management.

**Table 3**
Imaging techniques to evaluate sinuses

| Modality | Indications |
|---|---|
| CT without contrast | evaluate extent of CRS and complications of rhinosinusitis |
| | evaluate sinus anatomy, including anatomy of outflow tracts, nasal turbinate anatomy, and nasal septal deviation or spur |
| | evaluate sinus variants (eg, infraorbital ethmoid [Haller] cells, frontal bulla and cells, agger nasi cells, sphenoethmoidal [Onodi] cells. |
| | evaluate for a mucocele |
| | evaluate recurrent acute rhinosinusitis |
| | for operative stereotactic navigational image guidance during FESS (performed with an image guided protocol) |
| | evaluate persistent nasal congestion or obstruction |
| | immunocompromised patient with fever and sinonasal complaints |
| | evaluation of fungal rhinosinusitis |
| CT with contrast | limited role; can be useful for complications of rhinosinusitis |
| MRI with contrast | evaluate for the complications of rhinosinusitis, such as orbital and intracranial extension |
| | evaluate for presence, location, and extent of a sinus tumor and for extra-sinus involvement, such as orbital and intracranial extension |
| | differentiate a mucocele from a tumor |
| | rule out a structural, neoplastic, or inflammatory process originating outside paranasal sinuses |
| | evaluate AFRS |

Abbreviations: AFRS, allergic fungal rhinosinusitis; CRS, chronic rhinosinusitis; CT, computed tomography; FESS, functional endoscopic sinus surgery; MRI, magnetic resonance imaging.

### *Physical examination*

#### *Acute bacterial rhinosinusitis*

When the clinical history suggests rhinosinusitis, a directed physical examination may help differentiate ABRS from AR or an uncomplicated viral URI.[73–75] The examination begins with careful inspection of the face. ABRS can be associated with edema and tenderness overlying an affected area. Diplopia and proptosis are ominous signs that may be observed if ABRS involves the orbits.

In contrast, allergic facies show dark infraorbital swollen semicircles. Allergic children frequently exhibit a transverse nasal crease (caused by constant nose itching) or Morgan-Dennie lines (accentuated horizontal skin folds on the lower eyelid running parallel to the lower lid margin).

The nasal mucosa and quality of secretions should be assessed. Red, swollen nasal tissue is seen in infectious rhinitis and rhinosinusitis; pale boggy turbinates suggest AR. Secretions are clear and watery at the onset of URTIs but become thicker, colored (yellow-green), and opaque after a few days. Usually, the discharge will remain purulent for several days and then become clearer shortly before resolution. Typical “colds” last 5 to 7 days and rarely last as long as 10 days. Persistence of purulent secretions beyond 10 days in the middle meatus area is characteristic of ABRS, and secretions can be yellow-green, green, or gray.[73] However, the absence of purulent discharge has not been proved to be a highly reliable indicator for the absence of ABRS. Allergic nasal secretions are generally clear and watery; with extreme inflammation, a pale yellow color might be observed. Purulent exudates in the middle meatus are believed to be highly predictive of ABRS[73] but might be difficult to visualize unless the nasal mucosa is decongested with a topical vasoconstrictor. Endonasal examination can be performed with a headlight and speculum or the otic speculum, but diagnostic nasal endoscopy is the most effective means of visualizing the middle meatus. Conversely, the absence of purulent secretions does not exclude the possibility of active sinus infection.

The oropharynx should be examined for signs of posterior pharyngeal mucopurulent secretions. On occasion, ABRS might present with upper dental pain secondary to overlapping neural innervations with the maxillary sinus and the upper molar teeth. In addition, some cases of maxillary rhinosinusitis are odontogenic in origin. Odontogenic rhinosinusitis is usually associated with some evidence of a periapical collection and is typically unilateral. However, it may spread to all the sinuses on 1 side, and the site of origin may be missed without a careful evaluation of the CT scan. Examination of the ears might show otitis media, particularly in children with rhinosinusitis; in fact, unresolved persistent ABRS might lead to recurrent otitis media if inflammatory changes involve the eustachian tubes.[45,81] Auscultation of the chest for wheezing might disclose an asthmatic component to a patient’s cough. The absence of audible wheezing does not exclude the possibility of asthma; subtle abnormalities might only be apparent at spirometry (see “Laboratory tests” section).

**Table 4**
Factors associated with rhinosinusitis[a]

| |
|---|
| Infectious rhinitis: viral upper respiratory tract infections |
| Rhinitis or congestion secondary to: granulomatosis with polyangiitis (aka Wegener granulomatosis), midline granuloma, periapical abscess, eosinophilic granulomatosis with polyangiitis (Churg-Strauss syndrome), sarcoidosis |
| Immunodeficiency: common variable immune deficiency, specific antibody deficiency, IgA deficiency, acquired immunodeficiency syndrome |
| Genetic abnormalities: cystic fibrosis, primary ciliary dyskinesia, Kartagener syndrome, Young syndrome |
| Gastroesophageal reflux disease (LPR) (debatable) |
| Sleep apnea |

[a]Adapted from Hamilos[105] and Kaliner.[106]

Transillumination of the maxillary sinuses might be reported as opaque (no transmission), dull (decreased transmission), or normal, but the sensitivity and specificity of this technique alone are poor.[82] Unless the clinician has additional knowledge of a patient's sinus anatomy (eg, from a CT scan), it is impossible to differentiate active disease from a congenitally small sinus or bilateral mild involvement of larger sinuses from normal-size sinuses.[83,84] In 1 prospective study, however, abnormal transillumination combined with purulent nasal secretions and a history of maxillary pain, poor response to decongestants, and colored rhinorrhea was the best predictor of ABRS.[83]

*Recurrent acute rhinosinusitis*

In assessing patients with RARS, the physical examination should be modified to evaluate for signs of immunodeficiency (associated recurrent otitis media, poor growth in children, unexplained dermatitis, absence of lymphoid tissue, bronchiectasis, bronchitis, or pneumonia), complications of primary infections (eg, mastoiditis or orbital cellulitis), CF (suggested by poor growth, nasal polyps, barrel chest, digital clubbing, and diffuse chest abnormalities on auscultation), ciliary dysfunction (nasal polyps, digital clubbing, dextrocardia, and situs inversus), and anatomic abnormalities (eg, septal deviation, nasal polyps, foreign bodies, and tumors).

In selected patients with RARS, diagnostic nasal endoscopy should be considered. This can be performed with rigid and/or flexible (fiberoptic) telescopes. Rigid endoscopy provides greater image quality and allows the examiner to perform procedures, such as culture, biopsy, or injection. This modality provides the most optimal visualization of abnormalities of the septum, turbinates, superior, middle, and inferior meati, olfactory clefts, nasopharynx, adenoids, and eustachian tube orifices. The origin and extent of any nasal polyps can be identified, as can the presence of purulent and meatal secretions.[30,84] Flexible telescopes can visualize these nasal and nasopharyngeal regions, but they also can be used to examine additional structures of the upper aerodigestive tract, including the tonsils, tongue base, epiglottis, glottis, and vocal cords. Flexible endoscopy also tends to be more comfortable for the patient. It should be noted that endoscopic visualization of a sinus lumen is typically not possible unless the patient has had prior surgical sinusotomy or an accessory ostium is present.

*Chronic rhinosinusitis*

Physical examination and nasal endoscopy may help distinguish patients with CRSsNP from those with CRSwNP. The origin and extent of nasal polyps can be identified, as can the presence of purulent and meatal secretions. In children, the presence of polyps should raise concerns about CF. Severe persistent asthma and nonsteroidal anti-inflammatory drug intolerance can be associated with CRSwNP.[76]

Because asthma is common in patients with CRS,[85] these patients should be evaluated with a directed history and physical examination focusing on the lower respiratory tract. Sometimes cough may be the only symptom of asthma. The absence of audible wheezing does not exclude the possibility of asthma; subtle abnormalities might only be apparent on spirometry (see "Laboratory tests" section).

Similarly to RARS, the physical examination in patients with CRS should evaluate for physical findings associated with comorbid conditions, such as immunodeficiencies, CF, or ciliary dysfunction, complications related to sinus infections such as mastoiditis or orbital cellulitis, and anatomic abnormalities (eg, septal deviation, nasal polyps, foreign bodies, or tumors). A tumor should be ruled out in a patient with unilateral CRS.[86]

## Imaging studies

Summary Statement 4: Perform a CT scan when imaging of the sinuses is indicated. It is required before surgical intervention or when complications of rhinosinusitis are suspected. (StrRec, A)

Summary Statement 5: Radiographic imaging is recommended in a patient with unilateral CRS to exclude a tumor or anatomic defect or foreign body. (Rec, C)

Summary Statement 6: Perform MRI if soft tissue resolution is required, such as with a suspected tumor or in patients with complications. If a CT scan depicts a soft tissue mass, the patient should then be referred to an ear, nose, and throat physician. (Rec, B)

The diagnosis of ABRS is generally made based on history and physical examination.[73,80] Imaging is useful when acute complications are suspected, the response to initial management is poor, or when the diagnosis is in question.

*Standard radiography*

Standard radiography has a limited role since the widespread use of CT for imaging of the paranasal sinuses. There are 4 standard radiographic views of the paranasal sinuses; these include 2 anterior-posterior (A-P) views (Caldwell, Waters), a lateral view, and a submentovertex view.[87] The Caldwell view is a direct A-P view and shows the frontal sinuses, maxillary sinuses, and to some degree the ethmoid air cells, although superimposition of the ethmoid air cells on these A-P views limit their evaluation. The Waters view, also known as the *occipitomental view*, is likely the best view to evaluate the maxillary sinuses, particularly to evaluate for the presence of a maxillary sinus air-fluid level. The lateral and submentovertex views are a useful adjunct to evaluate the frontal and maxillary sinuses and assess adenoid size in children.[87] Although some information of the sphenoid sinus may be gained by the lateral and submentovertex views, the sphenoid sinus is probably the most difficult sinus to image with standard radiography.[87] Compared with CT, none of the standard radiographic views reliably image the severity or location of sinus disease,[88] or for that matter, the presence of a subtle air-fluid level. A nasal mass may or may not be visualized with standard radiography. Moreover, standard radiography does not provide reliable information regarding the sinus outflow tracts; evaluating the sinus outflow tracts provides vital information to evaluate for a possible anatomic outflow obstruction and to help determine the need for surgery.

*Computed tomography*

Computed tomography of the sinuses can provide confirmatory evidence for rhinosinusitis when the symptoms are vague, the physical findings are equivocal, or the clinical disease persists despite optimal medical therapy. The value of CT has been described in prior studies, which have shown that up to half of patients with CRS symptoms had negative scans for CRS.[89–91]

High-resolution CT is the imaging gold standard to evaluate for uncomplicated acute or chronic sinus disease.[92] CT imaging exquisitely visualizes the severity and location of the sinus disease, the presence of a subtle air-fluid level or aerated secretions, the anatomy of outflow tracts, the presence of an obstructed outflow tract, and the size of adenoids in children. CT imaging also provides valuable information about the integrity of the osseous sinus walls.[92] A thinned or remodeled osseous sinus wall can be caused by an ABRS or AFRS, or with certain tumors. Sclerosis of the sinus walls is a typical finding of CRS.[92]

Most direct CT examinations are obtained with 3-mm coronal slices. Modern scanners typically obtain thin (<1 mm) axial slices that are reformatted in the coronal plane and, at some institutions, in the sagittal plane. The coronal plane optimally images the ostiomeatal complex, a vital outflow tract for the maxillary sinus, anterior ethmoids, and ultimately the frontal sinuses. Sagittal reformatted images provide valuable information of the frontal recesses. A preoperative sinus CT can be immensely useful for computer-assisted stereotactic image-guided surgical navigation during functional endoscopic sinus surgery (FESS). For this technique, thin-section (ie, 1 mm) axial CT images are obtained with scanning parameters specific for the computer application used. Unless a complication is suspected, it is preferable to perform the CT scan after maximal medical therapy. Sinus CT imaging is particularly helpful in the diagnosis of fungal rhinosinusitis.[93] The hallmark of all fungal sinus disease is the presence of increased attenuation within the sinus opacification; however, the presence of increased attenuation as an isolated finding is a nonspecific one and can be present with inspissated secretions and hemorrhage.[88] In the case of AFRS, the classic findings include multiple sinus opacifications with increased attenuation, expanded sinuses, and osseous wall remodeling.[94] The typical findings of a sinus fungus ball, although often nonspecific, include isolated high-density sinus opacification and a centralized focus of calcification.[95] CT findings of invasive fungal rhinosinusitis include high-density sinus disease with extension into the adjacent soft tissues, classically involving the premaxillary and retromaxillary fat if the maxillary sinus is involved.[96] This soft tissue invasion can be present with or without associated osseous destruction.[97] The lack of osseous destruction observed in some cases is explained by the proclivity of invasive fungal sinus disease to spread along vessels that traverse the sinus walls.[97] Indeed, in the immunocompromised patient, invasive fungal rhinosinusitis should be suspected in any opacified sinus that is associated with peri-sinus soft tissue infiltration, with or without osseous destruction. In addition, unilateral severe nasal cavity mucosal thickening has been described as an early manifestation of invasive fungal rhinosinusitis in the immunocompromised patient.[97]

Computed tomography also is useful to evaluate for the presence of nasal cavity lesions such as inflammatory polyps or polypoid tumors. Nasal septal deviation, spurs, and the turbinate morphology are best displayed by CT imaging.[94]

A CT scan also may show a mucocele, which is an expansile cyst that causes complete sinus opacification and expansion beyond its normal confines.[98] Although a mucocele can be suspected on a CT scan, an opacified and expanded sinus also can be observed with solid tumors. Therefore, it may be difficult to differentiate a neoplastic soft tissue lesion from a mucocele on a standard CT scan. An MRI can easily differentiate between a mucocele and a tumor.[94] Although a mucocele may enhance along its periphery at MRI, it does not enhance within its center, as opposed to a solid tumor, which usually will contain some degree of enhancement within its substance. Contrast-enhanced CT also may be useful for this purpose, although MRI is preferred.

Sinus anatomic variants, such as Haller cells, frontal bulla and cells, agger nasi cells, and Onodi cells, are best imaged with CT imaging.[94] Most of these variant air cells are often incidental findings; however, these air cells can be significant and can cause an outflow obstruction if they are large enough or if they are strategically located at (or within) the entrance site of an outflow tract. An Onodi cell is a sinus variant that can be a surgical pitfall. An Onodi cell is defined as a posterior ethmoid air cell that shares a common wall with the optic canal and that typically resides above the sphenoid sinus. If the surgeon is unaware of an Onodi cell variant, the surgeon may inadvertently injure the optic canal and nerve.[94]

The integrity of the anterior skull base also is best visualized with CT imaging. CT is quite useful to localize an anterior skull base cerebrospinal fluid leak. CT scanning performed for this indication can be performed without or, if needed, with intrathecal iodinated contrast material.[99]

Technical advances since the last published parameters have lowered the dosage of radiation associated with a sinus CT scan. Radiation doses of 0.13 mSv have been reported from screening sinus CT scans. This is significantly lower than the dose from a conventional head CT (2 mSv).[100,101]

There is a limited role for contrast-enhanced sinus CT imaging. The vast majority of cases of inflammatory sinus disease should be imaged without intravenous contrast. Most complications related to sinus disease can be observed with unenhanced CT imaging. However, MRI with contrast is preferred over contrast-enhanced sinus CT to evaluate for inflammatory sinus disease complications, particularly if intracranial spread of infection is suspected.[88] Similarly, most sinus tumors are not well delineated with a CT scan, with or without contrast, and ultimately should be evaluated with contrast-enhanced MRI. However, if the patient cannot obtain an MRI, then pre- and postcontrast sinus CT studies could be considered.

*Magnetic resonance imaging*

The major indication of sinus MRI is to evaluate the complications related to sinus disease or to determine the presence and map the location of a sinus tumor.[88,92] MRI provides superior imaging of the adjacent soft tissues compared with CT owing to its improved soft tissue resolution.[88]

Magnetic resonance imaging should not be performed to evaluate for uncomplicated sinus inflammatory disease; this role is reserved for CT. Although MRI may display even the most subtle sinus mucosal thickening, the trace sinus mucosal thickening that can be observed with MRI is often not clinically relevant.[102] Moreover, more serious rhinosinusitis, including excessively inspissated sinus disease (which is devoid of water molecules required to generate an MRI signal) and even extensive fungal disease, may not be seen at MRI.[103]

As discussed earlier, a sinus tumor can be occult at CT, particularly if the affected sinus is completely opacified and there is no

**Table 5**
Criteria for diagnosis of allergic fungal rhinosinusitis[180]

| | |
|---|---|
| Type I hypersensitivity to fungi by skin test or serum specific IgE | nasal polyps |
| Characteristic findings at sinus CT or MRI | eosinophilic mucin |
| Positive fungal stain | |

Abbreviations: CT, computed tomography; MRI, magnetic resonance imaging.

evidence of an associated osseous abnormality or extra-sinus extension. However, MRI can differentiate a soft tissue tumor from inflammatory sinus disease or fluid that completely opacifies a sinus. A sinus tumor at MRI is most often T2 hypointense and enhances centrally, whereas sinus opacification from inflammatory sinus disease is most often T2 hyperintense and does not enhance centrally.[94] In addition, MRI can determine the location of a tumor relative to any postobstructive sinus disease that may have been caused by the tumor.[104] As with complications of inflammatory sinus disease, MRI can determine whether a mass has invaded the brain or orbits, which are critical findings to be aware of before undergoing any tumor removal in this area.[104] MRI also can delineate whether an apparent primary sinonasal process arises from the brain or orbit. A significant example of this entity is a meningoencephalocele. Table 3 lists the indications for CT and MRI.

## Predisposing factors

### *Viral infections*

Viral URIs are common occurrences (Table 4).[105,106] In the United States, adults have an average of 2 to 3 viral URIs annually, whereas children have 3 to 8. If CT scanning of the sinuses is performed during viral URIs, 39% to 90% show sinus mucosal thickening, consistent with viral ARS.[44,107,108] The symptoms of patients with a viral URI are not different in those with normal CT scans compared with those with sinus mucosal involvement. In the overwhelming majority of cases, irrespective of what the CT scan shows, the URI resolves within 3 weeks without any need for antibiotics.[108,109] ABRS is reported to occur subsequently in 0.5% to 13% of patients with URIs.[44,76,110,111]

Identification of viruses by molecular methods such as polymerase chain reaction has improved the ability to detect viruses in tissues such as nasal mucosa. In a polymerase chain reaction study of sinus mucosal surgical specimens from 20 patients with CRS, respiratory syncytial virus was detected in 4 (20%), whereas adenovirus was not detected in any.[112] In a study of turbinate epithelial cells, rhinovirus was not detected by polymerase chain reaction in any of 27 normal controls but was found in 8 of 39 patients with CRS (21%).[113] In contrast, biopsy examination of the maxillary sinus mucosa in patients with symptoms of ARS showed that 50% had RNA evidence of rhinovirus.[114] Evidence thus supports the clinical observation that a significant number of ABRS infections is caused by viruses, but that viruses are less likely to play an important role in CRS compared with ABRS.[3,16,80]

### *Allergic rhinitis*

Summary Statement 7: Perform an evaluation for specific IgE antibodies to airborne allergens in patients with RARS or CRS. (Rec, B)

Allergic rhinitis is a very common chronic disease. The prevalence of the disease is estimated at 10% to 15% of the population at any given time. Usually AR develops during childhood, although a significant proportion of patients (30%) develop AR after the third decade of life.[115] Allergic inflammation of nasal tissue causes swelling and congestion of the mucous membranes, which may interfere with normal sinus drainage. In addition, there can be increased mucus production of a quality that interferes with normal ciliary function. Obstructed sinuses can fill with secretions and become hypoxic and acidotic, leading to further mucociliary dysfunction. Then, bacteria can multiply and infect the mucosa, resulting in an influx of neutrophils and additional inflammation.

Multiple studies in adults and children support the association of AR and rhinosinusitis in the acute and chronic forms. A recent retrospective longitudinal cohort study of CRS determined premorbid factors in newly diagnosed CRS cases compared with controls. The study found that patients with CRS had a higher prevalence of AR before the diagnosis of CRS was made, suggesting at least an association between the 2 conditions.[77] In children, AR has been reported to be present in 36% to 60% of those with CRS.[116] In young adults with ARS, there is a reported incidence of AR ranging from 25% to 31%.[9,10] CRS in adults is associated with AR in 40% to 84% of patients.[12,117–119] One study reported an association between extensive sinus disease quantified by CT and AR in 78% of patients.[120] Another study reported that rhinosinusitis in patients with AR is associated with more extensive abnormalities on sinus CT images.[121] However, other studies have failed to confirm significant CT differences between allergic and nonallergic subjects with CRS.[11,122] A study of pediatric patients undergoing FESS suggested that those with allergies may have persistent disease despite surgery compared with those without allergies.[123] A recent study showed that patients with CRS and AR are more likely to have had previous sinus surgery compared with CRS without AR.[124] In surgical outcomes for CRSwNP, AR does not seem to modify outcomes of FESS in symptoms or steroid requirements.[125] There are 2 studies of anti-IgE therapy (omalizumab) for CRSwNP that reported success and another that found no efficacy.[126–128] One distinct form of CRS, AFRS, is clearly related to allergic sensitization.[129] There are observational studies of allergen immunotherapy that have reported safety[130,131] and clinical improvement in AFRS when performed in conjunction with appropriate surgery and corticosteroids.[132–135] One retrospective questionnaire study reported the effectiveness of subcutaneous allergen immunotherapy in the treatment of recurrent rhinosinusitis associated with AR.[136]

In numerous studies of nasal lavage fluids from patients with CRS, the presence of different molecules was associated with allergic inflammation, including histamine, leukotrienes, and T-helper cell type 2 cytokines.[20,61,137] These data are further evidence that allergic responses contribute to CRS.

### *Nonallergic rhinitis*

Summary Statement 8: Physicians should recognize that NAR can accompany and is in the differential of CRS. (Rec, C)

Nonallergic rhinitis can occur alone or in combination with AR, in which case the diagnosis is mixed rhinitis. Studies have reported that approximately 40 million Americans have mixed rhinitis or NAR alone.[138] In rhinitis studies, the prevalence of NAR varies from 17% to 52%.[139,140] There appears to be a slight female predominance.[141] It also has been reported to be more common in those older than 50 years.[142] However, in some reported cohorts of children with rhinitis, it has been observed that many with nasal symptoms are not allergic.[143,144] The diagnosis of NAR requires a careful history and skin test reactions that are negative or irrelevant.[145] Depending on the subtype of NAR, the nasal examination may be completely normal or may have some evidence of edema and secretions.

Classically, patients with NAR present with symptoms of rhinorrhea and congestion that are triggered by exposure to strong odors (eg, cleaning solutions, perfumes) or changes in temperature, barometric pressure, or humidity.[145] One form of NAR is NAR with nasal eosinophilia syndrome; in 1 study, NAR with nasal eosinophilia syndrome was estimated to account for 15% to 20% of NAR cases.[146] Other causes of NAR include atrophic rhinitis, hormonally induced rhinitis, and drug-induced rhinitis.

In some studies of CRS in which the diagnosis is based on symptomatology, it is interesting to note that many subjects do not have objective findings on endoscopy or CT scans.[19,147] In 1 study of 768 adults (204 allergic and 564 nonallergic), 73% of nonallergic patients and 65% of allergic patients with symptom-based CRS had normal CT and nasal endoscopy findings.[147] It is likely that some of these patients had NAR.

*Immunodeficiency*

Summary Statement 9: Evaluate patients for an immune deficiency if CRS is resistant to usual medical and/or surgical therapy. (Rec, B)

Summary Statement 10: As part of an immunodeficiency evaluation, check quantitative immunoglobulins (IgG, IgA and IgM), specific antibody responses (eg, after tetanus toxoid and pneumococcal vaccine), and, if necessary, T-cell numbers (enumeration of T-cell number by flow cytometry) and function. (Rec, B)

Immunodeficiency should be considered in the evaluation of patients with RARS or CRS. It is especially important to evaluate patients whose aggressive medical and surgical therapy has failed.[3,148–150] There are 2 studies that found immunodeficiency in only 0% to 3% of such patients.[151,152] However, there are 5 studies that found the prevalence of immunodeficiency to be much higher, ranging from 11% to 19%.[149,153–156] At least 2 serious sinus infections are considered 1 of the 10 warning signs of primary immunodeficiency (PID) proposed by the Jeffrey Modell Foundation and the American Red Cross.[157] When the patient also has a history of recurrent otitis media, recurrent lower respiratory tract infections, or bronchiectasis, the suspicion for immunodeficiency is increased; a history of life-threatening infections or infections with opportunistic organisms are other indications for pursuing an immunodeficiency evaluation.[158] Depending on the age of the patient, the physical examination may include findings known to be associated with specific immunodeficiency syndromes: abnormal lung sounds, ocular telangiectasia, absence of tonsils, clubbing, and petechiae.[158] Although humoral deficiency is the most likely culprit, other immune defects might present with RARS; an example would be acquired immunodeficiency syndrome, in which there are cellular and humoral impairments.[159,160]

Appropriate laboratory studies in patients with RARS or CRS includes quantitative immunoglobulin measurements (IgG, IgA, and IgM), specific antibody responses to tetanus toxoid and pneumococcal vaccines, and measurement of T-cell number (enumeration of T-cell number by flow cytometry) and function. It should be noted that evaluation of tetanus antibodies is especially useful because most patients have been immunized, and 90% to 100% of children who have completed primary immunization should have protective titers.[161] Immune responses to polysaccharide antigens are unreliable at younger than 2 years. In patients older than 2 years, the polysaccharide antigen response can be determined by measuring specific antibody levels before and 4 to 8 weeks after immunization with unconjugated pneumococcal vaccine. According to the working group of the Basic and Clinical Immunology Interest Section of the American Academy of Allergy, Asthma and Immunology, children 2 and 5 years old should respond to approximately half the serotypes tested, and patients older than 5 years should respond to at least approximately 70% of the serotypes.[162]

In patients with refractory CRS or RARS, the most common PIDs are humoral, with specific antibody deficiency, IgA deficiency, and common variable immunodeficiency being examples.[153,160] In 1 study of 842 children with a PID, more than half the 425 participants with humoral defects had recalcitrant rhinosinusitis.[148] Other PIDs that could present with recurrent or refractory rhinosinusitis include ataxia telangiectasia,[163] Wiskott-Aldrich syndrome,[164] and deficiency of complement protein such as C3 deficiency.[165] When these syndromes are suspected clinically, referral to a board-certified allergist-immunologist for evaluation and treatment is indicated. RARS or CRS may occur in patients infected with human immunodeficiency virus. In studies before the existence of retroviral therapy, prevalence estimates of CRS occurring in these patients were 30% to 68%.[166] With early diagnosis and antiretroviral therapy, the prevalence is decreasing. In a study of 470 adults receiving antiretroviral therapy followed to 80 months, the prevalence of CRS ranged from 3% to 6%.[167]

*Immunoglobulin replacement*

Immunodeficiency has been reported to be an underlying risk factor for the development of refractory, recurrent acute, or recalcitrant CRS.[149,153–156] Immunoglobulin replacement is approved as a replacement therapy for antibody deficiency disorders, including common variable immunodeficiency, X-linked agammaglobulinemia, Wiskott-Aldrich syndrome, and hyper-IgM syndrome.[158,168,169] The use of immunoglobulin in other immune disorders (eg, specific antibody deficiency or IgG subclass deficiencies) remains controversial.[158]

The appropriate use of immunoglobulin in patients with humoral immunodeficiency can prevent complications from CRS, including subperiosteal abscess, intracranial abscess, meningitis, sepsis, or even death.[170]

Considerable controversy exists regarding prescribing immunoglobulin for therapy of patients with specific antibody deficiency and normal immunoglobulin levels (see "Practice Parameters for the Diagnosis and Management of Primary Immunodeficiency"[171]). Most experts in this area consider demonstration of impaired antibody production essential. It must be shown that (1) the patient has significant and clearly documented infectious morbidity (eg, recurrent pneumonias and frequent episodes of documented ABRS and not just isolated CRS), (2) other disorders (eg, allergy or anatomic defects) have been sought and treated aggressively if present, and (3) other modes of therapy (antimicrobial, anti-inflammatory, and surgical) are inadequate or poorly tolerated. Many clinicians who care for these patients will perform a clinical trial of IgG replacement (400 mg/kg per month) for up to 6 months. If administered to children with milder antibody deficiencies, immunoglobulin therapy should be discontinued if there has been an extended period of significant improvement because the susceptibility to infection might decrease over time.[172] Humoral immune function should be reassessed but no sooner than 3 months (preferably 4–6 months) after the last infusion. Patients must be followed closely, and therapy should be discontinued, generally after no more than 3 to 6 months, if there is lack of clinical efficacy.

*Gastroesophageal reflux disease*

Summary Statement 11: Evaluate patients for GERD if they have appropriate symptoms, realizing that it probably coexists rather than explains the etiology of rhinosinusitis. (Opt, C)

Gastroesophageal reflux disease has been suggested as a cause of rhinosinusitis. The mechanism is thought to be direct reflux of gastric acid into the pharynx and subsequently to the nasopharynx, causing inflammation of the sinus ostium and leading to rhinosinusitis.[173] Recently, a meta-analysis performed by Flook and Kumar[174] concluded that the evidence of a link between CRS and GERD is poor, with no good randomized controlled trials (RCTs) available. A study of 30 children with CRS was performed using 24-hour monitoring with dual-pH probes, 1 in the nasopharynx and 1 in the distal esophagus. Nineteen (63%) showed gastroesophageal reflux, well above the expected prevalence of 5% in the healthy general population. Of these 19, 6 (32%) exhibited nasopharyngeal reflux. Sinonasal symptoms improved in 79% after treatment of GERD. The recommendation of the investigators was that children with CRS refractory to medical therapy be evaluated for GERD and treated before sinus surgery is considered.[175]

A study in adults evaluated the prevalence of GERD in 11 patients with CRS (confirmed by CT) who had not responded to conventional therapy and 11 healthy control subjects. A 3-site ambulatory esophagopharyngeal pH monitoring technique was used. Ambulatory pH monitoring documented GERD in 7 of 11 patients and 2 of 11 healthy volunteers.[176]

A more recent study has shown a higher prevalence of nasopharyngeal reflux in patients with refractory symptoms despite FESS compared with those without sinus disease and those with successful sinus surgery.[177]

An uncontrolled study involved 19 adult patients with CRS, 18 of whom had undergone sinus surgery.[178] Sixty-eight percent had classic GERD symptoms, and 78% had abnormal results at an esophageal pH probe. Twelve were treated with proton pump inhibitors, 4 were treated with proton pump inhibitors and prokinetics, and 2 had repeat surgery. Six months later, 12 (67%) had improvement in sinus symptoms, with 4 having dramatic improvement. The investigators suggested that medical therapy as a treatment for adults with CRS be confined to patients with abnormal pH results.[178] The few adult studies that showed a link between GERD and nasal symptoms were small case–control studies with moderate levels of potential bias. There is not enough evidence to consider antireflux therapy for refractory CRS in adults, and there is no evidence that GERD is a significant causal factor in CRS.

To determine whether a neural arc exists between GERD and nasal symptoms, Wong et al[179] infused normal saline and hydrochloric acid into the lower esophagus through an esophageal manometry catheter and concomitantly analyzed nasal symptom scores, nasal inspiratory peak flow, and mucus production. Their study showed a trend in mucus production after saline and hyperchloric infusion with return to baseline within 45 minutes, supporting the possibility of a neural reflex between the esophagus and the nasal mucosa.[179]

## Allergic fungal rhinosinusitis

Summary Statement 12: Be aware that a subgroup of patients with CRSwNP has AFRS, which is a distinct entity associated with eosinophilic mucin and type I hypersensitivity to fungi. (Rec, B)

Summary Statement 13: Treat AFRS with a combination of surgery and systemic and/or topical corticosteroids for optimal disease control. (Rec, B)

Summary Statement 14: Consider systemic or topical antifungals as useful adjunctive treatment for AFRS. (Rec, C)

A subgroup of patients with CRSwNP with characteristic eosinophilic mucin is categorized as having AFRS. The original criteria for diagnosis of AFRS as proposed by Bent and Kuhn[180] are listed in Table 5. Over time there has been significant controversy in the diagnosis of AFRS but the characteristic findings that are most often associated with AFRS are type I hypersensitivity, fungal elements on pathology, characteristic CT findings, and eosinophilic mucin. Approximately 5% to 10% of patients undergoing sinus surgery are estimated to have AFRS. There appears to be a difference in the incidence of AFRS relative to geography, with the highest incidence diagnosed in the southern United States and along the Mississippi River Basin.[181] The most common fungi to cause this clinical syndrome are *Bipolaris*, *Curvularia*, *Aspergillus*, and *Drechslera* species, although a wide variety of other fungi has been observed in a myriad of case reports.[182–185] The pathogenesis of AFRS is believed to be similar to allergic bronchopulmonary aspergillosis resulting from an allergic response in a predisposed individual to inhaled fungi.[186] Patients with AFRS often have asthma and AR.[187] AFRS is distinct from invasive fungal disease (often seen in immunocompromised patients or diabetic patients) and distinct from fungus ball. Patients with AFRS typically develop nasal congestion and have thick "peanut buttery discharge." Classic findings on sinus CT scan include high attenuation areas and occasionally bony erosion.[188] MRI findings characteristic of AFRS include a central low signal on T1- and T2-weighted images corresponding to areas of eosinophilic mucin with peripheral high-signal intensity corresponding to areas of inflammation.[189]

Treatment of AFRS includes surgical therapy in combination with systemic and/or topical corticosteroids. Surgery for this disease process seeks to address the following objectives: (1) removal of polyps, (2) removal of fungal debris, (3) removal of eosinophilic mucin, (4) enlarging the natural sinus ostia, and (5) preservation of the mucous membranes of the newly marsupialized sinus cavities. The ideal goal is restoration of normal mucociliary clearance. With the understanding that this is often impossible, a more practical goal is to create patent, mucosalized sinus cavities that are amenable to cleaning by patient self-irrigation and office procedures for debridement or irrigation. Surgery also allows for better delivery of topical steroids to the sinuses.[190]

Oral steroids have been shown to cause regression of sinus mucosal thickening in patients with AFRS before undergoing sinus surgery.[191] Treatment with a short course of oral steroids may be useful to decrease bleeding and edema, thus improving surgical landmarks, but insufficient evidence exists to advocate longer courses of systemic steroids preoperatively. Systemic steroids are commonly used in the postoperative management of AFRS. Initial reports of their use came from retrospective case series in adults[192–195] and children.[196,197] Rupa et al[198] conducted an RCT of the use of prednisone 50 mg/d for 6 weeks, followed by 6 additional weeks of tapering vs no treatment with systemic steroids (placebo).[198] In this study, all patients also received systemic itraconazole 200 mg/d for 12 weeks and steroid nasal spray in the postoperative period.[198] At 6 weeks, prednisone treatment was associated with complete relief of preoperative symptoms in 8 patients and none of the patients who received placebo.[198] Nasal endoscopy showed that 8 of 12 patients who had received oral steroids and 1 patient who had received placebo were free of disease.[198] At 12 weeks, symptom relief was complete in all patients who received prednisone but in only 1 patient who received placebo.[198] Significant steroid-induced side effects were noted in the steroid-treated patients, including weight gain, cushingoid features, acne, and steroid-induced diabetes.[198] Although this is the only RCT of systemic steroids for AFRS, most expert opinion reports advocate using lower doses and shorter durations of systemic steroids in the postoperative management of AFRS.[192–197]

Systemic or topical antifungal treatments for AFRS have been used, with mixed results. The only reports of the use of antifungal treatment for AFRS involve open treatment trials[199,200] or retrospective case series in adults[191–195] and children.[196,197] In an open treatment study, Khalil et al[199] compared oral itraconazole (100 mg/d), topical fluconazole nasal spray, topical fluconazole irrigation, and the combination of itraconazole plus fluconazole nasal spray with placebo as a treatment to prevent postoperative recurrence of AFRS in 50 patients after surgery. After 3 months of treatment, the rates of AFRS relapse were 66.7% with itraconazole, 10% with topical fluconazole nasal spray, 28.6% with topical fluconazole irrigation, and 75% with placebo 75%.[199] It was concluded that topical fluconazole was an effective treatment.[199] The dose of itraconazole in this study was lower than that used in other studies and may have been subtherapeutic. In another open treatment study, Chan et al[200] treated patients with AFRS who were refractory to prednisone, INS, and amphotericin B nasal sprays with 100 mg of itraconazole 3 times a day for 1 month, which was decreased to 200 mg/d for at least 2 more months. By endoscopic examination, 12 cases had improvement, 15 had no difference, and 5 had worse stage after 3 months.[200]

Other studies have incorporated itraconazole in the postsurgical management of AFRS in conjunction with systemic steroid treatment.[193,198,201] In the largest case series, Rains and Mineck[201] treated 139 patients (average dose 276 mg/d; average duration of therapy 4.3 months). Treatment with itraconazole was generally safe, and only 6 patients (4.3%) had significant liver enzyme elevation (>2 times the upper limit of normal).[201] Unfortunately, the data presented in this study do not allow for an assessment of whether itraconazole provided a clinical benefit.[201] Although there may be a subset of patients who respond dramatically to itraconazole, it is unclear how to identify those patients.

Because the pathogenesis of AFRS is believed to be an immediate hypersensitivity to fungal antigens, immunotherapy with relevant fungal antigens has been considered for treatment of AFRS. Early reports indicated that immunotherapy was beneficial in patients with AFRS by lowering reoperation rates and decreasing symptoms.[131,135] However, a follow-up study failed to show a benefit from immunotherapy in patients with AFRS.[202] RCTs of immunotherapy would be required to evaluate the utility of immunotherapy for AFRS.

## Cystic fibrosis

Summary Statement 15: Consider an evaluation for CF in any patient who developed CRS at a young age or in any child with nasal polyps, especially if *P aeruginosa* is cultured from the sinuses. (Rec, B)

Summary Statement 16: Consider adjunctive use of topical therapies, including dornase alfa and/or antibiotic solutions, in addition to endoscopic sinus surgery in patients with CF and CRS. (Rec, B)

Cystic fibrosis is a disorder caused by mutations in *CFTR* on the long arm of chromosome 7.[203] The heterozygous carrier rate for such mutations is approximately 3% to 4%, with clinical disease occurring in approximately 1 of 2,000.[204] The primary pathophysiology appears to involve decreased chloride ion secretion, thus impairing the associated transport of water. This results in increased viscosity of all exocrine secretions, particularly in the airway (nose, sinuses, and lungs) and gastrointestinal tract. In consequence, this promotes mucus stasis in the airways with bacterial infection. However, other specific hyper-inflammatory mechanisms also have been implicated. These include upregulation of cyclooxygenase enzymes and increased plasma cells, neutrophils, and mast cells compared with patients with CRS without CF and controls.[205,206] Patients with CF also exhibit dilation of glandular ducts, increased submucosal glands, and increases in surfactant gene expression.[207] Experiments also have shown heightened expression of endothelial L-selectin ligand, which modulates leukocyte recruitment into tissues.[208] Taken together, these observations underscore that CRS in patients with CF arises from multiple pathophysiologic processes and not just from secretion retention with bacterial overgrowth. Patients with CF also are known to exhibit underdevelopment of the paranasal sinus cavities, which can lead to smaller ostia and greater retention of secretions.[27]

The historical gold standard for diagnosis is the Gibson-Cooke sweat test or quantitative pilocarpine iontophoresis. Assuming that at least 75 mg of sweat is obtained, chloride levels higher than 60 mEq/L are considered diagnostic in children; adults can have values 10 to 15 mEq/L higher than this.[7,209] A sweat test should be performed in any child with nasal polyps or any patient with chronic colonization of the nose and sinuses with *Pseudomonas* species.[7,210] When results are equivocal, the diagnosis can be clarified by DNA analysis for known genetic mutations: more than 1,000 *CFTR* mutations are known currently.[203] Among these, 16 mutations are thought to account for 85% of CF alleles across the population. The most common is ΔF508, which accounts for more than 70% of CF cases in patients of European ancestry.[211] The ΔF508 product cannot traffic out of the cytoplasm and remains nonfunctional. Several studies have suggested that patients with CRS without clinical evidence of CF carry *CFTR* alleles at a rate significantly higher than in the general population, with rates of up to 12% reported in children and adults.[203,212] DNA analysis has been recommended in all patients with intermediate or positive sweat chloride testing results because this confirms the diagnosis and the results occasionally affect treatment choices. Drugs that are specifically designed to treat patients with certain mutations are being investigated and 1 was recently approved for treatment of patients with G551D mutation.[213]

Virtually all patients with CF have CRS as a consequence of combinations of factors outlined earlier. Clinically, chronic inflammation subsequently stimulates even thicker mucus production, which induces a vicious cycle of chronic sinus disease. CF is an important consideration in all patients who develop CRS at a young age and in any child with nasal polyposis. Overall, sinonasal polyps are observed in approximately 40% of patients with CF, with the prevalence increasing as a function of age.[206,214] As a consequence of thick, inspissated respiratory secretions and the presence of nasal polyps, radiographic evidence of sinus disease is invariably present in patients with CF, occurring in 92% to 100% of patients older than 2 years.[7,215,216]

Clinical signs and symptoms of CRS in patients with CF are similar to those in such patients without CF, although often more subtle because patients become accustomed to having sinus symptoms. Physical examination findings also are similar, except for the higher incidence of polyps. Interestingly, although patients with CF are observed to have worse baseline CT and endoscopy scores compared with matched patients with CRS without CF, improvements in endoscopy score and QOL are similar between groups after treatment with endoscopic sinus surgery.[217]

The spectrum of sinus pathogens obtained during endoscopic sinus surgery in patients with CF primarily include *P aeruginosa*, *S aureus*, and *Streptococcus viridans* and are similar to those recovered from the patient's lower airway, particularly with regard to *P aeruginosa* and *S aureus*.[218] *Burkholderia cepacia*, a gram-negative bacillus, has emerged as an important pathogen in the lower airways of patients with CF, and one should look out for this organism in sinus cultures.[219,220] In addition, there is emerging evidence that *B cepacia* can be cultured in the sinuses of immunocompetent patients with nasal polyposis without CF.[221] The sinuses also may act as a reservoir that seeds the lower airways with bacteria, especially *P aeruginosa*,[218,222] which is present in greater preponderance in CF than is observed in the sinuses of patients with CRS without CF.[210] Fungi also are cultured from the sinonasal tract in up to one third of patients with CF, but the pathophysiologic significance is unclear.[223]

There is no evidence supporting the use of topical antibiotics in the management of CRS in patients with CF, but the utility of topical antibiotic irrigations after sinus surgery has been explored. Compared with a historical control of adults receiving surgery alone, those who underwent postoperative antibiotic lavage, including monthly antral cannulations, required fewer revision operations at the 1- and 2-year follow-up points[224]; more recent work has shown that inhaled tobramycin eradicated *Pseudomonas* species from the lower airways of children for 1 to 3 months after treatment.[225] Other recent small studies have examined augmenting the benefits of surgery with use of nasally inhaled dornase alfa postoperatively. Compared with saline placebo, those receiving dornase alfa found more improvement in nasal symptoms and forced expiratory volume in 1 second ($FEV_1$) up to 12 months after surgery.[226,227]

As alluded to earlier, endoscopic sinus surgery is thought to be effective in the management of CRS in adults with CF,[217,224] and the surgical complication rate appears similar to that of the CRS population without CF. It should be noted that most data in this area are derived from retrospective case series.[217] Many centers advocate aggressive management of rhinosinusitis, including FESS, in patients with CF undergoing lung transplantation.[228–230]

A systematic literature review of FESS in patients with CF has supported the safety of surgery and found a positive effect on symptoms. Endoscopy scores and $FEV_1$ may not improve postoperatively.[231]

## Ciliary dysfunction

Summary Statement 17: Suspect primary ciliary dyskinesia in children with recurrent otitis media, rhinosinusitis, and

pneumonia with bronchiectasis especially if situs inversus is present. (Rec, B)

Primary ciliary dyskinesia (PCD) is a rare autosomal recessive group of disorders occurring in 10 per million children based on a prevalence study from Europe.[7,232,233] Most of these patients have recurrent otitis media, rhinosinusitis, and pneumonia with bronchiectasis.[7,232] Affected patients are generally sterile because defects are associated with sperm and fallopian tube dysfunction. Nearly half the patients have situs inversus with or without dextrocardia, a constellation of clinical findings first described in 4 patients by Kartagener in 1933.[234] Loss of normal mucociliary transport in patients with PCD increases susceptibility to bacterial infection. Some defects also are associated with abnormal neutrophil chemotaxis.[235]

Many symptoms of PCD are nonspecific, such as rhinitis and cough, and sophisticated diagnostic testing should be conducted in centers with experience in treating and diagnosing PCD. Diagnosis of PCD is an area of controversy, and it is currently not clear whether the diagnosis of PCD should be based on genetic testing or functional studies.

Screening tests include measurement of nasal nitric oxide (nNO) and the saccharine test. Nasal NO is low in PCD.[232] Typically, nNO is measured during breath holding (which precludes this test in infants). Low nNO must be evaluated in the clinical context because other conditions, such as CF and diffuse panbronchiolitis, may yield low levels of nNO.[236,237] A high nNO with a low-risk history excludes the diagnosis of PCD.[238] The saccharin test also is useful for screening.[232] A small amount of saccharin is placed at the bottom of the inferior meatus. After 3 minutes, the patient swallows every 30 seconds until a sweet taste is detected. Normally, the patient should detect the saccharin within 6 to 10 minutes.[207] A normal saccharin test result may be useful in ruling out PCD, but an abnormal result needs further evaluation because falsely positive and negative results have been reported.[239]

Visual assessment can be performed by collecting ciliated cells, which are suspended on a glass slide.[232] Ciliary motion should be recorded with a charge-coupled device camera with beat frequency and pattern analysis, because particular patterns are associated with specific ultrastructural abnormalities.[240]

Ciliary structure is determined by transmission electron microscopy and is the definitive test.[232] It is important to communicate with the pathology service to assure proper fixation is used (typically glutaraldehyde).[241,242] In the presence of chronic inflammation (eg, because of infection or smoking), ciliary function might be compromised. In fact, improvement in saccharin clearance has been found after successful FESS.[243] In the setting of CRS, a tracheal biopsy (noninflamed area) might be required for confirmation of suspected primary cilia defects. Defective cilia might be missing any of the following components: outer dynein arms, inner dynein arms, entire dynein arms, central pair, central sheath, radial spokes, or nexin links.[232] Molecular testing may be useful in screening for PCD. There are more than 15 genes involved in different aspects of ciliary structure and function in which mutations have been found to lead to PCD, with the most common genes being the dynein heavy chains DNAH5 and DNAH11.[232]

## Associated conditions

### *Otitis media*

Summary Statement 18: When evaluating a patient with rhinosinusitis, clinicians should look for the presence of otitis media. The converse is also true. (Rec, C)

There are many clinical similarities between otitis media and rhinosinusitis. The ears and paranasal sinuses are located in close proximity to the nasal cavity and have a similar epithelial lining, namely pseudostratified columnar ciliated epithelium. The 3 major pathogens that cause acute otitis media (AOM) and ABRS, *S pneumoniae*, *H influenzae*, and *M catarrhalis*, are the same.[81] The peak age incidence of AOM is 3 to 24 months, and ABRS is most common at 2 to 6 years of age. The important risk factors for AOM and ABRS are viral URIs and AR or NAR.

In many children, AOM and ABRS begin soon after the onset of a viral URI. In a prospective study of 112 children 13 to 15 months of age followed for 1,231 patient-months, the overall incidence of URIs was 6.12 episodes per patient-year, that of AOM was 2.01 episodes per patient-year, and that of ABRS was 0.48 episodes per patient-year.[111] Thirty percent of all URIs were complicated by AOM, 8% were complicated by ABRS, and 2% were complicated by AOM and ABRS.[111] The highest incidence of concomitant URI and AOM occurred in children 6 to 11 months of age, whereas the highest concomitant occurrence of URI and ABRS occurred in children 12 to 23 months of age.[111]

Although many patients with otitis media with effusion have ABRS, the data on this association are limited in the literature.[244–246] In a more recent study of 520 patients undergoing adenotonsillectomies, 15.4% had sinusitis and otitis media with effusion.[247] Therefore, when children with ABRS or CRS are evaluated, it is common to find evidence of AOM or otitis media with effusion and one should be on the lookout for it. Although the relation is less frequent in adults, one should always incorporate an ear examination when evaluating patients with rhinosinusitis.

### *Asthma*

Summary Statement 19: Treat rhinosinusitis vigorously in patients with asthma because medical and surgical management of rhinosinusitis results in objective and subjective improvement of asthma. (Rec, C)

The association between rhinosinusitis and asthma has long been appreciated. In one study, 100% of patients with steroid-dependent asthma had abnormal CT scans of the sinuses compared with 88% of patients with mild-to-moderate asthma.[248] In another group of patients with severe asthma, 84% showed sinus CT abnormalities. There was a significant correlation among sinus CT scores, eosinophils in peripheral blood and induced sputum, and level of exhaled nitric oxide.[249] A recent study in support of the unified airway theory has shown a direct correlation between severity of asthma and severity of CRS measured radiologically.[250] This study also showed that CRSwNP is more likely in severe asthma than in intermittent or mild asthma.

Although these studies suggest that rhinosinusitis triggers or worsens asthma, it could be argued that they merely coexist and represent different end products of the same inflammatory process occurring in different organ systems.

Various mechanisms have been proposed to explain the relation between rhinosinusitis and asthma. They include nasopharyngeal bronchial reflex,[251] pulmonary aspiration of inflammatory cells and mediators,[252] inhalation of dry cold air,[253] and local upper respiratory tract inflammation leading to pulmonary inflammation.[254] In one study of 106 patients with acute exacerbations of CRS, histamine challenges to the lower airway before and after medical treatment of rhinosinusitis were performed. $FEV_1$ was measured as an index of bronchial narrowing, and mid-inspiratory flow was measured as an index of extrabronchial airway narrowing.[255] Intrabronchial and extrabronchial hyperreactivity decreased, with the decrease in extrabronchial hyperreactivity being more pronounced and preceding the decrease in intrabronchial hyperreactivity. The changes in intrabronchial and extrabronchial reactivity were strongly associated with pharyngitis, as determined by history, physical examination, and nasal lavage fluid analysis. The investigators proposed that airway hyperresponsiveness in rhinosinusitis might depend on pharyngobranchial reflexes triggered by the postnasal drip of

inflammatory mediators and infected material from infected sinuses into the pharynx. In a later study, these same investigators found actual damage of pharyngeal mucosa in patients with CRS marked by epithelial thinning and a striking increase in pharyngeal nerve fiber density.[256] This would favor increased access of irritants to submucosal nerve endings, inducing the release of sensory neuropeptides through axon reflexes with activation of a neural arch, resulting in reflex airway constriction.

The linkage previously described between asthma and severity of rhinosinusitis, including eosinophils in peripheral blood and sputum and NO levels in exhaled air, would support the concept that the influence of upper respiratory disease on asthma is mediated through the circulation. It has been hypothesized that inflamed sinus tissue not only releases mediators and cytokines into the circulation, thereby directly inducing inflammation of the upper airway, but also releases chemotactic factors that recruit eosinophils from the bone marrow and from the circulation into the upper and lower airways.[254] The mucosal inflammation in the polyps is orchestrated by T-helper cell type 2 cytokines and it is speculated that it is amplified by *S aureus* exotoxins. It is characterized by increased eosinophilic inflammation and formation of IgE antibodies to staphylococcal exotoxins.[257]

Perhaps the most direct evidence of a cause-and effect relation of rhinosinusitis to asthma is provided by studies that have shown significant improvement in asthma symptoms when rhinosinusitis is appropriately treated. Two uncontrolled observational studies in children with combined infectious rhinosinusitis and asthma showed significant improvement in the asthmatic state, including pulmonary function, when rhinosinusitis was medically treated.[258,259]

Functional endoscopic sinus surgery also has been shown to result in improvement in lower airway disease. In one study, 15 adult patients with CRS who required INSs and at least intermittent oral prednisone to control asthma showed an improvement in symptoms and a decrease in total dosage and number of days of systemic corticosteroid use in the postoperative year.[260] More objective findings were reported in an uncontrolled study of adult patients who not only showed improvement in symptoms but also had a significant increase in peak expiratory flow after FESS.[261]

In a prospective randomized study of 43 patients, medical and surgical treatments of CRS resulted in subjective and objective improvements in asthma. Overall, asthma control improved significantly after the 2 treatment modalities but was better maintained after medical therapy.[262] Although these reports are encouraging, it is evident that blinded RCTs are needed in children and adults to assess therapies of CRS and the response of asthma. Further research is required to establish the relations between the upper and lower airways.

## ABRS

### *Antibiotics in ABRS*

Summary Statement 20: Treat for ABRS if symptoms last longer than 10 days or with recrudescence of symptoms after progressive improvement (Rec, B).

Summary Statement 21: To avoid resistance and potential adverse effects from antibiotics, the workgroup recommends evaluation of $\beta$-lactam allergy by penicillin skin testing and/or graded oral challenge if $\beta$-lactam is the most appropriate antibiotic ABRS. (Rec, B)

### *Acute bacterial rhinosinusitis*

Acute rhinosinusitis and ABRS are defined in the Executive summary. ABRS is used when the inclusion criteria in the studies are stringent enough to suggest ABRS, and ARS is used when the studies may include patients with viral or bacterial rhinosinusitis. Although most cases of ARS are viral in origin, treatment of bacterial infection should be considered when symptoms last longer than 7 to 10 days or with recrudescence of symptoms after progressive improvement. The most commonly reported bacterial pathogens in ABRS are *S pneumoniae*, *Streptococcus pyogenes*, *H influenzae*, *M catarrhalis*, and *S aureus*.[263] The antibiotics currently approved by the FDA for ABRS are azithromycin, clarithromycin, amoxicillin-clavulanate, cefprozil, cefuroxime axetil, loracarbef, levofloxacin, trimethoprim-sulfamethoxazole, and moxifloxacin. Although some studies have reported comparisons of different antibiotics for adult ABRS, not one was found to be superior.[76] It should be noted that, owing to concerns over bacterial resistance, the Infectious Diseases Society of America no longer recommends the use of macrolides for empiric treatment of ABRS.[263] That organization recommends amoxicillin-clavulanate as first-line therapy and doxycycline, levofloxacin, and moxifloxacin in patients allergic to penicillin.[263] To avoid resistance and potential adverse effects from antibiotics, the workgroup recommends evaluation of $\beta$-lactam allergy by penicillin skin testing and/or graded oral challenge if $\beta$-lactam is the most appropriate antibiotic for an urgent case of ABRS. Since its licensure, the prevalence of *S pneumoniae* as a cause of ABRS has probably decreased and *H influenzae* increased. Accordingly, amoxicillin clavulanate is an excellent selection for children with ABRS. Pediatric therapy is discussed in further detail later in the document. The Infectious Diseases Society of America recommends 5 to 7 days of treatment with antibiotics for uncomplicated ABRS in adults and 10 to 14 days in children.[261] Intravenous antibiotics may be considered in children who cannot tolerate oral medications for ABRS or in those with orbital, subperiosteal, or epidural abscesses.[264] The guidelines recommend evaluating a patient with multiple medication allergies by skin testing, if appropriate, or graded oral challenge so that appropriate antibiotics are used.

Although the literature suggests that antibiotics shorten the time to cure in ABRS, there is concern about the adverse effects of antibiotics, including resistance. A previous expert panel recommended a watchful waiting approach without antibiotics in nonsevere ABRS. The panel recommended re-evaluation as necessary and antibiotics if there was worsening or no improvement with symptomatic therapy.[3] A Cochrane database review assessed the effect of antibiotics in uncomplicated ABRS in a primary care setting and concluded that antibiotics are not recommended as first-line treatment in adults with clinically diagnosed ABRS.[265] Their review of 10 trials found that irrespective of the treatment group, 47% of patients were cured after 1 week and 71% after 2 weeks.[265] The investigators noted that the potential benefit of antibiotics needs to be assessed in the context of a high prevalence of adverse effects. This review did not make recommendations for pediatric patients, patients with suppressed immune system, and patients with severe disease.[265] It is important to caution that this was a review in the primary care setting and many cases of ABRS are indeed viral in origin.[265]

### *Steroids in ABRS*

Summary Statement 22: Use INSs for treatment of ARS as monotherapy or with antibiotics. (Rec, B)

Most studies of INS use in ABRS treatment were reported in subjects who were already on antibiotics, although there are some data on INS use as monotherapy for the treatment of ABRS. A trial comparing INS with placebo and amoxicillin in ABRS found that 200 $\mu$g of mometasone furoate twice daily improved symptoms compared with placebo or amoxicillin.[266] A study with fluticasone furoate and another with mometasone furoate showed similar positive effects of INS monotherapy in ABRS, whereas 1 study with budesonide did not show a benefit.[267–269] These studies show that INS monotherapy may be an effective treatment option for uncomplicated ABRS. Potentially, the use of INS monotherapy may

decrease the unnecessary use of antibiotics and thus lower the risk of antibiotic-associated adverse effects and antimicrobial resistance.

Topical INSs are beneficial in ABRS when added to antibiotics. Studies have shown a higher rate of clinical success and more rapid recovery with the addition of INS to antibiotics in the treatment of ABRS.[270,271] A Cochrane database review of the literature found 4 well-conducted randomized, placebo-controlled trials of INS as monotherapy or as adjunctive therapy to antibiotics. The review concluded that there may be a modest beneficial effect with INS in the resolution or improvement of symptoms associated with ABRS. Minor adverse effects such as epistaxis, headache, and nasal itching were reported in these studies.[272] Another recent systematic review and meta-analysis concluded that INSs offer a small therapeutic benefit in ABRS which may be greater with higher doses and with courses of at least 21 days. Antibiotics and INSs were prescribed in 5 of the 6 trials included in this review. Facial pain and congestion were the individual symptoms most improved with topical INS in this study.[273]

There are sparse data on the use of systemic corticosteroids in the treatment of ABRS. A recent randomized, double-blinded, placebo-controlled trial comparing 30 mg/d of prednisolone or placebo for 7 days did not find systemic corticosteroid monotherapy to be superior to placebo.[274] The most recent Cochrane database review on the use of oral steroids in ABRS concluded that oral corticosteroids as adjunctive therapy to oral antibiotics are effective for short-term relief of symptoms in ABRS. However, they also noted that the data are limited and there was a significant risk of bias.[275]

### *Adjunctive therapy with decongestants, antihistamines, and saline in ABRS*

A systematic review of antihistamines and decongestants in common colds found that there is insufficient evidence to suggest that antihistamines or decongestants are of benefit for the common cold. Antihistamines may slightly alleviate rhinorrhea and sneezing, but the overall benefit is minimal. Decongestants decrease congestion over 6 to 10 hours, but there is no evidence to suggest benefit for longer than 10 hours.[276,277] Thus, there is little evidence to suggest the use of antihistamines or decongestants in ABRS, although they may help with symptoms. Topical decongestants, when used for a short period, are of benefit in decreasing congestion but can lead to rebound congestion if used for a longer term.

Nasal irrigation with saline is often used as adjunct treatment of rhinosinusitis, but the evidence is limited. A recent Cochrane database review of saline nasal irrigation for acute URTIs concluded that the trials were too small and had too high a risk of bias to support the use of nasal saline for acute upper respiratory infections.[278] Although the evidence is limited, saline irrigation may improve mucociliary clearance and provide symptomatic relief by mechanically facilitating mucus removal.

### *Complementary treatment*

Supplements such as zinc and vitamin C are extensively used in the treatment of the common cold and ARS; however, the studies don not show consistent benefit in treating ABRS.[279] Similarly, herbal supplements are used for treatment of the common cold and for ABRS. However, the evidence is often of poor quality and more rigorous studies are necessary before conclusions can be drawn about the effectiveness of herbal supplements in treating ABRS.[280]

## CRS

### *Systemic antibiotics in CRS*

Summary Statement 23: Clinicians should use systemic antibiotics for acute exacerbations of CRS. However, in some patients, this may not be necessary. (Rec, C)

Antibiotic treatment for CRS is controversial because of a lack of evidence from well-conducted clinical trials. Clinical trials that specifically attempt to eradicate pathogens or that document sterilization of sinus cavities are very limited. Eradication of infection also depends greatly on whether sinus aeration and adequate mucociliary clearance can be restored. A recent Cochrane review identified only 1 RCT of antibiotics, the study of long-term macrolide treatment (see below), but this study excluded nonplacebo comparison studies.[281] Since then, another RCT of long-term macrolides was published, with negative results.[282]

Antibiotics are acknowledged as useful for acute exacerbations of CRS.[3,18,44] The most appropriate patients with CRS for antibiotic treatment are those with persistent purulent drainage. For patients with persistent purulence despite previous antibiotics, obtaining a sinus culture is strongly recommended.[105]

### *CRS without nasal polyps*

A few nonplacebo-controlled comparison RCTs of systemic antibiotics have been conducted for CRS. These studies have focused on "CRS," presumably more representative of CRSsNP than CRSwNP. Short-term treatment trials are defined as those no longer than 4 weeks in duration. In a study by Huck et al,[283] 56 patients with ABRS, 25 patients with RARS, and 15 patients with CRS (maxillary involvement) were randomized to receive 500 mg of cefaclor twice a day or 500 mg of amoxicillin 3 times a day for 10 days. Clinical improvement was reported in 86% of patients with ARS and 56% of those with recurrent rhinosinusitis. No significant differences in outcomes were noted in cefaclor- vs amoxicillin-treated patients. The small number of patients with CRS precluded any meaningful comparison of differences in outcome compared with patients with recurrent or acute sinusitis. In a study by Legent et al,[284] amoxicillin-clavulanate was compared with ciprofloxacin. Treatment lasted only 9 days; however, patients were evaluated 40 days after treatment. Similar clinical cure and bacteriologic eradication rates were found for the 2 treatments; however, in patients who had a positive initial culture and who were evaluated 40 days after treatment, ciprofloxacin had a higher cure rate (83.3% vs 67.6%, $P = .043$) and fewer gastrointestinal side effects. In a study by Namyslowski et al,[285] patients with CRS or acute exacerbations of CRS were treated with amoxicillin-clavulanate or cefuroxime acetyl for 14 days. The bacteriologic cure rates, defined as eradication of the original pathogen with or without recolonization with nonpathogenic flora, were similar for the 2 treatments, although relapses were more frequent in cefuroxime-treated patients.[285]

Although consensus documents on rhinosinusitis treatment have historically included a recommendation for prolonged course of antibiotic treatment in refractory cases, there is very little published evidence to support this practice. In an open-label study of adult patients with CRS refractory to previous antibiotic treatment, Dubin et al[286] treated patients with 150 mg of clindamycin 3 times a day (13 patients), amoxicillin-clavulanate (2 patients), or doxycycline (1 patient) for 6 weeks and performed sinus CT scanning at baseline and week 3 and week 6 of treatment. Improvement in the Lund-Mackay score was noted after comparing baseline with week 6 (8.9 to 4.1).[286] This improvement occurred between weeks 3 and 6 in 6 patients (38%).[2865] Only 1 of these 6 patients was recommended for sinus surgery after the 6 weeks of treatment.[286] This small study suggests some patients with CRSsNP may benefit from prolonged antibiotic treatment. This may be especially relevant to treatment of pediatric CRS, in which the histopathology is most consistent with chronic infection.[287,288]

### *CRS with nasal polyps*

Mucosal colonization with *S aureus* has been found in 64% of patients with CRSwNP compared with roughly 30% of healthy

subjects or patients with CRS.[289] In addition, IgE directed against staphylococcal superantigens have been found in the tissues of a large percentage of patients with CRSwNP who had colonization.[205] Given the substantial evidence for the presence of colonizing *S aureus* producing superantigens in CRSwNP,[289,290] 2 recent studies assessed whether anti-staphylococcal antibiotic treatment could ameliorate symptoms or decrease nasal polyp size.

Van Zele et al[291] conducted a randomized, double-blinded, placebo-controlled trial to assess whether doxycycline could decrease nasal polyp size and provide anti-inflammatory effects. Doxycycline (200 mg on the first day followed by 100 mg once daily for 20 days) caused a small but statistically significant decrease in polyp size beginning at week 2 and persisting for 12 weeks.[291] A significant decrease in nasal secretion of eosinophil cationic protein also was found after 20 days of doxycycline treatment.[291] However, doxycycline caused no statistically significant improvement in nasal peak inspiratory flow rate.[291]

A placebo controlled study was performed by Schalek et al.[292] In this study, 23 patients undergoing FESS who tested positive for *S aureus* enterotoxin-producing strains were randomized to oral anti-staphylococcal antibiotics (quinolone, amoxicillin-clavulanate or cotrimoxazole) or placebo for 3 weeks.[292] The 2 groups were compared preoperatively and at 3 and 6 months using endoscopic scoring and the Sino-Nasal Outcome Test-22.[292] Slightly better results were found in the antibiotic group, but this difference did not reach significance.[292] Doxycycline had a significant but small effect on polyp size compared with placebo, which was present for the length of the study (12 weeks).[292] Doxycycline showed a significant effect on postnasal discharge but not on other CRS symptoms.[292]

### *Long-term systemic macrolide antibiotics*

Long-term use of macrolide antibiotics has been popularized by reports suggesting that macrolides have anti-inflammatory effects.[293] However, clinical studies showing beneficial effects are quite limited. These studies do not clearly differentiate effects in CRSsNP or CRSwNP.

Ragab et al[294] performed a prospective RCT of medical vs surgical treatment of CRS. In this trial, 90 patients with CRSsNP or CRSwNP were randomly assigned to medical vs surgical treatment. All patients received an initial 6 weeks of medical treatment and only patients remaining symptomatic after this treatment were randomized into the study.[294] Medical treatment consisted of erythromycin (500 mg twice daily for 2 weeks followed by 250 mg twice daily for 10 weeks), alkaline nasal irrigation, and intranasal corticosteroids for 12 weeks.[294] Surgically treated patients received a 2-week course of 500 mg of erythromycin twice daily, Dexa-Rhinaspray, and alkaline nasal douches followed by a 3-month course of fluticasone propionate intranasal spray (100 $\mu$g/d per nostril) plus alkaline nasal douche. Patients in the medical and surgical groups showed significant improvement, and no significant differences in subjective and objective parameters of CRS were found between groups.[294] The combined use of antibiotics with nasal douches and INSs precludes any assessment of the effect of long-term macrolides in this study.

The study by Wallwork et al[295] was a randomized, placebo-controlled investigation of 150 mg/d of roxithromycin vs placebo for 12 weeks. Patients in the roxithromycin group showed a statistically significant change from baseline in Sino-Nasal Outcome Test-20 score at 12 weeks, which was not seen in the placebo group.[295] By using a "change from baseline" analysis, the roxithromycin group also showed an improvement in saccharine transit time and nasal endoscopy not observed in the placebo group.[295] The statistical analysis in this study was unconventional in that it evaluated the results of each study arm at study end against respective values at baseline rather than a more conventional comparison of the change from baseline in each arm using an analysis of covariance model.[295]

In a study by Videler et al,[282] 60 patients with CRSsNP or CRSwNP were randomized to receive azithromycin vs placebo at 500 mg/d for 3 days and then 500 mg weekly for 11 weeks. Multiple clinical assessment tools were used, including symptom scoring, the Short Form-36, rigid nasal endoscopy, peak nasal inspiratory flow, and endoscopically guided middle meatus cultures. No significant differences were found between groups at the end of treatment.

### *Topical antibiotics in CRS*

Summary Statement 24: Consider a 3- to 6-week course of topical antibiotics for CRS. (Rec, C)

A recent systematic review of topical antimicrobials for CRS concluded that there is some evidence for the use of antibiotic nasal irrigations or nebulizations.[296] The highest level of evidence exists for studies of postsurgical patients and culture-directed therapy. CRS and acute exacerbations of CRS might conceivably benefit. Most topical antibiotic studies have involved administration of nebulized antibiotic for 3 to 6 weeks in prospective observational studies only rather than double-blinded or placebo-controlled studies.[297,298] Excellent to good improvement was reported in 82% of cases. Endoscopic improvement and an increase in infection-free interval after treatment were reported in another study.[298] Recent examples include the study of mupirocin irrigations for patients with refractory CRS with culture-proven *S aureus* infection.[299] Topical irrigation with 80 mg/L of gentamicin or tobramycin also can be useful for this purpose.[300] Most studies reported a low rate of side effects. Twice-daily irrigation with gentamicin for 3 to 15 weeks caused low but measurable systemic absorption, with blood levels ranging from 0.3 to 0.7 mg/mL.[301] Sensorineural hearing loss was noted in 23% of patients with CF who had used frequent irrigations.[302] Topical aminoglycosides should be used with caution and for a defined treatment period. Topical antibiotics can be administered with or without a nebulizer.

### *Intravenous antibiotics for CRS*

Intravenous antibiotics have been used in the treatment of CRS; however, the studies have been conflicting. In an observational cohort, Anand et al[303] reported improvement in symptom scores; however, the study was underpowered and no comparator group was included. In a retrospective chart review of patients with CRS treated with intravenous antibiotics for an average of 4.8 weeks, only 29% of patients had disease resolution and there was an 89% relapse rate.[304] There are also potentially serious complications associated with intravenous antiobiotics.[305] A recent evidence-based review recommended against the use of intravenous antibiotics for uncomplicated CRS.[306]

### *Combination therapy with systemic antibiotics and systemic steroids for CRS*

Summary Statement 25: Consider the use of systemic antibiotics plus a short course of oral steroids in the treatment of CRS. Greater benefit with antibiotics has been reported in CRSsNP than in CRSwNP. (Rec, A)

Oral steroids have been used as an adjunct to antibiotic or INS for treatment of CRSsNP in limited studies. These studies reported improved CRS outcomes after treatment. Subramanian et al[307] performed a retrospective chart review of 40 patients with CRS who were treated with antibiotics for 4 weeks plus 20 mg of prednisone twice daily for 8 to 10 days. The study population consisted of patients with CRSsNP and CRSwNP. Thirty-six of the 40 patients showed symptomatic and/or radiographic improvement after the medical regimen. Twenty-six patients had sustained

**Table 6**
Recommendation for induction of aspirin drug tolerance (aka aspirin desensitization)[a,349–352]

| | |
|---|---|
| Assessment and premedication (≤1 wk before procedure) | $FEV_1$ >70% predicted on day of procedure (if outpatient)[b] |
| | start or continue leukotriene modifier therapy |
| | start or continue treatment with high-dose inhaled corticosteroid and long-acting β-agonist if poorly controlled asthma (may continue current asthma medication if asthma is well controlled) |
| | systemic steroid burst if low $FEV_1$ or bronchial instability |
| | if receiving maintenance systemic steroids, consider doubling daily dose (if on alternate-day steroids, change to daily dose) |
| | discontinue oral antihistamines and decongestants 48 h procedure[c] |
| Protocol[d] | |
| Cumulative time (h) | Aspirin dose (mg) |
| 0 | 20.25 |
| 1.5[e] | 40.5[f] |
| 3.0 | 60.75 |
| 4.5 | 81 |
| 6.0 | 101.25 |
| 7.5 | 162.5 |
| 9.0 | 325 |
| 10.5 | 650[g] |

Abbreviation: $FEV_1$, forced expiratory volume in 1 second.
[a]Once a patient is diagnosed with aspirin-exacerbated respiratory disease, there are 2 choices. The patient is advised to completely avoid cyclooxygenase-1 inhibitors or to consider aspirin desensitization and continuous aspirin therapy. Patients with aspirin-exacerbated respiratory disease in whom aspirin desensitization should be considered include those who have suboptimal control with currently available pharmacologic therapy, those who have required multiple polyp removal surgeries, those who require frequent or daily systemic steroids to control nasal or asthma symptoms, and those who require aspirin or other nonsteroidal anti-inflammatory drugs for other coexisting disease, such as cardiovascular disease or arthritis. Contraindications to aspirin desensitization include pregnancy, unstable asthma, gastric ulcers, and bleeding disorders.
[b]The patient's asthma should be optimized and stable. An $FEV_1$ ≤70% predicted warrants conducting this procedure in an inpatient setting. Inpatient desensitization also should be used for patients with risk factors such as recent myocardial infarction or β-blocker use.
[c]Discontinue antihistamines and decongestants before the challenge so that a naso-ocular reaction can be observed and aspirin sensitivity can be confirmed.
[d]Before the procedure, document informed consent and advise the patient it may take several days to complete (often 2 days). The patient should understand that there may be a severe exacerbation of asthma, and that if aspirin is stopped for longer than 48 hours, the desensitization procedure will need to be repeated. If the procedure is performed over 2 days, the first dose given on day 2 should be the highest tolerated dose the patient received on day 1. Throughout the procedure, $FEV_1$ and clinical assessment should occur every 90 minutes and with symptoms. Intravenous access, emergency resuscitation equipment (including nebulized β-agonists and intramuscular epinephrine), and medical supervision also should be present.
[e]Dosing interval may be extended to 3 hours based on individual patient characteristics. An alternative protocol, involving use of Alka-Seltzer, is shown in Table 7.
[f]Reactions will likely occur with early doses, usually 40.5 to 60.75 mg. The average time to reaction is 1 to 2 hours after the last dose. Treat reactions. After the patient is completely stabilized (but not <3 hours after the last dose), the provoking dose can be repeated. When the provocation dose is tolerated, dose escalation may continue. A persistent decrease in $FEV_1$ greater than 15%, with or without associated symptoms, lasting longer than 3 hours despite therapy, is an indication to discontinue the desensitization process for the day. If nasal, gastrointestinal, or cutaneous reactions occur on day 1, pretreat with histamine-1 and histamine-2 receptor antagonists for the remainder of the procedure.
[g]After successful desensitization, the patient should continue taking 650 mg twice daily, but tapering of the dose can be attempted if the patient is doing well 6 months after desensitization. Some patients may require only 325 mg twice or once a day to maintain improvement. If the need for higher-dose aspirin or another nonsteroidal anti-inflammatory drug is likely, continue maintenance with at least 325 mg/d.

symptomatic benefit beyond 8 weeks of the initial treatment. Using a log-rank test to compare rates of sinusitis relapse, patients with CRSwNP or a history of sinus surgery were more likely to develop relapse within 8 weeks. In contrast, atopy, asthma, and persistent obstruction of the ostiomeatal unit were not associated with early relapse.

The highest level of evidence comes from a prospective case series[308] and a recently published double-blinded, placebo-controlled trial in children.[309] In the latter study, children were randomized to receive amoxicillin-clavulanate in combination with either methylprednisolone (MP) or matching placebo. The amoxicillin-clavulanate plus MP treatment arm was superior in decreasing radiographic extent of disease and alleviating symptoms.

### *Glucocorticoids in CRS*

#### *Systemic glucocorticoids*

Summary Statement 26: Consider a short course of oral steroids for treatment of CRSsNP. (Rec, C)

Summary Statement 27: Use short-term treatment with oral steroids in CRSwNP because it decreases polyp size and alleviates symptoms. (StrRec, A)

#### *CRS without nasal polyps*

In a retrospective series of children with CRS, oral glucocorticoids alone, but not antibiotics alone, led to significant radiologic improvement.[310] Lal et al[311] performed a systematic review of oral glucocorticoids for CRSsNP and reported symptom resolution in 54% of patients with CRSsNP vs 51% of patients with CRS in general.

#### *CRS with nasal polyps*

A brief course of oral glucocorticoids is popularly used to relieve CRS symptoms and decrease nasal polyps ("medical polypectomy"). Treatment usually results in clinical improvement and transient improvement in sense of smell, although the duration of clinical benefit is variable and may decrease with repeated courses (expert opinion). A systematic review of oral glucocorticoids for CRSwNP found only 1 randomized trial that met the inclusion criteria.[312] In this trial, 60 adult patients with severe nasal polyps were randomly assigned to receive oral prednisone (2-week taper starting at 30 mg/d for 4 days with a 5-mg decrease every 2 days) or no steroid treatment for 2 weeks.[313] The prednisone-treated patients showed significant improvement in symptom scores and polyp size at 2 weeks compared with 18 patients who received placebo.[313]

Hissaria et al[314] performed a randomized double-blinded, placebo-controlled trial with 20 subjects per group. The group receiving prednisolone treatment (50 mg/d for 14 days) was associated with improvement in rhinosinusitis outcome measurement scores, a decrease in polyp size, and improvement in the extent of sinus disease at MRI. Other studies have reported the benefit of prednisone given over a 2-week period (30 mg/d for 4 days followed by a 2-day decrease of 5 mg) followed by INSs for 10 weeks.[315]

**Table 7**
Alternative Protocol for Induction of Aspirin Drug Tolerance (aka Aspirin Desensitization)[a] using Alka-Seltzer[349–352]

| | |
|---|---|
| Assessment and premedication (≤1 wk before procedure) | $FEV_1$ >70% predicted on day of procedure (if outpatient)[b]<br>start or continue leukotriene modifier therapy<br>start or continue treatment with high-dose inhaled corticosteroid and long-acting β-agonist if poorly controlled asthma (may continue current asthma medication if asthma is well controlled)<br>systemic steroid burst if low $FEV_1$ or bronchial instability<br>if receiving maintenance systemic steroids, consider doubling daily dose (if on alternate-day steroids, change to daily dose)<br>discontinue oral antihistamines and decongestants 48 h before procedure[c] |
| Prepare 5-mg/mL mixture of water and Alka-Seltzer | dissolve 325 mg of Alka-Seltzer (regular strength) in 65 mL of water (alternatively, dissolve 500 mg of Alka-Seltzer Extra Strength in 100 mL of water) |
| Protocol[d] | |
| Cumulative time (h) | Aspirin dose (mg) in mixture (mL) |
| 0 | 5 (1) |
| 1[e] | 25 (5) |
| 2.5 | 80 (16)[f] |
| 4 | 160 (32)[g] |
| 5.5 | 325 (65)[h] |
| 7 | 650[i] |

Abbreviation: $FEV_1$, forced expiratory volume in 1 second.
[a]Once a patient is diagnosed with aspirin-exacerbated respiratory disease, there are 2 choices. The patient is advised to completely avoid cyclooxygenase-1 inhibitors or to consider aspirin desensitization and continuous aspirin therapy. Patients with aspirin-exacerbated respiratory disease in whom aspirin desensitization should be considered include those who have suboptimal control with currently available pharmacologic therapy, those who have required multiple polyp removal surgeries, those who require frequent or daily systemic steroids to control nasal or asthma symptoms, and those who require aspirin or other nonsteroidal anti-inflammatory drugs for other coexisting disease, such as cardiovascular disease or arthritis. Contraindications to aspirin desensitization include pregnancy, unstable asthma, gastric ulcers, and bleeding disorders.
[b]The patient's asthma should be optimized and stable. $FEV_1$ ≤70% predicted warrants conducting this procedure in an inpatient setting. Inpatient desensitization also should be used for patients with risk factors such as recent myocardial infarction or β-blocker use.
[c]Discontinue antihistamines and decongestants before the challenge so that a naso-ocular reaction can be observed and aspirin sensitivity can be confirmed.
[d]Before the procedure, document informed consent. The patient should understand that there may be a severe exacerbation of asthma, and that if aspirin is stopped for longer than 48 hours, the desensitization procedure will need to be repeated. Throughout the procedure, $FEV_1$ and clinical assessment should occur every 90 minutes and with symptoms. Intravenous access, emergency resuscitation equipment (including nebulized β-agonists and intramuscular epinephrine), and medical supervision also should be present.
[e]Dosing interval may be extended to 3 hours based on individual patient characteristics.
[f]Instead of the mixture of Alka-Seltzer and water, the clinician may consider administering 1 81-mg tablet of aspirin for this step. Reactions to aspirin tend to occur with early doses, usually 40.5 to 60.75 mg. The average time to reaction is 1 to 2 hours after the last dose. Treat reactions. After the patient is completely stabilized (but not <3 hours after the last dose), the provoking dose can be repeated. When the provocation dose is tolerated, dose escalation may continue. A persistent decrease in $FEV_1$ greater than 15%, with or without associated symptoms, lasting longer than 3 hours despite therapy, is an indication to discontinue the desensitization process for the day. If nasal, gastrointestinal, or cutaneous reactions occur on day 1, pretreat with histamine-1 and histamine-2 receptor antagonists for the remainder of the procedure.
[g]Instead of the mixture of Alka-Seltzer and water, the clinician may consider administering 2 tablets of aspirin containing 81 mg each (total 162 mg) for this step.
[h]Instead of the mixture of Alka-Seltzer and water, the clinician may consider administering 1 325-mg tablet of aspirin for this step.
[i]Administered as 2 tablets of aspirin containing 325 mg each (total 650 mg). After successful desensitization, the patient should continue taking 650 mg twice daily, but tapering of the dose can be attempted if the patient is doing well 6 months after desensitization. Some patients may require only 325 mg twice or once a day to maintain their improvement. If the need for higher-dose aspirin or another nonsteroidal anti-inflammatory drug is likely, continue maintenance with at least 325 mg/d.

In an open-label study, patients with severe nasal polyps received oral prednisone (n = 60) or no steroid treatment (control group, n = 18) for 2 weeks.[313] Treatment with prednisone consisted of 2-week taper starting at 30 mg/d for 4 days with a 5-mg decrease every 2 days followed by intranasal budesonide (400 mg twice daily) and showed significant improvement in symptom scores and polyp size at 2 and 12 weeks compared with 18 patients who received placebo.[313] In clinical practice, topical steroids are often begun simultaneously with oral steroids. The British rhinosinusitis guidelines suggest prednisolone (0.5 mg/kg each morning for 5–10 days) accompanied by instillations of betamethasone nasal drops (not approved or available in the United States).[109]

An MP treatment arm was included in a recent doxycycline trial for CRSwNP.[291] In this trial, MP treatment alone significantly decreased nasal polyp size compared with placebo.

*Steroid nasal sprays (INSs) and steroid sinus irrigations*

Summary Statement 28: Use INS (sprays and aerosols) for the treatment of CRSwNP and CRSsNP. (StrRec, A)

*Intranasal corticosteroids (sprays and aerosols) for CRSsNP*

Intranasal corticosteroids have been studied in CRSsNP. The studies vary in whether they included patients with previous sinus surgery. A meta-analysis of 5 published studies was reported in the European Position Paper on rhinosinusitis and nasal polyps 2012 document.[76,317–321] This analysis included the study by Lavigne et al[317] and Furukido et al[319] using topical steroid delivery to the sinuses but did not include other studies for various reasons, including lack of a placebo control group[321] or lack of an INS-only treatment arm.[322,323] It is not clear why the studies of Qvarnberg et al,[324] Parikh et al,[316] Dijkstra et al,[325] Hanson et al,[326] and Mosges et al[327] were not included in this analysis. The meta-analysis concluded that "topical" steroid treatment was effective for CRSsNP, but it is important to point out that 2 of the 5 studies reviewed involved instillation of steroid into the sinuses.[76] INSs per se have not been consistently effective in CRSsNP. Adequacy of delivery of INSs to the sinuses is a significant factor affecting the efficacy of INSs in CRSsNP (see discussion of topical steroid instillations below).

*Intranasal steroids (sprays and aerosols) for CRSwNP*

Intranasal steroids (sprays and aerosols) have been extensively studied as a treatment for CRSwNP, with studies dating to 1975. Several different INSs have been shown to be effective at decreasing nasal polyp size or preventing the regrowth of nasal polyp after surgical removal, including (in alphabetic order) beclomethasone diproprionate, budesonide, ciclesonide, flunisolide, fluticasone furoate, fluticasone propionate, mometasone furoate, and triamcinolone acetonide. None of the studies compared one INS to another. The published studies have consistently shown INS to be superior to placebo for improving nasal patency, lessening nasal symptoms, decreasing polyp size, and improving QOL when used for 1 to 12 months; however, the magnitude of effect is variable and not seen in all studies (eg, Keith et al[328]). Furthermore, the extent to which use of INS prevents the need for sinus surgery or regrowth of nasal polyps is still not well established.[329] Some studies have shown superior results from the use of higher doses of INS.[330–332]

*Steroid sinus instillations or drops*

Topically applied corticosteroids have been studied as a means of improving the therapeutic efficacy of corticosteroids for CRSwNP. These studies compared topical corticosteroid treatment with placebo, not with intranasal treatment. The studies were mixed with respect to prior sinus surgery.

*Steroid sinus instillations or drops for CRSsNP*

Two studies of topical steroid irrigations (rinses) for CRSsNP have been conducted, both of which showed a benefit from topical steroid instillation through a catheter.[317,318]

*Steroid sinus instillations or drops for CRSwNP*

Topically applied steroid instillations also have been studied as a treatment for CRSwNP. Three studies showed a beneficial effect of topically applied steroids on polyp size[331,333,334] and 1 showed improvement in patient QOL.[335] The study by Keith et al[328] showed a nonsignificant decrease in nasal polyp size but improvement in nasal blockage and peak nasal inspiratory flow. The study by Ehnhage et al[336] found no benefit from topically applied steroids. In this study, patients underwent FESS at week 5 after initiation of fluticasone propionate nasal drops or placebo, after which the treatment was continued another 5 weeks. It is possible that the effects of fluticasone propionate nasal drops were masked by FESS in this study. In the study by Aukema et al,[334] topically delivered fluticasone propionate was superior to placebo at improving disease-specific symptoms and grading of nasal polyp severity using a visual analog scale score. The duration of this study was 12 weeks, and treatment was unassociated with significant systemic toxicity. The primary outcome measurement in this study was the physician's assessment of the need for sinus surgery. Treatment with fluticasone propionate nasal drops was associated a decreased need for sinus surgery (from 78% to 52%).

Topical steroid instillations and/or drops are not approved by the FDA in the United States.

*Saline irrigations*

Summary Statement 29: Use nasal saline irrigation as an adjunctive treatment for the therapy of CRS. (Rec, A)

Nasal saline irrigation is used as an adjunct treatment of CRS. It has been shown to improve QOL and decrease infections and medications.[337–339] A Cochrane Database review evaluating the efficacy and safety of nasal saline irrigation concluded that saline irrigations are well tolerated and that saline is beneficial for symptoms of CRS as a sole modality and as an adjunct to treatment.[338] There also was some evidence that hypertonic saline may be better than isotonic saline.[338]

Although generally considered safe, 2 deaths in the United States related to *Naegleria fowleri* were reported in individuals using nasal irrigation with Neti pots. *Naegleria fowleri*, present in unboiled or otherwise unsterilized water, causes the fatal brain infection primary amoebic meningoencephalitis.[340]

Distilled or boiled tap water is the safest way of mixing the solution for saline irrigation and patients should be instructed on cleaning the device to prevent bacterial contamination.[341]

The optimal delivery method for saline irrigation is not clear. Studies have suggested that squeeze bottles may provide the best delivery to sinuses and are superior to saline sprays, nebulizers, or low-pressure devices, such as the Neti pot.[339,342]

*Antihistamines*

Summary Statement 30: Consider antihistamines for treatment of symptoms associated with AR in patients with coexistent CRS. (Opt, D)

Patients with underlying AR also might benefit from a daily, nonsedating second-generation antihistamine, particularly if sneezing and rhinorrhea are present.[76] Allergen remediation measures in the home or workplace and specific allergen immunotherapy to decrease sensitivity to specific allergens can help lessen mucosal edema over time.

*α-Adrenergic decongestants*

Summary Statement 31: Neither oral nor topical decongestants are beneficial for maintenance treatment of CRS. (Opt, D)

Long-term use of oral decongestants is generally not recommended for maintenance treatment because of concerns about increasing blood pressure and lack of supportive clinical evidence. Topical decongestants can be considered for short-term and possibly for intermittent or episodic therapy of nasal congestion but are inappropriate for regular daily use because of the risk of development of rhinitis medicamentosa.[343]

*Leukotriene modifiers*

Anti-leukotriene agents have been used as an adjunct to topical glucocorticoids in the treatment of CRSwNP.[344–346] A small randomized trial reported a modest benefit of montelukast after 1 month for health-related QOL but not for nasal eosinophil cationic protein levels or polyp size.[344] Montelukast also was shown to afford a modest symptomatic benefit over placebo (significantly less headache, facial pain, and sneezing) when given as an adjunctive therapy to oral prednisolone and budesonide nasal spray.[346] In patients with aspirin-intolerant asthma, montelukast blocked the increase in nasal airway resistance and decrease in nasal volume induced by intranasal lysine-aspirin, whereas the nasal reaction to lysine-aspirin remained unchanged with placebo.[347] It is unclear whether the 5-lipoxygenase inhibitor zileuton is any more effective than cysteinyl leukotriene D4 receptor blockers (eg, montelukast or zafirlukast) for treatment of nasal polyps. Leukotriene-modifier drugs are useful to help protect against significant aspirin-induced bronchospasm during aspirin desensitization.[348]

*Pharmacologic induction of aspirin drug tolerance (aka aspirin desensitization)*

Summary Statement 32: Consider aspirin desensitization followed by aspirin therapy in patients with AERD that is refractory to other medical therapy. (Rec, C)

A subgroup of patients with CRSwNP and asthma note worsening respiratory symptoms with aspirin and nonsteroidal anti-inflammatory drug ingestion and have been classified as having Samter triad or AERD. Management of patients with AERD involves avoidance of aspirin and other nonsteroidal anti-inflammatory drugs and aggressive medical and/or surgical treatment of underlying asthma, rhinitis, and rhinosinusitis. A pharmacologic induction of a drug-tolerance procedure, also called aspirin desensitization, during which tolerance to aspirin is induced and maintained, is a potential therapeutic option for patients with AERD. This procedure consists of administration of incremental oral doses of aspirin over 1 to 2 days until a dose of 650 mg of aspirin can be taken without adverse reaction (Tables 6, 7).[349,350–352] Although 650 mg twice a day is the optimal initial dose, lower doses such 325 mg twice a day also may be effective.[349] The desensitization procedure may be conducted in an outpatient setting, particularly if the patient's $FEV_1$ exceeds 70% predicted. The procedure requires frequent monitoring with spirometry in an observational setting with trained staff. Coexistent asthma needs to be optimized with medications, including INSs, long-acting β-agonists, and leukotriene inhibitors, before the procedure.[353,354] Initiation of a proton pump inhibitor and misoprostol may be considered, based on patient preference.[355] Recently, a modified oral aspirin desensitization protocol using intranasal ketorolac followed by rapid oral aspirin challenge was published. This protocol decreased the duration of the desensitization process and was safer compared with standard oral aspirin desensitization protocols.[356]

Induction of drug tolerance of patients with AERD may be appropriate if aspirin is therapeutically necessary or if the respiratory disease is poorly controlled with medical and/or surgical treatment. Aspirin desensitization therapy improves clinical outcomes for upper and lower respiratory tract disease.[357–359] There is a documented decrease in asthma-related hospitalizations, emergency department visits, and medication use with aspirin desensitization. In addition, improvements in asthma symptom scores and sinus disease and symptoms including sense of smell have been noted. During long-term aspirin desensitization, urinary leukotriene E4 is lowered to baseline levels, leukotriene C4 and histamine in nasal secretions disappear, bronchial responsiveness to leukotriene E4 is greatly decreased, and cysteinyl leukotriene receptor-I expression decreases on respiratory cells.[360–364]

Zileuton, a 5-lipoxygenase inhibitor, has been studied as add-on therapy in 40 patients with AERD. This addition resulted not only in alleviation of asthma but also in return of smell, less rhinorrhea, and a trend toward less stuffiness and greater nasal inspiratory flow.[365]

## Antifungal drugs

Summary Statement 33: Realize that neither topical antifungals (sprays and irrigations) nor systemic terbinafine are beneficial for treatment of CRS. (Rec, A)

Antifungal treatment for CRS is predicated on studies showing that (1) fungal hyphae colonize the mucus of a large percentage of patients with CRS[366,367] and (2) that patients with CRS may show a systemic immune hyperresponsiveness to common inhalant fungi, such as *Alternaria* species, as evidenced by activation of peripheral blood T lymphocytes to produce IL-5, IL-13, and interferon-$\gamma$.[368] However, some studies have failed to confirm the latter observation.[369]

A double-blinded, placebo-controlled trial of topical amphotericin B involving 24 patients treated for 6 months produced a small but statistically significant improvement in sinus mucosal thickening.[370] However, a subsequent double-blinded, placebo-controlled trial in Europe involving 116 patients treated for 3 months failed to show efficacy over placebo.[371] Suboptimal delivery of a topical antifungal medication to affected sinus areas is a potential explanation for failure of antifungal treatment. However, a study of oral terbinafine given at a dose of 625 mg/d vs placebo also failed to show efficacy in symptomatic or radiographic improvement for the treatment of CRS in a 12-week RCT of 56 patients.[372] There are no other studies of systemic antifungal treatment for CRS. In summary, the published clinical trials of antifungal treatment failed to show benefit of antifungal treatment and fall short of providing compelling proof for the "fungal hypothesis" of CRS pathogenesis. Potential limitations of these trials include that (1) the studies enrolled patients with CRS without regard to the presence or absence of nasal polyps (it is unknown whether fungi might play a greater role in CRSwNP than in CRSwNP), (2) the antifungal trials involved a very crude quantification of "fungal burden" in the sinus mucus and did not confirm whether antifungal treatment actually eradicated colonization, (3) the degree of systemic immune hyperresponsiveness to fungi was not assessed before treatment, and (4) the studies involving antifungal rinses did not assess how well the antifungal drug actually rinsed the sinuses.

### *Biologic therapy with anti–IL-5*

Summary Statement 34: Clinicians should be apprised that, although not approved for commercial use, anti–IL-5 monoclonal antibody (reslizumab or mepolizumab) has shown benefit in treatment of CRSwNP. (Rec, B)

Gevaert et al[373] performed a phase I, double-blinded, placebo-controlled RCT of a single-dose treatment with reslizumab at 3 or 1 mg/kg or placebo. In this study, nasal polyp score was only significantly decreased in the 1-mg/kg reslizumab treatment group at week 12. In contrast, peripheral blood eosinophil numbers and concentrations of eosinophil cationic protein in serum and nasal secretions were decreased up to 8 weeks in the 2 active treatment arms. Individual nasal polyp scores improved in only 50% of treated patients for 4 weeks ("responders"). Responders had increased IL-5 concentrations in nasal secretions at baseline compared with nonresponders.

Gevaert et al[374] conducted a double-blinded, placebo-cotrolled RCT of mepolizumab as a treatment for CRSwNP in patients deemed "refractory" to corticosteroid therapy (defined only insofar as to indicate that patients "must have had failure of standard care for CRSwNP"). In this study, patients received active treatment ($n = 20$), consisting of 2 single intravenous injections (28 days apart) of 750 mg of mepolizumab, or placebo ($n = 10$) over an 8-week period. Mepolizumab treatment was associated with a significant decrease in nasal polyp size lasting at least 1 month after dosing in 12 of the 20 patients ($P = .028$ vs placebo). This study found no relation between mepolizumab response and nasal IL-5 levels.

### *Biologic therapy with anti-IgE (omalizumab)*

Summary Statement 35: Consider anti-IgE (omalizumab) for treatment of CRSwNP. (Rec, C)

A 2010 RCT by Pinto et al[127] did not find a significant effect when patients with CRS were treated with omalizumab, but 2 recent studies have suggested a benefit.[128] Gevaert et al[128] conducted a double-blinded, placebo-controlled RCT of omalizumab as a treatment in patients with CRSwNP and comorbid asthma. Allergic and nonallergic patients with CRSwNP and asthma were included. Patients received 4 to 8 (subcutaneous) doses of omalizumab ($n = 16$) or placebo ($n = 8$) based on standard dosing guidelines (based on serum IgE level and body mass). Omalizumab treatment was associated with a significant decrease in total nasal endoscopic polyp scores after 16 weeks compared with placebo. This decrease was confirmed by sinus CT scoring (Lund-Mackay score) and was irrespective of the presence of allergy. Omalizumab also alleviated airway symptoms (nasal congestion, anterior rhinorrhea, loss of sense of smell, wheezing, and dyspnea) and QOL scores. It should be considered after failure of medical and surgical treatment.

## Surgical treatment of rhinosinusitis

Summary Statement 36: Consider antral puncture and irrigation in the management of acute ethmomaxillary rhinosinusitis

**Table 8**
Indications for referral to a specialist (allergist and/or otolaryngologist)

| |
|---|
| When the condition or its treatment is interfering with a patient's performance or causing significant loss of school or work on a long-term or recurrent basis or when the patient's quality of life is significantly affected |
| When there are significant comorbidities of rhinosinusitis, such as otitis, asthma, bronchiectasis, nasal polyps, or bronchitis |
| When there are complications of acute rhinosinusitis, such as orbital cellulitis or orbital abscess and/or brain abscess |
| When there is consideration for an allergic or immunologic basis for rhinosinusitis or when immunocompetence needs to be assessed |
| When the condition becomes chronic, persists for several months, or recurs 2 to 3 times per year, despite treatment by primary care physician |
| When there is the need for complex pharmacology to treat recalcitrant infections caused by underlying allergies, allergic fungal rhinosinusitis, or resistant pathogens or for treatment of aspirin-exacerbated respiratory disease |

**Table 9**
What the specialist should provide to the referring physician

| |
|---|
| Clarification of allergic, immunologic, or nonallergic causative basis for patient's condition |
| Assessment of nasal and sinus outflow tract anatomy, evaluation for persistent inflammation, and assessment of the contribution of these factors in the causation of rhinosinusitis |
| Assistance in developing an effective treatment plan, including patient education, allergen avoidance, pharmacotherapy, anti-infectious therapy, and immunotherapy |
| Evaluation for associated conditions, such as asthma and immunodeficiency |
| Surgical treatment by otolaryngologist if medical therapy fails |

refractory to medical therapy or in ABRS in an immunosuppressed patient in whom early identification of pathogenic organisms is paramount. (Rec, D)

Summary Statement 37: Consider ostial dilatation with a balloon in a small sub-segment of patients with medically unresponsive ABRS, especially those with early or localized disease. (Rec, D)

Summary Statement 38: Endoscopic surgical intervention is required in ABRS to provide drainage when there is a significant risk of intracranial complication or in a patient with visual compromise or periorbital or intraorbital abscess. (Rec, C)

Summary Statement 39: Consider endoscopic surgical intervention as an adjunct to medical treatment in patients with CRS that is poorly responsive to medical therapy. (Rec, C)

The surgical approach to sinus disease underwent a significant change in the latter part of the 20th century as a result of the widespread use of nasal endoscopy, improved imaging, and renewed insights into sinus physiology and pathophysiology. The middle meatus and the ethmoid sinuses were recognized as important factors in the persistence of frontal and maxillary sinusitis.[375] This region was termed the *ostiomeatal complex* in recognition of the importance of this drainage area to disease in the dependent sinuses.[30,376]

Current knowledge continues to indicate that limited and localized inflammation within the ostiomeatal complex may cause or exacerbate disease within the dependent sinuses.[377] There is also evidence that the underlying bone may become involved in the area of disease and that the inflammation may spread through the bone to adjacent areas. This bone involvement may explain why medical therapy alone may not resolve CRS in some patients and why surgical intervention is sometimes required. Surgery also provides access for topical therapy aimed at the bacterial biofilms that have been implicated in the persistence of CRS.[378,379]

Thus, surgical therapy is typically directed toward removing mucosal disease and the involved bone within the ethmoid sinuses and sinus ostia under endoscopic visualization (FESS). During surgery, significant attention should be paid to mucoperiosteal preservation and the avoidance of bone exposure to minimize the risk of delayed healing and improve ciliary regeneration.[380]

After surgical intervention, most patients with bacterial rhinosinusitis have marked improvements in disease-specific symptoms.[381] However, frequently, endoscopic and radiologic evidence of asymptomatic disease persists, requiring local debridement and continued long-term medical therapy.[382] Eventually, with proper ventilation and appropriate local and systemic therapy, residual endoscopic evidence of chronic inflammation seems to slowly resolve in many patients.[383] Such local therapy may include saline nasal irrigations, steroid or antibiotic nasal irrigations, or, more recently, the use of steroid-eluting stents, which slowly release topical nasal steroids within the cavity over time.[384,385]

## Evaluation for surgery

### *Acute bacterial rhinosinusitis*

In ABRS the necessity for surgery is usually predicated by a threatened complication or by symptoms unresponsive to medical therapy.

### *Chronic rhinosinusitis*

In CRS, patient evaluation should include a careful history and evaluation for environmental and general host factors that might predispose to rhinosinusitis, in addition to evaluation of the local host factors within the sinuses and ostiomeatal complex. There also should be demonstrated failure to resolve on medical therapy. It is important that patients with environmental allergies and environmental exposures have these controlled in conjunction with surgical intervention whenever this is possible. Surgical intervention exposes virgin mucosa to nasal airflow and thus potentially allows initiation of the inflammatory process at a new site. Although there has been some controversy about the influence of continued smoking after surgical intervention, at least 1 study has indicated that this is a major factor in persistent disease.[386]

Surgery is typically required for fungal rhinosinusitis. Fungus balls, typically within the maxillary or sphenoid sinuses, AFRS, and invasive fungal sinusitis generally require surgical intervention. Because the radiographic and endoscopic appearance of unilateral polypoid disease may frequently be the result of fungal disease or tumor (eg, inverted papilloma), biopsy examination should be considered in these patients. Rhinosinusitis of dental origin also typically presents as unilateral disease.[387] Such patients typically require endoscopic surgical intervention for sinus drainage and management of the underlying dental cause, typically an apical abscess or infected dental implant, for resolution of the disease.

### *Surgical approaches*

Endoscopic approaches have generally become the surgical standard of care for CRS. However, open surgical procedures may still be required in rare situations. Given the markedly improved safety of general anesthesia and rapid recovery after total intravenous anesthesia, endoscopic sinus surgery is typically performed

**Table 10**
Indications for surgical intervention

| |
|---|
| When nasal polyps obstruct sinus drainage or cause significant nasal congestion and persist despite appropriate medical treatment |
| When there is recurrent or persistent infectious rhinosinusitis despite adequate trials of medical management that at least includes topical nasal steroids and nasal irrigations; in many cases, ≥1 course of antibiotics is required, chosen to cover the spectrum of pathogens anticipated to be causing the disease, and a course of oral steroids may be considered if there is no contraindication |
| For biopsy of sinonasal tissue to rule out granulomatous disease, neoplasm, ciliary dyskinesia, or fungal infections |
| When maxillary antral puncture is required (eg, as for culture-directed therapy) |
| When anatomic defects obstruct the sinus outflow tract, particularly the ostiomeatal complex (and adenoidal tissues in children) |
| For rhinosinusitis with threatened complications (eg, threat of brain abscess, meningitis, cavernous sinus thrombosis, or frontal bone osteomyelitis) |

under total intravenous anesthesia, although local anesthesia is a viable alternative.[7]

In part, the migration toward general anesthesia also has been spurred as a result of the recognition of the importance of carefully removing disease and meticulously preserving the mucoperiosteum, thus increasing the length of carefully performed surgical procedures. In most cases, surgery is performed on an outpatient basis, but patients with significant underlying medical conditions may require overnight observation. Endoscopic surgical procedures are carried out through the nostril under endoscopic visualization and do not involve external incisions. The extent of the surgical dissection is dictated by the amount and location of disease identified by preoperative sinus CT and by findings during the surgical procedure. There are different opinions regarding the extent of surgery that should be performed, ranging from a very minimal procedure or balloon dilatation of the affected ostia, to very complete opening of all the sinuses. However, the standard teaching for the functional endoscopic approach is that the surgical procedure should extend beyond the margins of the ostiomeatal disease and the inflamed boney partitions should be removed. Although symptomatic improvement from balloon dilation has been well documented, in general, patients selected for this approach have only minor disease, a significant proportion of which might be amenable to medical therapy alone. Conclusions regarding long-term resolution of disease with minimal interventional approaches remain unproved. With endoscopic sinus surgery, postoperative pain after surgery is typically minimal, and early symptom improvement is generally the rule. The incidence of severe surgical complications is 0.1% to 0.5%.[388] However, poorly performed surgery or inadequate postsurgical follow-up and medical therapy may result in worsened symptoms, persistent inflammation, or even "empty nose syndrome." The meticulous surgical techniques used in endoscopic sinus surgery require considerable experience.

The surgical treatment of rhinosinusitis has been significantly enhanced by the routine use of nasal endoscopy and by the use of CT imaging and the 2 modalities are complimentary in diagnostic evaluation. Although CRS is typically a multifactorial disease with environmental and general host factors, localized persistent disease within the ostiomeatal complex plays a significant part in continuation of the disease process.

There are very few studies comparing medical vs surgical therapy. A Cochrane database review from 2006 concluded that, based on the few studies that were available, FESS could not be considered superior to medical therapy.[389] Although limited in number, randomized studies that have compared surgery with medical treatment in CRS have shown that the 2 therapies offer significant improvement. A recent multicenter study concluded that surgery provides longer-lasting and superior QOL compared with medical therapy.[294,390.391] Therefore, although medical therapy is the mainstay of disease management, FESS should be considered when medical therapy fails. Properly conducted, sinus surgery can result in significant improvement in the large majority of patients, and long-term follow-up after surgery has shown significantly improved overall QOL, decreased medication requirements, and alleviation of sinonasal symptoms and asthma. However, appropriate surgical intervention requires a combination of surgery, local postoperative care, and topical and systemic medical management. In addition to removing inflamed tissue and improving sinus drainage, surgery provides access for topical therapies to control the inflammatory cascade.

Balloon dilatation of the sinuses in very select cases may be a valid alternative to medical or other forms of surgical intervention. Balloon catheter technology has been validated in multiple proof-of-concept studies as a feasible means to dilate sinus ostia, with improvement in subjective and objective measurements of disease compared with pretreatment baseline. These have been elaborated in a recent review.[392] However, it remains debatable whether balloon sinus ostial dilation is efficacious as an alternative to traditional FESS. One RCT of 32 patients, ostensibly designed to evaluate efficacy of balloon dilation of the frontal sinuses, suggested a slight advantage of balloon dilation of the frontal ostium compared with classic FESS.[393] These findings did not achieve statistical significance. A major limitation of this study is that more half the frontal sinuses in the FESS group underwent a Draf I procedure, which is a procedure that does not deliberately address the frontal ostium.[393] An Austrian study prospectively compared balloon sinuplasty alone with a hybrid procedure.[394] The investigators observed a failure rate of 65% for balloon-only and of 66% for hybrid procedures, leading them to terminate the study at 45 patients and to doubt the utility of the balloon as stand-alone therapy or as a part of conventional FESS.[394] Case–control studies comparing balloon sinuplasty with FESS suggested that there might be benefit to FESS in patients with CRS-related comorbidities or ongoing occupational exposure. Those in the balloon group also required larger numbers of antibiotic courses and office interventions during a 12 month follow-up.[395] In summary, balloon catheter technology has been shown as a safe method to dilate sinus ostia but no studies to date can conclude an advantage over FESS.

Recent trends have included the use of drug-eluting stents after FESS. The hypothesis behind this approach is that moderate local concentrations of steroid introduced into the healing milieu will promote more optimal healing patterns and suppress recurrence of inflammatory disease.[320] Meta-analysis of 2 prospective randomized placebo-controlled multicenter trials using a stent that eluted mometasone over 30 days showed a 51% decrease in postoperative lysis of adhesions ($P = .0016$) and a 40% decrease in oral steroid needs ($P = .0023$) compared with controls. Also, a 46% relative decrease in frank polyposis was observed with the mometasone-eluting stents compared with controls ($P < .0001$).[385,396,397] It is notable that the series (n = 143) included a broad base of patients among whom more than one fourth had previous sinus surgery and more than half had nasal polyposis. One limitation of these data is that follow-up was carried out for months only. Although there is some decrease in need for oral steroids after the introduction of steroid-eluting stents, further investigation is necessary to elucidate whether local application of topical steroid influences long-term outcomes over years after FESS. Safety also has been assessed for the steroid-eluting stents. Prospective studies after implantation of the stents have not found elevation in intraocular pressures, increase in cataract risk, or adrenal cortical suppression.[384,396,397]

Tables 8 and 9 list indications for referral to a specialist treating sinus disease and how the specialist can assist the referring physician. Table 10 lists indications for surgical interventions.

## Pediatric rhinosinusitis

The presentation and diagnosis of rhinosinusitis in children is described and detailed alongside the description of the same sections in adults in this practice parameter. It is noteworthy to point out some characteristics of pediatric disease that are slightly different from those in adults. As to symptoms, cough is a prominent symptom of rhinosinusitis in children and rhinosinusitis is always considered in the differential diagnosis of a child with cough (acute or chronic). The frequency of URTIs in children (especially those in daycare) is higher than that in adults and therefore has a greater impact on rhinosinusitis in children. Related to the physical examination, some younger children might not tolerate nasal endoscopy, and clinicians are sometimes hindered in their physical examination and have to rely on history and or imaging studies for appropriate diagnosis. Unilateral nasal drainage in children should alert the clinician to the possible differential diagnosis of unilateral choanal atresia and nasal foreign body. Nasal polyps are not as

common in children as they are in adults and usually represent underlying CF, AFRS, or antrochoanal polyps. Adenoids, present in children and rarely present in adults, play an important role in the diagnosis and presentation and in the management of rhinosinusitis in children. Infection of the adenoids (ie, adenoiditis) presents with symptoms similar to those of rhinosinusitis in children and it is often difficult to distinguish the 2 entities based solely on symptoms and physical examination. It has been suggested that only a Lund-Mackay score above 5 is indicative for CRS in children.[398] The Lund-Mackay scoring system stages sinus disease based on the severity observed on a sinus CT scan.[399]

## Medical treatment of pediatric rhinosinusitis

Summary Statement 40: Realize that ARS in children is a self-limited process in most cases and treatment with antibiotics seems to accelerate resolution. (Rec, A)

Summary Statement 41: Use an INS as a potentially useful adjunct to antibiotics in the treatment of ARS in children. (StrRec, A)

Summary Statement 42: Realize that ancillary therapy in the form of nasal irrigations, antihistamines, decongestants, or mucolytics has not been shown to be helpful in the treatment of ARS in children. (Opt, D)

Summary Statement 43: Realize that there are limited data to justify the use of oral antibiotics for the treatment of CRS in children. (Opt, C)

Summary Statement 44: Consider use of antibiotic therapy in acute exacerbations of CRS. (Rec, C)

Summary Statement 45: Use INS in the treatment of CRS in children. (Rec, C)

## Acute bacterial rhinosinusitis

### *Antibiotics*

Antibiotics are the most frequently used therapeutic agents in ABRS. Published trials in children and adults were reviewed in a recent meta-analysis of RCTs in which 3 of the 17 evaluated studies were performed in the pediatric age group.[400] In total, 3,291 outpatients (2,915 adults and 376 children) were treated in the trials included. The diagnosis of ABRS in the trials was based on clinical criteria in most studies and radiologic and other laboratory criteria in the rest. In most studies, inclusion of patients with viral URTIS was avoided by enrolling patients whose symptoms were longer than 7 to 10 days in duration. The results suggested that, compared with placebo, antibiotics were associated with a higher rate of cure or improvement within 7 to 15 days, with the rate of resolution of symptoms being faster with antibiotics in most RCTs. The overall positive effect in favor of antibiotics was significant but modest. No difference in cure was found when a subgroup analysis was performed for age. A more recent randomized, placebo-controlled trial evaluated the efficacy of amoxicillin (90 mg/kg) and clavulanate or placebo in children 1 to 10 years of age with a clinical presentation compatible with ABRS (persistent symptoms, acutely worsening symptoms, or severe symptoms).[401] Symptom scores were obtained at multiple time points and the children were evaluated at day 14 from onset of treatment and their condition was rated as cured, improved, or failed. Twenty-eight patients in each group completed the study and their average age was approximately 5 years. Children receiving the antibiotic were more likely to be cured (50% vs 14%, $P = .01$) and less likely to experience treatment failure (14% vs 68%, $P < .001$) than children receiving placebo. Similar to other studies, there were more side effects in the antibiotic-treated group compared with placebo treatment (44% vs 14% of children, $P = .014$). In another RCT in patients 1 to 15 years of age with clinical and radiographic signs and symptoms of ABRS, patients received a cephalosporin (8–12 mg/kg of cefditoren daily) or amoxicillin-clavulanate (80–90 mg/kg of amoxicillin daily) for 14 days.[402] The results showed comparable rates of improvement at 14 days: 78.8% for cefditoren and 84.7% for amoxicillin-clavulanate. The median time to improvement was 3 days in the 2 groups and the rate of diarrhea was significantly higher in the patients treated with amoxicillin-clavulanate (18%) compared with those treated with cefditoren (4.5%).

Most of these studies could be criticized for potentially including patients with ongoing viral URIs and selecting patients based on clinical symptoms and examination only, without radiologic documentation. However, the results suggest that most cases of uncomplicated ABRS will improve irrespective of treatment used but will do so faster and will have a better chance of improvement if given antibiotics. Antibiotic therapy would be reserved for children with complications or concomitant disease that could be exacerbated by ABRS (asthma, chronic bronchitis). In some situations, children with purulent rhinorrhea are prevented from staying in daycare and thus have created problems for working parents. Whether an acceleration of improvement of symptoms with antibiotics in these children is worth the increased risk of antimicrobial resistance remains to be determined.

When considering antibiotic choices, uncomplicated ABRS in a child who has not received multiple previous courses of antibiotics can still be treated with amoxicillin (45 or 80 mg/kg daily).[264] Another reasonable and safe choice is amoxicillin-clavulanate, which provides good coverage of typical organisms, especially those producing $\beta$-lactamase. As the likelihood that the prevalence of *H influenzae* has increased in children with ABRS, amoxicillin clavulanate is the preferred treatment. If hypersensitivity to any of these antimicrobials is suspected, alternative choices include quinolones or clindamycin or linezolid with a second or third generation cephalosporins (for those with late or delayed >72-hour non–type I reaction to amoxicillin).[264,403,404] As mentioned earlier, penicillin skin testing may be considered in patients with $\beta$-lactam allergy if $\beta$-lactams are the most appropriate antibiotic. Clindamycin is useful if anaerobic organisms are suspected but provides no coverage against gram-negative organisms.

### *Intranasal steroids*

In a pediatric trial, 89 children with ABRS received amoxicillin-clavulanate and were randomized to receive budesonide or placebo nasal sprays for 3 weeks.[271] There were significant improvements in the scores of cough and nasal discharge at the end of the second week in the steroid group compared with placebo, suggesting a benefit of adding INSs to antibiotics in the treatment of ABRS. Several trials in mixed adult and pediatric populations (usually 12–14 years and older) have shown similar benefits of using an INS with an antibiotic for the treatment of ABRS.[405,406] Therefore, there is reasonable evidence to support the addition of an INS to antibiotics in the treatment of ABRS. In a randomized, placebo-controlled trial in patients older than 12 years with ABRS, 200 $\mu$g of mometasone twice daily (twice the allergic rhinitis dose) was more effective in controlling symptoms than placebo and amoxicillin.[266] Thus, there is also some evidence that a high dose of INSs in older children might be effective as monotherapy for ABRS. However, generalizing to younger children is not justified in the absence of more studies.

### *Ancillary therapy*

A systematic review of the literature was undertaken to evaluate the efficacy of decongestants (oral or intranasal), antihistamines, and nasal irrigation in children with clinically diagnosed acute sinusitis.[407] RCTs that evaluated children 0 to 18 years of age with ABRS, defined as 10 to 30 days of rhinorrhea, congestion, or daytime

cough, were included. Of 402 articles reviewed, 44 references were retrieved and all were excluded because they did not satisfy the set criteria. The investigators concluded that there is no evidence to determine whether the use of these agents is efficacious in children with ABRS. In a more recent publication, erdosteine, a mucolytic agent, was investigated in a randomized, placebo-controlled trial.[408] Eighty-one patients completed the study (average age 8.5 years) and all had symptoms consistent with ABRS. The 2 treatment groups had an alleviation in symptoms on day 14 of treatment, with no statistically significant differences between the active and placebo groups. Therefore, there is really no good evidence to support the use of ancillary therapies in the treatment of ABRS in children.

## Chronic rhinosinusitis

### *Antibiotics*

There is no good evidence in the literature to support the use of antibiotics for the treatment of CRS in children. Otten and Grote[409] investigated 141 children 3 to 10 years of age with CRS as defined by purulent nasal drainage lasting at least 3 months, signs of purulent rhinitis at rhinoscopy, and unilateral or bilateral abnormalities of the maxillary sinus on plain films. The patients were assigned nonselectively to receive 1 of the following 4 treatments for 10 days: saline nose drops (placebo), xylometazoline 0.5% nose drops with 250 mg of amoxicillin orally 3 times daily, drainage of the maxillary sinus under anesthesia and irrigation through an indwelling catheter for at least 5 days, and a combination of drainage and irrigation with xylometazoline and amoxicillin. They followed the patients for up to 26 weeks after treatment and found no significant differences in cure rate among the treatments based on history, physical examination, or maxillary sinus films. In the total group, the cure rate was approximately 69%. Although this study did not show a significant difference among treatments, it has some methodologic limitations, including lack of randomization or blinding, and that the placebo group actually received saline, which alone might have been helpful. Further, this study did not assess the state of the ethmoid sinuses and used plain x-rays as the objective diagnostic modality. In a later study, the same group performed a randomized, double-blinded study of cefaclor (20 mg/kg daily) vs placebo in 79 healthy children 2 to 12 years old with CRS defined essentially as in the first study.[410] All patients had a maxillary sinus tap and washout and were randomized to cefaclor or placebo orally for 1 week and were followed at 6 weeks. After 6 weeks, there was no significant difference in resolution rate between the children on cefaclor (64.8%) and those on placebo (52.5%). Among the limitations of this study that could have influenced the outcome is that all children had an initial tap and washout, which could have helped the entire group even before enrollment, making the antibiotic irrelevant, and plain radiographs were used to evaluate the sinuses.

Despite the lack of good evidence to support the use of antibiotics for any length of time in children with CRS, in practice, these children are often treated with the same antibiotics listed in the section on ARS but typically for longer periods that vary from 3 to 6 weeks. Because of the lack of data to support this practice, its usefulness must be weighed against the increasing risks of inducing antimicrobial resistance. Moreover, it is difficult to ascertain whether what is actually being treated is CRS or acute exacerbations on top of pre-existing chronic disease. The exact type of antibiotics used is usually dependent on local resistance patterns, which might be different in different countries. Further, it is advisable to always treat with as narrow a spectrum of antibiotics as will likely cover the bacteria that are prevalent in a specific geographic locale.

Intravenous antibiotic therapy for CRS resistant to maximal medical treatment has been studied as an alternative to endoscopic sinus surgery. In a retrospective analysis of 70 children 10 months to 15 years old with CRS, Don et al[411] found that 89% had complete resolution of symptoms after maxillary sinus irrigation and selective adenoidectomy followed by 1 to 4 weeks of culture-directed intravenous antibiotics. Cefuroxime (intravenous) was most frequently used followed by ampicillin-sulbactam, ticarcillin clavulanate, and vancomycin. Despite the good success rate, the therapy was not without adverse effects, which included superficial thrombophlebitis (9%), dislodgment of wire during placement necessitating venotomy (1%), and antibiotic-related complications such as serum sickness, pseudomembranous colitis, and drug fevers. A similar retrospective study evaluated 22 children with CRS refractory to medical therapy and with an age range from 1.25 to 14.5 years.[154] All underwent adenoidectomy, maxillary sinus aspiration and irrigation, and placement of intravenous catheters and then culture-directed intravenous antibiotic therapy until resolution of symptoms (mean duration of therapy 5 weeks). All patients achieved control of symptoms at the end of intravenous therapy and 89% showed long-term amelioration of CRS symptoms (>12 months after cessation of intravenous therapy). The retrospective design, lack of randomization, and lack of placebo arms limit the value of these studies. Furthermore, it is difficult to assign benefit to intravenous antibiotic therapy when other interventions were used, such as irrigation and aspiration of the sinus and adenoidectomy.

### *Steroids*

There are no RCTs evaluating the effect of INSs in children with CRS. However, the combination of proven efficacy of INSs in CRS with and without nasal polyps in adults and proven efficacy and safety of INSs in AR in children makes INSs a reasonable and safe choice for treatment of CRS.[412–414] A recent randomized, placebo-controlled, double-blinded trial was conducted in children with CRS with signs and symptoms longer than 3 months in duration and CT abnormalities.[309] All children were treated with amoxicillin-clavulanate for 30 days and were randomized to receive methylprednisolone or placebo orally for first 15 days of treatment (1 mg/kg daily [maximum 40 mg] for 10 days, 0.75 mg/kg daily for 2 days, 0.5 mg/kg daily for 2 days, and 0.25 mg/kg daily for 1 day). The average age of the children was 8 years and the total CT score was 11 to 12 (maximal score 24), suggesting mild to moderate disease. When comparing post-treatment outcomes with baseline, there were significant improvements in all parameters (symptoms and CT scores) in the 2 groups, suggesting that antibiotics alone and antibiotics and steroids together improved outcomes compared with baseline. Furthermore, there was a significant additional effect of oral steroids over placebo on cough, CT scan, nasal obstruction, postnasal drainage, and total symptom scores. The strength of the evidence for the efficacy of antibiotics alone is unfortunately diminished by the absence of a placebo group, but the superiority of the combination of antibiotics and steroids over antibiotics alone is clearly supported by this trial.

### *Ancillary therapy*

Nasal irrigations and decongestants have been thought to help in decreasing the frequency of rhinosinusitis episodes. Michel et al[415] in 2005 performed a randomized, prospective, double-blinded, controlled study looking at the effect of a 14-day treatment (1–2 sprays) with isotonic saline solution or a nasal decongestant in children 2 to 6 years of age. Outcomes evaluated included the degree of mucosal inflammation and nasal patency. They found that the 2 groups showed improvement in outcomes measured with no significant differences between groups. There were no side effects observed with the saline spray. The decongestant group used 120% more drug than prescribed, showing the potential for these medications to be overused. No cases of rhinitis medicamentosa were reported.

A recent Cochrane review analyzed RCTs in which saline was evaluated in comparison with no treatment, a placebo, as an adjunct to other treatments, or against other treatments.[338] Eight trials satisfied the inclusion criteria, of which 3 were conducted in children. The studies included a broad range of delivery techniques, tonicity of saline used, and comparator treatments. Overall there was evidence that saline is beneficial in the treatment of the symptoms of CRS when used as the sole modality of treatment. Various forms of administration of saline were well tolerated. In a more recent trial, Wei et al[337] enrolled 40 children with CRS in a randomized, prospective, double-blinded study comparing once-daily irrigation with saline with saline and gentamicin for 6 weeks. There were statistically significant improvements in QOL scores after 3 weeks and a decrease of CT scores after 6 weeks in the 2 groups, with no significant difference between groups, suggesting that the addition of gentamycin to saline irrigations provided no additional benefit.

Clinicians have certainly tried other treatments for CRS, including antihistamines and leukotriene modifiers, especially in light of their effectiveness in treating AR. However, no data exist about their potential efficacy and thus usefulness in the context of CRS in children.

## Surgical treatment of rhinosinusitis in children

Summary Statement 46: Realize that surgery is used much less frequently in the management of CRS in children compared with adults and that the mainstay of therapy is medical. (Rec, C)

Summary Statement 47: Consider adenoidectomy with or without maxillary sinus irrigation as the first-line surgical therapy in children with CRS. (Rec, C)

### *Acute bacterial rhinosinusitis*

Surgery for ABRS in children is indicated only in cases of associated complications, such as orbital cellulitis or abscess and brain abscess.

### *Chronic rhinosinusitis*

Surgical intervention for rhinosinusitis is usually considered for patients with CRS whose maximal medical therapy has failed. This is difficult to define but usually includes a course of antibiotics and intranasal and/or systemic steroids and differs widely between practitioners and practice locations. Adenoidectomy with or without antral irrigation, balloon sinus dilation, and FESS are the most commonly used modalities.

#### *Adenoidectomy with or without sinus irrigation and balloon dilation*

The rationale behind removal of the adenoids in patients with CRS stems from the hypothesis that the adenoids are a nasopharyngeal bacterial reservoir and the possibility that many of the symptoms might be related to adenoiditis proper. The benefit of adenoidectomy alone in the treatment of children with CRS was recently evaluated by a meta-analysis.[416] The review included 9 studies that met the inclusion criteria. Mean sample size was 46 subjects with a mean age of 5.8 years (range 4.4–6.9 years). All studies showed that sinusitis symptoms or outcomes improved in at least half the patients after adenoidectomy. Eight of 9 studies were sufficiently similar to undergo meta-analysis and, in these, the summary estimate of the proportion of patients who showed significant improvement after adenoidectomy was 69.3%. Ramadan and Tiu[417] reported on the failures of adenoidectomy over a 10-year period and found that children younger than 7 years and those with asthma were more likely to have failed adenoidectomy and go on to require salvage FESS.

Maxillary antral irrigation is frequently performed in conjunction with adenoidectomy. To evaluate the efficacy of this added intervention, Ramadan and Cost[418] analyzed 60 children who underwent adenoidectomy for CRS (symptoms and positive scans despite prolonged medical treatment), 32 of which also had a sinus wash and culture through the middle meatus. All children received postoperative antibiotics for 2 weeks and outcomes were assessed at least 12 months postoperatively. Patients who underwent adenoidectomy alone had a 61% success rate at 12 months compared with children who underwent adenoidectomy with a sinus wash who had a higher success rate of 88%. Children with a high Lund-Mackay CT score and asthma had better success with adenoidectomy with a wash compared with adenoidectomy alone. In a similar retrospective study, Criddle et al[155] reviewed the records of 23 children who had adenoidectomy with a sinus wash for CRS (persistent symptoms in all and a positive scan in 7 of 23) followed by a course of postoperative oral antibiotics (average duration 5.8 weeks). If there was no improvement after the procedure on oral antibiotics, intravenous antibiotics were used in a small proportion of the children. Long-term resolution rate was reported in 78% of the 18 patients who did not need intravenous antibiotics. These data suggest that antral irrigation adds to the efficacy of adenoidectomy and suggests that a prolonged course of intravenous antibiotics (as reported earlier) might not be necessary to obtain a good result.

Balloon sinuplasty was approved by the FDA for use in children in the United States in 2006, and a preliminary study in children has shown the procedure to be safe and feasible.[419] Most surgeons currently use the illuminated catheter to confirm cannulation of the sinus, thus avoiding fluoroscopy and its inherent risks. In a recent nonrandomized, prospective evaluation of children with CRS whose maximal medical therapy failed, balloon catheter sinuplasty and adenoidectomy were compared.[420] Outcomes were assessed at 1 year after surgery and were based on Sinonasal-5 quality of life scores and the need for revision surgery. Twenty-four of 30 patients (80%) who underwent balloon sinuplasty showed alleviation of their symptoms compared with 10 of 19 patients (52.6%) who underwent adenoidectomy ($P < .05$). Because some of the patients who underwent balloon sinuplasty also underwent irrigation, it is difficult to discern the effect of dilation vs irrigation from this study. In summary, most of the available surgical data support adenoidectomy with sinus irrigation as a first step in the management of a child with CRS refractory to maximal medical management. Whether balloon maxillary sinuplasty imparts additional benefit to irrigation alone or in combination with adenoidectomy cannot be established with the currently available data.

#### *Functional endoscopic sinus surgery*

A meta-analysis of FESS results in the pediatric population has shown that this surgical modality is effective in alleviating symptoms, with an 88% success rate and a low complication rate.[421] Initial concerns about possible adverse effects of FESS on facial growth have been allayed by a long-term follow-up study by Bothwell et al[422] that showed no impact of FESS on qualitative and quantitative parameters of pediatric facial growth evaluated up to 10 years postoperatively. Many have advocated a limited approach to FESS in children, consisting of removal of any obvious obstruction (such as polyps and concha bullosa) and anterior bulla ethmoidectomy and maxillary antrostomy. This approach typically has yielded significant improvements in nasal obstruction (91%), rhinorrhea (90%), post nasal drainage (90%), headache (97%), hyposmia (89%), and chronic cough (96%).[423]

In summary, the most supported surgical approach to the child with CRS whose maximal medical therapy has failed probably consists of an initial attempt at an adenoidectomy with a maxillary sinus

wash with or without balloon dilation followed by FESS in case of recurrence of symptoms. An exception to this statement are children with CF, nasal polyposis, antrochoanal polyposis, or AFRS, when FESS to decrease disease burden is the initial favored surgical option.

## References


[1] Pleis JR, Ward BW, Lucas JW. Summary health statistics for U.S. adults: National Health Interview Survey, 2009. *Vital Health Stat 10*. 2010:1–207. III.
[2] Bhattacharyya N. Incremental health care utilization and expenditures for chronic rhinosinusitis in the United States. *Ann Otol Rhinol Laryngol*. 2011;120:423–427. III.
[3] Rosenfeld RM, Andes D, Bhattacharyya N, et al. Clinical practice guideline: adult sinusitis. *Otolaryngol Head Neck Surg*. 2007;137(suppl):S1–S31. IV.
[4] Smith SS, Evans CT, Tan BK, Chandra RK, Smith RB, Kern RC. National burden of antibiotic use for adult rhinosinusitis. *J Allergy Clin Immunol*. 2013;132:1230–1232. III.
[5] Bhattacharyya N. Functional limitations and workdays lost associated with chronic rhinosinusitis and allergic rhinitis. *Am J Rhinol Allergy*. 2012;26:120–122. III.
[6] Gliklich RE, Metson R. The health impact of chronic sinusitis in patients seeking otolaryngologic care. *Otolaryngol Head Neck Surg*. 1995;113:104–109. III.
[7] Slavin RG, Spector SL, Bernstein IL, et al. The diagnosis and management of sinusitis: a practice parameter update. *J Allergy Clin Immunol*. 2005;116(suppl):S13–S47. IV.
[8] Spector SL, Bernstein IL, Li JT, et al. Parameters for the diagnosis and management of sinusitis. *J Allergy Clin Immunol*. 1998;102:S107–S144. IV.
[9] Savolainen S. Allergy in patients with acute maxillary sinusitis. *Allergy*. 1989;44:116–122. IIb.
[10] Van Dishoeck HA, Franssen MG. The incidence and correlation of allergy and chronic maxillary sinusitis. *Pract Otorhinolaryngol (Basel)*. 1957;19:502–506. IIb.
[11] Pearlman AN, Chandra RK, Chang D, et al. Relationships between severity of chronic rhinosinusitis and nasal polyposis, asthma, and atopy. *Am J Rhinol Allergy*. 2009;23:145–148. III.
[12] Emanuel IA, Shah SB. Chronic rhinosinusitis: allergy and sinus computed tomography relationships. *Otolaryngol Head Neck Surg*. 2000;123:687–691. III.
[13] McNally PA, White MV, Kaliner MA. Sinusitis in an allergist's office: analysis of 200 consecutive cases. *Allergy Asthma Proc*. 1997;18:169–175. III.
[14] Lanza DC, Kennedy DW. Adult rhinosinusitis defined. *Otolaryngol Head Neck Surg*. 1997;117:S1–S7. IV.
[15] Kaliner MA, Osguthorpe JD, Fireman P, et al. Sinusitis: bench to bedside. Current findings, future directions. *Otolaryngol Head Neck Surg*. 1997;116:S1–S20. IV.
[16] Meltzer EO, Hamilos DL, Hadley JA, et al. Rhinosinusitis: establishing definitions for clinical research and patient care. *J Allergy Clin Immunol*. 2004;114(suppl):155–212. IV.
[17] Lund VJ, Kennedy DW. Quantification for staging sinusitis. The Staging and Therapy Group. *Ann Otol Rhinol Laryngol Suppl*. 1995;167:17–21. IV.
[18] Wald ER. Chronic sinusitis in children. *J Pediatr*. 1995;127:339–347. IV.
[19] Stankiewicz JA, Chow JM. Nasal endoscopy and the definition and diagnosis of chronic rhinosinusitis. *Otolaryngol Head Neck Surg*. 2002;126:623–627. III.
[20] Zhang N, Van Zele T, Perez-Novo C, et al. Different types of T-effector cells orchestrate mucosal inflammation in chronic sinus disease. *J Allergy Clin Immunol*. 2008;122:961–968. IIb.
[21] Hamilos DL. Chronic sinusitis. *J Allergy Clin Immunol*. 2000;106:213–227. IV.
[22] Asero R, Bottazzi G. Hypersensitivity to molds in patients with nasal polyposis: a clinical study. *J Allergy Clin Immunol*. 2000;105:186–188. IIb.
[23] Spaeth J, Krugelstein U, Schlondorff G. The paranasal sinuses in CT-imaging: development from birth to age 25. *Int J Pediatr Otorhinolaryngol*. 1997;39:25–40. IIb.
[24] Medina J, Hernandez H, Tom LW, Bilaniuk L. Development of the paranasal sinuses in children. *Am J Rhinol*. 1997;11:203–209. IIb.
[25] Zeifer B. Pediatric sinonasal imaging: normal anatomy and inflammatory disease. *Neuroimaging Clin North Am*. 2000;10:137–159. ix. IV.
[26] Nishioka GJ, Cook PR, McKinsey JP, Rodriguez FJ. Paranasal sinus computed tomography scan findings in patients with cystic fibrosis. *Otolaryngol Head Neck Surg*. 1996;114:394–399. IIa.
[27] Woodworth BA, Ahn C, Flume PA, Schlosser RJ. The delta F508 mutation in cystic fibrosis and impact on sinus development. *Am J Rhinol*. 2007;21:122–127. IIb.
[28] Bolger W. Anatomy of the paranasal sinuses. In: Kennedy D, Bolger W, Zinreich SJ, eds. *Diseases of the Sinuses: Diagnosis and Management*. Hamilton, ON, Canada: Decker; 2001:1–22. IV.
[29] Yousem DM, Kennedy DW, Rosenberg S. Ostiomeatal complex risk factors for sinusitis: CT evaluation. *J Otolaryngol*. 1991;20:419–424. IIb.
[30] Kennedy DW, Zinreich SJ, Rosenbaum AE, Johns ME. Functional endoscopic sinus surgery. Theory and diagnostic evaluation. *Arch Otolaryngol*. 1985;111:576–582. IV.
[31] Aust R, Stierna P, Drettner B. Basic experimental studies of ostial patency and local metabolic environment of the maxillary sinus. *Acta Otolaryngol Suppl*. 1994;515:7–10; discussion 1. IIa.
[32] Aust R, Drettner B. Oxygen tension in the human maxillary sinus under normal and pathological conditions. *Acta Otolaryngol*. 1974;78:264–269. IIa.
[33] Aust R, Falck B, Svanholm H. Studies of the gas exchange and pressure in the maxillary sinuses in normal and infected humans. *Rhinology*. 1979;17:245–251. IIa.
[34] Bendouah Z, Barbeau J, Hamad WA, Desrosiers M. Biofilm formation by Staphylococcus aureus and Pseudomonas aeruginosa is associated with an unfavorable evolution after surgery for chronic sinusitis and nasal polyposis. *Otolaryngol Head Neck Surg*. 2006;134:991–996. IIb.
[35] Psaltis AJ, Weitzel EK, Ha KR, Wormald PJ. The effect of bacterial biofilms on post-sinus surgical outcomes. *Am J Rhinol*. 2008;22:1–6. IIb.
[36] Prince AA, Steiger JD, Khalid AN, et al. Prevalence of biofilm-forming bacteria in chronic rhinosinusitis. *Am J Rhinol*. 2008;22:239–245. III.
[37] Foreman A, Holtappels G, Psaltis AJ, et al. Adaptive immune responses in Staphylococcus aureus biofilm-associated chronic rhinosinusitis. *Allergy*. 2011;66:1449–1456. IIa.
[38] Wood AJ, Fraser JD, Swift S, Patterson-Emanuelson EA, Amirapu S, Douglas RG. Intramucosal bacterial microcolonies exist in chronic rhinosinusitis without inducing a local immune response. *Am J Rhinol Allergy*. 2012;26:265–270. IIa.
[39] Costerton JW, Stewart PS, Greenberg EP. Bacterial biofilms: a common cause of persistent infections. *Science*. 1999;284:1318–1322. III.
[40] Cohen M, Kofonow J, Nayak JV, et al. Biofilms in chronic rhinosinusitis: a review. *Am J Rhinol Allergy*. 2009;23:255–260. IV.
[41] Kilty SJ, Desrosiers MY. The role of bacterial biofilms and the pathophysiology of chronic rhinosinusitis. *Curr Allergy Asthma Rep*. 2008;8:227–233. III.
[42] Lee RJ, Xiong G, Kofonow JM, et al. T2R38 taste receptor polymorphisms underlie susceptibility to upper respiratory infection. *J Clin Invest*. 2012;122:4145–4159. IIa.
[43] Adappa ND, Howland TJ, Palmer JN, et al. Genetics of the taste receptor T2R38 correlates with chronic rhinosinusitis necessitating surgical intervention. *Int Forum Allergy Rhinol*. 2013;3:184–187. IIa.
[44] Gwaltney JM Jr. Acute community-acquired sinusitis. *Clin Infect Dis*. 1996;23:1209–1223; quiz 24–25. IV.
[45] DeMuri GP, Wald ER. Clinical practice. Acute bacterial sinusitis in children. *N Engl J Med*. 2012;367:1128–1134. IV.
[46] Hsin CH, Tsao CH, Su MC, Chou MC, Liu CM. Comparison of maxillary sinus puncture with endoscopic middle meatal culture in pediatric rhinosinusitis. *Am J Rhinol*. 2008;22:280–284. IIb.
[47] Gordts F, Abu Nasser I, Clement PA, Pierard D, Kaufman L. Bacteriology of the middle meatus in children. *Int J Pediatr Otorhinolaryngol*. 1999;48:163–167. IIb.
[48] Wald ER. Staphylococcus aureus: is it a pathogen of acute bacterial sinusitis in children and adults? *Clin Infect Dis*. 2012;54:826–831. IV.
[49] Gwaltney JM Jr, Scheld WM, Sande MA, Sydnor A. The microbial etiology and antimicrobial therapy of adults with acute community-acquired sinusitis: a fifteen-year experience at the University of Virginia and review of other selected studies. *J Allergy Clin Immunol*. 1992;90:457–461; discussion 62. III.
[50] Wald ER, Milmoe GJ, Bowen A, Ledesma-Medina J, Salamon N, Bluestone CD. Acute maxillary sinusitis in children. *N Engl J Med*. 1981;304:749–754. III.
[51] Sydnor TA, Kopp EJ, Anthony KE, LoCoco JM, Kim SS, Fowler CL. Open-label assessment of levofloxacin for the treatment of acute bacterial sinusitis in adults. *Ann Allergy Asthma Immunol*. 1998;80:357–362. IIb.
[52] Finegold SM, Flynn MJ, Rose FV, et al. Bacteriologic findings associated with chronic bacterial maxillary sinusitis in adults. *Clin Infect Dis*. 2002;35:428–433. III.
[53] Centers for Disease Control and Prevention. Active Bacterial Core Surveillance Report, Emerging Infections Program Network, *Streptococcus pneumoniae*, 2009. http://www.cdc.gov/abcs/reports-findings/survreports/spneu09.html. Published 2010.
[54] Harrison CJ, Woods C, Stout G, Martin B, Selvarangan R. Susceptibilities of Haemophilus influenzae, Streptococcus pneumoniae, including serotype 19A, and Moraxella catarrhalis paediatric isolates from 2005 to 2007 to commonly used antibiotics. *J Antimicrob Chemother*. 2009;63:511–519. IIb.
[55] Critchley IA, Jacobs MR, Brown SD, Traczewski MM, Tillotson GS, Janjic N. Prevalence of serotype 19A Streptococcus pneumoniae among isolates from U.S. children in 2005–2006 and activity of faropenem. *Antimicrob Agents Chemother*. 2008;52:2639–2643. III.
[56] Effects of new penicillin susceptibility breakpoints for Streptococcus pneumoniae—United States, 2006–2007. *MMWR Morb Mortal Wkly Rep*. 2008;57:1353–1355. IIb.
[57] Jacobs MR, Good CE, Windau AR, et al. Activity of ceftaroline against recent emerging serotypes of Streptococcus pneumoniae in the United States. *Antimicrob Agents Chemother*. 2010;54:2716–2719. IIb.
[58] Tristram S, Jacobs MR, Appelbaum PC. Antimicrobial resistance in Haemophilus influenzae. *Clin Microbiol Rev*. 2007;20:368–389. III.
[59] Brook I. Bacteriology of chronic sinusitis and acute exacerbation of chronic sinusitis. *Arch Otolaryngol Head Neck Surg*. 2006;132:1099–1101. IIb.
[60] Brook I, Foote PA, Hausfeld JN. Increase in the frequency of recovery of methicillin-resistant Staphylococcus aureus in acute and chronic maxillary sinusitis. *J Med Microbiol*. 2008;57:1015–1017. IIb.
[61] Bachert C, Gevaert P, Holtappels G, Johansson SG, van Cauwenberge P. Total and specific IgE in nasal polyps is related to local eosinophilic inflammation. *J Allergy Clin Immunol*. 2001;107:607–614. IIb.
[62] Brook I, Frazier EH. Bacteriology of chronic maxillary sinusitis associated with nasal polyposis. *J Med Microbiol*. 2005;54:595–597. IIb.

[63] Stein M, Caplan ES. Nosocomial sinusitis: a unique subset of sinusitis. *Curr Opin Infect Dis*. 2005;18:147–150. IV.
[64] Vargas F, Bui HN, Boyer A, et al. Transnasal puncture based on echographic sinusitis evidence in mechanically ventilated patients with suspicion of nosocomial maxillary sinusitis. *Intensive Care Med*. 2006;32:858–866. IIb.
[65] Abreu NA, Nagalingam NA, Song Y, et al. Sinus microbiome diversity depletion and Corynebacterium tuberculostearicum enrichment mediates rhinosinusitis. *Sci Transl Med*. 2012;4:151ra124. IIa.
[66] Boase S, Foreman A, Cleland E, et al. The microbiome of chronic rhinosinusitis: culture, molecular diagnostics and biofilm detection. *BMC Infect Dis*. 2013;13:210. IIa.
[67] Feazel LM, Robertson CE, Ramakrishnan VR, Frank DN. Microbiome complexity and Staphylococcus aureus in chronic rhinosinusitis. *Laryngoscope*. 2012;122:467–472. IIa.
[68] deShazo RD. Fungal sinusitis. *Am J Med Sci*. 1998;316:39–45. IV.
[69] Stevens MH. Aspergillosis of the frontal sinus. *Arch Otolaryngol*. 1978;104:153–156. III.
[70] Rizk SS, Kraus DH, Gerresheim G, Mudan S. Aggressive combination treatment for invasive fungal sinusitis in immunocompromised patients. *Ear Nose Throat J*. 2000;79:278–280, 282, 284–285. IV.
[71] Washburn RG. Fungal sinusitis. *Curr Clin Top Infect Dis*. 1998;18:60–74. IV.
[72] Gadosnaki A. Potential interventions for preventing pneumonia among young children: lack of effect of antibiotic treatment for upper respiratory infections. *Pediatr Infect Dis J*. 1993;12:115–120. III.
[73] Lacroix JS, Ricchetti A, Lew D, et al. Symptoms and clinical and radiological signs predicting the presence of pathogenic bacteria in acute rhinosinusitis. *Acta Otolaryngol*. 2002;122:192–196. Ib.
[74] Ray DA, Rohren CH. Characteristics of patients with upper respiratory tract infection presenting to a walk-in clinic. *Mayo Clin Proc*. 2001;76:169–173. III.
[75] Alho OP, Ylitalo K, Jokinen K, et al. The common cold in patients with a history of recurrent sinusitis: increased symptoms and radiologic sinusitis-like findings. *J Fam Pract*. 2001;50:26–31. III.
[76] Fokkens WJ, Lund VJ, Mullol J, et al. European Position Paper on Rhinosinusitis and Nasal Polyps 2012. *Rhinol Suppl*. 2012;(23). 3 p preceding table of contents, 1–298. IV.
[77] Tan BK, Chandra RK, Pollak J, et al. Incidence and associated premorbid diagnoses of patients with chronic rhinosinusitis. *J Allergy Clin Immunol*. 2013;131:1350–1360. IIb.
[78] Perry BF, Login IS, Kountakis SE. Nonrhinologic headache in a tertiary rhinology practice. *Otolaryngol Head Neck Surg*. 2004;130:449–452. III.
[79] Kari E, DelGaudio JM. Treatment of sinus headache as migraine: the diagnostic utility of triptans. *Laryngoscope*. 2008;118:2235–2239. IIb.
[80] Meltzer EO, Hamilos DL. Rhinosinusitis diagnosis and management for the clinician: a synopsis of recent consensus guidelines. *Mayo Clin Proc*. 2011;86:427–443. IV.
[81] Wald ER. Acute otitis media and acute bacterial sinusitis. *Clin Infect Dis*. 2011;52(suppl 4):S277–S283. IV.
[82] Spector SL, Lotan A, English G, Philpot I. Comparison between transillumination and the roentgenogram in diagnosing paranasal sinus disease. *J Allergy Clin Immunol*. 1981;67:22–26. IIa.
[83] Williams JW Jr, Simel DL, Roberts L, Samsa GP. Clinical evaluation for sinusitis. Making the diagnosis by history and physical examination. *Ann Intern Med*. 1992;117:705–710. IIa.
[84] Lancer JM, Jones AS. Flexible fibreoptic rhinolaryngoscopy. Results of 338 consecutive examinations. *J Laryngol Otol*. 1985;99:771–773. III.
[85] Jarvis D, Newson R, Lotvall J, et al. Asthma in adults and its association with chronic rhinosinusitis: the GA2LEN survey in Europe. *Allergy*. 2012;67:91–98. III.
[86] Tritt S, McMains KC, Kountakis SE. Unilateral nasal polyposis: clinical presentation and pathology. *Am J Otolaryngol*. 2008;29:230–232. III.
[87] Som PM, Curtin HD, eds. *Head and Neck Imaging*. 5th ed. ed: St Louis, MO: Mosby Elsevier; 2011. IV.
[88] Fatterpekar GM, Delman BN, Som PM. Imaging the paranasal sinuses: where we are and where we are going. *Anat Rec (Hoboken)*. 2008;291:1564–1572. IV.
[89] Conley D, Pearlman A, Zhou K, Chandra R, Kern R. The role of point-of-care CT in the management of chronic rhinosinusitis: a case-control study. *Ear Nose Throat J*. 2011;90:376–381. IIa.
[90] Stankiewicz JA, Chow JM. A diagnostic dilemma for chronic rhinosinusitis: definition accuracy and validity. *Am J Rhinol*. 2002;16:199–202. IIb.
[91] Bhattacharyya T, Piccirillo J, Wippold FJ II. Relationship between patient-based descriptions of sinusitis and paranasal sinus computed tomographic findings. *Arch Otolaryngol Head Neck Surg*. 1997;123:1189–1192. IIb.
[92] Mafee MF, Tran BH, Chapa AR. Imaging of rhinosinusitis and its complications: plain film, CT, and MRI. *Clin Rev Allergy Immunol*. 2006;30:165–186. IV.
[93] Chen JC, Ho CY. The significance of computed tomographic findings in the diagnosis of fungus ball in the paranasal sinuses. *Am J Rhinol Allergy*. 2012;26:117–119. IIb.
[94] Rao VM, el-Noueam KI. Sinonasal imaging. Anatomy and pathology. *Radiol Clin North Am*. 1998;36:921–939, vi. IV.
[95] Thompson GR III, Patterson TF. Fungal disease of the nose and paranasal sinuses. *J Allergy Clin Immunol*. 2012;129:321–326. IV.
[96] Groppo ER, El-Sayed IH, Aiken AH, Glastonbury CM. Computed tomography and magnetic resonance imaging characteristics of acute invasive fungal sinusitis. *Arch Otolaryngol Head Neck Surg*. 2011;137:1005–1010. IIb.
[97] DelGaudio JM, Swain RE Jr, Kingdom TT, Muller S, Hudgins PA. Computed tomographic findings in patients with invasive fungal sinusitis. *Arch Otolaryngol Head Neck Surg*. 2003;129:236–240. IIb.
[98] Lee TJ, Li SP, Fu CH, et al. Extensive paranasal sinus mucoceles: a 15-year review of 82 cases. *Am J Otolaryngol*. 2009;30:234–238. III.
[99] La Fata V, McLean N, Wise SK, DelGaudio JM, Hudgins PA. CSF leaks: correlation of high-resolution CT and multiplanar reformations with intraoperative endoscopic findings. *AJNR Am J Neuroradiol*. 2008;29:536–541. IIb.
[100] Schell B, Bauer RW, Lehnert T, et al. Low-dose computed tomography of the paranasal sinus and facial skull using a high-pitch dual-source system—first clinical results. *Eur Radiol*. 2011;21:107–112. IIb.
[101] Leung R, Chaung K, Kelly JL, Chandra RK. Advancements in computed tomography management of chronic rhinosinusitis. *Am J Rhinol Allergy*. 2011;25:299–302. III.
[102] Rak KM, Newell JD II, Yakes WF, Damiano MA, Luethke JM. Paranasal sinuses on MR images of the brain: significance of mucosal thickening. *AJR Am J Roentgenol*. 1991;156:381–384. IIb.
[103] Aribandi M, McCoy VA, Bazan C III. Imaging features of invasive and noninvasive fungal sinusitis: a review. *Radiographics*. 2007;27:1283–1296. IV.
[104] Maroldi R, Ravanelli M, Borghesi A, Farina D. Paranasal sinus imaging. *Eur J Radiol*. 2008;66:372–386. IV.
[105] Hamilos DL. Chronic rhinosinusitis: epidemiology and medical management. *J Allergy Clin Immunol*. 2011;128:693–707; quiz 8–9. IV.
[106] Kaliner M. Medical management of sinusitis. *Am J Med Sci*. 1998;316:21–28. IIb.
[107] Gwaltney JM Jr, Phillips CD, Miller RD, Riker DK. Computed tomographic study of the common cold. *N Engl J Med*. 1994;330:25–30. IIb.
[108] Puhakka T, Makela MJ, Alanen A, et al. Sinusitis in the common cold. *J Allergy Clin Immunol*. 1998;102:403–408. IIb.
[109] Scadding GK, Durham SR, Mirakian R, et al. BSACI guidelines for the management of rhinosinusitis and nasal polyposis. *Clin Exp Allergy*. 2008;38:260–275. IV.
[110] Berg O, Carenfelt C, Rystedt G, Anggard A. Occurrence of asymptomatic sinusitis in common cold and other acute ENT-infections. *Rhinology*. 1986;24:223–225. IIb.
[111] Revai K, Dobbs LA, Nair S, Patel JA, Grady JJ, Chonmaitree T. Incidence of acute otitis media and sinusitis complicating upper respiratory tract infection: the effect of age. *Pediatrics*. 2007;119:e1408–e1412. III.
[112] Ramadan HH, Farr RW, Wetmore SJ. Adenovirus and respiratory syncytial virus in chronic sinusitis using polymerase chain reaction. *Laryngoscope*. 1997;107:923–925. IIb.
[113] Jang YJ, Kwon HJ, Park HW, Lee BJ. Detection of rhinovirus in turbinate epithelial cells of chronic sinusitis. *Am J Rhinol*. 2006;20:634–636. III.
[114] Pitkaranta A, Starck M, Savolainen S, et al. Rhinovirus RNA in the maxillary sinus epithelium of adult patients with acute sinusitis. *Clin Infect Dis*. 2001;33:909–911. IIb.
[115] Bellanti JA, Wallerstedt DB. Allergic rhinitis update: epidemiology and natural history. *Allergy Asthma Proc*. 2000;21:367–370. IV.
[116] Rachelefsky GS, Katz RM, Siegel SC. Chronic sinusitis in children with respiratory allergy: the role of antimicrobials. *J Allergy Clin Immunol*. 1982;69:382–387. IIb.
[117] Gosepath J, Pogodsky T, Mann WJ. Characteristics of recurrent chronic rhinosinusitis after previous surgical therapy. *Acta Otolaryngol*. 2008;128:778–784. III.
[118] Houser SM, Keen KJ. The role of allergy and smoking in chronic rhinosinusitis and polyposis. *Laryngoscope*. 2008;118:1521–1527. IIb.
[119] Van Lancker JA, Yarnold PA, Ditto AM, et al. Aeroallergen hypersensitivity: comparing patients with nasal polyps to those with allergic rhinitis. *Allergy Asthma Proc*. 2005;26:109–112. III.
[120] Newman LJ, Platts-Mills TA, Phillips CD, Hazen KC, Gross CW. Chronic sinusitis. Relationship of computed tomographic findings to allergy, asthma, and eosinophilia. *JAMA*. 1994;271:363–367. IIb.
[121] Ramadan HH, Fornelli R, Ortiz AO, Rodman S. Correlation of allergy and severity of sinus disease. *Am J Rhinol*. 1999;13:345–347. IIb.
[122] Tan BK, Zirkle W, Chandra RK, et al. Atopic profile of patients failing medical therapy for chronic rhinosinusitis. *Int Forum Allergy Rhinol*. 2011;1:88–94. IIb.
[123] Lee TJ, Liang CW, Chang PH, Huang CC. Risk factors for protracted sinusitis in pediatrics after endoscopic sinus surgery. *Auris Nasus Larynx*. 2009;36:655–660. IIb.
[124] Lin SY, Reh DD, Navas-Acien A. Allergic rhinitis, chronic rhinosinusitis, and symptom severity: a population-based study. *Int Forum Allergy Rhinol*. 2012;2:51–56. IIb.
[125] Bonfils P, Malinvaud D. Influence of allergy in patients with nasal polyposis after endoscopic sinus surgery. *Acta Otolaryngol*. 2008;128:186–192. III.
[126] Vennera Mdel C, Picado C, Mullol J, Alobid I, Bernal-Sprekelsen M. Efficacy of omalizumab in the treatment of nasal polyps. *Thorax*. 2011;66:824–825. IIb.
[127] Pinto JM, Mehta N, DiTineo M, Wang J, Baroody FM, Naclerio RM. A randomized, double-blind, placebo-controlled trial of anti-IgE for chronic rhinosinusitis. *Rhinology*. 2010;48:318–324. Ib.
[128] Gevaert P, Calus L, Van Zele T, et al. Omalizumab is effective in allergic and nonallergic patients with nasal polyps and asthma. *J Allergy Clin Immunol*. 2013;131:110–116.e1. Ib.
[129] Hutcheson PS, Schubert MS, Slavin RG. Distinctions between allergic fungal rhinosinusitis and chronic rhinosinusitis. *Am J Rhinol Allergy*. 2010;24:405–408. IV.

[130] Campbell JM, Graham M, Gray HC, Bower C, Blaiss MS, Jones SM. Allergic fungal sinusitis in children. *Ann Allergy Asthma Immunol*. 2006;96:286–290. III.
[131] Greenhaw B, deShazo RD, Arnold J, Wright L. Fungal immunotherapy in patients with allergic fungal sinusitis. *Ann Allergy Asthma Immunol*. 2011;107:432–436. III.
[132] Bassichis BA, Marple BF, Mabry RL, Newcomer MT, Schwade ND. Use of immunotherapy in previously treated patients with allergic fungal sinusitis. *Otolaryngol Head Neck Surg*. 2001;125:487–490. III.
[133] Mabry RL, Mabry CS. Immunotherapy for allergic fungal sinusitis: the second year. *Otolaryngol Head Neck Surg*. 1997;117:367–371. III.
[134] Mabry RL, Manning SC, Mabry CS. Immunotherapy in the treatment of allergic fungal sinusitis. *Otolaryngol Head Neck Surg*. 1997;116:31–35. III.
[135] Mabry RL, Marple BF, Folker RJ, Mabry CS. Immunotherapy for allergic fungal sinusitis: three years' experience. *Otolaryngol Head Neck Surg*. 1998;119:648–651. IIb.
[136] Nathan RA, Santilli J, Rockwell W, Glassheim J. Effectiveness of immunotherapy for recurring sinusitis associated with allergic rhinitis as assessed by the Sinusitis Outcomes Questionnaire. *Ann Allergy Asthma Immunol*. 2004;92:668–672. III.
[137] Van Zele T, Claeys S, Gevaert P, et al. Differentiation of chronic sinus diseases by measurement of inflammatory mediators. *Allergy*. 2006;61:1280–1289. IIb.
[138] Settipane RA, Charnock DR. Epidemiology of rhinitis: allergic and nonallergic. *Clin Allergy Immunol*. 2007;19:23–34. III.
[139] Mullarkey MF, Hill JS, Webb DR. Allergic and nonallergic rhinitis: their characterization with attention to the meaning of nasal eosinophilia. *J Allergy Clin Immunol*. 1980;65:122–126. IV.
[140] Bousquet J, Fokkens W, Burney P, et al. Important research questions in allergy and related diseases: nonallergic rhinitis: a GA2LEN paper. *Allergy*. 2008;63:842–853. IV.
[141] Kaliner MA. The treatment of vasomotor nonallergic rhinitis. *Clin Allergy Immunol*. 2007;19:351–362. IV.
[142] Bachert C, van Cauwenberge P, Olbrecht J, van Schoor J. Prevalence, classification and perception of allergic and nonallergic rhinitis in Belgium. *Allergy*. 2006;61:693–698. IIb.
[143] Marinho S, Simpson A, Lowe L, Kissen P, Murray C, Custovic A. Rhinoconjunctivitis in 5-year-old children: a population-based birth cohort study. *Allergy*. 2007;62:385–393. IIb.
[144] Marinho S, Simpson A, Soderstrom L, Woodcock A, Ahlstedt S, Custovic A. Quantification of atopy and the probability of rhinitis in preschool children: a population-based birth cohort study. *Allergy*. 2007;62:1379–1386. IIb.
[145] Brandt D, Bernstein JA. Questionnaire evaluation and risk factor identification for nonallergic vasomotor rhinitis. *Ann Allergy Asthma Immunol*. 2006;96:526–532. III.
[146] Jacobs RL, Freedman PM, Boswell RN. Nonallergic rhinitis with eosinophilia (NARES syndrome). Clinical and immunologic presentation. *J Allergy Clin Immunol*. 1981;67:253–262. IIb.
[147] Tahamiler R, Canakcioglu S, Ogreden S, Acioglu E. The accuracy of symptom-based definition of chronic rhinosinusitis. *Allergy*. 2007;62:1029–1032. III.
[148] Bernatowska E, Mikoluc B, Krzeski A, Piatosa B, Gromek I. Chronic rhinosinusitis in primary antibody immunodeficient patients. *Int J Pediatr Otorhinolaryngol*. 2006;70:1587–1592. IIa.
[149] Chee L, Graham SM, Carothers DG, Ballas ZK. Immune dysfunction in refractory sinusitis in a tertiary care setting. *Laryngoscope*. 2001;111:233–235. IIa.
[150] Wise MT, Hagaman DD. An immunological approach to chronic and recurrent sinusitis. *Curr Opin Otolaryngol Head Neck Surg*. 2007;15:10–17. IV.
[151] May A, Zielen S, von Ilberg C, Weber A. Immunoglobulin deficiency and determination of pneumococcal antibody titers in patients with therapy-refractory recurrent rhinosinusitis. *Eur Arch Otorhinolaryngol*. 1999;256:445–449. III.
[152] Costa Carvalho BT, Nagao AT, Arslanian C, et al. Immunological evaluation of allergic respiratory children with recurrent sinusitis. *Pediatr Allergy Immunol*. 2005;16:534–538. III.
[153] Carr TF, Koterba AP, Chandra R, et al. Characterization of specific antibody deficiency in adults with medically refractory chronic rhinosinusitis. *Am J Rhinol Allergy*. 2011;25:241–244. IIb.
[154] Adappa ND, Coticchia JM. Management of refractory chronic rhinosinusitis in children. *Am J Otolaryngol*. 2006;27:384–389. III.
[155] Criddle MW, Stinson A, Savliwala M, Coticchia J. Pediatric chronic rhinosinusitis: a retrospective review. *Am J Otolaryngol*. 2008;29:372–378. III.
[156] Alqudah M, Graham SM, Ballas ZK. High prevalence of humoral immunodeficiency patients with refractory chronic rhinosinusitis. *Am J Rhinol Allergy*. 2010;24:409–412. IIb.
[157] Jeffrey Modell Foundation. *Primary Immunodeficiency Resource Center;* 2012. http://www.jmfworld.com/.
[158] Quinti I, Soresina A, Spadaro G, et al. Primary Immunodeficiency Network. Long-term follow-up and outcome of a large cohort of patients with common variable immunodeficiency. *J Clin Immunol*. 2007;27:308–316. III.
[159] Tahkokallio O, Seppala IJ, Sarvas H, Kayhty H, Mattila PS. Concentrations of serum immunoglobulins and antibodies to pneumococcal capsular polysaccharides in patients with recurrent or chronic sinusitis. *Ann Otol Rhinol Laryngol*. 2001;110:675–681. IIa.
[160] Cunningham-Rundles C, Bodian C. Common variable immunodeficiency: clinical and immunological features of 248 patients. *Clin Immunol*. 1999;92:34–48. III.
[161] Gross S, Blaiss MS, Herrod HG. Role of immunoglobulin subclasses and specific antibody determinations in the evaluation of recurrent infection in children. *J Pediatr*. 1992;121:516–522. III.
[162] Orange JS, Ballow M, Stiehm ER, et al. Use and interpretation of diagnostic vaccination in primary immunodeficiency: a working group report of the Basic and Clinical Immunology Interest Section of the American Academy of Allergy, Asthma & Immunology. *J Allergy Clin Immunol*. 2012;130(suppl):S1–S24. IV.
[163] Aucouturier P, Bremard-Oury C, Griscelli C, Berthier M, Preud'homme JL. Serum IgG subclass deficiency in ataxia-telangiectasia. *Clin Exp Immunol*. 1987;68:392–396. III.
[164] Shelley CS, Remold-O'Donnell E, Davis AE III, et al. Molecular characterization of sialophorin (CD43), the lymphocyte surface sialoglycoprotein defective in Wiskott-Aldrich syndrome. *Proc Natl Acad Sci U S A*. 1989;86:2819–2823. III.
[165] Skattum L, van Deuren M, van der Poll T, Truedsson L. Complement deficiency states and associated infections. *Mol Immunol*. 2011;48:1643–1655. IV.
[166] Zurlo JJ, Feuerstein IM, Lebovics R, Lane HC. Sinusitis in HIV-1 infection. *Am J Med*. 1992;93:157–162. III.
[167] Campanini A, Marani M, Mastroianni A, Cancellieri C, Vicini C. Human immunodeficiency virus infection: personal experience in changes in head and neck manifestations due to recent antiretroviral therapies. *Acta Otorhinolaryngol Ital*. 2005;25:30–35. III.
[168] Lucas M, Lee M, Lortan J, Lopez-Granados E, Misbah S, Chapel H. Infection outcomes in patients with common variable immunodeficiency disorders: relationship to immunoglobulin therapy over 22 years. *J Allergy Clin Immunol*. 2010;125:1354–1360e4. IIb.
[169] Schwartz SA. Intravenous immunoglobulin treatment of immunodeficiency disorders. *Pediatr Clin North Am*. 2000;47:1355–1369. III.
[170] Ocampo CJ, Peters AT. Antibody deficiency in chronic rhinosinusitis: epidemiology and burden of illness. *Am J Rhinol Allergy*. 2013;27:34–38. IV.
[171] Bonilla FA, Bernstein IL, Khan DA, et al. Practice parameter for the diagnosis and management of primary immunodeficiency. *Ann Allergy Asthma Immunol*. 2005;94(suppl 1):S1–S63. IV.
[172] Herrod HG. Follow-up of pediatric patients with recurrent infection and mild serologic immune abnormalities. *Ann Allergy Asthma Immunol*. 1997;79:460–464. III.
[173] Barbero GJ. Gastroesophageal reflux and upper airway disease. *Otolaryngol Clin North Am*. 1996;29:27–38. IV.
[174] Flook EP, Kumar BN. Is there evidence to link acid reflux with chronic sinusitis or any nasal symptoms? A review of the evidence. *Rhinology*. 2011;49:11–16. IIa.
[175] Phipps CD, Wood WE, Gibson WS, Cochran WJ. Gastroesophageal reflux contributing to chronic sinus disease in children: a prospective analysis. *Arch Otolaryngol Head Neck Surg*. 2000;126:831–836. IIa.
[176] Ulualp SO, Toohill RJ, Hoffmann R, Shaker R. Possible relationship of gastroesophagopharyngeal acid reflux with pathogenesis of chronic sinusitis. *Am J Rhinol*. 1999;13:197–202. IIa.
[177] DelGaudio JM. Direct nasopharyngeal reflux of gastric acid is a contributing factor in refractory chronic rhinosinusitis. *Laryngoscope*. 2005;115:946–957. IIb.
[178] DiBaise JK, Huerter JV, Quigley EM. Sinusitis and gastroesophageal reflux disease. *Ann Intern Med*. 1998;129:1078. IIa.
[179] Wong IW, Rees G, Greiff L, Myers JC, Jamieson GG, Wormald PJ. Gastroesophageal reflux disease and chronic sinusitis: in search of an esophageal-nasal reflex. *Am J Rhinol Allergy*. 2010;24:255–259. IIb.
[180] Bent JP III, Kuhn FA. Allergic fungal sinusitis/polyposis. *Allergy Asthma Proc*. 1996;17:259–268. III.
[181] Ferguson BJ, Barnes L, Bernstein JM, et al. Geographic variation in allergic fungal rhinosinusitis. *Otolaryngol Clin North Am*. 2000;33:441–449. III.
[182] Bartynski JM, McCaffrey TV, Frigas E. Allergic fungal sinusitis secondary to dermatiaceous fungi—Curvularia lunata and Alternaria. *Otolaryngol Head Neck Surg*. 1990;103:32–39. III.
[183] Friedman GC, Hartwick RW, Ro JY, Saleh GY, Tarrand JJ, Ayala AG. Allergic fungal sinusitis. Report of three cases associated with dematiaceous fungi. *Am J Clin Pathol*. 1991;96:368–372. III.
[184] Gourley DS, Whisman BA, Jorgensen NL, Martin ME, Reid MJ. Allergic Bipolaris sinusitis: clinical and immunopathologic characteristics. *J Allergy Clin Immunol*. 1990;85:583–591. III.
[185] Houser SM, Corey JP. Allergic fungal rhinosinusitis: pathophysiology, epidemiology, and diagnosis. *Otolaryngol Clin North Am*. 2000;33:399–409. IV.
[186] Manning SC, Schaefer SD, Close LG, Vuitch F. Culture-positive allergic fungal sinusitis. *Arch Otolaryngol Head Neck Surg*. 1991;117:174–178. III.
[187] Manning SC, Holman M. Further evidence for allergic pathophysiology in allergic fungal sinusitis. *Laryngoscope*. 1998;108:1485–1496. IIa.
[188] Nussenbaum B, Marple BF, Schwade ND. Characteristics of bony erosion in allergic fungal rhinosinusitis. *Otolaryngol Head Neck Surg*. 2001;124:150–154. III.
[189] Zinreich SJ, Kennedy DW, Malat J, et al. Fungal sinusitis: diagnosis with CT and MR imaging. *Radiology*. 1988;169:439–444. III.
[190] Kuhn FA, Javer AR. Allergic fungal sinusitis: a four-year follow-up. *Am J Rhinol*. 2000;14:149–156. III.
[191] Landsberg R, Segev Y, DeRowe A, Landau T, Khafif A, Fliss DM. Systemic corticosteroids for allergic fungal rhinosinusitis and chronic rhinosinusitis

with nasal polyposis: a comparative study. *Otolaryngol Head Neck Surg*. 2007;136:252–257. IIa.
[192] deShazo RD, Swain RE. Diagnostic criteria for allergic fungal sinusitis. *J Allergy Clin Immunol*. 1995;96:24–35. III.
[193] Kupferberg SB, Bent JP III, Kuhn FA. Prognosis for allergic fungal sinusitis. *Otolaryngol Head Neck Surg*. 1997;117:35–41. III.
[194] Schubert MS, Goetz DW. Evaluation and treatment of allergic fungal sinusitis. II. Treatment and follow-up. *J Allergy Clin Immunol*. 1998;102:395–402. III.
[195] Kuhn FA, Javer AR. Allergic fungal rhinosinusitis: our experience. *Arch Otolaryngol Head Neck Surg*. 1998;124:1179–1180. III.
[196] Kinsella JB, Bradfield JJ, Gourley WK, Calhoun KH, Rassekh CH. Allergic fungal sinusitis. *Clin Otolaryngol Allied Sci*. 1996;21:389–392. III.
[197] Kupferberg SB, Bent JP. Allergic fungal sinusitis in the pediatric population. *Arch Otolaryngol Head Neck Surg*. 1996;122:1381–1384. III.
[198] Rupa V, Jacob M, Mathews MS, Seshadri MS. A prospective, randomised, placebo-controlled trial of postoperative oral steroid in allergic fungal sinusitis. *Eur Arch Otorhinolaryngol*. 2010;267:233–238. Ib.
[199] Khalil Y, Tharwat A, Abdou AG, et al. The role of antifungal therapy in the prevention of recurrent allergic fungal rhinosinusitis after functional endoscopic sinus surgery: a randomized, controlled study. *Ear Nose Throat J*. 2011;90:E1–E7. Ib.
[200] Chan KO, Genoway KA, Javer AR. Effectiveness of itraconazole in the management of refractory allergic fungal rhinosinusitis. *J Otolaryngol Head Neck Surg*. 2008;37:870–874. IIb.
[201] Rains BM III, Mineck CW. Treatment of allergic fungal sinusitis with high-dose itraconazole. *Am J Rhinol*. 2003;17:1–8. III.
[202] Marple B, Newcomer M, Schwade N, Mabry R. Natural history of allergic fungal rhinosinusitis: a 4- to 10-year follow-up. *Otolaryngol Head Neck Surg*. 2002;127:361–366. III.
[203] Hsu J, Avila PC, Kern RC, Hayes MG, Schleimer RP, Pinto JM. Genetics of chronic rhinosinusitis: state of the field and directions forward. *J Allergy Clin Immunol*. 2013;131:977–993.e5. IV.
[204] Coltrera MD, Mathison SM, Goodpaster TA, Gown AM. Abnormal expression of the cystic fibrosis transmembrane regulator in chronic sinusitis in cystic fibrosis and non-cystic fibrosis patients. *Ann Otol Rhinol Laryngol*. 1999;108:576–581. IIa.
[205] Owens JM, Shroyer KR, Kingdom TT. Expression of cyclooxygenase and lipoxygenase enzymes in sinonasal mucosa of patients with cystic fibrosis. *Arch Otolaryngol Head Neck Surg*. 2008;134:825–831. IIa.
[206] Schraven SP, Wehrmann M, Wagner W, Blumenstock G, Koitschev A. Prevalence and histopathology of chronic polypoid sinusitis in pediatric patients with cystic fibrosis. *J Cyst Fibros*. 2011;10:181–186. IIa.
[207] Knipping S, Holzhausen HJ, Riederer A, Bloching M. Cystic fibrosis: ultrastructural changes of nasal mucosa. *Eur Arch Otorhinolaryngol*. 2007;264:1413–1418. IIa.
[208] Ebbens FA, Toppila-Salmi SK, Renkonen JA, et al. Endothelial L-selectin ligand expression in nasal polyps. *Allergy*. 2010;65:95–102. IIa.
[209] Hall SK, Stableforth DE, Green A. Sweat sodium and chloride concentrations—essential criteria for the diagnosis of cystic fibrosis in adults. *Ann Clin Biochem*. 1990;27:318–320. IIa.
[210] Brook I. Microbiology of sinusitis. *Proc Am Thorac Soc*. 2011;8:90–100. III.
[211] Wang X, Moylan B, Leopold DA, et al. Mutation in the gene responsible for cystic fibrosis and predisposition to chronic rhinosinusitis in the general population. *JAMA*. 2000;284:1814–1819. IIa.
[212] Raman V, Clary R, Siegrist KL, Zehnbauer B, Chatila TA. Increased prevalence of mutations in the cystic fibrosis transmembrane conductance regulator in children with chronic rhinosinusitis. *Pediatrics*. 2002;109:E13. IIa.
[213] Ramsey BW, Davies J, McElvaney NG, et al. A CFTR potentiator in patients with cystic fibrosis and the G551D mutation. *N Engl J Med*. 2011;365:1663–1672. Ib.
[214] Hadfield PJ, Rowe-Jones JM, Mackay IS. The prevalence of nasal polyps in adults with cystic fibrosis. *Clin Otolaryngol Allied Sci*. 2000;25:19–22. III.
[215] Eggesbo HB, Sovik S, Dolvik S, Kolmannskog F. CT characterization of inflammatory paranasal sinus disease in cystic fibrosis. *Acta Radiol*. 2002;43:21–28. IIa.
[216] Orlandi RR, Wiggins RH III. Radiological sinonasal findings in adults with cystic fibrosis. *Am J Rhinol Allergy*. 2009;23:307–311. III.
[217] Khalid AN, Mace J, Smith TL. Outcomes of sinus surgery in adults with cystic fibrosis. *Otolaryngol Head Neck Surg*. 2009;141:358–363. IIa.
[218] Godoy JM, Godoy AN, Ribalta G, Largo I. Bacterial pattern in chronic sinusitis and cystic fibrosis. *Otolaryngol Head Neck Surg*. 2011;145:673–676. IIb.
[219] Jones AM, Dodd ME, Webb AK. Burkholderia cepacia: current clinical issues, environmental controversies and ethical dilemmas. *Eur Respir J*. 2001;17:295–301. IV.
[220] Allice T, Scutera S, Chirillo MG, Savoia D. Burkholderia respiratory tract infections in Italian patients with cystic fibrosis: molecular characterization. *J Infect*. 2006;53:159–165. III.
[221] Marioni G, Rinaldi R, Staffieri C, et al. Burkholderia cepacia complex nasal isolation in immunocompetent patients with sinonasal polyposis not associated with cystic fibrosis. *Eur J Clin Microbiol Infect Dis*. 2007;26:73–75. III.
[222] Hansen SK, Rau MH, Johansen HK, et al. Evolution and diversification of Pseudomonas aeruginosa in the paranasal sinuses of cystic fibrosis children have implications for chronic lung infection. *ISME J*. 2012;6:31–45. III.
[223] Wise SK, Kingdom TT, McKean L, DelGaudio JM, Venkatraman G. Presence of fungus in sinus cultures of cystic fibrosis patients. *Am J Rhinol*. 2005;19:47–51. III.
[224] Moss RB, King VV. Management of sinusitis in cystic fibrosis by endoscopic surgery and serial antimicrobial lavage. Reduction in recurrence requiring surgery. *Arch Otolaryngol Head Neck Surg*. 1995;121:566–572. IIa.
[225] Gibson RL, Emerson J, Mayer-Hamblett N, et al. Duration of treatment effect after tobramycin solution for inhalation in young children with cystic fibrosis. *Pediatr Pulmonol*. 2007;42:610–623. IIa.
[226] Cimmino M, Nardone M, Cavaliere M, et al. Dornase alfa as postoperative therapy in cystic fibrosis sinonasal disease. *Arch Otolaryngol Head Neck Surg*. 2005;131:1097–1101. Ib.
[227] Mainz JG, Schiller I, Ritschel C, et al. Sinonasal inhalation of dornase alfa in CF: A double-blind placebo-controlled cross-over pilot trial. *Auris Nasus Larynx*. 2011;38:220–227. Ib.
[228] Holzmann D, Speich R, Kaufmann T, et al. Effects of sinus surgery in patients with cystic fibrosis after lung transplantation: a 10-year experience. *Transplantation*. 2004;77:134–136. IIb.
[229] Gutierrez C, Ribalta G, Largo I. Retrospective analysis of chronic rhinosinusitis in patients with cystic fibrosis. *Acta Otorrinolaringol Esp*. 2012;63:286–291. III.
[230] Davidson TM, Murphy C, Mitchell M, Smith C, Light M. Management of chronic sinusitis in cystic fibrosis. *Laryngoscope*. 1995;105:354–358. IV.
[231] Macdonald KI, Gipsman A, Magit A, et al. Endoscopic sinus surgery in patients with cystic fibrosis: a systematic review and meta-analysis of pulmonary function. *Rhinology*. 2012;50:360–369. Ia.
[232] Bush A, Hogg C. Primary ciliary dyskinesia: recent advances in epidemiology, diagnosis, management and relationship with the expanding spectrum of ciliopathy. *Expert Rev Respir Med*. 2012;6:663–682. IV.
[233] Kuehni CE, Frischer T, Strippoli MP, et al. Factors influencing age at diagnosis of primary ciliary dyskinesia in European children. *Eur Respir J*. 2010;36:1248–1258. III.
[234] Kartagener M. Zur Pathologie der Bronkiektasien: Bronchiektasien bei Situs viscerum inversus. *Beitr Klin Tuberk*. 1933;83:489–501. III.
[235] Afzelius BA, Ewetz L, Palmblad J, Uden AM, Venizelos N. Structure and function of neutrophil leukocytes from patients with the immotile-cilia syndrome. *Acta Med Scand*. 1980;208:145–154. IIa.
[236] Thomas SR, Kharitonov SA, Scott SF, Hodson ME, Barnes PJ. Nasal and exhaled nitric oxide is reduced in adult patients with cystic fibrosis and does not correlate with cystic fibrosis genotype. *Chest*. 2000;117:1085–1089. IIa.
[237] Nakano H, Ide H, Imada M, et al. Reduced nasal nitric oxide in diffuse panbronchiolitis. *Am J Respir Crit Care Med*. 2000;162:2218–2220. IIa.
[238] Piacentini GL, Bodini A, Peroni DG, et al. Nasal nitric oxide levels in healthy pre-school children. *Pediatr Allergy Immunol*. 2010;21:1139–1145. III.
[239] Strippoli MP, Frischer T, Barbato A, et al. Management of primary ciliary dyskinesia in European children: recommendations and clinical practice. *Eur Respir J*. 2012;39:1482–1491. III.
[240] Papon JF, Coste A, Roudot-Thoraval F, et al. A 20-year experience of electron microscopy in the diagnosis of primary ciliary dyskinesia. *Eur Respir J*. 2010;35:1057–1063. III.
[241] Shoemark A, Dixon M, Corrin B, Dewar A. Twenty-year review of quantitative transmission electron microscopy for the diagnosis of primary ciliary dyskinesia. *J Clin Pathol*. 2012;65:267–271. III.
[242] Escudier E, Couprie M, Duriez B, et al. Computer-assisted analysis helps detect inner dynein arm abnormalities. *Am J Respir Crit Care Med*. 2002;166:1257–1262. III.
[243] Asai K, Haruna S, Otori N, Yanagi K, Fukami M, Moriyama H. Saccharin test of maxillary sinus mucociliary function after endoscopic sinus surgery. *Laryngoscope*. 2000;110:117–122. IIb.
[244] Grote JJ, Kuijpers W. Middle ear effusion and sinusitis. *J Laryngol Otol*. 1980;94:177–183. III.
[245] Finkelstein Y, Talmi YP, Rubel Y, Bar-Ziv J, Zohar Y. Otitis media with effusion as a presenting symptom of chronic sinusitis. *J Laryngol Otol*. 1989;103:827–832. III.
[246] Hoople GD, Blaisdell IH. Some clinical observations on acute catarrhal otitis media. *Proc R Soc Med*. 1944;37:270–274. III.
[247] Hong CK, Park DC, Kim SW, Cha CI, Cha SH, Yeo SG. Effect of paranasal sinusitis on the development of otitis media with effusion: influence of eustachian tube function and adenoid immunity. *Int J Pediatr Otorhinolaryngol*. 2008;72:1609–1618. III.
[248] Bresciani M, Paradis L, Des Roches A, et al. Rhinosinusitis in severe asthma. *J Allergy Clin Immunol*. 2001;107:73–80. III.
[249] ten Brinke A, Grootendorst DC, Schmidt JT, et al. Chronic sinusitis in severe asthma is related to sputum eosinophilia. *J Allergy Clin Immunol*. 2002;109:621–626. IIb.
[250] Lin DC, Chandra RK, Tan BK, et al. Association between severity of asthma and degree of chronic rhinosinusitis. *Am J Rhinol Allergy*. 2011;25:205–208. III.
[251] Kaufman J, Wright GW. The effect of nasal and nasopharyngeal irritation on airway resistance in man. *Am Rev Respir Dis*. 1969;100:626–630. IIa.
[252] Ozcan M, Ortapamuk H, Naldoken S, Olcay I, Ozcan KM, Tuncel U. Pulmonary aspiration of nasal secretions in patients with chronic sinusitis and asthma. *Arch Otolaryngol Head Neck Surg*. 2003;129:1006–1009. IIa.
[253] Griffin MP, McFadden ER Jr, Ingram RH Jr. Airway cooling in asthmatic and nonasthmatic subjects during nasal and oral breathing. *J Allergy Clin Immunol*. 1982;69:354–359. IIb.
[254] Denburg JA, Sehmi R, Saito H, Pil-Seob J, Inman MD, O'Byrne PM. Systemic aspects of allergic disease: bone marrow responses. *J Allergy Clin Immunol*. 2000;106(suppl):S242–S246. IIb.

[255] Bucca C, Rolla G, Scappaticci E, et al. Extrathoracic and intrathoracic airway responsiveness in sinusitis. *J Allergy Clin Immunol*. 1995;95:52–59. III.
[256] Rolla G, Colagrande P, Scappaticci E, et al. Damage of the pharyngeal mucosa and hyperresponsiveness of airway in sinusitis. *J Allergy Clin Immunol*. 1997;100:52–57. III.
[257] Bachert C, Zhang N, Holtappels G, et al. Presence of IL-5 protein and IgE antibodies to staphylococcal enterotoxins in nasal polyps is associated with comorbid asthma. *J Allergy Clin Immunol*. 2010;126:962–968. IIb.
[258] Rachelefsky GS, Katz RM, Siegel SC. Chronic sinus disease with associated reactive airway disease in children. *Pediatrics*. 1984;73:526–529. III.
[259] Friedman R, Ackerman M, Wald E, Casselbrant M, Friday G, Fireman P. Asthma and bacterial sinusitis in children. *J Allergy Clin Immunol*. 1984;74:185–189. III.
[260] Palmer JN, Conley DB, Dong RG, Ditto AM, Yarnold PR, Kern RC. Efficacy of endoscopic sinus surgery in the management of patients with asthma and chronic sinusitis. *Am J Rhinol*. 2001;15:49–53. III.
[261] Ikeda K, Tanno N, Tamura G, et al. Endoscopic sinus surgery improves pulmonary function in patients with asthma associated with chronic sinusitis. *Ann Otol Rhinol Laryngol*. 1999;108:355–359. IIa.
[262] Ragab S, Scadding GK, Lund VJ, Saleh H. Treatment of chronic rhinosinusitis and its effects on asthma. *Eur Respir J*. 2006;28:68–74. III.
[263] Chow AW, Benninger MS, Brook I, et al. IDSA clinical practice guideline for acute bacterial rhinosinusitis in children and adults. *Clin Infect Dis*. 2012;54:e72–e112. IV.
[264] Wald ER, Applegate KE, Bordley C, et al. Clinical practice guideline for the diagnosis and management of acute bacterial sinusitis in children aged 1 to 18 years. *Pediatrics*. 2013;132:e262–e280. Ib.
[265] Lemiengre MB, van Driel ML, Merenstein D, Young J, De Sutter AI. Antibiotics for clinically diagnosed acute rhinosinusitis in adults. *Cochrane Database Syst Rev*. 2012;10:CD006089. Ia.
[266] Meltzer EO, Bachert C, Staudinger H. Treating acute rhinosinusitis: comparing efficacy and safety of mometasone furoate nasal spray, amoxicillin, and placebo. *J Allergy Clin Immunol*. 2005;116:1289–1295. Ib.
[267] Keith PK, Dymek A, Pfaar O, et al. Fluticasone furoate nasal spray reduces symptoms of uncomplicated acute rhinosinusitis: a randomised placebo-controlled study. *Prim Care Respir J*. 2012;21:267–275. Ib.
[268] Bachert C, Meltzer EO. Effect of mometasone furoate nasal spray on quality of life of patients with acute rhinosinusitis. *Rhinology*. 2007;45:190–196. Ib.
[269] Williamson IG, Rumsby K, Benge S, et al. Antibiotics and topical nasal steroid for treatment of acute maxillary sinusitis: a randomized controlled trial. *JAMA*. 2007;298:2487–2496. Ib.
[270] Dolor RJ, Witsell DL, Hellkamp AS, Williams JW Jr, Califf RM, Simel DL. Comparison of cefuroxime with or without intranasal fluticasone for the treatment of rhinosinusitis. The CAFFS Trial: a randomized controlled trial. *JAMA*. 2001;286:3097–3105. Ib.
[271] Barlan IB, Erkan E, Bakir M, Berrak S, Basaran MM. Intranasal budesonide spray as an adjunct to oral antibiotic therapy for acute sinusitis in children. *Ann Allergy Asthma Immunol*. 1997;78:598–601. Ib.
[272] Zalmanovici A, Yaphe J. Intranasal steroids for acute sinusitis. *Cochrane Database Syst Rev*. 2009;4:CD005149. Ia.
[273] Hayward G, Heneghan C, Perera R, Thompson M. Intranasal corticosteroids in management of acute sinusitis: a systematic review and meta-analysis. *Ann Fam Med*. 2012;10:241–249. Ia.
[274] Venekamp RP, Bonten MJ, Rovers MM, Verheij TJ, Sachs AP. Systemic corticosteroid monotherapy for clinically diagnosed acute rhinosinusitis: a randomized controlled trial. *CMAJ*. 2012;184:E751–E757. Ia.
[275] Venekamp RP, Thompson MJ, Hayward G, et al. Systemic corticosteroids for acute sinusitis. *Cochrane Database Syst Rev*. 2011;12:CD008115. 1a.
[276] Arroll B. Common cold. *Clin Evid (Online)*. 2011;2011. Ia.
[277] Shaikh N, Wald ER, Pi M. Decongestants, antihistamines, and nasal irrigation for acute sinusitis in children. *Cochrane Database Syst Rev*. 2010;12:CD007909. Ia.
[278] Kassel JC, King D, Spurling GK. Saline nasal irrigation for acute upper respiratory tract infections. *Cochrane Database Syst Rev*. 2010;3:CD006821. Ia.
[279] Singh M, Das RR. Zinc for the common cold. *Cochrane Database Syst Rev*. 2011;2:CD001364. Ia.
[280] Wu T, Zhang J, Qiu Y, Xie L, Liu GJ. Chinese medicinal herbs for the common cold. *Cochrane Database Syst Rev*. 2007;1:CD004782. Ia.
[281] Piromchai P, Thanaviratananich S, Laopaiboon M. Systemic antibiotics for chronic rhinosinusitis without nasal polyps in adults. *Cochrane Database Syst Rev*. 2011;5:CD008233. Ia.
[282] Videler WJ, Badia L, Harvey RJ, et al. Lack of efficacy of long-term, low-dose azithromycin in chronic rhinosinusitis: a randomized controlled trial. *Allergy*. 2011;66:1457–1468. Ib.
[283] Huck W, Reed BD, Nielsen RW, et al. Cefaclor vs amoxicillin in the treatment of acute, recurrent, and chronic sinusitis. *Arch Fam Med*. 1993;2:497–503. Ib.
[284] Legent F, Bordure P, Beauvillain C, Berche P. Controlled prospective study of oral ciprofloxacin versus amoxicillin/clavulanic acid in chronic suppurative otitis media in adults. *Chemotherapy*. 1994;40(suppl 1):16–23.
[285] Namyslowski G, Misiolek M, Czecior E, et al. Comparison of the efficacy and tolerability of amoxicillin/clavulanic acid 875 mg b.i.d. with cefuroxime 500 mg b.i.d. in the treatment of chronic and acute exacerbation of chronic sinusitis in adults. *J Chemother*. 2002;14:508–517. Ib.
[286] Dubin MG, Kuhn FA, Melroy CT. Radiographic resolution of chronic rhinosinusitis without polyposis after 6 weeks vs 3 weeks of oral antibiotics. *Ann Allergy Asthma Immunol*. 2007;98:32–35. IIb.
[287] Chan KH, Abzug MJ, Coffinet L, Simoes EA, Cool C, Liu AH. Chronic rhinosinusitis in young children differs from adults: a histopathology study. *J Pediatr*. 2004;144:206–212. IIa.
[288] Coffinet L, Chan KH, Abzug MJ, Simoes EA, Cool C, Liu AH. Immunopathology of chronic rhinosinusitis in young children. *J Pediatr*. 2009;154:754–758. IIb.
[289] Van Zele T, Gevaert P, Watelet JB, et al. Staphylococcus aureus colonization and IgE antibody formation to enterotoxins is increased in nasal polyposis. *J Allergy Clin Immunol*. 2004;114:981–983. IIb.
[290] Bachert C, Zhang N, Patou J, van Zele T, Gevaert P. Role of staphylococcal superantigens in upper airway disease. *Curr Opin Allergy Clin Immunol*. 2008;8:34–38. IV.
[291] Van Zele T, Gevaert P, Holtappels G, et al. Oral steroids and doxycycline: two different approaches to treat nasal polyps. *J Allergy Clin Immunol*. 2010;125:1069–1076e4. Ib.
[292] Schalek P, Petras P, Klement V, Hahn A. Short-term antibiotics treatment in patients with nasal polyps and enterotoxins producing Staphylococcus aureus strains. *Eur Arch Otorhinolaryngol*. 2009;266:1909–1913. Ib.
[293] Harvey RJ, Wallwork BD, Lund VJ. Anti-inflammatory effects of macrolides: applications in chronic rhinosinusitis. *Immunol Allergy Clin North Am*. 2009;29:689–703. Ia.
[294] Ragab SM, Lund VJ, Scadding G. Evaluation of the medical and surgical treatment of chronic rhinosinusitis: a prospective, randomised, controlled trial. *Laryngoscope*. 2004;114:923–930. Ib.
[295] Wallwork B, Coman W, Mackay-Sim A, Greiff L, Cervin A. A double-blind, randomized, placebo-controlled trial of macrolide in the treatment of chronic rhinosinusitis. *Laryngoscope*. 2006;116:189–193. Ib.
[296] Lim M, Citardi MJ, Leong JL. Topical antimicrobials in the management of chronic rhinosinusitis: a systematic review. *Am J Rhinol*. 2008;22:381–389. Ia.
[297] Scheinberg PA, Otsuji A. Nebulized antibiotics for the treatment of acute exacerbations of chronic rhinosinusitis. *Ear Nose Throat J*. 2002;81:648–652. IIb.
[298] Vaughan WC, Carvalho G. Use of nebulized antibiotics for acute infections in chronic sinusitis. *Otolaryngol Head Neck Surg*. 2002;127:558–568. IIa.
[299] Uren B, Psaltis A, Wormald PJ. Nasal lavage with mupirocin for the treatment of surgically recalcitrant chronic rhinosinusitis. *Laryngoscope*. 2008;118:1677–1680. IIb.
[300] Elliott KA, Stringer SP. Evidence-based recommendations for antimicrobial nasal washes in chronic rhinosinusitis. *Am J Rhinol*. 2006;20:1–6. Ia.
[301] Whatley WS, Chandra RK, MacDonald CB. Systemic absorption of gentamicin nasal irrigations. *Am J Rhinol*. 2006;20:251–254. III.
[302] Cheng AG, Johnston PR, Luz J, et al. Sensorineural hearing loss in patients with cystic fibrosis. *Otolaryngol Head Neck Surg*. 2009;141:86–90. III.
[303] Anand V, Levine H, Friedman M, et al. Intravenous antibiotics for refractory rhinosinusitis in nonsurgical patients: preliminary findings of a prospective study. *Am J Rhinol*. 2003;17:363–368. IIb.
[304] Fowler K, Duncavage J, Murray J, Tanner S. Chronic sinusitis and intravenous antibiotic therapy: resolution, recurrence, and adverse events. *J Allergy Clin Immunol*. 2003;111:S85. III.
[305] Lin JW, Kacker A, Anand VK, Levine H. Catheter- and antibiotic-related complications of ambulatory intravenous antibiotic therapy for chronic refractory rhinosinusitis. *Am J Rhinol*. 2005;19:365–369. III.
[306] Soler ZM, Oyer SL, Kern RC, et al. Antimicrobials and chronic rhinosinusitis with or without polyposis in adults: an evidenced-based review with recommendations. *Int Forum Allergy Rhinol*. 2013;3:31–47. Ib.
[307] Subramanian HN, Schechtman KB, Hamilos DL. A retrospective analysis of treatment outcomes and time to relapse after intensive medical treatment for chronic sinusitis. *Am J Rhinol*. 2002;16:303–312. III.
[308] Tosca MA, Cosentino C, Pallestrini E, et al. Medical treatment reverses cytokine pattern in allergic and nonallergic chronic rhinosinusitis in asthmatic children. *Pediatr Allergy Immunol*. 2003;14:238–241. IIb.
[309] Ozturk F, Bakirtas A, Ileri F, Turktas I. Efficacy and tolerability of systemic methylprednisolone in children and adolescents with chronic rhinosinusitis: a double-blind, placebo-controlled randomized trial. *J Allergy Clin Immunol*. 2011;128:348–352. Ib.
[310] Skorpinski EW, Vannelli PM, Yousef E, Brunell T, McGeady SJ. Radiologic outcomes in children with chronic rhinosinusitis and ostiomeatal complex obstruction after medical management. *Ann Allergy Asthma Immunol*. 2008;100:529–532. III.
[311] Lal D, Scianna JM, Stankiewicz JA. Efficacy of targeted medical therapy in chronic rhinosinusitis, and predictors of failure. *Am J Rhinol Allergy*. 2009;23:396–400. III.
[312] Patiar S, Reece P. Oral steroids for nasal polyps. *Cochrane Database Syst Rev*. 2007;1:CD005232. Ia.
[313] Alobid I, Benitez P, Pujols L, et al. Severe nasal polyposis and its impact on quality of life. The effect of a short course of oral steroids followed by long-term intranasal steroid treatment. *Rhinology*. 2006;44:8–13. Ib.
[314] Hissaria P, Smith W, Wormald PJ, et al. Short course of systemic corticosteroids in sinonasal polyposis: a double-blind, randomized, placebo-controlled trial with evaluation of outcome measures. *J Allergy Clin Immunol*. 2006;118:128–133. Ib.
[315] Benitez P, Alobid I, de Haro J, et al. A short course of oral prednisone followed by intranasal budesonide is an effective treatment of severe nasal polyps. *Laryngoscope*. 2006;116:770–775. Ib.
[316] Parikh A, Scadding GK, Darby Y, Baker RC. Topical corticosteroids in chronic rhinosinusitis: a randomized, double-blind, placebo-controlled trial using fluticasone propionate aqueous nasal spray. *Rhinology*. 2001;39:75–79. Ib.

[317] Lavigne F, Cameron L, Renzi PM, et al. Intrasinus administration of topical budesonide to allergic patients with chronic rhinosinusitis following surgery. *Laryngoscope*. 2002;112:858–864. Ib.
[318] Lund VJ, Black JH, Szabo LZ, Schrewelius C, Akerlund A. Efficacy and tolerability of budesonide aqueous nasal spray in chronic rhinosinusitis patients. *Rhinology*. 2004;42:57–62. Ib.
[319] Furukido K, Takeno S, Ueda T, Yajin K. Cytokine profile in paranasal effusions in patients with chronic sinusitis using the YAMIK sinus catheter with and without betamethasone. *Eur Arch Otorhinolaryngol*. 2005;262:50–54. Ib.
[320] Jorissen M, Bachert C. Effect of corticosteroids on wound healing after endoscopic sinus surgery. *Rhinology*. 2009;47:280–286. Ib.
[321] Giger R, Pasche P, Cheseaux C, et al. Comparison of once- versus twice-daily use of beclomethasone dipropionate aqueous nasal spray in the treatment of allergic and non-allergic chronic rhinosinusitis. *Eur Arch Otorhinolaryngol*. 2003;260:135–140. Ib.
[322] Sykes DA, Wilson R, Chan KL, Mackay IS, Cole PJ. Relative importance of antibiotic and improved clearance in topical treatment of chronic mucopurulent rhinosinusitis. A controlled study. *Lancet*. 1986;2:359–360. Ib.
[323] Cuenant G, Stipon JP, Plante-Longchamp G, Baudoin C, Guerrier Y. Efficacy of endonasal neomycin-tixocortol pivalate irrigation in the treatment of chronic allergic and bacterial sinusitis. *ORL J Otorhinolaryngol Relat Spec*. 1986;48:226–232. Ib.
[324] Qvarnberg Y, Kantola O, Salo J, Toivanen M, Valtonen H, Vuori E. Influence of topical steroid treatment on maxillary sinusitis. *Rhinology*. 1992;30:103–112. Ib.
[325] Dijkstra MD, Ebbens FA, Poublon RM, Fokkens WJ. Fluticasone propionate aqueous nasal spray does not influence the recurrence rate of chronic rhinosinusitis and nasal polyps 1 year after functional endoscopic sinus surgery. *Clin Exp Allergy*. 2004;34:1395–1400. Ib.
[326] Hansen FS, Djupesland PG, Fokkens WJ. Preliminary efficacy of fluticasone delivered by a novel device in recalcitrant chronic rhinosinusitis. *Rhinology*. 2010;48:292–299. Ib.
[327] Mosges R, Bachert C, Rudack C, et al. Efficacy and safety of mometasone furoate nasal spray in the treatment of chronic rhinosinusitis. *Adv Ther*. 2011;28:238–249. Ib.
[328] Keith P, Nieminen J, Hollingworth K, Dolovich J. Efficacy and tolerability of fluticasone propionate nasal drops 400 microgram once daily compared with placebo for the treatment of bilateral polyposis in adults. *Clin Exp Allergy*. 2000;30:1460–1468. Ib.
[329] Lund VJ, Flood J, Sykes AP, Richards DH. Effect of fluticasone in severe polyposis. *Arch Otolaryngol Head Neck Surg*. 1998;124:513–518. Ib.
[330] Jankowski R, Klossek JM, Attali V, Coste A, Serrano E. Long-term study of fluticasone propionate aqueous nasal spray in acute and maintenance therapy of nasal polyposis. *Allergy*. 2009;64:944–950. Ib.
[331] Penttila M, Poulsen P, Hollingworth K, Holmstrom M. Dose-related efficacy and tolerability of fluticasone propionate nasal drops 400 microgram once daily and twice daily in the treatment of bilateral nasal polyposis: a placebo-controlled randomized study in adult patients. *Clin Exp Allergy*. 2000;30:94–102. Ib.
[332] Holmstrom M. Clinical performance of fluticasone propionate nasal drops. *Allergy*. 1999;54(suppl 53):21–25. Ib.
[333] Chalton R, Mackay I, Wilson R, Cole P. Double blind, placebo controlled trial of betamethasone nasal drops for nasal polyposis. *Br Med J (Clin Res Ed)*. 1985;291:788. Ib.
[334] Aukema AA, Mulder PG, Fokkens WJ. Treatment of nasal polyposis and chronic rhinosinusitis with fluticasone propionate nasal drops reduces need for sinus surgery. *J Allergy Clin Immunol*. 2005;115:1017–1023. Ib.
[335] Olsson P, Ehnhage A, Nordin S, Stjarne P. Quality of life is improved by endoscopic surgery and fluticasone in nasal polyposis with asthma. *Rhinology*. 2010;48:325–330. Ib.
[336] Ehnhage A, Olsson P, Kolbeck KG, et al. Functional endoscopic sinus surgery improved asthma symptoms as well as PEFR and olfaction in patients with nasal polyposis. *Allergy*. 2009;64:762–769. Ib.
[337] Wei JL, Sykes KJ, Johnson P, He J, Mayo MS. Safety and efficacy of once-daily nasal irrigation for the treatment of pediatric chronic rhinosinusitis. *Laryngoscope*. 2011;121:1989–2000. Ib.
[338] Harvey R, Hannan SA, Badia L, Scadding G. Nasal saline irrigations for the symptoms of chronic rhinosinusitis. *Cochrane Database Syst Rev*. 2007;3:CD006394. Ia.
[339] Pynnonen MA, Mukerji SS, Kim HM, Adams ME, Terrell JE. Nasal saline for chronic sinonasal symptoms: a randomized controlled trial. *Arch Otolaryngol Head Neck Surg*. 2007;133:1115–1120. Ib.
[340] Yoder JS, Straif-Bourgeois S, Roy SL, et al. Primary amebic meningoencephalitis deaths associated with sinus irrigation using contaminated tap water. *Clin Infect Dis*. 2012;55:e79–e85. III.
[341] Keen M, Foreman A, Wormald PJ. The clinical significance of nasal irrigation bottle contamination. *Laryngoscope*. 2010;120:2110–2114. IIb.
[342] Harvey RJ, Psaltis A, Schlosser RJ, Witterick IJ. Current concepts in topical therapy for chronic sinonasal disease. *J Otolaryngol Head Neck Surg*. 2010;39:217–231. IV.
[343] Mortuaire G, de Gabory L, Francois M, et al. Rebound congestion and rhinitis medicamentosa: nasal decongestants in clinical practice. Critical review of the literature by a medical panel. *Eur Ann Otorhinolaryngol Head Neck Dis*. 2013;130:137–144. III.
[344] Pauli C, Fintelmann R, Klemens C, et al. [Polyposis nasi—improvement in quality of life by the influence of leukotrien receptor antagonists]. *Laryngorhinootologie*. 2007;86:282–286. Ib.
[345] Ragab S, Parikh A, Darby YC, Scadding GK. An open audit of montelukast, a leukotriene receptor antagonist, in nasal polyposis associated with asthma. *Clin Exp Allergy*. 2001;31:1385–1391. IIb.
[346] Stewart RA, Ram B, Hamilton G, Weiner J, Kane KJ. Montelukast as an adjunct to oral and inhaled steroid therapy in chronic nasal polyposis. *Otolaryngol Head Neck Surg*. 2008;139:682–687. Ib.
[347] Micheletto C, Tognella S, Visconti M, Pomari C, Trevisan F, Dal Negro RW. Montelukast 10 mg improves nasal function and nasal response to aspirin in ASA-sensitive asthmatics: a controlled study vs placebo. *Allergy*. 2004;59:289–294. IIa.
[348] White A, Ludington E, Mehra P, Stevenson DD, Simon RA. Effect of leukotriene modifier drugs on the safety of oral aspirin challenges. *Ann Allergy Asthma Immunol*. 2006;97:688–693. III.
[349] Lee JY, Simon RA, Stevenson DD. Selection of aspirin dosages for aspirin desensitization treatment in patients with aspirin-exacerbated respiratory disease. *J Allergy Clin Immunol*. 2007;119:157–164. IIb.
[350] Joint Task Force on Practice Parameters, American Academy of Allergy, Asthma and Immunology, American College of Allergy, Asthma and Immunology, Joint Council of Allergy, Asthma and Immunology. Drug allergy: an updated practice parameter. *Ann Allergy Asthma Immunol*. 2010;105:259–273. IV.
[351] Stevenson DD, Simon RA. Selection of patients for aspirin desensitization treatment. *J Allergy Clin Immunol*. 2006;118:801–804. IV.
[352] Hope AP, Woessner KA, Simon RA, Stevenson DD. Rational approach to aspirin dosing during oral challenges and desensitization of patients with aspirin-exacerbated respiratory disease. *J Allergy Clin Immunol*. 2009;123:406–410. III.
[353] Macy E, Bernstein JA, Castells MC, et al. Aspirin challenge and desensitization for aspirin-exacerbated respiratory disease: a practice paper. *Ann Allergy Asthma Immunol*. 2007;98:172–174. IV.
[354] White AA, Stevenson DD, Simon RA. The blocking effect of essential controller medications during aspirin challenges in patients with aspirin-exacerbated respiratory disease. *Ann Allergy Asthma Immunol*. 2005;95:330–335. III.
[355] Woessner KM, Simon RA. Cardiovascular prophylaxis and aspirin "allergy." *Immunol Allergy Clin North Am*. 2013;33:263–274. IV.
[356] Lee RU, White AA, Ding D, et al. Use of intranasal ketorolac and modified oral aspirin challenge for desensitization of aspirin-exacerbated respiratory disease. *Ann Allergy Asthma Immunol*. 2010;105:130–135. IIa.
[357] Berges-Gimeno MP, Simon RA, Stevenson DD. Long-term treatment with aspirin desensitization in asthmatic patients with aspirin-exacerbated respiratory disease. *J Allergy Clin Immunol*. 2003;111:180–186. IIb.
[358] Stevenson DD, Hankammer MA, Mathison DA, Christiansen SC, Simon RA. Aspirin desensitization treatment of aspirin-sensitive patients with rhinosinusitis-asthma: long-term outcomes. *J Allergy Clin Immunol*. 1996;98:751–758. IIb.
[359] Sweet JM, Stevenson DD, Simon RA, Mathison DA. Long-term effects of aspirin desensitization—treatment for aspirin-sensitive rhinosinusitis-asthma. *J Allergy Clin Immunol*. 1990;85:59–65. IIa.
[360] Arm JP, O'Hickey SP, Hawksworth RJ, et al. Asthmatic airways have a disproportionate hyperresponsiveness to LTE4, as compared with normal airways, but not to LTC4, LTD4, methacholine, and histamine. *Am Rev Respir Dis*. 1990;142:1112–1118. IIb.
[361] Sousa AR, Parikh A, Scadding G, Corrigan CJ, Lee TH. Leukotriene-receptor expression on nasal mucosal inflammatory cells in aspirin-sensitive rhinosinusitis. *N Engl J Med*. 2002;347:1493–1499. IIa.
[362] Nasser SM, Patel M, Bell GS, Lee TH. The effect of aspirin desensitization on urinary leukotriene E4 concentrations in aspirin-sensitive asthma. *Am J Respir Crit Care Med*. 1995;151:1326–1330. IIb.
[363] Juergens UR, Christiansen SC, Stevenson DD, Zuraw BL. Inhibition of monocyte leukotriene B4 production after aspirin desensitization. *J Allergy Clin Immunol*. 1995;96:148–156. IIb.
[364] Ferreri NR, Howland WC, Stevenson DD, Spiegelberg HL. Release of leukotrienes, prostaglandins, and histamine into nasal secretions of aspirin-sensitive asthmatics during reaction to aspirin. *Am Rev Respir Dis*. 1988;137:847–854. IIa.
[365] Dahlen B, Nizankowska E, Szczeklik A, et al. Benefits from adding the 5-lipoxygenase inhibitor zileuton to conventional therapy in aspirin-intolerant asthmatics. *Am J Respir Crit Care Med*. 1998;157:1187–1194. Ia.
[366] Ponikau JU, Sherris DA, Kern EB, et al. The diagnosis and incidence of allergic fungal sinusitis. *Mayo Clin Proc*. 1999;74:877–884. III.
[367] Braun H, Stammberger H, Buzina W, Freudenschuss K, Lackner A, Beham A. [Incidence and detection of fungi and eosinophilic granulocytes in chronic rhinosinusitis]. *Laryngorhinootologie*. 2003;82:330–340. IIa.
[368] Shin SH, Ponikau JU, Sherris DA, et al. Chronic rhinosinusitis: an enhanced immune response to ubiquitous airborne fungi. *J Allergy Clin Immunol*. 2004;114:1369–1375. IIa.
[369] Orlandi RR, Marple BF, Georgelas A, Durtschi D, Barr L. Immunologic response to fungus is not universally associated with rhinosinusitis. *Otolaryngol Head Neck Surg*. 2009;141:750–756.e1–2. IIa.
[370] Ponikau JU, Sherris DA, Weaver A, Kita H. Treatment of chronic rhinosinusitis with intranasal amphotericin B: a randomized, placebo-controlled, double-blind pilot trial. *J Allergy Clin Immunol*. 2005;115:125–131. Ib.
[371] Ebbens FA, Scadding GK, Badia L, et al. Amphotericin B nasal lavages: not a solution for patients with chronic rhinosinusitis. *J Allergy Clin Immunol*. 2006;118:1149–1156. Ib.

[372] Kennedy DW, Kuhn FA, Hamilos DL, et al. Treatment of chronic rhinosinusitis with high-dose oral terbinafine: a double blind, placebo-controlled study. *Laryngoscope*. 2005;115:1793–1799. Ib.
[373] Gevaert P, Lang-Loidolt D, Lackner A, et al. Nasal IL-5 levels determine the response to anti–IL-5 treatment in patients with nasal polyps. *J Allergy Clin Immunol*. 2006;118:1133–1141. Ib.
[374] Gevaert P, Van Bruaene N, Cattaert T, et al. Mepolizumab, a humanized anti–IL-5 mAb, as a treatment option for severe nasal polyposis. *J Allergy Clin Immunol*. 2011;128:989–995.e1–8. Ib.
[375] Proctor DF. The nose, paranasal sinuses and pharynx. In: Walters W, ed. *Lewis-Walters Practice of Surgery*. Hagerstown: WF Prior Co; 1966:1–37.
[376] Naumann H, ed. *Pathologische Anatomie der Chronischen Rhinitis und Sinusitis. Proceedings of the VIII International Congress of Oto-rhinolaryngology*. Amsterdam: Excerpta Medica; 1965.
[377] Kennedy D. Functional endoscopic sinus surgery: concepts, surgical indications and instrumentation. In: Kennedy D, Bolger WE, Zinreich SJ, eds. *Diseases of the Sinuses: Diagnosis and Management*. Hamilton, ON, Canada: Decker; 2001:197–210. IV.
[378] Harvey RJ, Goddard JC, Wise SK, Schlosser RJ. Effects of endoscopic sinus surgery and delivery device on cadaver sinus irrigation. *Otolaryngol Head Neck Surg*. 2008;139:137–142. IIb.
[379] Toth L, Csomor P, Sziklai I, Karosi T. Biofilm detection in chronic rhinosinusitis by combined application of hematoxylin-eosin and gram staining. *Eur Arch Otorhinolaryngol*. 2011;268:1455–1462. IIa.
[380] Moriyama H, Yanagi K, Otori N, Asai K, Fukami M. Healing process of sinus mucosa after endoscopic sinus surgery. *Am J Rhinol Allergy*. 1996;10:61–66. IIb.
[381] Smith TL, Kern R, Palmer JN, et al. Medical therapy vs surgery for chronic rhinosinusitis: a prospective, multi-institutional study with 1-year follow-up. *Int Forum Allergy Rhinol*. 2013;3:4–9. IIa.
[382] Kennedy DW. Prognostic factors, outcomes and staging in ethmoid sinus surgery. *Laryngoscope*. 1992;102(suppl 57):1–18. IIb.
[383] Khalid AN, Quraishi SA, Kennedy DW. Long-term quality of life measures after functional endoscopic sinus surgery. *Am J Rhinol*. 2004;18:131–136. IIb.
[384] Murr AH, Smith TL, Hwang PH, et al. Safety and efficacy of a novel bioabsorbable, steroid-eluting sinus stent. *Int Forum Allergy Rhinol*. 2011;1:23–32. Ib.
[385] Han JK, Marple BF, Smith TL, et al. Effect of steroid-releasing sinus implants on postoperative medical and surgical interventions: an efficacy meta-analysis. *Int Forum Allergy Rhinol*. 2012;2:271–279. Ia.
[386] Reh DD, Higgins TS, Smith TL. Impact of tobacco smoke on chronic rhinosinusitis: a review of the literature. *Int Forum Allergy Rhinol*. 2012;2:362–369. IIb.
[387] Longhini AB, Ferguson BJ. Clinical aspects of odontogenic maxillary sinusitis: a case series. *Int Forum Allergy Rhinol*. 2011;1:409–415. III.
[388] Ramakrishnan VR, Kingdom TT, Nayak JV, Hwang PH, Orlandi RR. Nationwide incidence of major complications in endoscopic sinus surgery. *Int Forum Allergy Rhinol*. 2012;2:34–39. III.
[389] Khalil HS, Nunez DA. Functional endoscopic sinus surgery for chronic rhinosinusitis. *Cochrane Database Syst Rev*. 2006;3:CD004458. IIa.
[390] Alobid I, Benitez P, Bernal-Sprekelsen M, et al. Nasal polyposis and its impact on quality of life: comparison between the effects of medical and surgical treatments. *Allergy*. 2005;60:452–458. Ib.
[391] Smith TL, Kern RC, Palmer JN, et al. Medical therapy vs surgery for chronic rhinosinusitis: a prospective, multi-institutional study. *Int Forum Allergy Rhinol*. 2011;1:235–241. IIb.
[392] Batra PS. Evidence-based practice: balloon catheter dilation in rhinology. *Otolaryngol Clin North Am*. 2012;45:993–1004. III.
[393] Plaza G, Eisenberg G, Montojo J, Onrubia T, Urbasos M, O'Connor C. Balloon dilation of the frontal recess: a randomized clinical trial. *Ann Otol Rhinol Laryngol*. 2011;120:511–518. Ib.
[394] Tomazic PV, Stammberger H, Braun H, et al. Feasibility of balloon sinuplasty in patients with chronic rhinosinusitis: the Graz experience. *Rhinology*. 2013;51:120–127. IIb.
[395] Koskinen A, Penttila M, Myller J, et al. Endoscopic sinus surgery might reduce exacerbations and symptoms more than balloon sinuplasty. *Am J Rhinol Allergy*. 2012;26:e150–e156. IIb.
[396] Marple BF, Smith TL, Han JK, et al. Advance II: a prospective, randomized study assessing safety and efficacy of bioabsorbable steroid-releasing sinus implants. *Otolaryngol Head Neck Surg*. 2012;146:1004–1011. Ib.
[397] Forwith KD, Chandra RK, Yun PT, Miller SK, Jampel HD. ADVANCE: a multisite trial of bioabsorbable steroid-eluting sinus implants. *Laryngoscope*. 2011;121:2473–2480. IIb.
[398] Bhattacharyya N, Jones DT, Hill M, Shapiro NL. The diagnostic accuracy of computed tomography in pediatric chronic rhinosinusitis. *Arch Otolaryngol Head Neck Surg*. 2004;130:1029–1032. IIa.
[399] Lund VJ, Mackay IS. Staging in rhinosinusitis. *Rhinology*. 1993;31:183–184. IV.
[400] Falagas ME, Giannopoulou KP, Vardakas KZ, Dimopoulos G, Karageorgopoulos DE. Comparison of antibiotics with placebo for treatment of acute sinusitis: a meta-analysis of randomised controlled trials. *Lancet Infect Dis*. 2008;8:543–552. Ia.
[401] Wald ER, Nash D, Eickhoff J. Effectiveness of amoxicillin/clavulanate potassium in the treatment of acute bacterial sinusitis in children. *Pediatrics*. 2009;124:9–15. Ib.
[402] Poachanukoon O, Kitcharoensakkul M. Efficacy of cefditoren pivoxil and amoxicillin/clavulanate in the treatment of pediatric patients with acute bacterial rhinosinusitis in Thailand: a randomized, investigator-blinded, controlled trial. *Clin Ther*. 2008;30:1870–1879. Ib.
[403] Pichichero ME, Casey JR. Safe use of selected cephalosporins in penicillin-allergic patients: a meta-analysis. *Otolaryngol Head Neck Surg*. 2007;136:340–347. Ia.
[404] Pichichero ME. A review of evidence supporting the American Academy of Pediatrics recommendation for prescribing cephalosporin antibiotics for penicillin-allergic patients. *Pediatrics*. 2005;115:1048–1057. IV.
[405] Meltzer EO, Charous BL, Busse WW, Zinreich SJ, Lorber RR, Danzig MR. Added relief in the treatment of acute recurrent sinusitis with adjunctive mometasone furoate nasal spray. The Nasonex Sinusitis Group. *J Allergy Clin Immunol*. 2000;106:630–637. Ib.
[406] Meltzer EO, Orgel HA, Backhaus JW, et al. Intranasal flunisolide spray as an adjunct to oral antibiotic therapy for sinusitis. *J Allergy Clin Immunol*. 1993;92:812–823. Ib.
[407] Shaikh N, Wald ER, Pi M. Decongestants, antihistamines and nasal irrigation for acute sinusitis in children. *Cochrane Database Syst Rev*. 2010;12:CD007909. Ia.
[408] Unuvar E, Tamay Z, Yildiz I, et al. Effectiveness of erdosteine, a second generation mucolytic agent, in children with acute rhinosinusitis: a randomized, placebo controlled, double-blinded clinical study. *Acta Paediatr*. 2010;99:585–589. Ib.
[409] Otten FW, Grote JJ. Treatment of chronic maxillary sinusitis in children. *Int J Pediatr Otorhinolaryngol*. 1988;15:269–278. IIa.
[410] Otten HW, Antvelink JB, Ruyter de Wildt H, Rietema SJ, Siemelink RJ, Hordijk GJ. Is antibiotic treatment of chronic sinusitis effective in children? *Clin Otolaryngol Allied Sci*. 1994;19:215–217. Ib.
[411] Don DM, Yellon RF, Casselbrant ML, Bluestone CD. Efficacy of a stepwise protocol that includes intravenous antibiotic therapy for the management of chronic sinusitis in children and adolescents. *Arch Otolaryngol Head Neck Surg*. 2001;127:1093–1098. III.
[412] Gawchik S, Goldstein S, Prenner B, John A. Relief of cough and nasal symptoms associated with allergic rhinitis by mometasone furoate nasal spray. *Ann Allergy Asthma Immunol*. 2003;90:416–421. Ib.
[413] Ratner PH, Meltzer EO, Teper A. Mometasone furoate nasal spray is safe and effective for 1-year treatment of children with perennial allergic rhinitis. *Int J Pediatr Otorhinolaryngol*. 2009;73:651–657. Ib.
[414] Schenkel EJ, Skoner DP, Bronsky EA, et al. Absence of growth retardation in children with perennial allergic rhinitis after one year of treatment with mometasone furoate aqueous nasal spray. *Pediatrics*. 2000;105:E22. Ib.
[415] Michel O, Essers S, Heppt WJ, Johannssen V, Reuter W, Hommel G. The value of Ems Mineral Salts in the treatment of rhinosinusitis in children. Prospective study on the efficacy of mineral salts versus xylometazoline in the topical nasal treatment of children. *Int J Pediatr Otorhinolaryngol*. 2005;69:1359–1365. Ib.
[416] Brietzke SE, Brigger MT. Adenoidectomy outcomes in pediatric rhinosinusitis: a meta-analysis. *Int J Pediatr Otorhinolaryngol*. 2008;72:1541–1545. Ia.
[417] Ramadan HH, Tiu J. Failures of adenoidectomy for chronic rhinosinusitis in children: for whom and when do they fail? *Laryngoscope*. 2007;117:1080–1083. III.
[418] Ramadan HH, Cost JL. Outcome of adenoidectomy versus adenoidectomy with maxillary sinus wash for chronic rhinosinusitis in children. *Laryngoscope*. 2008;118:871–873. IIb.
[419] Ramadan HH. Safety and feasibility of balloon sinuplasty for treatment of chronic rhinosinusitis in children. *Ann Otol Rhinol Laryngol*. 2009;118:161–165. IIb.
[420] Ramadan HH, Terrell AM. Balloon catheter sinuplasty and adenoidectomy in children with chronic rhinosinusitis. *Ann Otol Rhinol Laryngol*. 2010;119:578–582. IIa.
[421] Hebert RL II, Bent JP III. Meta-analysis of outcomes of pediatric functional endoscopic sinus surgery. *Laryngoscope*. 1998;108:796–799. Ia.
[422] Bothwell MR, Piccirillo JF, Lusk RP, Ridenour BD. Long-term outcome of facial growth after functional endoscopic sinus surgery. *Otolaryngol Head Neck Surg*. 2002;126:628–634. IIa.
[423] Chang PH, Lee LA, Huang CC, Lai CH, Lee TJ. Functional endoscopic sinus surgery in children using a limited approach. *Arch Otolaryngol Head Neck Surg*. 2004;130:1033–1036. III.