Current Allergy and Asthma Reports (2019) 19:35
https://doi.org/10.1007/s11882-019-0868-0

OTITIS (DP SKONER, SECTION EDITOR)

Charcot-Leyden Crystals in Eosinophilic Inflammation: Active Cytolysis Leads to Crystal Formation

Shigeharu Ueki[1] · Yui Miyabe[1,2] · Yamamoto Yohei[3] · Mineyo Fukuchi[1] · Makoto Hirokawa[1] · Lisa A. Spencer[4] · Peter F. Weller[5]

© Springer Science+Business Media, LLC, part of Springer Nature 2019

Abstract

Purpose of Review Charcot-Leyden crystals (CLCs), slender bipyramidal hexagonal crystals, were first described by Jean-Martin Charcot in 1853, predating Paul Ehrlich's "discovery" of eosinophils by 26 years. To date, CLCs are known as a classical hallmark of eosinophilic inflammation. CLC protein expresses palmitate cleaving lysophospholipase activity and is a member of the family of S-type lectins, galectin-10. We summarize current knowledge regarding the pathological observations of CLCs and their mechanism of generation focusing on eosinophil cell death.

Recent Findings The presence of CLCs in vivo has been consistently associated with lytic eosinophils. Recent evidence revealed that cytolysis represents the occurrence of extracellular trap cell death (ETosis), an active non-apoptotic cell death process releasing filamentous chromatin structure. Galectin-10 is a predominant protein present within the cytoplasm of eosinophils but not stored in secretory granules. Activated eosinophils undergo ETosis and loss of galectin-10 cytoplasmic localization results in intracellular CLC formation. Free galectin-10 released following plasma membrane disintegration forms extracellular CLCs. Of interest, galectin-10-containing extracellular vesicles are also released during ETosis. Mice models indicated that CLCs could be a novel therapeutic target for Th2-type airway inflammation.

Summary The concept of ETosis, which represents a major fate of activated eosinophils, expands our current understanding by which cytoplasmic galectin-10 is crystalized/externalized. Besides CLCs and free galectin-10, cell-free granules, extracellular chromatin traps, extracellular vesicles, and other alarmins, all released through the process of ETosis, have novel implications in various eosinophilic disorders.

Keywords Charcot-Leyden crystal · Degranulation · Extracellular traps · Eosinophils · Galectin-10

This article is part of the Topical Collection on *Otitis*

✉ Shigeharu Ueki
ueki-shige@nifty.com

1 Department of General Internal Medicine and Clinical Laboratory Medicine, Akita University Graduate School of Medicine, 1-1-1, Hondo, Akita 010-8543, Japan

2 Department of Otorhinolaryngology, Head & Neck Surgery, Akita University Hospital, Akita, Japan

3 Department of Molecular Pathology and Tumor Pathology, Akita University Graduate School of Medicine, Akita, Japan

4 Department of Pediatrics, University of Colorado School of Medicine, Denver, CO, USA

5 Divisions of Allergy and Inflammation and Infectious Diseases, Department of Medicine, Beth Israel Deaconess Medical Center, Harvard Medical School, Boston, MA, USA

Abbreviations

CLC	Charcot-Leyden crystal
CRSwNP	Chronic rhinosinusitis with nasal polyps
EETosis	Eosinophil extracellular trap cell death
ETosis	Extracellular trap cell death
ETs	Extracellular traps, DNA traps
EV	Extracellular vesicle
NETosis	Neutrophil extracellular trap cell death

Introduction

In 1853, slender needle-like crystals were first reported by Jean-Martin Charcot who found the crystals in cardiac blood and spleen of a patient with leukemia. In 1872, Ernst Viktor von Leyden also described similar crystals in the sputum of asthmatic patients. Of note, these observations predated Paul Ehrich's first description of

Published online: 15 June 2019

eosinophils in 1879. Later in 1914, Schwarz proposed the close relationship between eosinophils and the crystals (also see ref. [1–3] for CLC history). To date, Charcot-Leyden crystals (CLCs), slender bipyramidal hexagonal crystals (~100 μm in maximum length), have been recognized as a classical hallmark of eosinophilic inflammation in tissue and body fluid. However, our understanding has not been gone much beyond any definition of "byproduct of eosinophilic inflammation" for a long time. In this mini-review, we summarize the pathological literature and recent findings in the mechanisms of CLC production.

CLC Is Made by Crystallization of Galectin-10

Back in 1950, Ayres et al. reported CLC could be formed within a few seconds from eosinophils with a detergent and wetting agents [4]. CLCs were considered to be made by an unknown protein, and biochemical studies revealed CLC protein was highly insoluble at neutral pH and remarkably stable to various enzymes and exhibited a tendency toward non-covalent aggregates [5, 6]. CLC protein consisted of a 16.5-kDa markedly hydrophobic polypeptide, comprising 142 amino acids [7]. On the basis of chromatographic and other studies, CLC protein was found to exhibit lysophospholipase activity toward lysopalmitoyl phosphatidylcholine [8–10]. Later on, based on amino acid sequence and 3D structure, the CLC protein has been assigned to the galectin superfamily of S-type lectins, galectin-10 [3, 11, 12].

Of note, CLCs have not been found in non-human species and protein sequence comparison indicated they are likely human specific [13]. Crystals of similar shape were found in mice but are composed of a non-eosinophil-derived chitinase-like protein Ym1 [14]. An ovine orthologue, galectin-14, has been shown to be associated with eosinophilic inflammation, but it was not likely crystalized due to its structure that has little identity with galectin-10 (25% amino acid identity) [15, 16].

Considerable expression of galectin-10 mRNA and protein was identified in human eosinophils and basophils [12]. In eosinophils, galectin-10 is a major constituent comprising an estimated 7–10% of total cellular protein. Proteome analysis of peripheral blood eosinophils revealed that galectin-10 is the 5th most abundant protein among 7086 identified proteins [17]. Relatively recently, proteomic analysis identified the expression of galectin-10 in CD4+CD25+ regulatory T cells [18] and IL-22 producing CD4+ T cells [19]. Thus, the expression of galectin-10 has been exclusively described in a small part of human immune cells, i.e., eosinophils, basophils, and T cell subsets.

Pathological Features of CLCs

Pathological and cytological evidence has consistently indicated the presence of CLCs in tissue and body fluid coincident with local eosinophilia. In contrast, limited reports were available on basophil- or T cell–associated CLCs despite their galectin-10 expression. A recent report showed CLCs in a bone marrow biopsy from a T cell leukemia patient [20], likely due to the expression of galectin-10 in T cell blasts. CLCs have been observed at the sites of eosinophil infiltration in tissues, body fluids, and secretions in a variety of pathological condition, including non-allergic diseases (Table 1). As early as 1947, Samter stated that "numerous observations have established the relation between the presence of disintegrating eosinophilic leukocytes and Charcot-Leyden crystals" [2]. CLCs have been repeatedly described in association with "necrotic" or "damaged" cells ([21–25], Table 1). In addition, the presence of CLCs in nasal polyps from patients with eosinophilic chronic rhinosinusitis was associated with disease severity [26••].

Subcellular Localization of Galectin-10

Eosinophils are bone marrow–derived, terminally differentiated granulocytes. They lack dividing capacity; therefore, tissue eosinophils are supplied from the bloodstream. Once in the tissue, eosinophils act as remarkable secretory cells able to release a large and varied pool of cytotoxic granular proteins, mediators, and growth factors. These mediators are predominantly stored as preformed pools within secretory granules [27]. Live eosinophils release granular contents through exocytotic or piecemeal degranulation [28]. Eosinophils adherent to the surface of a large multicellular parasite have been shown to undergo exocytotic degranulation, wherein intracellular granules fuse with the plasma membrane, resulting in release of entire granule contents. By contrast, piecemeal degranulation differentially releases granule-derived proteins, as discrete secretory vesicles [29].

One early immunonanogold ultrastructural study localized CLC protein in crystalloid-free granules [30], although later study showed the presence of CLC protein mainly in the cytoplasm and in the euchromatin of the nucleus [31]. Our recent immunostaining study showed that galectin-10 is mainly localized in the cytoplasm but not in specific granules, both in peripheral blood and tissue eosinophils [26••]. Intracellular galectin-10 has been shown to play a role in Treg anergy and their suppressive capacities [18]; however, its functional roles in eosinophil cytoplasm are not yet known.

Cytolytic ETosis Mediates CLC Formation

Although eosinophil activation in inflamed foci appears to be associated with the presence of CLCs, little has been known about the actual mechanism of their production. Our recent study uncovered that cytoplasmic galectin-10 could be

Table 1 Presence of CLC in various pathological conditions

Disease categories	Diseases	Sites of the CLC detection	"Necrotic" condition	Phagocytosis by macrophages	Selected references
Infectious diseases	Suppurative lymphadenitis (bacterial)	Lymph node	P		Arora V.K. et al. Acta Cytol. 1997;41(2):409–12.
	Eosinophilic cystitis (*Klebsiella*)	Bladder			Popescu O.E. et al. Arch Pathol Lab Med. 2009;133(2):289–94.
	Hepatic abscess (amebic)	Liver	P		Miyagawa K. et al. Japanese Journal of Medical Technology 2017;66(3):483–8
	Hepatic abscess (paracytic)	Liver	P		Misra V. et al. J Cytol. 2009;26(2):77–9
	Trematodiasis (*Fasciola hepatica*)	Colon	P		Pehlivanoglu B. et al. Turk Patoloji Derg. 2016;32(2):82–90.
	Nematodosis (hookworm and *Strongyloides stercoralis*)	Feces			Wesolowska M. et al. Helminthologia 2018;55(2):166–72.
	Ascariasis Ascaris lumbricoides	Liver	P		Pinilla A.E. et al. Rev. Inst. Med. Trop. S. Paulo 2001;43(6):343–6.
	Anisakis	Gastrointestinal tract	P		Yantiss R.K. Mod Pathol. 2015;28(1) Suppl 1:S7–21.
Allergic diseases and others	Asthma	Sputum			Leyden E. Virchows Arch. Path. Anal. 1872;54:324–52.
	Allergic rhinitis	Mucus	P		Pantanowitz L. et al. Ear Nose Throat J. 2004;83(7):489–90
	Eosinophilic otitis media	Middle ear effusion	P		Murakami A. et al. Ann Otol Rhinol Laryngol. 2012;121(9):609–14.
	Eosinophilic chronic rhinosinusitis	Mucus, tissue	P	P	Ueki S et al. Blood. 2018; 132(20);2183-7.
	Eosinophilic mucin rhinosinusitis	Mucus	P		Ferguson B.J. Laryngoscope. 2000; 110(5 Pt 1):799–813
	Allergic aspergillus sinusitis	Mucus	P		Katzenstein A.L. et al. J Allergy Clin Immunol. 1983;72(1):89–93.
	Allergic bronchopulmonary aspergillosis	Mucus	P		Bosken C.H. et al. Am J Surg Pathol. 1988;12(3):216–22.
	Chronic eosinophilic pneumonia	Lung	P	P	Kanner R.E. et al. Chest 1977;71(1):95–8.
	Eosinophilic colitis	Colon		P	Lewis J.T. et al. Am J Surg Pathol. 2007;31(3):481–5.
	Kimura's disease and angiolymphoid hyperplasia with eosinophilia(ALHE)	Salivary gland, lymph node, etc.	P	P	Kuo T.T. et al. Am J Surg Pathol. 1988;12(11):843–54.
	Langerhans cell histiocytosis (eosinophilic granuloma)	Bone, soft tissue	P	P	Arora V.K. et al. Acta Cytol. 1997;41(2):409–12.
		Lymph node	P		Tan H.W. et al. J Clin Pathol. 2006;59(5):548–9.
	Eosinophilic granulomatosis with polyangiitis (Churg-Strauss syndrome)	Lymph node	P	P	Swanson E.J. et al. J Hematopathol. 2017;10(1):39–45.
	Pemphigus vegetans	Skin	P		Pinto G.M. et al. J Am Acad Dermatol. 1992;27 (2 Pt 2):281–4.
	Eosinophilic cholecystitis	Gallbladder	P		Fujibayashi M. et al. J Tokyo Wom Med Univ. 2010;80(3):77–82.
	Eosinophilic arthritis	Synovial fluid			Atanes A. et al. Scand J Rheumatol. 1996;25(3):183–5
	Sialodochitis fibrinosa	Discharged fluid			NemotoT. et al. Japanese Journal of Oral and Maxillofacial Surgery 2006;52(2):81–84.
	Eosinophilic myocarditis	Myocardium	P		Aoki Y. et al. Int J Legal Med. 1996;108(4):221–4.
	Chronic subdural hematoma	Hematoma capsule	P		Mueller W. et al. Neurosurg Rev. 1990;13(4):305–8.
Tumors of hematopoietic and lymphoid tissues	Acute myelogenous leukemia	Cardiac blood, spleen			Charcot J.M. Mem. Soc. Biol. 1853;5:44–50.
		Bone marrow	P		Vermeersch P. et al. Am J Hematol. 2007;82(11):1029.
	Chronic myelogenous leukemia	Bone marrow (lump in the left lumbar region)	P		Arora V.K. et al. Acta Cytol. 1997;41(2):409–12.
		Synovial fluid			del Blanco J. et al. J Rheumatol. 1991;18(12):1944.

Table 1 (continued)

Disease categories	Diseases	Sites of the CLC detection	"Necrotic" condition	Phagocytosis by macrophages	Selected references
	Chronic eosinophilic leukemia	Bone marrow			Kuk J.S. et al. Am J Hematol. 2006;81(6):458–61.
	Hypereosinophilic syndrome	Bone marrow	P		Pujol-Moix N. et al. Haematologica. 2003;88(9):e131.
		Liver	P		Ikeda H. et al. Gastroenterology Res. 2011;4(4):168–73.
		Renal tubule, urine			Hirszel P. et al. Am J Kidney Dis. 1988;12(4):319–22.
	Mastocytoma and systemic mastocytosis	Skin		P	Lao L.M. et al. J Dermatol Sci. 1998;17(3):198–204.
		Bone marrow		P	Alayed K.M. et al. Pathology. 2010;42(1):85–7.
	Lymphoma Hodgkin's disease	Lymph node	P		Carson H.J. et al. Leuk Lymphoma. 1996;23(1–2):153–7.
	T cell lymphoblastic lymphoma	Lymph node	P		Ali N.D. et al. Blood. 2017;129(3):394.
	Granulocytic(myeloid) sarcoma	Mandible, pubis	P	P	Strauchen J.A. et al. Arch Pathol Lab Med. 2002;126(1):85–6.
Solid tumors	Gastric carcinoma	Stomach			Caruso R.A. et al. Ultrastruct Pathol. 2012;36(3):139–44.
	Solid and papillary epithelial neoplasm of the pancreas	Pancreas	P		Dvorak A.M. et al. Lab Invest. 1990;62(5):608–15.
	Cystic teratoma	Pleural effusion			Krishnan S. et al. Acta Cytol. 1983;27(5):529–32.
	Melanoma	Tumor, myocardium, renal tubule, blood vessel, etc.			Dincsoy H.P. et al. Am J Clin Pathol. 1981;75(2):236–43.

P positive

crystalized and externalized through active cytolysis [26••]. As early as the 1860s, eosinophil cytolysis has been implicated the generation of abundant cell-free granules [32]. Several researchers have reported that local turnover of eosinophils in diseased tissue occurs through pathways other than apoptosis [33–35]. Eosinophil cytolysis has been described by different terms, such as lytic degranulation, necrosis, necrobiosis, cell lysis, and primary lysis, although the presence of cell-free eosinophil granules is often overlooked [36].

Nowadays, accumulating evidences revealed that cytolysis could represent the occurrence of extracellular trap cell death (ETosis) [37–39]. ETosis represents a suicidal cell death process originally found in human neutrophils (i.e., neutrophil extracellular trap cell death (NETosis)) [40]. Most cases of stimuli-induced ETosis are a NADPH oxidase–dependent process that leads to histone hypercitrulination primarily mediated by peptidylarginine deiminase 4 [41]. Unlike apoptosis that produces fragmented DNA, NETosis involves development of sticky chromatin structures (neutrophil extracellular traps (NETs)) through rupture of nuclear and plasma membranes (reviewed in [42]). In eosinophils, various stimuli including calcium ionophore, phorbol 12-myristate 13-acetate, IL-5/GM-CSF with platelet-activating factor, immunoglobulins, autoantibodies, and fungi can induce rapid (within 30 to 180 min) eosinophil ETosis (EETosis) [37, 43–47]. To date, EETosis has been implicated in a wide range of eosinophilic diseases, such as asthma [48, 49], allergic bronchopulmonary aspergillosis [50, 51], eosinophilic otitis [45, 52], eosinophilic chronic rhinosinusitis (chronic rhinosinusitis with nasal polyps (CRSwNP)) [38, 45, 53••], hypereosinophilic syndrome [26••, 37], Wells syndrome (eosinophilic cellulitis) [54], and chronic obstructive pulmonary diseases [55].

EETosis is akin to that of NETosis in terms of suicidal cell death that results in development of net-like chromatin [37]. However, it is noteworthy that EETosis has different attributes. In NETosis, granules are intracellularly disrupted before plasma membrane disintegration; therefore, NETs are associated with various antimicrobial, free but granule-derived proteins such as myeloperoxidase [40, 45]. On the other hand, intact eosinophil granules are released extracellularly in the process of EETosis; therefore, eosinophil extracellular traps (EETs) are often associated with membrane-bound cell-free

granules [26••, 37, 45, 50, 56]. Another difference between NETs is that EETs (including their nuclear-derived histones) are spared from endogenous protease digestion so that EETs consisted of intact and stable chromatin fibers [37, 45, 57–61]. Considering innate immune responses, staunch fibers might offer an advantage in terms of immobilizing large parasites and hampering them [62] and may also pathologically contribute to the highly viscous nature of eosinophil-dominant airway secretions [38, 45, 58].

Using isolated eosinophils, we tested the hypothesis that EETosis leads to CLC formation [26••]. In live eosinophils, galectin-10 was eccentrically located in the peripheral cytoplasm. During the process of ETosis, galectin-10 was homogeneously redistributed in the cytoplasm coincident with nuclear shape changes, followed by intracellular CLC formation [26••]. This is not likely due to de novo galectin-10 transcription, since this dynamic process occurs within 30–60 min. A recent study in neutrophils indicated that mechanical change of cell shape and nucleus/plasma membrane disintegration in NETosis is a passive process followed by an active biological process [63]. It is conceivable that in eosinophils, the change of galectin-10 distribution is due to loss of energy-dependent localization. Time-lapse imaging revealed that once intracellular crystallization has started, relatively small (< 10 μm) CLCs build up within 1–2 min. Finally, the plasma membrane ruptures and extracellular CLCs appear. As observed in human tissue and secretions, varied sizes of CLCs can be formed extracellularly when a high density of eosinophils is induced to undergo ETosis. EETosis-mediated CLC formation was also confirmed by others [53••]. Thus, galectin-10 can be crystallized by an ETosis-mediated process that (1) involved dynamic changes of intracellular localization and (2) increased extracellular concentration of free galectin-10 [26••].

Whether the primary role of CLC is cytotoxic or is more intricately involved in immunoregulatory processes remains to be elucidated [64]. Deposits of crystals are known to cause diverse of diseases, namely, crystallopathies [65]. Crystals (e.g., monosodium urate crystals) are sensed by innate immune cells through germline-encoded pattern recognition signaling receptors (PRRs) [66]. CLC-engulfing macrophages have been occasionally observed in tissue from eosinophilic diseases ([26••, 67–69], Table 1). Rodriguez-Alcazar et al. reported that CLCs can be recognized by the cytosolic PRR NLP3 inflammasome upon their macrophage phagocytosis, thereby inducing the release of the proinflammatory cytokine IL-1β in vitro and in vivo [70••]. Persson et al. has recently reported that CLCs could be therapeutic targets [53••]. Naïve mice received an intratracheal injection of CLCs showed an increase of inflammatory cytokines and neutrophil/monocyte influx in the airways. These effects were not observed by soluble galectin-10 injection. In addition, mice simultaneously injected CLCs with innocuous ovalbumin resulted in dendritic cell uptake and Th2-type responses. Interestingly, antibodies directed against key epitopes of the CLC crystallization interface dissolved CLCs and reversed crystal-driven inflammation, IgE synthesis, and bronchial hyperreactivity in a humanized mouse model of asthma [53••]. Thus, a new concept of CLC crystallopathy has emerged.

Extracellular Vesicles Contain Galectin-10

Extracellular vesicles (EVs), secreted small membrane-enclosed vesicles, encompass proteins, lipids, and nucleic acids and have emerged as important intercellular messengers present in all body fluids [71]. Recently, eosinophil EVs have been shown to be released by several inflammatory stimuli [72].

It is of interest that EETosis generates not only CLCs but also galectin-10-enclosed EVs [37]. During the temporal course of ETosis, eosinophils bud off plasma membrane–enveloped EVs that retain cytoplasmic contents including galectin-10 even after rupture of the originating cell [26••, 37, 53••]. The sizes of EETosis-mediated EVs are varied, approximately 200 to 5000 nm in diameter, which are relatively larger than live eosinophil–derived EVs (20 to 1000 nm) [72]. Unlike apoptotic bodies, EETosis-mediated EVs do not expose phosphatidylserine [37], a find-me signature for macrophage engulfment. Indeed, galectin-10-containing EVs were abundantly present in association with lytic eosinophils and CLCs in diseased tissue [26••]. Although their pathophysiological roles require future investigation, they might transfer their bioactive cargo to neighboring cells.

Extracellular Release of Free Galectin-10

In addition to EV and CLC production, plasma and nuclear membrane disintegration during the process of EETosis causes the bulk of cytoplasmic galectin-10 to be released in a soluble form. In vitro experiments showed that the free galectin-10 concentration in supernatant (free of cell debris, EVs, and crystals) is increased by EETosis and is completely reversed by NADPH oxidase inhibitors [26••]. Clinically, the increase of galectin-10 in inflammatory sites has been reported in several diseases, including nasal lavage fluid in patients with aspirin-sensitive respiratory disease [73], nasal fluid in allergic rhinitis [74], and sputum in asthma and allergic bronchopulmonary aspergillosis [53••, 75].

Live eosinophils' exocytosis and piecemeal degranulation release granule contents; in contrast, EETosis releases cytoplasmic granules as membrane-bound intact granules [37]. One can postulate that measuring local free galectin-10 might indicate the occurrence of eosinophil ETosis/cytolysis. In eosinophilic esophagitis, an electron microscopy study has shown that approximately 80% of eosinophils underwent cytolysis [76]. Furuta et al. measured the galectin-10

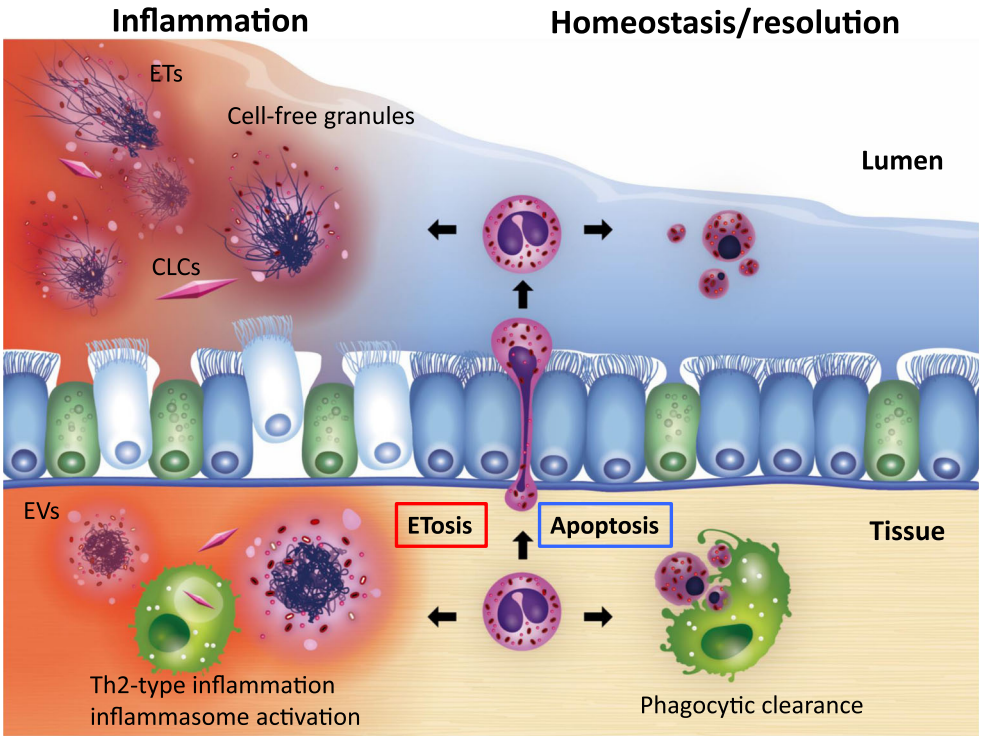

Figure 1 CLC formation and the fate of eosinophils in tissue and exudate. Eosinophils are selecting different types of cell death programs. Non-activated eosinophils undergo apoptosis, a physiologically important process for homeostatic removal of their toxic contents by phagocytes and mucociliary clearance. Activated eosinophils can undergo ETosis that produce CLCs, extracellular vesicles (EVs), extracellular traps (ETs), free granules, and other intracellular alarmins that worsen tissue damage and increase mucus viscosity.

concentration of esophageal luminal samples from eosinophilic esophagitis patients and found the concentration is well correlated with eosinophilic inflammation in tissue [77]. In eosinophilic chronic rhinosinusitis, ETotic eosinophils were shown to be abundantly present in the sinus secretions [38, 45]. Most recently, Wu et al. reported the concentration of galectin-10 in nasal secretions from CRSwNP patients [78]. After 2-week oral glucocorticosteroid treatment, they divided patient groups into responders and non-responders according to nasal polyp score. Strikingly, the average concentration of galectin-10 before glucocorticosteroid treatment was 160 times higher in the responder group compared with the non-responder group. Multivariate analysis revealed that galectin-10 concentration holds potential for predicting responders [78].

Galectin-10 is clearly externalized at sites of inflammation but no obvious targeting ligands have been found yet. Galectins have been linked to immunity, regulating cytokine production, receptor signaling, apoptosis, activation, and migration of leukocytes [15, 79–81]. Among them, galectin-1, 3, and 9 have been shown to regulate eosinophil recruitment, activation, and apoptosis (see review [82]).

Concluding Remarks

Leyden's original manuscript indicated numerous granule-like structures and slender crystals in sputum samples from asthmatic patients. A contemporary interpretation for his observation is the occurrence of ETosis-mediated eosinophil cytolysis accompanied by crystallization of galectin-10. The concept of proinflammatory EETosis and physiological apoptosis expands our current understanding of eosinophil fate in tissues and secretions (Fig. 1). Active production of CLCs, cell-free granules, extracellular traps, EVs, galectin-10, and released alarmins is a previously underappreciated phenomenon. Further studies on postmortem biological activities of eosinophils and CLC crystallopathy will contribute to a novel perspective on various eosinophil-associated diseases.

Acknowledgments The authors are grateful to Satomi Misawa for outstanding assistance in drawing the figure.

Funding Information This study was funded in part by a Research Grant on Allergic Disease and Immunology from the Japan Agency for Medical Research and Development (JP19ek0410055), Charitable Trust Laboratory Medicine Research Foundation of Japan, Japanese Society of Laboratory Medicine Fund for Promotion of Scientific Research, and JSPS KAKENHI 15KK0329, 16K08926 (SU), NIH R37AI020241 (PFW), and NIH R01AI121186 (LAS).

Compliance with Ethical Standards

Conflict of Interest The authors declare that they have no conflict of interest.

Human and Animal Rights and Informed Consent This article does not contain any studies with human or animal subjects performed by any of the authors.

References

Papers of particular interest, published recently, have been highlighted as:
•• Of major importance

1. Sakula A. Charcot-Leyden crystals and Curschmann spirals in asthmatic sputum. Thorax. 1986;41(7):503–7.
2. Samter M. Charcot-Leyden crystals. J Allergy. 1947;18(4):221–30.
3. Su J. A brief history of Charcot-Leyden crystal protein/galectin-10 research. Molecules. 2018;23(11).
4. Ayres WW, Starkey NM. Studies on Charcot-Leyden crystals. Blood. 1950;5(3):254–66.
5. Dawe CJ, Williams WL. Histochemical studies of Charcot-Leyden crystals. Anat Rec. 1953;116(1):53–74.
6. Ackerman SJ, Loegering DA, Gleich GJ. The human eosinophil Charcot-Leyden crystal protein: biochemical characteristics and measurement by radioimmunoassay. J Immunol. 1980;125(5): 2118–26.
7. Ackerman SJ, Corrette SE, Rosenberg HF, Bennett JC, Mastrianni DM, Nicholson-Weller A, et al. Molecular cloning and characterization of human eosinophil Charcot-Leyden crystal protein (lysophospholipase). Similarities to IgE binding proteins and the S-type animal lectin superfamily. J Immunol. 1993;150(2):456–68.
8. Weller PF, Bach D, Austen KF. Human eosinophil lysophospholipase: the sole protein component of Charcot-Leyden crystals. J Immunol. 1982;128(3):1346–9.
9. Weller PF, Goetzl EJ, Austen KF. Identification of human eosinophil lysophospholipase as the constituent of Charcot-Leyden crystals. Proc Natl Acad Sci U S A. 1980;77(12):7440–3.
10. Weller PF, Bach DS, Austen KF. Biochemical characterization of human eosinophil Charcot-Leyden crystal protein (lysophospholipase). J Biol Chem. 1984;259(24):15100–5.
11. Leonidas DD, Elbert BL, Zhou Z, Leffler H, Ackerman SJ, Acharya KR. Crystal structure of human Charcot–Leyden crystal protein, an eosinophil lysophospholipase, identifies it as a new member of the carbohydrate-binding family of galectins. Structure. 1995;3(12):1379–93.
12. Acharya KR, Ackerman SJ. Eosinophil granule proteins: form and function. J Biol Chem. 2014;289(25):17406–15.
13. Choi E, Miller AD, Devenish E, Asakawa M, McConkey M, Peters-Kennedy J. Charcot-Leyden crystals: do they exist in veterinary species? A case report and literature review. J Vet Diagn Investig. 2017;29(6):904–9.
14. Guo L, Johnson RS, Schuh JC. Biochemical characterization of endogenously formed eosinophilic crystals in the lungs of mice. J Biol Chem. 2000;275(11):8032–7.
15. Dunphy JL, Barcham GJ, Bischof RJ, Young AR, Nash A, Meeusen EN. Isolation and characterization of a novel eosinophil-specific galectin released into the lungs in response to allergen challenge. J Biol Chem. 2002;277(17):14916–24.
16. Young AR, Barcham GJ, Kemp JM, Dunphy JL, Nash A, Meeusen EN. Functional characterization of an eosinophil-specific galectin, ovine galectin-14. Glycoconj J. 2009;26(4):423–32.
17. Wilkerson EM, Johansson MW, Hebert AS, Westphall MS, Mathur SK, Jarjour NN, et al. The peripheral blood eosinophil proteome. J Proteome Res. 2016;15(5):1524–33.
18. Kubach J, Lutter P, Bopp T, Stoll S, Becker C, Huter E, et al. Human CD4+CD25+ regulatory T cells: proteome analysis identifies galectin-10 as a novel marker essential for their anergy and suppressive function. Blood. 2007;110(5):1550–8.
19. Noh S, Jin S, Park CO, Lee YS, Lee N, Lee J, et al. Elevated galectin-10 expression of IL-22-producing T cells in patients with atopic dermatitis. J Investig Dermatol. 2016;136(1):328–31.
20. Ali ND, Weissmann D. Charcot-Leyden crystals in T-cell lymphoblastic lymphoma. Blood. 2017;129(3):394.
21. Staribratova D, Belovejdov V, Staikov D, Dikov D. Demonstration of Charcot-Leyden crystals in eosinophilic cystitis. Archives of pathology & laboratory medicine. 2010;134(10):1420.
22. Manny JS, Ellis LR. Acute myeloid leukemia with Charcot-Leyden crystals. Blood. 2012;120(3):503.
23. Ikeda H, Katayanagi K, Kurumaya H, Harada K, Sato Y, Sasaki M, et al. A case of hypereosinophilia-associated multiple mass lesions of liver showing non-granulomatous eosinophilic hepatic necrosis. Gastroenterol Res. 2011;4(4):168–73.
24. Thakral D, Agarwal P, Saran RK, Saluja S. Significance of Charcot Leyden crystals in liver cytology-a case report. Diagn Cytopathol. 2015;43(5):392–4.
25. Muller W, Firsching R. Significance of eosinophilic granulocytes in chronic subdural hematomas. Neurosurg Rev. 1990;13(4):305–8.
26.•• Ueki S, Tokunaga T, Melo RCN, Saito H, Honda K, Fukuchi M, et al. Charcot-Leyden crystal formation is closely associated with eosinophil extracellular trap cell death. Blood. 2018;132(20):2183–7 **This research reveals an active process by which Charcot-Leyden crystals are formed in eosinophilic diseases**.
27. Melo RCN, Weller PF. Contemporary understanding of the secretory granules in human eosinophils. J Leukoc Biol. 2018;104(1):85–93.
28. Weller PF, Spencer LA. Functions of tissue-resident eosinophils. Nat Rev Immunol. 2017;17(12):746–60.
29. Spencer LA, Bonjour K, Melo RC, Weller PF. Eosinophil secretion of granule-derived cytokines. Front Immunol. 2014;5:496.
30. Dvorak AM, Letourneau L, Login GR, Weller PF, Ackerman SJ. Ultrastructural localization of the Charcot-Leyden crystal protein (lysophospholipase) to a distinct crystalloid-free granule population in mature human eosinophils. Blood. 1988;72(1):150–8.
31. Calafat J, Janssen H, Knol EF, Weller PF, Egesten A. Ultrastructural localization of Charcot-Leyden crystal protein in human eosinophils and basophils. Eur J Haematol. 1997;58(1):56–66.
32. Erjefalt JS, Persson CG. New aspects of degranulation and fates of airway mucosal eosinophils. Am J Respir Crit Care Med. 2000;161(6):2074–85.
33. Watanabe K, Misu T, Inoue S, Edamatsu H. Cytolysis of eosinophils in nasal secretions. Ann Otol Rhinol Laryngol. 2003;112(2):169–73.
34. Uller L, Andersson M, Greiff L, Persson CG, Erjefalt JS. Occurrence of apoptosis, secondary necrosis, and cytolysis in eosinophilic nasal polyps. Am J Respir Crit Care Med. 2004;170(7):742–7.
35. Persson C, Ueki S. Lytic eosinophils produce extracellular DNA traps as well as free eosinophil granules. J Allergy Clin Immunol. 2018;141(3):1164.
36. Persson CG, Erjefalt JS. Eosinophil lysis and free granules: an in vivo paradigm for cell activation and drug development. Trends Pharmacol Sci. 1997;18(4):117–23.
37. Ueki S, Melo RC, Ghiran I, Spencer LA, Dvorak AM, Weller PF. Eosinophil extracellular DNA trap cell death mediates lytic release of free secretion-competent eosinophil granules in humans. Blood. 2013;121(11):2074–83.
38. Ueki S, Tokunaga T, Fujieda S, Honda K, Hirokawa M, Spencer LA, et al. Eosinophil ETosis and DNA traps: a new look at eosinophilic inflammation. Curr Allergy Asthma Rep. 2016;16(8):54.
39. Choi Y, Lee Y, Park HS. Which factors associated with activated eosinophils contribute to the pathogenesis of aspirin-exacerbated respiratory disease? Allergy Asthma Immunol Res. 2019;11(3):320–9.
40. Fuchs TA, Abed U, Goosmann C, Hurwitz R, Schulze I, Wahn V, et al. Novel cell death program leads to neutrophil extracellular traps. J Cell Biol. 2007;176(2):231–41.
41. Sorensen OE, Borregaard N. Neutrophil extracellular traps - the dark side of neutrophils. J Clin Invest. 2016;126(5):1612–20.
42. Brinkmann V. Neutrophil extracellular traps in the second decade. J Innate Immun. 2018;10(5–6):414–21.

43. Fukuchi M, Ueki S, Saito H, Miyabe Y, Konno Y, Omokawa A, et al. Comparison of CD16-negative selection vs. MACSxpress system for isolation of blood eosinophils. Allergol Int. 2019.
44. Yamauchi Y, Ueki S, Konno Y, Ito W, Takeda M, Nakamura Y, et al. The effect of hepatocyte growth factor on secretory functions in human eosinophils. Cytokine. 2016;88:45–50.
45. Ueki S, Konno Y, Takeda M, Moritoki Y, Hirokawa M, Matsuwaki Y, et al. Eosinophil extracellular trap cell death-derived DNA traps: their presence in secretions and functional attributes. J Allergy Clin Immunol. 2016;137(1):258–67.
46. Mukherjee M, Lacy P, Ueki S. Eosinophil extracellular traps and inflammatory pathologies-untangling the web! Front Immunol. 2018;9:2763.
47. Hellmark T, Ohlsson S, Pettersson A, Hansson M, Johansson ACM. Eosinophils in anti-neutrophil cytoplasmic antibody associated vasculitis. BMC Rheumatol. 2019;3:9.
48. Mukherjee M, Bulir DC, Radford K, Kjarsgaard M, Huang CM, Jacobsen EA, et al. Sputum autoantibodies in patients with severe eosinophilic asthma. J Allergy Clin Immunol. 2018;141(4):1269–79.
49. Choi Y, Le Pham D, Lee DH, Lee SH, Kim SH, Park HS. Biological function of eosinophil extracellular traps in patients with severe eosinophilic asthma. Exp Mol Med. 2018;50(8):104.
50. Muniz VS, Silva JC, Braga YAV, Melo RCN, Ueki S, Takeda M, et al. Eosinophils release extracellular DNA traps in response to Aspergillus fumigatus. J Allergy Clin Immunol. 2018;141(2): 571–85 e7.
51. Omokawa A, Ueki S, Kikuchi Y, Takeda M, Asano M, Sato K, et al. Mucus plugging in allergic bronchopulmonary aspergillosis: implication of the eosinophil DNA traps. Allergol Int. 2018;67(2):280–2.
52. Ohta N, Ueki S, Konno Y, Hirokawa M, Kubota T, Tomioka-Matsutani S, et al. ETosis-derived DNA trap production in middle ear effusion is a common feature of eosinophilic otitis media. Allergol Int. 2018;67(3):414–6.
53.•• Persson EK, Verstraete K, Heyndrickx I, Gevaert E, Aegerter H, Percier J-M, et al. Protein crystallization promotes type 2 immunity and is reversible by antibody treatment. Science. 2019;364(6442) **This study shows the first demonstration of CLC-dissolving antibody as a therapeutic modality for CLC-triggered Th2 airway inflammation**.
54. Wouters J, Waelkens E, Vandoninck S, Segaert S, van den Oord JJ. Mass spectrometry of flame figures. Acta Derm Venereol. 2015;95(6):734–5.
55. Uribe Echevarria L, Leimgruber C, Garcia Gonzalez J, Nevado A, Alvarez R, Garcia LN, et al. Evidence of eosinophil extracellular trap cell death in COPD: does it represent the trigger that switches on the disease? Int J Chron Obstruct Pulmon Dis. 2017;12:885–96.
56. Muniz VS, Baptista-Dos-Reis R, Neves JS. Functional extracellular eosinophil granules: a bomb caught in a trap. Int Arch Allergy Immunol. 2013;162(4):276–82.
57. Ueki S, Ohta N, Takeda M, Konno Y, Hirokawa M. Eosinophilic otitis media: the aftermath of eosinophil extracellular trap cell death. Curr Allergy Asthma Rep. 2017;17(5):33.
58. Ueki S, Hebisawa A, Kitani M, Asano K, Neves JS. Allergic bronchopulmonary aspergillosis–a luminal hypereosinophilic disease with extracellular trap cell death. Front Immunol. 2018;9.
59. Papayannopoulos V, Staab D, Zychlinsky A. Neutrophil elastase enhances sputum solubilization in cystic fibrosis patients receiving DNase therapy. PLoS One. 2011;6(12):e28526.
60. Brinkmann V, Reichard U, Goosmann C, Fauler B, Uhlemann Y, Weiss DS, et al. Neutrophil extracellular traps kill bacteria. Science. 2004;303(5663):1532–5.
61. Urban CF, Ermert D, Schmid M, Abu-Abed U, Goosmann C, Nacken W, et al. Neutrophil extracellular traps contain calprotectin, a cytosolic protein complex involved in host defense against Candida albicans. PLoS Pathog. 2009;5(10):e1000639.
62. Munoz-Caro T, Rubio RM, Silva LM, Magdowski G, Gartner U, McNeilly TN, et al. Leucocyte-derived extracellular trap formation significantly contributes to Haemonchus contortus larval entrapment. Parasit Vectors. 2015;8:607.
63. Neubert E, Meyer D, Rocca F, Gunay G, Kwaczala-Tessmann A, Grandke J, et al. Chromatin swelling drives neutrophil extracellular trap release. Nat Commun. 2018;9(1):3767.
64. Klion AD. Charcot-Leyden crystals: solving an enigma. Blood. 2018;132(20):2111–2.
65. Mulay SR, Anders HJ. Crystallopathies. N Engl J Med. 2016;374(25):2465–76.
66. So AK, Martinon F. Inflammation in gout: mechanisms and therapeutic targets. Nat Rev Rheumatol. 2017;13(11):639–47.
67. Lao LM, Kumakiri M, Nakagawa K, Ishida H, Ishiguro K, Yanagihara M, et al. The ultrastructural findings of Charcot-Leyden crystals in stroma of mastocytoma. J Dermatol Sci. 1998;17(3):198–204.
68. Dvorak AM, Furitsu T, Letourneau L, Ishizaka T, Ackerman SJ. Mature eosinophils stimulated to develop in human cord blood mononuclear cell cultures supplemented with recombinant human interleukin-5. Part I. Piecemeal degranulation of specific granules and distribution of Charcot-Leyden crystal protein. Am J Pathol 1991;138(1):69–82.
69. Swanson EJ, Manivel JC, Valen PA, Mesa H. Necrotizing eosinophilic granulomatous lymphadenitis with ring- and C-shaped granulomas—an underrecognized specific manifestation of nodal Churg-Strauss syndrome. J Hematop. 2017;10(1):39–45.
70.•• Rodriguez-Alcazar JF, Ataide MA, Engels G, Schmitt-Mabmunyo C, Garbi N, Kastenmuller W, et al. Charcot-Leyden crystals activate the NLRP3 inflammasome and cause IL-1beta inflammation in human macrophages. J Immunol. 2019;202(2):550–8 **This study shows the first demonstration of functional roles of CLCs**.
71. Wahlund CJE, Eklund A, Grunewald J, Gabrielsson S. Pulmonary extracellular vesicles as mediators of local and systemic inflammation. Front Cell Dev Biol. 2017;5:39.
72. Akuthota P, Carmo LAS, Bonjour K, Murphy RO, Silva TP, Gamalier JP, et al. Extracellular microvesicle production by human eosinophils activated by "inflammatory" stimuli. Front Cell Dev Biol. 2016;4.
73. Negrete-Garcia MC, Jimenez-Torres CY, Alvarado-Vasquez N, Montes-Vizuet AR, Velazquez-Rodriguez JR, Jimenez-Martinez MC, et al. Galectin-10 is released in the nasal lavage fluid of patients with aspirin-sensitive respiratory disease. ScientificWorldJournal. 2012;2012:474020.
74. Ghafouri B, Irander K, Lindbom J, Tagesson C, Lindahl M. Comparative proteomics of nasal fluid in seasonal allergic rhinitis. J Proteome Res. 2006;5(2):330–8.
75. Chua JC, Douglass JA, Gillman A, O'Hehir RE, Meeusen EN. Galectin-10, a potential biomarker of eosinophilic airway inflammation. PLoS One. 2012;7(8):e42549.
76. Saffari H, Hoffman LH, Peterson KA, Fang JC, Leiferman KM, Pease LF 3rd, et al. Electron microscopy elucidates eosinophil degranulation patterns in patients with eosinophilic esophagitis. J Allergy Clin Immunol. 2014;133(6):1728–34 e1.
77. Furuta GT, Kagalwalla AF, Lee JJ, Alumkal P, Maybruck BT, Fillon S, et al. The oesophageal string test: a novel, minimally invasive method measures mucosal inflammation in eosinophilic oesophagitis. Gut. 2013;62(10):1395–405.
78. Wu D, Yan B, Wang Y, Zhang L, Wang C. Charcot-Leyden crystal concentration in nasal secretions predicts clinical response to glucocorticoids in chronic rhinosinusitis with nasal polyps. J Allergy Clin Immunol. 2019.
79. Pace KE, Hahn HP, Pang M, Nguyen JT, Baum LG. Cutting edge: CD7 delivers a pro-apoptotic signal during galectin-1-induced T cell death. J Immunol. 2000;165(5):2331–4.

80. Chung CD, Patel VP, Moran M, Lewis LA, Miceli MC. Galectin-1 induces partial TCR -chain phosphorylation and antagonizes processive TCR signal transduction. J Immunol. 2000;165(7): 3722–9.
81. Sano H, Hsu DK, Yu L, Apgar JR, Kuwabara I, Yamanaka T, et al. Human galectin-3 is a novel chemoattractant for monocytes and macrophages. J Immunol. 2000;165(4):2156–64.
82. Rao SP, Ge XN, Sriramarao P. Regulation of eosinophil recruitment and activation by galectins in allergic asthma. Front Med (Lausanne). 2017;4:68.

Publisher's Note Springer Nature remains neutral with regard to jurisdictional claims in published maps and institutional affiliations.