For reprint orders, please contact reprints@expert-reviews.com

Expert Reviews

An update on the immunopathogenesis of eosinophilic esophagitis

Expert Rev. Gastroenterol. Hepatol. 4(2), 141–148 (2010)

Alfredo J Lucendo† and Baltasar Lucendo

†*Author for correspondence*
Department of Gastroenterology, Hospital General de Tomelloso, Vereda de Socuéllamos, s/n, 13700 Tomelloso, Spain
Tel.: +34 926 525 927
Fax: +34 926 525 870
alucendo@vodafone.es

Eosinophilic esophagitis (EoE) is a chronic clinicopathological entity characterized by large numbers of intraepithelial eosinophils infiltrating the esophageal mucosa, which is not caused by gastroesophageal reflux. This disease has become widely recognized over the past few years and new methods have been developed to reveal its underlying pathophysiological mechanisms. Owing to the high prevalence of food and/or airborne allergen sensitization in EoE patients, the allergic nature of the disease had to be defined, which has certain factors in common with other IgE-dependent entities, such as bronchial asthma or allergic rhinitis. Of these, some cytokines and chemokines previously studied in asthma have also been implicated in molecular mechanisms causing eosinophil-rich esophageal inflammation. However, the role played by IgE in relation to the esophageal eosinophilic infiltrate must be clarified, together with the possible function of mast cells in the inflammatory infiltrate and its activation stimuli. A putative role has also been recently suggested for gastroesophageal reflux in the origin of EoE that should be profoundly analyzed, together with the role of specific genes implicated in other digestive inflammatory disorders. This article reviews recent advances in the immunopathogenesis of EoE, which should also consider other pathways to activate the esophageal mucosal immune system.

Keywords: allergy • eosinophilic esophagitis • food allergy • immunopathogenesis • inflammation

Eosinophilic esophagitis (EoE) is a chronic inflammatory clinicopathological entity characterized by the presence of large numbers of intraepithelial eosinophils in esophageal mucosal biopsies. EoE was first described more than 25 years ago and is recognized as the most common eosinophilic gastrointestinal disease (EGID). Patients usually present with dysphagia and other esophageal symptoms, which seem to be caused by the inflammatory response and not anatomic obstruction [1,2].

Eosinophilic esophagitis has often been associated with atopic manifestations, and gastroesophageal reflux disease (GERD) was rarely linked to this condition [1,2]. The intraepithelial esophageal eosinophil density observed in EoE is much higher than in certain patients with GERD [3]; nevertheless both entities can coexist in the same patient. In this case, the symptoms and pathologic features are usually unresponsive to acid suppression treatment.

Eosinophilic esophagitis is diagnosed by esophageal and/or upper GI tract symptoms accompanied by 15 or more intraepithelial eosinophils/high-power field in one or more biopsy specimens without pathologic GERD, as shown by normal pH monitoring of the distal esophagus or the lack of response to high-dose proton pump inhibitor medication [4].

Together with eosinophils, T lymphocytes and mast cells can also be identified in the esophageal inflammatory infiltrate using specific immunostaining techniques. This inflammatory infiltration shows histopathological changes in the esophageal structure and various motor disorders objectively evaluated by manometry that are responsible for the patients' symptoms.

The growing recognition of EoE in recent years has led to a progressive rise in related international publications. This has helped to clarify many aspects of its epidemiology and clinical manifestations. Although light has been shed on the physiopathology of EoE, there are some questions that remain unanswered.

This article reviews the current knowledge of the physiopathology of EoE in the published literature and suggests new avenues for conducting further research into its etiopathogenic mechanisms.

 10.1586/EGH.10.9 © 2010 Expert Reviews Ltd ISSN 1747-4124

EoE as a digestive allergic disease

Eosinophilic esophagitis is considered to be an atopy-associated inflammatory disorder. Allergies have been linked to its origin for several reasons because most patients have a family history of bronchial asthma or allergic rhinitis; atopic dermatitis; hypersensitivity to drugs, food or airborne allergens; blood eosinophilia; or elevated serum IgE levels [5–7], thereby leading to the use of the term 'allergic eosophagitis' [8].

Positive skin-prick responses and radioallergosorbent test results have generally been observed in patients with EoE who usually respond in a satisfactory clinical and histopathological manner to therapies used in other allergic diseases. In 1995 Kelly *et al.* provided firm evidence of the immunoallergic origin of EoE and reported that the histological lesions and symptoms of pediatric patients following elemental amino acid-based diets lacking antigenic capacity had been resolved [9]. The potential role of airborne allergens must be considered in EoE, because seasonal variations regarding its diagnosis have been correlated with the seasonal pollen count [10].

From an epidemiological point of view, it could be said that over the past few decades EoE has become increasingly prevalent in numerous populations, in parallel to the rising incidence of bronchial asthma and many others allergic diseases in common geographical areas. Over the past 10 years, there has been an 18-fold rise in the prevalence of EoE in Australia [11] and a 35-fold rise in Philadelphia, USA [12]. The hygiene hypothesis provided a general explanation for the increase in EGIDs and allergic diseases, parallel to a decrease in infectious diseases: reduced exposure to microorganisms during childhood has modified the patterns of gut microflora, leading to a change in the fine tuning of T helper-cell (Th)1, Th2 and Treg responses. As a result, there is an imbalance of the immune system and a predisposition to develop allergic and autoimmune disorders that are triggered by altered or missing innate immune cell activation [13].

Eosinophil accumulation & Th2 responses

A Th2-type response is associated with the pathogenesis of EoE because T cells, IL-5 expression, eosinophils and positive IgE-immunostaining were shown to characterize esophageal inflammatory infiltration [14]. Th2-type responses are mediated by Th CD4 cells and driven by cytokines, such as IL-4, -5, -9 and -13, whose potential role in EoE has been researched.

IL-5 plays an integral role in inducing eosinophilic inflammation [15–17]. It is an important factor to regulate the proliferation, differentiation, survival and activation, not only of eosinophils, but also of Th cell lymphocytes and mast cells in chronic allergic reactions. IL-5 has also been clearly implicated in the physiopathology of allergic asthma [16,17] and the fibrous remodeling phenomena that occurs in bronchial [18] and cutaneous [19] inflammation.

Experimental murine models of EoE have shown that an overactive Th2-mediated response is required to induce the disorder. Research involving transgenic mice that overexpressed IL-5 showed an increase in circulating blood eosinophils and an intense accumulation of eosinophils in the esophageal lamina propria and small intestine, which was proportional to the serum concentration of IL-5 [20,21] when stimulated with inhaled [22,23] or epicutaneous allergens [24]. By contrast, IL-5-deficient mice did not develop EoE when exposed to airborne allergens [23].

Moreover, the blood lymphocytes of patients with EoE produce significantly higher levels of IL-5 following stimulation *in vitro* compared with normal controls [25]. Also, the percentage of blood-circulating IL-5$^+$ CD4 T cells correlates with the severity of esophageal tissue eosinophilia [26].

Even though some evidence has shown the central role of IL-5 in the molecular mechanisms of EoE, the anti-IL-5 humanized monoclonal antibody mepolizumab appears to have a limited therapeutic effect in EoE adult patients [27]. In a randomized placebo-controlled double-blind trial, this drug significantly reduced the eosinophil density of esophageal tissues by approximately 50%; however, there was no further reduction in eosinophils once the dosage was increased. Mepolizumab failed to modify mast cell or T lymphocyte density in the esophageal mucosa, but changes in the expression of molecules associated with esophageal remodeling were reversed. EoE patients showed minimal clinical improvement. As suggested by researchers, clinical improvement in EoE could be determined by eosinophil tissue depletion, which might require more than one targeting single molecule to be controlled simultaneously [27]. In light of these data, the effect of IL-5 in itself might not be enough to explain the molecular pathology of EoE. We should consider the synergistic effect of other factors, particularly in a subgroup of patients who do not apear to overexpress IL-5 [28].

Other Th2-type cytokines have also been studied in EoE. IL-13, an immunoregulatory cytokine involved in several allergic diseases, has been widely researched. IL-13 is expressed by the blood eosinophils of patients suffering from several eosinophilic inflammatory disorders including EoE [29] and has been suggested as a major regulator of the molecular pathways leading to EoE. A 16-fold increase in IL-13 mRNA expression has been observed in EoE patients compared with healthy subjects. Moreover, human esophageal epithelial cell cultures stimulated with IL-13 are capable of partially reproducing the characteristic EoE transcriptome [30], which can be reversed after topical steroid treatment in parallel to a significant reduction in IL-13 mRNA expression levels [30]. IL-13 also determined enhanced gene transcription of the eosinophil-activating chemoattractants eotaxin-1/CCL11 and eotaxin-3/CCL26 [31], operating through the nuclear transcription factor STAT6 (which has a central role in Th2 cell differentiation) [30]. Concordant results have been obtained from murine models of EoE: intratracheal IL-13 delivery induced experimental EoE [32], IL-13-deficient mice had attenuated degrees of allergen-induced experimental EoE [24] and mice with a targeted deletion of STAT6 are partially protected from allergen- and IL-13-induced experimental EoE. All of these results confirm the central role played by this cytokine in the development of the disease.

Th2 lymphocytes are powerful activators of the production of antibodies by B cells, especially IgE, through the stimulation of IL-4 and -13 [33]. We have evidence of local IgE production and class switching to IgE in the esophageal mucosa of EoE

patients: recent research has shown an increased expression of germline transcripts and IgE heavy chain compared with control individuals [34].

The role of eotaxins in EoE

The potential role of eotaxins in the physiopathology of EoE was recently analyzed. Eotaxins are a subfamily of chemokines with eosinophil-selective chemoattractant activity and are composed of three molecules named eotaxin-1, -2 and -3, which all interact with the same CCR-3 receptor primarily found in these leukocytes [35]. CCR-3 deficient mice were prevented from developing experimental EoE [36] and human patients with EoE showed elevated CCR-3 expression in peripheral blood eosinophils compared with nonatopic controls [26].

Eotaxin expression is mainly induced by the Th2 cytokines IL-4 and -13 [32,37]. Eotaxin-1/CCL11, which is ubiquitously expressed in the digestive tract, is the most widely studied chemokine. Its mRNA can be isolated from the mononuclear resident cells in the lamina propria of the small intestine, which has the highest number of gastrointestinal resident eosinophils in normal conditions. Eotaxin-1 appears to be essential for recruiting eosinophils to the GI tract and has a tissue-specific effect [38], whereas no increase in eotaxin-1 serum levels was observed in EoE patients [39]. In this respect, eotaxin-1-deficient mice have fewer eosinophils in all segments of the digestive tract, even when they are stimulated with allergens and under-elevated levels of IL-5 [22]. On the other hand, eotaxin-1 is required to develop IL-13-induced experimental murine EoE, because tissue eosinophilia is significantly lower in eotaxin-1-deficient mice compared with wild-type mice [32].

Different studies have focused on *eotaxin-2/CCL24* [40] and especially on *eotaxin-3/CCL26*, which is the most highly upregulated gene in EoE [36] and the single most overexpressed gene in the esophageal epithelial cells of patients with the disease. It has also been suggested that elevated levels of eotaxin-3 in the esophagus could be helpful to distinguish EoE from GERD [41].

Certain data support the important role of eotaxin-3 in the molecular basis of EoE: patients with EoE show higher eotaxin-3 plasmatic levels than control subjects and the gene expression of *eotaxin-3* and its protein in esophageal tissue is directly and closely related to tissue eosinophils and mast-cell densities. Furthermore, a single nucleotide polymorphism (SNP; +2496T>G, rs2302009) in the *eotaxin-3* gene has been associated with disease susceptibility. This SNP locates at the 3′ untranslated region of the *eotaxin-3* gene and may participate to maintain the mRNA stability [36]. However, since the potency of eotaxin-1 as a ligand for CCR-3 appears to be ten-times greater than that of eotaxin-3 [42], small changes in the gene expression of *eotaxin-1* could also play an important role in recruiting eosinophils towards the esophagus [28].

RANTES is another chemokine involved in inflammatory processes, whose genetic expression seems to be slightly increased in murine EoE compared with control epithelia [35,38] and also in a series of children with EoE compared with healthy subjects [40]. Both RANTES and eotaxins are produced by inflammatory cells, whereas they are not detected in epithelial cells of the normal esophagus, although it was recently shown that IL-4 and -13 are capable of selectively inducing the gene expression of *eotaxin-3* in skin keratinocytes [43].

Epithelial function in EoE

The esophageal epithelium has a different histological structure to the other organs of the digestive tract. Its flat epithelial cells are arranged in different layers, it lacks specific secretory or absorptive functions and looks like the mere lining of a duct. Also, the presence of resident cells in the innate immune system or lymphoid aggregates is negligible in comparison with other more distal sections, which are characterized by companion bacteria and having absorption functions. However, despite having the appearance of a passage duct lining, in normal conditions, esophageal epithelium has the same cell components as the surveillance mucosal system [44]. Far from simply acting as a physical barrier, it was recently acknowledged that the esophageal epithelium plays an active role in regulating inflammatory responses in EGIDs in general and particularly in EoE, allowing eosinophil–epithelial cell crosstalk, as studied in other allergic diseases (e.g., asthma and atopic dermatitis) [45]. The restriction of the inflammatory infiltrate to the esophagus in EoE implies organ-specific homing signals; intestinal epithelia are capable of releasing several chemokines as eotaxins that establish a differential local microenvironment directing eosinophils to specific organs [46]. Inversely, eosinophils are capable of synthesizing and releasing potent biological mediators that impact epithelial cells, causing basal epithelial cell proliferation [47] and dilated intercellular spaces [48]. This epithelial dysfunction could facilitate the uptake of underdegraded allergens and perpetuate the inflammatory condition. The mutual influences between epithelial cells and eosinophils should be further investigated.

Fibrous remodeling in EoE

Eosinophilic inflammation of the airways leads to structural changes in the bronchial wall known as bronchial remodeling. This occurs in several ways implying metaplasia of the mucosal glands, smooth muscle hypertrophy, subepithelial collagen deposition (fibrosis) and angiogenesis [49]. All of these phenomena cause impairment of the respiratory function. Fibrous remodeling in EoE has important clinical implications as it could be associated with symptoms of dysphagia, and may explain and predict future esophageal strictures and dysmotility.

Subepithelial fibrous remodeling in EoE has recently been described. Research carried out on a murine model showed that subepithelial fibrosis is caused by tissue eosinophilia induced by IL-5 [50]. EoE-associated fibrosis is related to esophageal eosinophil activation, as shown by eosinophil degranulation, which is determined by immunohistochemical staining for eosinophilic MBP [51].

Eosinophil-released MBP has been found to increase the expression of FGF9 in biopsies of EoE patients. This cytokine, which is implicated in the proliferative response to injury [47], correlates with EoE-associated basal cell hyperplasia.

Research carried out on children with EoE has equally shown significant subepithelial fibrosis of the lamina propria compared with normal controls or children with GERD, determined by increased expression of TGF-β and its signaling factor phosphorylated Smad2/3 in eosinophils [52]. In addition, EoE is associated with an increased number of activated blood vessels expressing VCAM-1.

According to recent research, after 3 months of budesonide therapy, the reduction in epithelial eosinophils was associated with a significant reduction in esophageal remodeling, decreased fibrosis, TGF-β and Smad2/3-positive cells and decreased VCAM-1-related vascular activation [53].

However, since it is difficult to systematically perform a biopsy on the lamina propria tissue of EoE patients, we are unaware of its implications with regard to structural changes in esophageal remodeling. Also, we do not have any data on the intensity and reversibility of fibrous remodeling of the esophagus in adult patients with EoE most exposed to structural changes due to persistent eosinophilic inflammation.

Mast cell function in EoE

Research has shown increased mast-cell density of the mucosal inflammatory infiltrate of patients with EoE by as much as 20-times the level observed in normal patients [44]. Although the role of this functionally complex cell type has been firmly established in bronchial asthma and other chronic allergies, much of the data implicating mast cells in the pathogenesis of EoE has been considered indirect and inferential [54], although it does indicate the central role played by mast cells [55]: their density correlates with the degree of eosinophilia in the epithelium and decreases after effective treatment with topical steroids in parallel to the number of eosinophils [44]. Mast cell activation has been shown through ultrastructural changes in their cytoplasmatic granules detected by electronic transmission microscopy and positive immunostaining against IgE, and is suggested as a factor that differentiates EoE from GERD [56]. Overexpression of various characteristic mast cell genes, such as those coding for tryptase, chymase and carboxypeptidase A3, have also been observed in EoE, although with very different expression levels [36], for example, some mast cell-specific genes increased twofold (*chymase*), whereas others increased up to sixfold (*tryptase*) or 20-fold (*carboxypeptidase A3*), showing dissociation from the threefold change in mast-cell levels. T-cell-dependent mucosal mast cells are suggested to be involved in the inflammatory process of EoE as a result of the expression of tryptase but not chymase [36].

The most extensively studied mechanism leading to mast cell activation and degranulation is the antigen crosslinking of IgE antibodies on their surface, resulting in the rapid release of autacoid mediators, such as histamine, that increase vessel permeability. However, neither antihistaminic drugs nor mast-cell stabilizers are effective in treating EoE patients [12]. Anaphylactic phenomena have not been described in patients with EoE, in whom histological damage is characterized by cell-mediated damage rather than by tissue angioedema [57]. A fourfold gene overexpression of the high affinity IgE receptor FcεRI has been described in EoE [36], but available data show that, at least in most cases of EoE, mast-cell activation does not appear to be mediated by IgE. There are multiple immunologic- and non-immunologic-mediated alternative mechanisms leading to the release of mediators by mast cells, aside from IgE [55].

In addition to their effector function, mast cells have an increasingly recognized immunoregulatory function [58]. Through H2 to H4 receptors, histamine can modulate immune responses acting on dendritic cells and T lymphocytes [59,60]. Th2 cytokines released by mast cells define an environment that helps allergic inflammatory processes [61], the recruitment of T lymphocytes, the proliferation of eosinophils in bone marrow and induces B-cell class switching to IgE. Some of them, such as IL-4, -5, -13 [30], GM-CSF and eotaxins, have been widely implicated in the physiopathology of EoE [62]. Mast cells by themselves could play a central role in orchestrating inflammation [63].

Available evidence concerning the role played by mast cells alongside eosinophils in the epithelial inflammatory infiltrate of EoE supports the idea that their function could be of considerable importance in its physiopathology. Interaction between both cell types could, therefore, be feasible and it is suggested that this interaction could act as a feedback loop that increases the inflammatory response (Figure 1). These possibilities require further research.

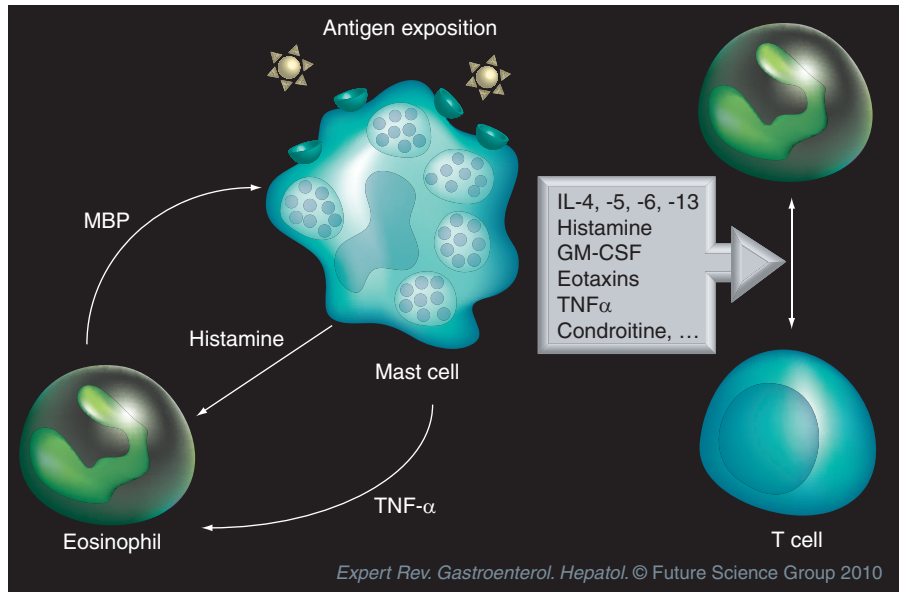

Figure 1. Mast cell immunoregulatory functions could define a molecular environment promoting inflammation and cell 'crosstalk' between mast cells themselves, eosinophils and T lymphocytes.

Expert commentary: unresolved aspects & proposed new research methods

Despite the extensive knowledge acquired in recent years, various mechanisms causing EoE and their contribution to clinical manifestations need to be further clarified. Available data presented so far show that Th2-type inflammatory pathways are involved in the origin of the disease, which are mainly mediated by $CD4^+$ helper T lymphocytes. However, the lymphocyte infiltrate in EoE is predominantly $CD8^+$ [44,64], which is implicated in MHC class I-restricted cytotoxic responses (Th1), a function that has not yet been researched in EoE.

Also, Th1-mediated immune responses have not been systematically analyzed in EoE, and evidence shows that this inflammatory pathway could have a potential role. The contribution of Th1 profile cytokines (of which IFN-γ and TNF-α are clear exponents) to the physiopathology of the disease is controversial. Straumann *et al.* found an increased expression of TNF-α in the esophageal biopsies of eight adult EoE patients [14], but the anti-TNF-α antibody infliximab did not have a beneficial effect on inflammation or symptoms in adults [65]. Gupta *et al.* reported an overexpression of the *IFN-γ* gene in the esophageal epithelium of a series of children affected by this disease [40]. We should, therefore, consider that the inflammatory cascade mediated by Th1 could also play a role in the pathogenesis of EoE, at least at a local level, since the production capacity of TNF-α by the blood lymphocytes of EoE patients did not increase compared with control subjects [26,66]. Conceptually, Th1 cytokines could act as counter-regulators of Th2 reactions, but the concurrent expression of Th1 and Th2 cytokines could exacerbate the symptoms, mainly in chronic processes [58]. This suggests that once a Th2 cell response has been established, Th1 counter-regulation is more complex.

Although similarities between EoE and bronchial asthma have been reported [67], including several common physiological mechanisms, some recently described EoE characteristics also suggest that it may be related to other primary digestive pathologies, especially GERD, inflammatory bowel disease and celiac disease. With regard to GERD, recent research has suggested that there is a bidirectional relationship between both diseases. Although the pathophysiology and gene expression patterns of EoE and GERD are clearly different [36], motor disturbances associated with EoE could determine impaired esophageal clearance and GERD symptoms. It has also been proposed that acid-suppressive medication could lead to the development of EoE. In this respect, food allergens are not degraded when gastric fluid pH is raised to levels commonly found in the stomachs of patients treated with proton pump inhibitor drugs, which might facilitate the uptake of underdegraded peptide allergens by increasing gastrointestinal mucosal permeability [68]. The complete allergen must be present to induce immediate IgE-mediated allergic responses, while the activation of T lymphocytes only needs the presence of specific peptides [69]. Peptides that do not contain epitopes for IgE recognition but which preserve those recognized by T cells are generated during the digestive process [70]. These peptides are capable of inducing strong inflammatory responses mediated exclusively by T cells [71], both local and systemic, without any previous IgE-mediated events. When faced with re-exposure to the antigen in the esophageal mucosa, sensitized lymphocytes organize the eosinophil inflammatory response without the involvement of IgE [58]. The complex relationship between EoE and GERD must be clarified through further research.

Several genes are involved in EoE, specifically those coding for eotaxin-3 and TGF-β. A SNP in the *eotaxin-3* gene has been associated with disease susceptibility [36], another SNP in the promoter of the *TGF-β1* gene has been linked to reduced esophageal remodeling following topical steroid treatment [53], and familial cases of EoE have also been commonly reported [72,73]. Consequently, EoE has a moderate genetic component, which could be related to other inflammatory gastrointestinal diseases. Emerging evidence associating EoE with celiac disease should be investigated [74,75].

Five-year view

Experience has taught us that EoE is a complex disease involving a large number of cells, molecules and genes. Rather than being unique, EoE could be a clinical and evolutionary spectrum in each individual patient. Eosinophilic infiltration of the esophagus could also represent the ultimate common phenotype resulting from the convergence of different activation forms of inflammation, which cannot be identical in each case [57]. Aside from its relationship with bronchial asthma and antigen exposure (which has not been able to provide an explanation for nonallergic cases of EoE), over the next few years, we will improve our knowledge of the relationship between EoE and other primary digestive mucosal immunity disorders, especially inflammatory bowel disease and celiac disease. The three diseases have similar geographical distribution, are becoming increasingly prevalent, have an important genetic load and are immunological tolerance disorders of the gut to antigens.

The specific interaction of food and/or inhaled antigens in genetically predisposed individuals, together with possible changes in mucosal immune mechanisms determined by chronic acid exposure, lead to esophageal eosinophilic inflammation and its related symptoms. Defining the range of each factor in this equation and their relevance in the final formula are key for developing studies and therapies adapted for each patient in the near future.

Financial & competing interests disclosure

The work of Alfredo J Lucendo was funded by a grant from FISCAM AN-2008/21. Neither of the authors had any conflict of interest or affiliation with any of the institutions, organizations or companies that might be mentioned in the manuscript. The authors have no other relevant affiliations or financial involvement with any organization or entity with a financial interest in or financial conflict with the subject matter or materials discussed in the manuscript apart from those disclosed.

No writing assistance was utilized in the production of this manuscript.

Key issues

- Eosinophilic esophagitis (EoE) is pathophysiologically related to allergies and has a Th2-type inflammatory response in common with bronchial asthma, characterized by IL-5, IL-13 and eotaxin expression.
- IL-5 is shown to play a central role in animal models of EoE, but anti-IL-5 therapy only had a partial histological effect on human patients, with minimal clinical benefits. Synergistic effects with other cytokines and chemokines, especially IL-13, and even the possibility of different inflammatory cascades not dependent on IL-5, should be considered.
- *Eotaxin-3* is the single most overexpressed gene in the esophageal epithelial cells of EoE patients and a single nucleotide polymorphism in the gene encoding the chemokine has been associated with disease susceptibility. Cooperation between systemic Th2-type immunity and an enhanced effect of eotaxin-3 on its CCR-3 receptor have been suggested in the basic pathogenesis of EoE.
- Fibrous remodeling of the esophageal lamina propria has been demonstrated in EoE, which has high clinical relevance determined by TGF-β expression and is associated with an increased number of activated blood vessels expressing VCAM-1.
- The role of mast cells in EoE must be considered as this cell type seems to be a constant component accompanying eosinophils in the esophageal inflammatory infiltrate. The interaction between both cell types that could increase the inflammatory response should be taken into account.
- A complex bidirectional relationship between EoE and gastroesophageal reflux disease (GERD) has been suggested: aside from motor disturbances associated with EoE determining impaired esophageal clearance and GERD symptoms, a possible pathophysiological role in facilitating antigen uptake by increasing mucosal permeability has been attributed to anti-GERD therapies.

References

Papers of special note have been highlighted as:
• of interest
•• of considerable interest

1 Atkins D, Kramer R, Capocelli K *et al*. Eosinophilic esophagitis: the newest esophageal inflammatory disease. *Nat. Rev. Gastroenterol. Hepatol.* 6, 267–278 (2009).

2 Straumann A, Spichtin HP, Bernoulli R *et al*. Idiopathic eosinophilic esophagitis: a frequently overlooked disease with typical clinical aspects and discrete endoscopic findings. *Schweiz. Med. Wochenschr.* 124, 1419–1429 (1994).

3 Winter HS, Madara JL, Stafford RJ *et al*. Intraepithelial eosinophils: a new diagnostic criterion for reflux esophagitis. *Gastroenterology* 83, 818–823 (1982).

4 Furuta GT, Liacouras CA, Collins MH *et al*. Eosinophilic esophagitis in children and adults: a systematic review and consensus recommendations for diagnosis and treatment. *Gastroenterology* 133, 1342–1363 (2007).

5 Dobbins JW. Eosinophilic gastroenteritis with esophageal involvement. *Gastroenterology* 72, 1312 (1977).

6 Ureles AL, Alschibaja T, Lodico D, Stabins SJ. Idiopathic eosinophilic infiltration of the gastrointestinal tract, diffuse and circumscribed. *Am. J. Med.* 30, 899 (1961).

7 Simon D, Marti H, Heer P *et al*. Eosinophilic esophagitis is frequently associated with IgE-mediated allergic airway diseases. *J. Allergy Clin. Inmunol.* 115, 1090–1092 (2005).

8 Picus D, Frank P. Eosinophilic esophagitis. *AJR Am. J. Roentgenol.* 136, 1001–1003 (1981).

9 Kelly KJ, Lazenby AJ, Rowe PC *et al*. Eosinophilic esophagitis attributed to gastroesophageal reflux: improvement with an amino acid-based formula. *Gastroenterology* 109, 1503–1512 (1995).

•• **First demonstration of eosinophilic esophagitis (EoE) as a food allergy, by successful treatment of eosinophilic inflammation and derived esophageal symptoms with an antigen-free diet.**

10 Moawad FJ, Veerappan G, Lake JM *et al*. The correlation between eosinophilic oesophagitis and aeroallergens. *Aliment. Pharmacol. Ther.* 31, 509–515 (2010).

11 Cherian S, Smith NM, Forbes DA. Rapidily increasing prevalence of eosinophilic esophagitis in Western Australia. *Arch. Dis. Child.* 91, 1000–1004 (2006).

12 Liacouras CA, Spergel JM, Ruchelli E *et al*. Eosinophilic esophagitis: a 10-year experience in 381 children. *Clin. Gastroenterol. Hepatol.* 3, 1198–1206 (2005).

13 Garn H, Renz H. Epidemiological and immunological evidence for the hygiene hypothesis. *Immunobiology* 212, 441–452 (2007).

14 Straumann A, Bauer M, Fischer B *et al*. Idiopathic eosinophilic esophagitis is associated with a T(H)2-type allergic inflammatory response. *J. Allergy Clin. Immunol.* 108, 954–961 (2001).

15 Weller PF, Lim K, Wan HC *et al*. Role of the eosinophil in allergic reactions. *Eur. Respir. J. Suppl.* 22, 109s–115s (1996).

16 Gleich GJ, Kita H. Bronchial asthma: lessons from murine models. *Proc. Natl Acad. Sci. USA* 94, 2101–2102 (1997).

17 Cieslewicz G, Tomkinson A, Adler A *et al*. The late, but not early, asthmatic response is dependent on IL-5 and correlates with eosinophil infiltration. *J. Clin. Invest.* 104, 301–308 (1999).

18 Gharaee-Kermani M, McGarry B, Lukacs N *et al*. The role of IL-5 in bleomycin-induced pulmonary fibrosis. *J. Leukoc. Biol.* 64, 657–666 (1998).

19 Phipps S, Ying S, Wangoo A *et al*. The relationship between allergen-induced tissue eosinophilia and markers of repair and remodelling in human atopic skin. *J. Immunol.* 169, 4604–4612 (2001).

20 Rothenberg ME. Eosinophilic gastrointestinal disorders. *J. Allergy Clin. Inmunol.* 113, 11–28 (2004).

21 Rothenberg ME, Mishra A, Brandt EB *et al*. Gastroeintestinal eosinophils. *Inmunol. Rev.* 179, 139–155 (2001).

22 Mishra A, Hogan SP, Brandt EB *et al*. An etiological role for aeroallergens and eosinophils in experimental esophagitis. *J. Clin. Invest.* 107, 83–90 (2001).

• **Showed development of experimental murine EoE after intranasal aeroallergen sensitization, demonstrating a pathophysiological connection between allergic respiratory hypersensitivity responses and EoE, and demonstrated an etiologic role for inhaled allergens and eosinophils in gastrointestinal inflammation.**

23 Mishra A, Hogan SP, Brandt EB *et al*. IL-5 promotes eosinophil trafficking to the esophagus. *J. Inmunol.* 168, 2464–2469 (2002).

24 Akei HS, Mishra A, Blanchard C *et al*. Epicutaneous antigen exposure primes for experimental eosinophilic esophagitis in mice. *Gastroenterology* 129, 985–994 (2005).

25 Yamazaki K, Murray JA, Arora AS *et al*. Allergen-specific *in vitro* cytokine production in adult patients with eosinophilic esophagitis. *Dig. Dis. Sci.* 51, 1934–1941 (2006).

26 Bullock JZ, Villanueva JM, Blanchard C *et al*. Interplay of adaptive Th2 immunity with eotaxin-3/c-C chemokine receptor 3 in eosinophilic esophagitis. *J. Pediatr. Gastroenterol. Nutr.* 45, 22–31 (2007).

• **Explains the development of EoE as cooperation between systemic CD4+ Th2-cell-mediated immunity and an enhanced eosinophil-CCR3/eotaxin-3 pathway, and demonstrates the reversibility of increased CCR3 expression after disease remission.**

27 Straumann A, Conus S, Grzonka P *et al*. Anti-interleukin-5 antibody treatment (mepolizumab) in active eosinophilic oesophagitis: a randomized, placebo-controlled, double-blind trial. *Gut* 59, 21–30 (2010).

•• **First randomized controlled trial in EoE patients using anti-IL5 biological therapy. The partial reduction in eosinophilic inflammation reached and the lack of relevant clinical improvement opened new ways to the study of alternative mechanisms of inflammation in the pathophysiology of EoE.**

28 Lucendo AJ, De Rezende L, Comas C *et al*. Treatment with topic steroids downregulates IL-5, *eotaxin-1/CCL11* and *eotaxin-3/CCL26* gene expression in eosinophilic esophagitis. *Am. J. Gastroenterol.* 103, 2184–2193 (2008).

• **Case series showing downregulation in gene expression of cytokines implicated in EoE after steroid treatment. A wide variability exists in gene expression patterns of cytokines between different patients, suggesting that IL-5 and eotaxins could act in a synergistic way.**

29 Schmid-Grendelmeier P, Altznauer F, Fischer B *et al*. Eosinophils express functional IL-13 in eosinophilic inflammatory diseases. *J. Immunol.* 169, 1021–1027 (2002).

30 Blanchard C, Mingler MK, Vicario M *et al*. IL-13 involvement in eosinophilic esophagitis: transcriptome analysis and reversibility with glucocorticoids. *J. Allergy Clin. Immunol.* 120, 1292–1300 (2007).

•• **Confirms the central role played by IL-13 in the development of EoE. Furthermore, gene expression changes were reversed after topical steroid treatment in parallel to a significant reduction in IL-13 mRNA expression levels.**

31 Neilsen CV, Bryce PJ. Interleukin-13 directly promotes oesophagus production of CCL11 and CCL24 and the migration of eosinophils. *Clin. Exp. Allergy* 40(3), 427–434 (2010).

32 Mishra A, Rothenberg ME. Intratracheal IL-13 induces eosinophilic esophagitis by an IL-5, eotaxin-1, and STAT6-dependent mechanism. *Gastroenterology* 125, 1419–1427 (2003).

33 Barner M, Mohrs M, Brombacher F *et al*. Differences between IL-4R α-deficient mice reveal a role for IL-13 in the regulation of Th2 responses. *Curr. Biol.* 8, 669–672 (1998).

34 Vicario M, Blanchard C, Stringer KF *et al*. Local B cells and IgE production in the esophageal mucosa in eosinophilic esophagitis. *Gut* 59, 12–20 (2010).

• **Demonstrates local immunoglobulin class switching to IgE, and IgE production in the esophageal mucosa of EoE patients as a significant mechanism contributing to disease pathogenesis.**

35 Zimmermann N, Hogan SP, Mishra A *et al*. Murine eotaxin-2: a constitutive eosinophil chemokine induced by allergen challenge and IL-4 overexpression. *J. Immunol.* 165, 5839–5846 (2000).

36 Blanchard C, Wang N, Stringer KF *et al*. Eotaxin-3 and a uniquely conserved gene-expression profile in eosinophilic esophagitis. *J. Clin. Invest.* 116, 536–547 (2006).

•• **Lead to the development of an EoE-specific transcriptome in which *eotaxin-3* is the most upregulated gene.**

37 van Wetering S, Zuyderduyn S, Ninaber DK *et al*. Epithelial differentiation is a determinant in the production of eotaxin-2 and -3 by bronchial epithelial cells in response to IL-4 and IL-13. *Mol. Immunol.* 44, 803–811 (2007).

38 Hogan SP, Mishra A, Brandt EB *et al*. A pathological function for eotaxin and eosinophils in eosinophilic gastrointestinal inflamation. *Nat. Inmunol.* 2, 353–360 (2001).

39 Fujiwara H, Morita A, Kobayashi H *et al*. Infiltrating eosinophils and eotaxin: their association with idiopathic eosinophilic esophagitis. *Ann. Allergy Asthma Immunol.* 89, 429–432 (2005).

40 Gupta SK, Fitzgerald JF, Kondratyuk T *et al*. Cytokine expression in normal and inflamed esophageal mucosa: a study into the pathogenesis of allergic eosinophilic esophagitis. *J. Pediatr. Gastroenterol. Nutr.* 42, 22–26 (2006).

41 Bhattacharya B, Carlsten J, Sabo E *et al*. Increased expression of eotaxin-3 distinguishes between eosinophilic esophagitis and gastroesophageal reflux disease. *Hum. Pathol.* 38, 1744–1753 (2007).

42 Kitaura M, Suzuki N, Imai T *et al*. Molecular cloning of a novel human CC chemokine (eotaxin-3) that is a functional ligand of CC chemokine receptor 3. *J. Biol. Chem.* 274, 27975–27980 (1999).

43 Kagami S, Saeki H, Komine M *et al*. Interleukin-4 and interleukin-13 enhances CCL26 production in a human keratinocyte cell line HaCaT cells. *Clin. Exp. Immunol.* 141, 459–466 (2005).

44 Lucendo AJ, Navarro M, Comas C *et al*. Immunophenotypic characterisation and quantification of the epithelial inflammatory infiltrate in eosinophilic esophagitis through stereology: an analysis of the disease's cellular mechanisms and the esophagus's immunological capacity. *Am. J. Surg. Pathol.* 31, 598–606 (2007).

45 Fillon S, Robinson ZD, Colgan SP *et al*. Epithelial function in EGID. *Immunol. Allergy Clin. North Am.* 29, 171–178 (2009).

46 Blanchard C, Rothenberg ME. Chemotactic factors associated with eosinophilic gastrointestinal diseases. *Immunol. Allergy Clin. North Am.* 29, 141–148 (2009).

47 Mulder DJ, Pacheco I, Hurlbut DJ *et al*. FGF9-iduced proliferative response to eosinophilic inflammation in oesophagitis. *Gut* 58, 166–173 (2009).

48 Ravelli AM, Villanacci V, Ruzzenenti N *et al*. Dilated intercellular spaces: a major morphological feature of esophagitis. *J. Pediatr. Gastroenterol. Nutr.* 42, 510–515 (2006).

49 Aceves SS, Broide DH. Airway fibrosis and angiogenesis due to eosinophil trafficking in chronic asthma. *Curr. Mol. Med.* 8, 350–358 (2008).

50 Mishra A, Wang M, Pemmaraju VR *et al*. Esophageal remodeling develops as a consequence of tissue specific IL-5-induced eosinophilia. *Gastroenterology* 134, 204–214 (2008).

51 Chehade M, Sampson HA, Morotti RA *et al*. Esophageal subepithelial fibrosis in children with eosinophilic esophagitis. *J. Pediatr. Gastroenterol. Nutr.* 45, 319–328 (2007).

52 Aceves SS, Newbury RO, Dohil R *et al*. Esophageal remodeling in paediatric eosinophilic esophagitis. *J. Allergy Clin. Immunol.* 119, 206–212 (2007).

•• **Esophageal fibrous remodeling is demonstrated in pediatric cases of EoE, consisting of in collagen deposition in the lamina propria (significantly higher than observed in normal and gastroesophageal reflux disease esophagitis), TGF-β and VCAM-1 expression.**

53 Aceves SS, Newbury RO, Chen D *et al*. Resolution of remodeling in eosinophilic esophagitis correlates with epithelial response to topical corticosteroids. *Allergy* 65, 109–116 (2010).

54 Wershil BK. Exploring the role of mast cells in eosinophilic esophagitis. *Allergy Clin. North Am.* 29, 189–195 (2009).

55 Lucendo AJ, Bellón T, Lucendo B. The role of mast cells in eosinophilic esophagitis. *Pediatr. Allergy Immunol.* 20, 512–518 (2009).

56 Kirsch R, Bokhary R, Marcon MA *et al*. Activated mucosal mast-cells differentiate eosinophilic (allergic) esophagitis from gastroesophageal reflux disease. *J. Pediatr. Gastroenterol. Nutr.* 44, 20–26 (2007).

57 Lucendo AJ. Immunopathological mechanisms of eosinophilic oesophagitis. *Allergol. Immunopathol. (Madr.)* 36, 215–227 (2008).

58 Montero Vega MT. New aspects on inflammation in allergic diseases. *Allergol. Inmunopathol. (Madr.)* 34, 156–179 (2006).

59 Jutel M, Blaser K, Akdis CA. The role of histamine in regulation of immune responses. *Chem. Immunol. Allergy* 91, 174–187 (2006).

60 Sayed BA, Brown MA. Mast cells as modulators of T-cell responses. *Immunol. Rev.* 217, 53–64 (2007).

61 Krishnaswamy G, Ajitawi O, Chi DS. The human mast cell: an overview. *Methods Mol. Biol.* 315, 13–34 (2006).

62 Lucendo Villarín AJ, De Rezende L. [Eosinophilic esophagitis. Review of current clinical and physiopathological concepts.] *Gastroenterol. Hepatol.* 30, 234–241 (2007).

63 Kinet JP. The essential role of mast cells in orchestrating inflammation. *Immunol Rev.* 217, 5–7 (2007).

64 Teitelbaum J, Fox V, Twarog F *et al*. Eosinophilic esophagitis in children: inmunopathological analysis and response to fluticasone propionate. *Gastroenterology* 122, 1216–1225 (2002).

65 Straumann A, Bussmann C, Conus S *et al*. Anti-TNF-α (infliximab) therapy for severe adult eosinophilic esophagitis. *J. Allergy Clin. Immunol.* 122, 425–427 (2008).

66 Rothenberg ME, Mishra A, Collins MH *et al*. Pathogenesis and clinical features of eosinophilic esophagitis. *J. Allergy Clin. Inmunol.* 108, 891–894 (2001).

67 Arora AS, Yamazaki K. Eosinophilic esophagitis: asthma of the esophagus? *Clin. Gastroenterol. Hepatol.* 2, 523–530 (2004).

68 Merwat SN, Spechler SJ. Might the use of acid-suppressive medications predispose to the development of eosinophilic esophagitis? *Am. J. Gastroenterol.* 104, 1902 (2009).

• **Interesting study looking at the possible role of proton pump inhibitor drugs in the origin of EoE; it is important to note that the consensus conference has recommended the use of proton pump inhibitors for 3 months for EoE diagnosis.**

69 Bohle B. T lymphocytes and food allergy. *Mol. Nutr. Food Res.* 48, 424–433 (2004).

70 Hong SJ, Michael JG, Fehringer A *et al*. Pepsin-digested peanut contains T-cell epitopes but not IgE epitopes. *J. Allergy Clin. Immunol.* 104, 473–478 (1999).

71 Haselden BM, Kay AB, Larche M. Immunoglobulin E-independent major histocompatibility complex-restricted T cell peptide epitope-induced late asthmatic reactions. *J. Exp. Med.* 189, 1885–1894 (1999).

72 Collins MH, Blanchard C, Albonia JP *et al*. Clinical, pathologic, and molecular characterization of familial eosinophilic esophagitis compared with sporadic cases. *Ciln. Gastroenterol. Hepatol.* 6, 621–629 (2008).

73 Martín-Muñoz MF, Lucendo AJ, Navarro M *et al*. Food allergy and eosinophilic esophagitis: two cases studies. *Digestion* 74, 49–54 (2006).

74 Verzegnassi F, Bua J, De Angelis P *et al*. Eosinophilic oesophagitis and coeliac disease: is it just a casual association? *Gut* 56(7), 1029–1030 (2007).

75 Leslie C, Mews C, Charles A *et al*. Celiac disease and eosinophilic esophagitis: a true association. *J. Pediatr. Gastroenterol. Nutr.* (2009) (Epub ahead of print).

Affiliations

- Alfredo J Lucendo, MD, PhD
  Department of Gastroenterology, Hospital General de Tomelloso, Vereda de Socuéllamos, s/n, 13700 Tomelloso, Spain
  Tel.: +34 926 525 927
  Fax: +34 926 525 870
  alucendo@vodafone.es
- Baltasar Lucendo, BSc
  Centre of Regenerative Medicine, University of Edinburgh, Edinburgh, UK