IgG4 related orbit disease - An unusual cause of an orbital mass

Chidambaram Viswanath Anand, FRCR[1], Chen Robert, MD[1], Anita Chan Sook Yee, MMed (Ophth)[2,3], Garry Choy, MD[4]

[1]Department of Diagnostic Radiology, Singapore General Hospital, Singapore, [2]Ocular inflammation and Immunology Department, Singapore National Eye centre, Singapore, [3]Department of Pathology, Singapore General Hospital, [4]Instructor of Radiology, Harvard Medical School, Massachusetts General Hospital, Boston MA

SUMMARY

IgG4-related disease is a newly described systemic autoimmune and allergic disease, characterized histologically by a fibroinflammatory response with IgG4 plasma cells. It was initially described as affecting the pancreas, but commonly involves the head and neck region as well. While a biopsy is essential for definitive diagnosis, cross sectional imaging may be the initial modality which may suggest this entity. We describe a case of pathologically proven IgG4 related disease which highlights some key radiologic features seen in this entity. Our case highlights some key radiological features of IgG4- related disease in the head and neck, with involvement of the lacrimal glands, pituitary gland and cranial nerves on CT.

INTRODUCTION

IgG4-related disease (IgG4-RD) is a recently established systemic autoimmune disease that is characterised by fibrosis and organ dysfunction resulting from infiltration of the organ by IgG4 plasma cells and lymphocytes. This disease was initially described as affecting the pancreas, but has been subsequently noted to affect almost every organ system throughout the body.[1] We present a case of IgG4-related disease in the head and neck, which demonstrates involvement of the lacrimal glands, pituitary stalk, and cranial nerves on CT.

CASE REPORT

A 55-year-old man presented with a two-week history of progressive left eye pain and an ill-defined painless mass in the left upper eyelid. On examination, there was proptosis bilaterally. There was full range of eye movements and vision was normal.

Subsequent CT of the orbits showed asymmetric enlargement of the lacrimal glands, left more than right. There was also enlargement of the infra-orbital and supraorbital nerves, pterygopalatine ganglion, and greater and lesser palatine nerves within the pterygopalatine fossa. The pituitary stalk was diffusely enlarged and bulbous in appearance (Figure 1). Based on the constellation of multiorgan involvement, diffuse systemic diseases such as IgG4-related disease and lymphoma were considered.

Serum immunoglobulin levels, including IgG4, were normal. Incision biopsy of the left lacrimal gland was performed under general anaesthesia through a lid crease incision. Histologic analysis of the biopsy sample showed very little residual normal lacrimal gland and instead it was replaced by a dense lymphoplasmocytic inflammatory infiltrate with mild early storiform-like sclerosis. The number of IgG4 positive plasma cells was more than 200 per high power field and the IgG4:IgG ratio was greater than 50% (Figure 2). Lymphoproliferative disease and autoimmune disorders such as granulomatosis with polyangiitis (GPA) were also excluded on histology prior to a histological diagnosis of IgG4-related lacrimal gland inflammation was made. Screening of the neck, chest, abdomen and pelvis with computed tomography did not reveal any other organ involvement.

The patient showed significant clinical improvement after oral Prednisolone and Azathioprine administration with resolution of the proptosis. There was also improvement of the eye pain and on examination there was no mass felt on the follow up in three months.

DISCUSSION

IgG4-related disease was established as a systemic disease in 2003.[2] It is thought to be related to both an autoimmune and allergic response, with resultant infiltration of one or several organs with characteristic IgG4 cells.[2,3] Previously thought to be disparate entities, various disease entities such as inflammatory pseudotumor of the orbit, orbital lymphoid hyperplasia, Mikulicz disease, Kuttner tumour, Hashimoto's thyroiditis, Reidel's thyroiditis and pituitary hyphophysitis are now included under the broad IgG4-RD spectrum as they all share similar characteristic histopathological manifestations.[1,4]

Definitive diagnosis of IgG4 disease is based upon biopsy, showing the histologic presence of a dense lymphoplasmocytic infiltrate, storiform fibrosis and obliterative phlebitis (in fulfilment of the morphological features described in the consensus criteria).[5] This consensus criteria also reports a non-organ specific tissue IgG4 plasma cell criteria that include 1) elevation of IgG4 positive plasma cells >50/hpf, and 2) ratio of IgG4:IgG plasma cells of more than 40%. However, in the lacrimal gland, it is typical to identify >100

This article was accepted: 23 October 2017
Corresponding Author: Viswanath Anand Chidambaram
Email: viswanath.chidamabaram@sgh.com.sg

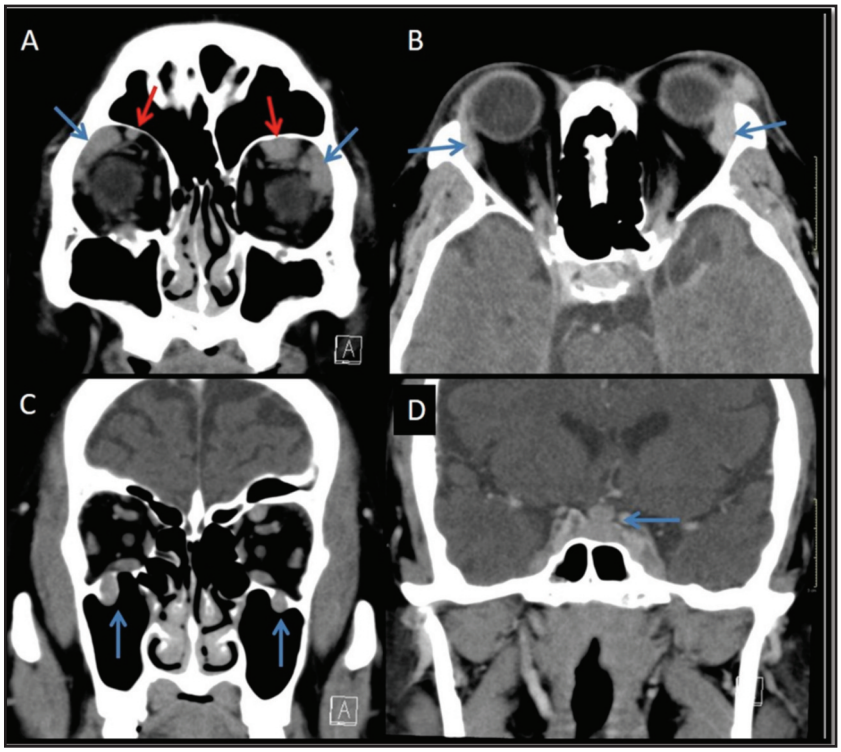

Fig. 1: Coronal (A) and axial (B) contrast enhanced CT images in soft tissue window settings demonstrate enlarged lacrimal glands (blue arrows in A, B). There are also asymmetric soft tissue density lesions in the supraorbital regions (red arrows in A, left larger than right) representing enlarged supraorbital nerves. Coronal contrast enhanced CT image in soft tissue window settings (C) demonstrate bilateral enlarged infraorbital nerves (blue arrows in C). Coronal contrast enhanced CT image in soft tissue window settings (D) demonstrate a diffusely enlarged pituitary stalk, which is bulbous in appearance (blue arrow in D). The stalk should normally be less than 2 mms thick and taper inferiorly to a point.

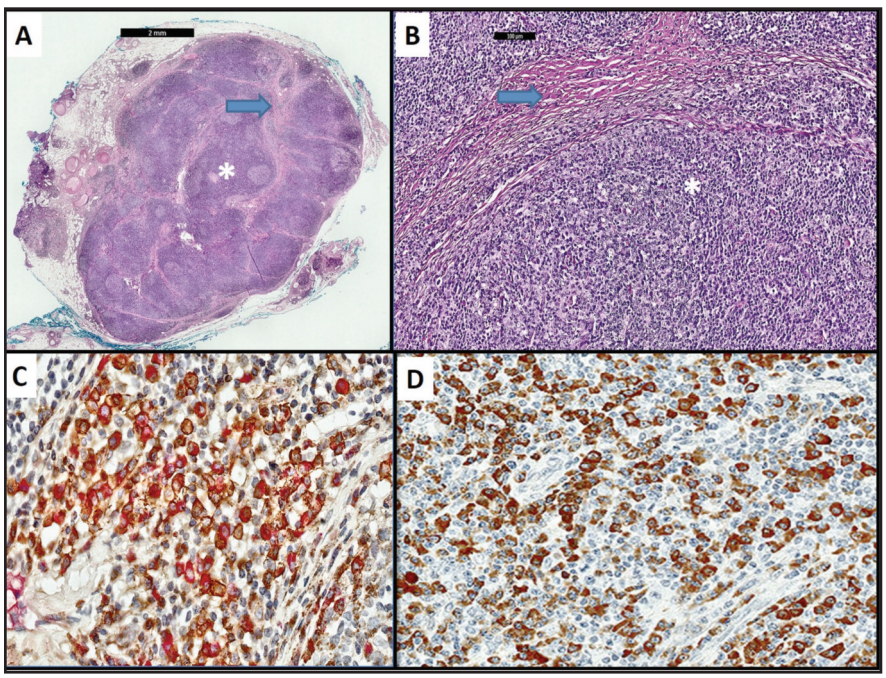

Fig. 2: A: Low power (2x, Hematoxylin and eosin, HE) view of biopsy. Complete effacement of lacrimal gland architecture by a dense lymphoplasmacytic infiltrate (asterix) with bands of fibrosis (early hyaline sclerosis, arrow) in keeping with the histology of IgG4-RD. B: High power view (20x, HE) showing the early hyaline sclerosis (arrow) and the dense lymphoplasmacytic infiltrate (asterix). C: High power view of dual immunohistochemistry of IgG4 positive plasma cells (red chromagen, alkaline phosphatase) and IgG Positive plasma cells (brown chromagen, DAB) showing IgG4: IgG ratio >50% (40x) D: Immunohistochemistry of IgG plasma cells showing >200 cells in 1 high power field (40x)

IgG4 positive plasma cells per high power field (HPF).[5] Elevated IgG4 serum concentrations > or equal to 135mg/dl may be useful for diagnosis, yet IgG4 serum levels can be normal in 20-40% of patients. As a result, clinicoradiological and histopathological findings are required for a definitive diagnosis.[2,5]

In the head and neck region, IgG4 disease has been described to cause enlargement of the extraocular muscles, pituitary stalk, retrobulbar soft tissues, salivary glands, lacrimal glands, and cranial nerve branches.[1] Several of these subsites were affected in our case. Of special note, IgG4-RD commonly involves the maxillary and mandibular branches of the trigeminal nerve, with preferential involvement of the infraorbital nerves. This finding was observed in our case was also a common observation in many different studies and considered an important diagnostic indicator when it is associated with multiorgan involvement.[1,4]

The common differential diagnosis on radiology includes lymphoma, granulomatosis with polyangiitis, Sarcoidosis and Grave's orbitopathy.[1] The degree of fibrosis in the affected organ is a major determinant of treatment response. Prognostically, orbital IgG4-RD usually shows dramatic response with steroids but relapses are common and hence long term low dose steroid or combination with immunosuppressant may be necessary.[2,3]

REFERENCES

1. Fujita A, Sakai O, Chapman MN, Sugimoto H. IgG4-related disease of the head and neck: CT and MR imaging manifestations. Radiographics 2012; 32(7): 1945-58.
2. Stone JH. IgG4-related disease: nomenclature, clinical features, and treatment. Semin Diagn Pathol 2012; 29(4): 177-90.
3. Rammeh S, Ajoulia W, Landolsib A, Sabbegh Znaidi B, Zermani R. Unilateral orbital mass as an unusual presentation of IgG4-related disease. Neurochirurgie 2016; 62(1): 64-6.
4. Toyoda K, Oba H, Kutomi K, Furui S, Oohara A, Mori H, et al. MR imaging of IgG4-related disease in the head and neck and brain. AJNR Am J Neuroradiol 2012; 33(11): 2136-9.
5. Deshpande V, Zen Y, Chan JK, Yi EE, Sato Y, Yoshino T, et al. Consensus Statement on the Pathology of IgG4-Related Disease. Mod Pathol 2012; 25(9): 1181-92.