Respiratory Medicine xxx (2015) 1–7

Contents lists available at ScienceDirect

Respiratory Medicine

journal homepage: www.elsevier.com/locate/rmed

Development of chronic pulmonary aspergillosis in adult asthmatics with ABPA

David Lowes [a], Livingstone Chishimba [a], Melanie Greaves [b], David W. Denning [a, *]

[a] The National Aspergillosis Centre, University Hospital of South Manchester, The University of Manchester, Manchester Academic Health Science Centre, Manchester, UK
[b] Department of Radiology, University Hospital of South Manchester NHS Foundation Trust, Manchester, UK

ARTICLE INFO

Article history:
Received 22 June 2015
Received in revised form
10 September 2015
Accepted 11 September 2015
Available online xxx

Keywords:
Fungal diseases
Fibrosis
Cavitation
Aspergillus fumigatus
Corticosteroids

ABSTRACT

Background: Chronic pulmonary aspergillosis (CPA) is an occasional complication of allergic bronchopulmonaryaspergillosis (ABPA) but the transition is poorly understood.
Methods: All patients referred to the UK's National Aspergillosis Centre with CPA between May 2009 and June 2012 were screened with serum total IgE and anti-*Aspergillus* IgE for a dual diagnosis of ABPA and CPA. Those patients suspected of having both conditions were re-evaluated and their imaging reviewed.
Results: Of 407 referred patients, 42 screened positive and 22 were confirmed as having both ABPA and CPA. Asthma was present from early childhood in 19 (86%), the median interval between ABPA and onset of CPA was 7.5 years; one patient developed ABPA and CPA simultaneously. Aspergillus IgG levels varied from 23 to 771 mg/L, median 82 mg/L. All 22 patients had bronchiectasis. In patients with ABPA, CT typically demonstrated varicose or cystic bronchiectasis primarily affecting segmental and proximal subsegmental upper lobe bronchi. Other findings included mucoid impaction and centrilobular nodules. Radiological changes associated with CPA included pleural thickening which was often bilateral and accentuated by adjacent hypertrophied extrapleural fat, upper lobe volume loss, thick walled apical cavities, some of which contained aspergillomas, and cavitating pulmonary nodules. CPA secondary to ABPA has more subtle radiological appearances than when due to other underlying diseases.
Conclusions: CPA may complicate ABPA and have distinct radiology features, in addition to bronchiectasis. A novel biomarker is required to anticipate this serious complication, as current serology is not specific enough.

© 2015 Elsevier Ltd. All rights reserved.

1. Introduction

Allergic bronchopulmonaryaspergillosis (ABPA) is an uncommon complication of asthma and cystic fibrosis occurring in 0.7–4.1% of asthmatics seen in secondary care [1–3]. Assuming a frequency of ABPA of 2.5% in adult asthmatics, there are an estimated 4,800,000 ABPA patients worldwide [4]. There are probably significant regional differences in prevalence of ABPA, with a lower figure likely in the USA and higher figure likely in India [5–9].

ABPA is characterised by worsening of asthma symptoms not relieved by escalation in treatments, usually with mucus plugging of the airways. Diagnosis of ABPA relies on a collection of nonspecific parameters including a history of asthma, peripheral eosinophilia, immediate skin test reactivity to *Aspergillus* antigen and/or elevated anti-*Aspergillus* IgE, elevated total serum IgE of greater than 1000 IU/L, and, in older series, central bronchiectasis [10].

The most well recognized complication of ABPA is bronchiectasis, the frequency of which is difficult to estimate as it was previously central to diagnosis. Other complications of ABPA are lobar shrinkage, persistent cavitation (>3 months), and pleural fibrosis, which are features of types of chronic pulmonary aspergillosis (CPA) [11,12], specifically chronic cavitary pulmonary aspergillosis (CCPA), which can progress to chronic fibrosing pulmonary aspergillosis. Other patients with ABPA develop aspergilloma, which is definitive evidence of either CCPA (if further cavitation also present) or simple aspergilloma. Other types of CPA not reported in ABPA are aspergillus nodule disease [13], and chronic necrotizing

* Corresponding author. National Aspergillosis Centre, Education and Research Centre, University Hospital of South Manchester, Southmoor Road, Manchester, M23 9LT, UK.
E-mail address: ddenning@manchester.ac.uk (D.W. Denning).

http://dx.doi.org/10.1016/j.rmed.2015.09.007
0954-6111/© 2015 Elsevier Ltd. All rights reserved.

pulmonary aspergillosis. CPA has a reported 5-year survival of 17.5%–60% if not amenable to surgical resection; work undergoing at the National Aspergillosis Centre (NAC) has found a 5-year survival of 62% [14–19].

The frequency of non-bronchiectasis features in ABPA has been reviewed and overall is present in approximately 10% of cases [20]. With one exception, all studies were earlier than 1985, and the epidemiology of asthma, some aspects of clinical management and referral patterns have changed since then [21–26]. The more recent study was a small radiology series from India [27]. Coming at the issue from the other direction, a review of underlying disease at the NAC found that 14.3% of cases of CPA had a coexisting diagnosis of ABPA [28]. Whilst this transition is a recognised phenomenon, neither the temporal sequence nor the aetiology of the transition have been described. A better understanding of this complication of ABPA would provide clinicians with more confidence to escalate antifungal therapy in patients with ABPA who are developing CPA, and potentially reduce the morbidity and mortality in this group of patients. The aim of this project was to describe the temporal sequence from asthma through ABPA to CPA and to document the clinical, serological and the radiological findings over time.

2. Patients and methods

This retrospective study reviewed patients referred to the UK's NAC, based at the University Hospital of South Manchester (UHSM). This national centre cares for the majority of problematic CPA patients in the UK. Patients referred from May 1st 2009 to June 1st 2012 were included. This audit was registered with the audit department at UHSM.

We screened all patients referred to the centre with CPA for dual diagnosis of CAP and ABPA using serum total IgE and anti-*Aspergillus* IgE. The full medical records and thoracic CT imaging of patients highlighted in the screening process were reviewed to confirm and establish the timing of the diagnosis of asthma, ABPA and CPA. Specialists in infectious diseases, respiratory medicine and radiology reviewed each patient's data separately and collectively. Only data available in written and electronic medical records was collected.

Asthma was defined as the presence of symptoms (more than one of wheeze, breathlessness, chest tightness, cough) plus reversible airflow obstruction as shown by an increase in FEV1 of >12% (and 200 mls) after bronchodilator (PBD). Patients with symptoms suggestive of asthma but with no evidence of PBD reversibility features of asthma (provided no fixed airflow obstruction) underwent airway hyper-responsiveness testing using methacholine challenge test (MCT). A diagnosis of asthma was considered when there was a significant bronchial responsiveness demonstrated by $\geq$ 20% fall in the FEV1 with methacholine challenge (PC20 or PD20 FEV1) on a 5-breath dosimeter protocol.

ABPA was defined as the highest serum total IgE of greater than 1000 IU/L, raised serum anti-*Aspergillus* IgE (or positive *Aspergillus* skin prick test), a history of asthma, with compatible symptoms of ABPA (expectoration of mucus plugs and difficult to control asthma). Central bronchiectasis was not required to make a diagnosis of ABPA. We also accepted as ABPA, patients with classical presentations of ABPA the combination of challenging asthma and mucous plugs requiring bronchoscopy or surgical resection years before, without current documentation of an IgE over 1,000 IU/L, if they had an total IgE over 500 IU/L and markedly elevated Aspergillus specific IgE (n = 2, Aspergillus IgE from 15.5 to 34kUa/L (normal <0.4)). When symptoms or radiological features were consistent with a diagnosis of ABPA or CPA, but the diagnosis was not confirmed, the term 'probable ABPA/CPA' was used. St George's Respiratory Questionnaire (SGRQ) score was collected on most patients and computed as described previously (scores range from 1 to 100, lower being better) [29–32].

For the purpose of this study, CPA was diagnosed with positive anti-*Aspergillus* IgG serology or microbiological or histological evidence of CPA with compatible radiological findings. The minimum radiological criteria for assigning the term CPA to cases were cavitation, marked pleural thickening and/or nodules [13,33–35]. The date of the onset of relevant CPA-related symptoms and/or radiological features (which came first) was recorded as 'probable onset of disease'. The first diagnostic evidence of chronic pulmonary aspergillosis (radiological, immunological, histological or microbiological) was recorded as 'confirmed chronic pulmonary aspergillosis'.

CT scans and chest radiographs were viewed using General Electric Centricity PACS software. *Aspergillus* antibody testing undertaken at the NAC utilised the Phadia ImmunoCAP tests, supported by Aspergillus precipitins assays, operated as per manufacturer's instructions. Data were stored and analysed using Microsoft Excel 2010 and SPS Statistics Version 20 IBM USA.

3. Results and analysis

Initial screening revealed 42 patients with a dual diagnosis of ABPA and CPA. On further review of these patients, 20 (patients 1 to 20) had all criteria required for diagnosis of asthma, ABPA and CPA. Patients 1 to 18 had asthma, ABPA and CCPA, whilst patients 19 and 20 had asthma, ABPA and *Aspergillus* nodule disease. A further two patients [21,22] had asthma, ABPA and the radiological appearances of CCPA but did not have positive anti-*Aspergillus* IgG serology. Of the remaining 20 patients, 5 did not meet the radiological criteria for CPA, five did not have ABPA but instead a strong Th-2 cytokine reaction to CPA leading to high IgE levels. Six patients were considered to have developed CPA related to causes other than ABPA (two non-tuberculous *Mycobacterium* disease, three pulmonary TB and one previous thoracic surgery). The remaining four patients had too much missing data in the medical records to allow timing and diagnostic judgements to be made. Fig. 1 shows the ages at which patients 1 to 22 developed asthma, ABPA and CPA; periods of long-term asthma remission are included.

Nineteen patients had childhood asthma, four of whom described their asthma being present from birth. The asthma remitted in adolescence of six of the patients. Of the three patients without childhood asthma, two developed asthma in their teenage years, whilst one (patient 18) did not develop asthma until age 64. Fig. 2 shows the time of ABPA prior to CPA. The median duration of ABPA prior to onset of CPA was 7.5 years (range 0–36 years). One patient (patient 11) developed ABPA and CPA simultaneously.

Patients weighed from 56.1 to 90.2 Kg (n = 18) and BMI was from 18.6 to 29.2 (median 21.9) (n = 15 patients). Total and activity SRGQ scores (n = 18) varied from 7.9 to 80.4 (median 57) and from 0 to 92.5 (median 69.3) respectively.

After the diagnosis of CPA, Aspergillus specific IgE was positive in all patients, with levels varying from 1.0 (patient number 7) to 87.4 with a median of 20.8 (normal <0.04 IUA/L). Aspergillus IgG levels varied from 23 to 771 in 19 patients with a median of 82 mg/L with 4 patients having a level <40 mg/L, the recommended cutoff. Three patients recruited earlier had positive Aspergillus precipitins at titres of >1:2. Mannose binding lectin serum levels were done in 20 patients and were <1.0 in 7 (35%) and undetectable in 4 (20%).

All 22 patients had bronchiectasis. There is some overlap in the radiological appearances of ABPA and CPA, and we found the

Please cite this article in press as: D. Lowes, et al., Development of chronic pulmonary aspergillosis in adult asthmatics with ABPA, Respiratory Medicine (2015), http://dx.doi.org/10.1016/j.rmed.2015.09.007

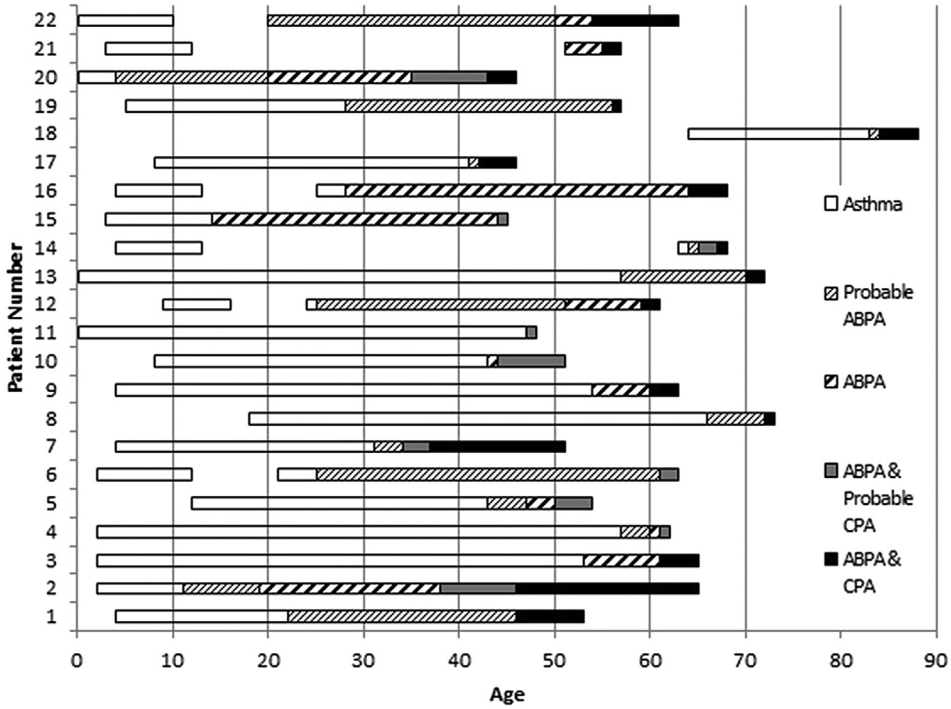

Fig. 1. Ages at which patients 1 to 22 developed asthma, ABPA and CPA, and periods of long-term asthma remission.

radiological appearances of CPA secondary to ABPA more subtle than when it occurs due to other underlying conditions. We found the following changes associated with CPA in ABPA: lobar volume loss with indrawing and hypertrophy of the adjacent extra-pleural fat, small cavitary disease formed directly within presumed *Aspergillus* nodules, such as the 20 mm by 14 mm nodule in patient 21, nodules of ground glass opacity (ie 13.4 mm diameter in patient 18), aspergillomas forming in bronchiectatic cavities, and pleural thickening with apical cavity formation, with or without aspergilloma. Often the pleural thickening seen was bilateral and not limited to the upper zones. These changes are demonstrated in Figs. 3–8. Fig. 9 demonstrates the early changes seen in the transition from ABPA to CPA, in this case arrested by substitution of itraconazole with voriconazole therapy. The course of radiological

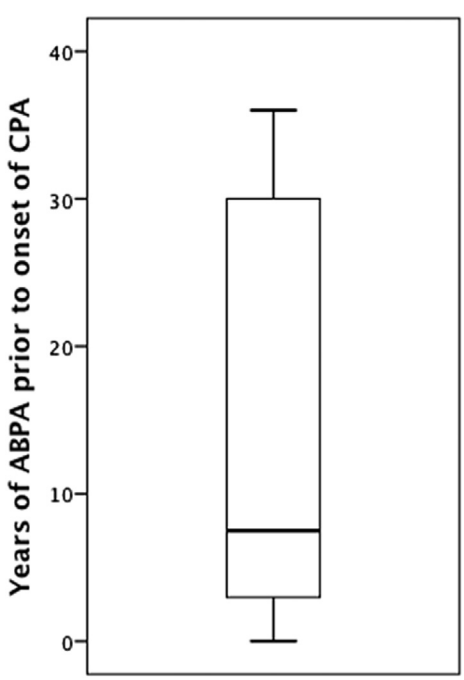

Fig. 2. Years of ABPA prior to onset of CPA.

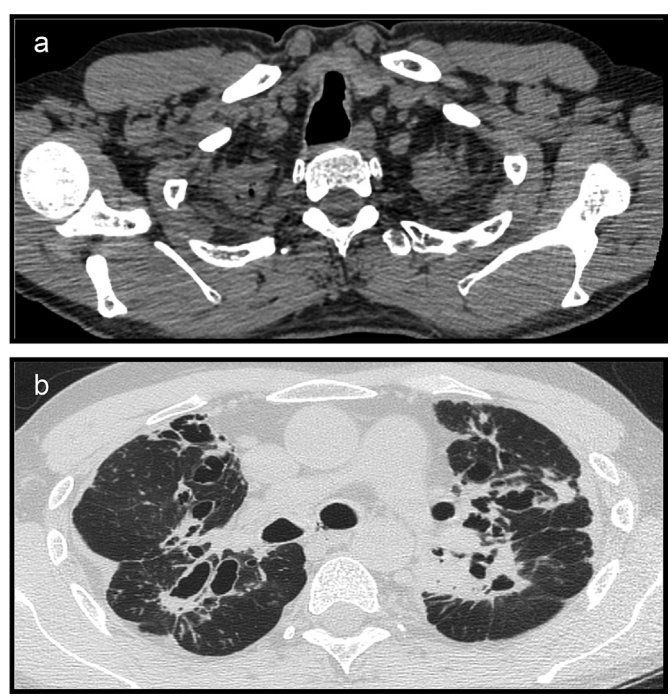

Fig. 3. Patient 1 age 51. a: Apical subpleural fibrosis/pleural thickening with hypertrophy of extra pleural fat. b: Bilateral central varicose bronchiectasis typical of ABPA. A mass of presumed fibrotic soft tissue surrounds left lower lobe bronchi at the hilum.

Please cite this article in press as: D. Lowes, et al., Development of chronic pulmonary aspergillosis in adult asthmatics with ABPA, Respiratory Medicine (2015), http://dx.doi.org/10.1016/j.rmed.2015.09.007

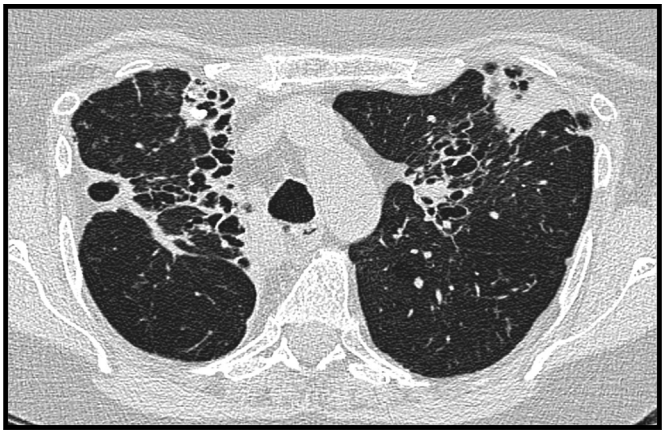

Fig. 4. Patient 2 age 65. CT at the level of the upper arch demonstrates central upper lobe bronchiectasis and volume loss with a 2 cm nodule anteriorly on the left. A small peripheral cavitating region can be seen on the right associated with volume loss, architectural distortion and indrawing of adjacent extrapleural fat.

changes from 1966 to 2014 in patient 2 are available to view at www.aspergillus.org.uk (case 44).

4. Discussion

Persistent cavitation over at least 3 months is highly characteristic of CPA and such cavities may or may not contain a fungal ball (aspergilloma). ABPA is a key underlying disorder in 12–14% of CPA cases in the UK [28]. Pulmonary cavitation has been described in ABPA in many older series at rates of 3–21% and occasionally to resolve later [21–23,27,36]. These patients should not be described as having CPA, in our view, unless they persist despite antimicrobial therapy for >3 months – we described one recently [37]. Aspergillomas are seen in 0–7% of ABPA patients yet are a definitive feature of CPA [21,22,26,36]. Several case reports of aspergilloma and ABPA have been reviewed by Agarwal and colleagues [3]. Aspergilloma formation is a late feature of chronic cavitary pulmonary aspergillosis, and it would be desirable to identify patients earlier than this [38]. Some ABPA patients develop upper lobe volume loss occasionally associated with pleural thickening which could be a manifestation of CPA [21,23]. Upper lobe volume loss and contraction was described as occurring in 36% and 40% of patients respectively in two UK series from the same London institution but has not been mentioned by other authors [21,23].

Pleural disease was described at a rate of 18% in London based on chest radiographs and 43% in India based on CT scan [23,27]. Pleural thickening is a common, but not universal manifestation of CCPA – some patients have thin walled cavities, and minimal pleural thickening. In contrast, there are several well recognised radiological manifestations of ABPA which are not typical of CPA, including bronchiectasis, mucus impaction, fleeting patchy consolidation and transient segmental or lobar collapse. None of these suggest CPA.

Therefore we contend that the development of persistent cavitation and/or pleural thickening and/or volume loss are highly suggestive of CPA complicating ABPA. Defining the minimum and early criterion is currently difficult, without alternative specific tests. Development of an aspergilloma is definitive, but late in the course. Prospective study with frequent imaging in a population not treated with antifungals will be required to propose criteria for the early diagnosis of CCPA. *Aspergillus* nodule disease appears to be much less frequent.

Elevated *Aspergillus* immunoglobulin G (IgG) serology is almost universal in CPA but is also found in ABPA [3], and *Aspergillus* bronchitis [2,39,40]. Therefore detection of raised *Aspergillus* IgG is not specific for CPA in this context, and requires radiological or other criteria for diagnosis. Likewise detection of *Aspergillus* spp. by culture, antigen or molecular testing is not specific for CPA, but commonly found in both conditions.

The long term presence of *Aspergillus* in the airways may contribute to bronchiectasis development [41,42]. *Aspergillus* sensitisation is associated with reduced FEV1 in patients with asthma, cystic fibrosis, COPD and in those with post-tuberculous

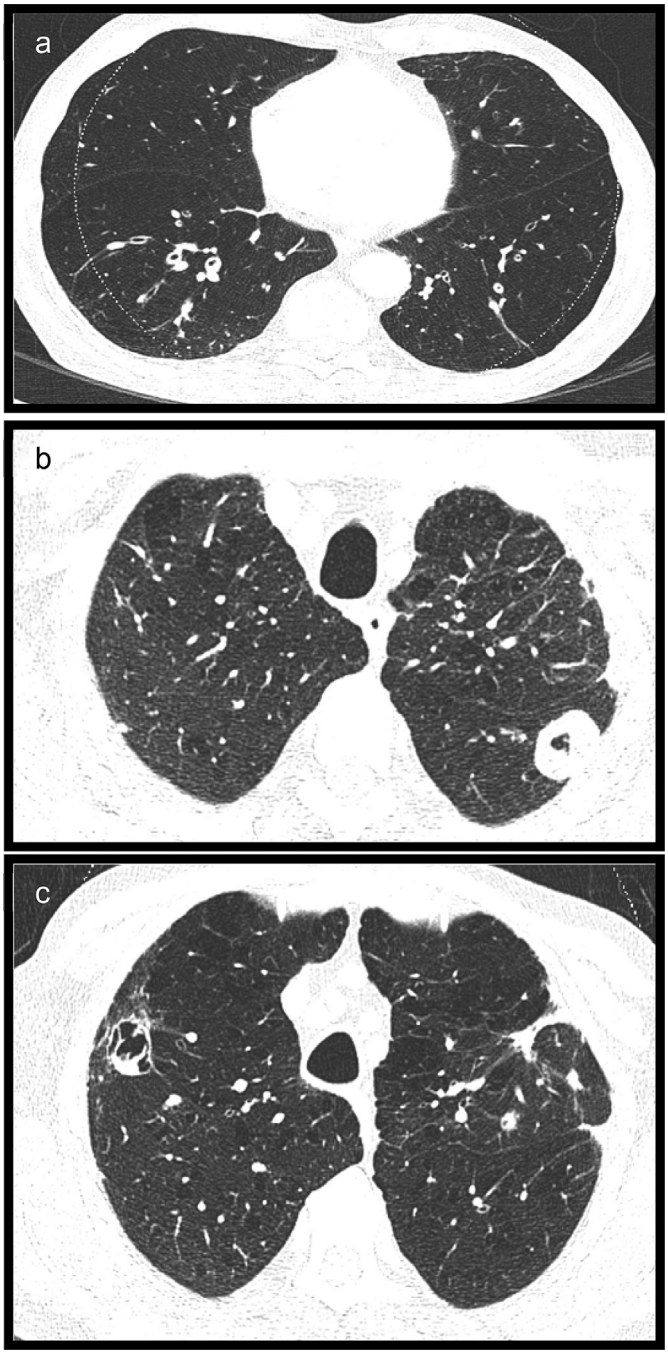

Fig. 5. Patient 18 age 85. a: Bronchial wall thickening with mild cylindrical bronchiectasis in the lower lobes where there is minor mucus plugging. b: Thick walled cavitating lesion in the apical segment of the left lower lobe. c: Complex, thin walled cavitating nodule in the right upper lobe with additional smaller nodules and pleural thickening on the left.

Please cite this article in press as: D. Lowes, et al., Development of chronic pulmonary aspergillosis in adult asthmatics with ABPA, Respiratory Medicine (2015), http://dx.doi.org/10.1016/j.rmed.2015.09.007

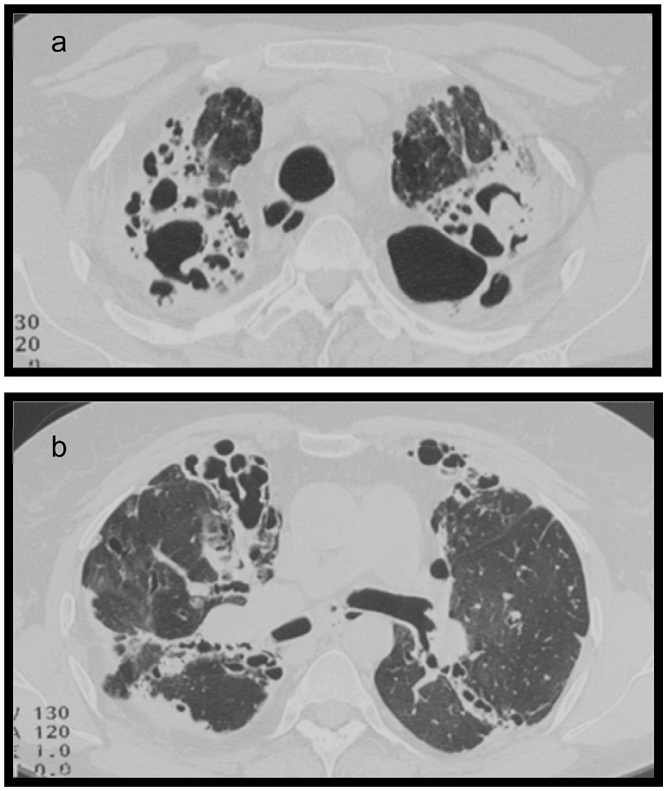

Fig. 6. Patient 7 age 42. a: Fibrocavitary disease of both upper lobes with a small aspergilloma within a cavity in the left apex. b: Severe central bronchiectasis, typical of severe ABPA.

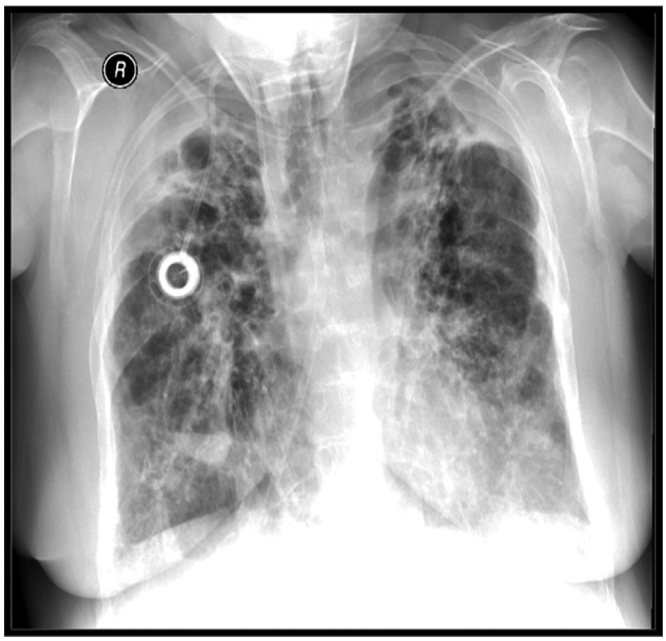

Fig. 7. Patient 7 age 50. Severe bronchiectasis with apical pleural thickening, fibrosis and cystic destruction of the lung. Indwelling intravenous device in situ on the right side.

fibrocavitary changes [2,41,43–45]. All patients with ABPA have airways colonised by *Aspergillus* to which they are sensitised and many have very high serum IgE. It is unclear why some develop complicating pulmonary nodules, cavitation and pleural thickening

Fig. 8. Patient 22. Bilateral upper lobe bronchiectasis with associated volume loss and patchy rather nodular fibrosis. There is associated indrawing of extrapleural fat posteromedially.

whilst the majority do not.

One possibility is the intensity of corticosteroid therapy given. It is possible that those treated with more corticosteroid have more abrogation of their immune response and direct promotion of growth of *Aspergillus* [46,47]. On the other hand, some data are consistent with prevention or amelioration of pulmonary fibrosis by corticosteroid [48,49], and the use of corticosteroid in frequently relapsing ABPA patients with aspergilloma seemed to improve clinical status [26]. Corticosteroids have little impact on the IL17 pathway, which appears to be important in pulmonary fungal disease pathogenesis [50]. Nodule development may be associated with corticosteroid therapy. Multiple aspergillomas in the lung appear to be uncommon, probably develop from nodules and appear to be associated with frequent high dose steroid therapy in some patients, including one with ABPA [51].

The generally long but highly variable intervals between the development of ABPA and CPA could reflect in part difficulty in defining the earliest point at which CPA develops. As the radiological features are not specific in the early phase of CPA development (see Fig. 9), it is currently impossible to pinpoint with any accuracy the precise point of transition. Nonetheless there is remarkable variability in timing during life, suggesting that non-genetic factors are in part responsible; possibly exposure, possibly intercurrent infections or possibly epigenetic events.

A family history of ABPA is found in about 5% of patients [52]. Various genetic links have been described including several HLA associations, single nucleotide polymorphisms (SNPs) in the surfactant protein A2, IL4 receptor, IL13, IL6, tissue growth factor beta, TLR3, TLR9, and heterozygozity in the cystic fibrosis transmembrane conductance regulator (CTFR) [3,53,54]. The genetic links with CPA are different, and the development of CPA appears to require defect in both poor defence against aspergillosis and impaired resolution of inflammation. Three of the immunological deficits associated with CPA are low gamma interferon (gIFN), low IL12 and low IL17A production in many patients [50]. Several SNPs in *TLR1*, Dectin-1, *IL1B*, *IL1RN* and *IL15*, *PLAT*, *VEGFA* and *DENND1B* are described [54,55]. Aberrations in IL1 and IL15 pathways, poor pathogen recognition as well as plasminogen activation and angiogenesis appear to be important. A common deficit with ABPA is inadequate initial clearance of *Aspergillus*. Once the full panoply of defects is understood in each condition, genetic analysis of both conditions found separately and together should confirm these findings.

A surprising finding was that in 6 patients (Fig. 1), asthma went into remission for long periods. Long periods of remission in asthma and ABPA are well recognised [56,57]. We have not

Please cite this article in press as: D. Lowes, et al., Development of chronic pulmonary aspergillosis in adult asthmatics with ABPA, Respiratory Medicine (2015), http://dx.doi.org/10.1016/j.rmed.2015.09.007

ARTICLE IN PRESS

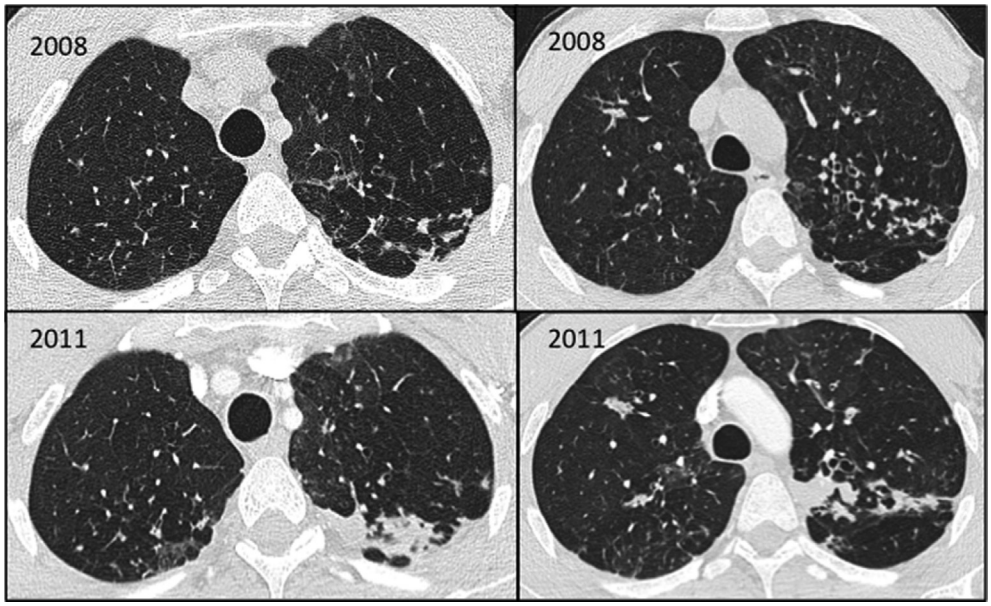

Fig. 9. Patient 19 who become breathless and unwell despite taking itraconazole and high dose inhaled corticosteroids. His CT appearances had changed dramatically over a 3-year interval and the relatively early features of the transition between ABPA alone to CPA are shown in 2 comparative slices here. There is bilateral bronchiectasis particularly in the apicoposterior left upper lobe associated with mucus plugging and centrilobular nodules and tree in bud like structures. The 2011 study shows increased focal nodularity and volume loss posteriorly on the left.

attempted to track ABPA remission and relapse, but in this group of patients the progressive nature of the radiologic features indicating CPA is not consistent with remission.

Longitudinal studies of cohorts of ABPA patients integrating radiographic, clinical and serological changes over time are required [58]. The positive and/or negative impact of corticosteroids (inhaled and oral), and other newer immunomodulators need study in this context, preferably with early endpoints. Our experience suggests that oral antifungal therapy with triazoles reduces symptoms and prevents progression of CPA, but larger prospective cohorts selected by genetic or other risk factors are required to clarify this.

5. Limitations

The main limitation to our study is its retrospective nature and the small sample size.

6. Conclusions

Our findings suggest that CPA complicating ABPA may have distinct radiology features. Bronchiectasis and distinctive radiological findings with nodules, some with cavitation, lobar shrinkage with indrawing of extrapleural fat, aspergillomas, and bilateral pleural thickening are characteristic. Prevention of further fibrosis probably requires antifungal therapy and minimization of corticosteroid use. Larger studies are needed to confirm these findings.

Contribution of authors

Prof. David Denning designed the study and supervised Dr. Lowes who carried out the data collection and wrote the manuscript. Dr. Chishimba provided expertise from a respiratory background as well as acting as co-supervisor of the project. Dr. Greaves provided the expertise and comments on the radiological images. Prof. Denning, Dr. Chishimba, and Dr. Lowes act as guarantors of the study.

Declaration of interests

Dr Livingstone Chishimba was funded by the NAC and the University of Manchester. He has received travel grants from GSK, Novartis, AstraZeneca, Pfizer, Astellas and Chiesi. He has received speaker fees from Chiesi. None of these have any bearing to the published work.

Dr Melanie Greaves: None to declare.

Dr David Lowes: None to declare.

Dr Denning holds Founder shares in F2G Ltd a University of Manchester spin-out antifungal discovery company, in Novocyt which markets the Myconostica real-time molecular assays and has current grant support from the National Institute of Allergy and Infectious Diseases, National Institute of Health Research, North-West Lung Centre Charity, Medical Research Council, Astellas and the Fungal Infection Trust. He acts as a consultant to Trinity group, T2 Biosystems, GSK, Sigma Tau, Oxon Epidemiology and Pulmicort. In the last 3 years, he has been paid for talks on behalf of Astellas, Gilead, Merck and Pfizer. He is also a member of the Infectious Disease Society of America Aspergillosis Guidelines and European Society for Clinical Microbiology and Infectious Diseases Aspergillosis Guidelines groups.

Acknowledgements

The authors would like to acknowledge the following.Mrs Chris Harris, manager of the NAC for helping out with patient identification and case note retrieval.

References

[1] D.A. Stevens, R.B. Moss, V.P. Kurup, A.P. Knutsen, P. Greenberger, M.A. Judson, et al., Allergic bronchopulmonary aspergillosis in cystic fibrosis – State of the art: cystic fibrosis foundation consensus conference, Clin. Infect. Dis. 37 (2003). S225–S64.

[2] C.G. Baxter, G. Dunn, A.M. Jones, K. Webb, R. Gore, M.D. Richardson, et al., Novel immunologic classification of aspergillosis in adult cystic fibrosis, J. Allergy Clin. Immunol. 132 (3) (2013), 560-+.

[3] R. Agarwal, A. Chakrabarti, A. Shah, D. Gupta, J.F. Meis, R. Guleria, et al.,

Please cite this article in press as: D. Lowes, et al., Development of chronic pulmonary aspergillosis in adult asthmatics with ABPA, Respiratory Medicine (2015), http://dx.doi.org/10.1016/j.rmed.2015.09.007

Allergic bronchopulmonary aspergillosis: review of literature and proposal of new diagnostic and classification criteria, Clin. Exp. Allergy 43 (8) (2013) 850–873.
[4] D.W. Denning, A. Pleuvry, D.C. Cole, Global burden of allergic bronchopulmonary aspergillosis with asthma and its complication chronic pulmonary aspergillosis in adults, Med. Mycol. 51 (4) (2013) 361–370.
[5] K. Varshokar, Diagnosis of allergic bronchopulmonary aspergillosis in asthmatic patients, J. Semnan Univ. Med. Sci. Fall Winter 3 (1,2) (2001-2002) 39–45.
[6] S.C. Donnelly, H. McLaughlin, C.P. Bredin, Period prevalence of allergic bronchopulmonary mycosis in a regional-hospital outpatient population in Ireland 1985-88, Ir. J. Med. Sci. 160 (9) (1991) 288–290.
[7] T. Eaton, M.B. Garrett, D. Milne, A. Frankel, A.U. Wells, Allergic bronchopulmonary aspergillosis in the asthma clinic – a prospective evaluation of CT in the diagnostic algorithm, Chest 118 (1) (2000) 66–72.
[8] A.F. Al-Mobeireek, M.O.G. El-Rab, S.S.A. Al-Hedaithy, K. Alasali, S. Al-Majed, I. Joharjy, Allergic bronchopulmonary mycosis in patients with asthma: period prevalence at a university hospital in Saudi Arabia, Respir. Med. 95 (5) (2001) 341–347.
[9] Y-L. Ma, W-B. Zhang, B. Yu, Y-W. Chen, S. Mu, Y-L. Cui, Prevalence of allergic bronchopulmonary aspergillosis in Chinese patients with bronchial asthma, Zhonghua jie he he hu xi za zhi = Zhonghua jiehe he huxi zazhi =, Chin. J. Tuberc. Respir. Dis. 34 (12) (2011) 909–913.
[10] R. Agarwal, D. Maskey, A.N. Aggarwal, B. Saikia, M. Garg, D. Gupta, et al., Diagnostic performance of various tests and criteria employed in allergic bronchopulmonary aspergillosis: a latent class analysis, PLoS One 8 (4) (2013) 7.
[11] K. Chawla, K. Kosaraju, S. Rayasam, C. Mukhopadhyay, Clinico-microbiological profile of chronic pulmonary aspergillosis from a tertiary care centre in southern India. Journal of clinical and diagnostic research, JCDR 7 (12) (2013) 2712–2715.
[12] K. Izumikawa, T. Tashiro, M. Tashiro, T. Takazono, K. Kosai, Y. Morinaga, et al., Pathogenesis and clinical features of chronic pulmonary aspergillosis – is it possible to distinguish CNPA and CCPA clinically? J. Infect. Chemother. 20 (3–4) (2014) 208–212.
[13] E. Muldoon, I. Page, P. Bishop, D. DW, P100: *Aspergillus* pulmonary nodules; presentation, radiology, and histological features, in: 6th Advances against Aspergillosis; Madrid, Spain, 2014.
[14] B. Camara, E. Reymond, C. Saint-Raymond, H. Roth, M.P. Brenier-Pinchart, C. Pinel, et al., Characteristics and outcomes of chronic pulmonary aspergillosis: a retrospective analysis of a tertiary hospital registry, Clin. Respir. J. 9 (1) (2015) 65–73.
[15] H. Ohba, S. Miwa, M. Shirai, M. Kanai, T. Eifuku, T. Suda, et al., Clinical characteristics and prognosis of chronic pulmonary aspergillosis, Respir. Med. 106 (5) (2012) 724–729.
[16] J. Jewkes, P. Kay, M. Paneth, K.M. Citron, Pulmonary aspergilloma – analysis of prognosis in relation to hemoptysis and survey of treatment, Thorax 38 (8) (1983) 572–578.
[17] B.W. Jhun, K. Jeon, J.S. Eom, J.H. Lee, G.Y. Suh, O.J. Kwon, et al., Clinical characteristics and treatment outcomes of chronic pulmonary aspergillosis, Med. Mycol. 51 (8) (2013) 811–817.
[18] H.S. Nam, K. Jeon, S.W. Um, G.Y. Suh, M.P. Chung, H. Kim, et al., Clinical characteristics and treatment outcomes of chronic necrotizing pulmonary aspergillosis: a review of 43 cases, Int. J. Infect. Dis. 14 (6) (2010). E479–E82.
[19] J.R. Tomlinson, S.A. Sahn, Aspergilloma in sarcoid and tuberculosis, Chest 92 (3) (1987) 505–508.
[20] D.W. Denning, A. Pleuvry, D.C. Cole, Global burden of allergic bronchopulmonary aspergillosis with asthma and its complication chronic pulmonary aspergillosis in adults, Med. Mycol. 51 (2013) 361–370.
[21] D.S. McCarthy, G. Simon, F.E. Hargreave, The radiological appearances in allergic broncho pulmonary aspergillosis, Clin. Radiol. 21 (4) (1970) 366–375.
[22] M.P.S. Menon, A.K. Das, Allergic bronchopulmonary aspergillosis (radiological aspects), Indian J. Chest Dis. Allied Sci. 19 (4) (1977), 157-&.
[23] M.S. Phelan, I.H. Kerr, Allergic bronchopulmonary aspergillosis – the radiological appearance during long-term follow-up, Clin. Radiol. 35 (5) (1984) 385–392.
[24] P.A. Greenberger, R. Patterson, A. Ghory, J.A. Arkins, T. Walsh, T. Graves, et al., Late sequelae of allergic bronchopulmonary aspergillosis, J. Allergy Clin. Immunol. 66 (4) (1980) 327–335.
[25] I. Kern, A. Lopert, Allergic bronchopulmonary aspergillosis with coexistant aspergilloma: a case report, J. Med. Case Rep. 4 (2010) 309.
[26] R. Agarwal, A.N. Aggarwal, M. Garg, B. Saikia, D. Gupta, A. Chakrabarti, Allergic bronchopulmonary aspergillosis with aspergilloma: an immunologically severe disease with poor outcome, Mycopathologia 174 (3) (2012) 193–201.
[27] N. Panchal, R. Bhagat, C. Pant, A. Shah, Allergic bronchopulmonary aspergillosis: the spectrum of computed tomography appearances, Respir. Med. 91 (4) (1997) 213–219.
[28] N.L. Smith, D.W. Denning, Underlying conditions in chronic pulmonary aspergillosis including simple aspergilloma, Eur. Respir. J. 37 (4) (2011) 865–872.
[29] K. Al-Shair, G.T.W. Atherton, D. Kennedy, G. Powell, D.W. Denning, A. Caress, Validity and reliability of the St. George's respiratory questionnaire in assessing health status in patients with chronic pulmonary aspergillosis, Chest 144 (2) (2013) 623–631.
[30] P.W. Jones, St. George's respiratory questionnaire: MCID, Copd 2 (1) (2005) 75–79.
[31] C.B. Wilson, P.W. Jones, C.J. Oleary, P.J. Cole, R. Wilson, Validation of the St. George's respiratory questionnaire in bronchiectasis, Am. J. Respir. Crit. Care Med. 156 (2) (1997) 536–541.
[32] P.W. Jones, F.H. Quirk, C.M. Baveystock, P. Littlejohns, A self-complete measure of health-status for chronic air-flow limitation – the St-Georges respiratory questionnaire, Am. Rev. Respir. Dis. 145 (6) (1992) 1321–1327.
[33] D.W. Denning, K. Riniotis, R. Dobrashian, H. Sambatakou, Chronic cavitary and fibrosing pulmonary and pleural aspergillosis: case series, proposed nomenclature change, and review, Clin. Infect. Dis. 37 (2003). S265–S80.
[34] C.G. Baxter, P. Bishop, S.E. Low, K. Baiden-Amissah, D.W. Denning, Pulmonary aspergillosis: an alternative diagnosis to lung cancer after positive F-18 FDG positron emission tomography, Thorax 66 (7) (2011) 638–640.
[35] S. Farid, S. Mohamed, M. Devbhandari, M. Kneale, M. Richardson, S.Y. Soon, et al., Results of surgery for chronic pulmonary aspergillosis, optimal antifungal therapy and proposed high risk factors for recurrence – a National Centre's experience, J. Cardiothorac. Surg. 8 (2013) 9.
[36] W.B. Gefter, D.M. Epstein, W.T. Miller, Allergic bronchopulmonary aspergillosis – less common patterns, Radiology 140 (2) (1981) 307–312.
[37] L. Chishimba, R.M. Niven, J. Cooley, D.W. Denning, Voriconazole and posaconazole improve asthma severity in allergic bronchopulmonary aspergillosis and severe asthma with fungal sensitization, J. Asthma 49 (4) (2012) 423–433.
[38] C.M. Roberts, K.M. Citron, B. Strickland, Intrathoracic aspergilloma: role of CT in diagnosis and treatment, Radiology 165 (1) (1987) 123–128.
[39] C.G. Baxter, D.W. Denning, A.M. Jones, A. Todd, C.B. Moore, M.D. Richardson, Performance of two aspergillus IgG EIA assays compared with the precipitin test in chronic and allergic aspergillosis, Clin. Microbiol. Infect. 19 (4) (2013) E197–E204.
[40] A. Chrdle, S. Mustakim, R.J. Bright-Thomas, C.G. Baxter, T. Felton, D.W. Denning, Aspergillus bronchitis without significant immunocompromise, Ann. N. Y. Acad. Sci. 1272 (2012) 73–85.
[41] A. Fairs, J. Agbetile, B. Hargadon, M. Bourne, W.R. Monteiro, C.E. Brightling, et al., IgE sensitization to aspergillus fumigatus is associated with reduced lung function in asthma, Am. J. Respir. Crit. Care Med. 182 (11) (2010) 1362–1368.
[42] D. Menzies, L. Holmes, G. McCumesky, C. Prys-Picard, R. Niven, Aspergillus sensitization is associated with airflow limitation and bronchiectasis in severe asthma, Allergy 66 (5) (2011) 679–685.
[43] S. Dhooria, P. Kumar, B. Saikia, A.N. Aggarwal, D. Gupta, D. Behera, et al., Prevalence of aspergillus sensitisation in pulmonary tuberculosis-related fibrocavitary disease, Int. J. Tuberc. Lung Dis. 18 (7) (2014) 850–855.
[44] R.W. Biagi, B.N. Bapat, Pulmonary function in aspergillus-sensitive asthma patients, Br. J. Clin. Pract. 24 (11) (1970) 470–474.
[45] M. Bafadhel, S. McKenna, J. Agbetile, A. Fairs, D. Desai, V. Mistry, et al., Aspergillus fumigatus during stable state and exacerbations of COPD, Eur. Respir. J. 43 (1) (2014) 64–71.
[46] Denning D. Fungal Infections > Corticosteroids 2014 [cited 2014 16 July 2014]. Available from: http://www.life-worldwide.org/fungal-diseases/corticosteroids1/.
[47] T.T.C. Ng, G.D. Robson, D.W. Denning, Hydrocortisone-enhanced growth of aspergillus spp – implications far pathogenesis, Microbiology 140 (1994) 2475–2479. Uk.
[48] J.Q. Mu, G.Q. Li, L.Q. Wei, Inhilation of glococorticosteroid in the rat model of blemycin-induced pulmonary fibrosis and its impact on the expression of basic fibroblast growth factor, Zhongguo Ying Yong Sheng Li Xue Za Zhi 26 (3) (2010) 330–333.
[49] C.A. Brandsma, W. Timens, M.R. Jonker, B. Rutgers, J.A. Noordhoek, D.S. Postma, Differential effects of fluticasone on extracellular matirx production by airway and parenchymal fibroblasts in severe COPD, Am. J. Physiol. Lung Cell. Mol. Physiol. 305 (8) (2013) L582–L589.
[50] R. Doffinger, C. Harris, S. Lear, P. Newton, H. Alachkar, D. Kumararatne, et al. (Eds.), Impaired Th1 and Th17 Immunity in Chronic Pulmonary Aspergillosis. 6th Advances against Aspergillosis (AAA 6th), 2014 (Madrid, Spain).
[51] M. Pendleton, D.W. Denning, Multifocal pulmonary aspergillomas: case series and review, Adv. against Aspergillosis I 1272 (2012) 58–67.
[52] A. Shah, J. Kala, S. Sahay, C. Panjabi, Frequency of familial occurrence in 164 patients with allergic bronchopulmonary aspergillosis, Ann. Allergy Asthma Immunol. 101 (4) (2008) 363–369.
[53] H. Sambatakou, V. Pravica, I.V. Hutchinson, D.W. Denning, Cytokine profiling of pulmonary aspergillosis, Int. J. Immunogenet. 33 (4) (2006) 297–302.
[54] N. Smith, P. Bowyer, A. Simpson, J. Hankinson, D. Denning, Reduced expression of TLR3, TLR10 and TREM1 by macrophages in CCPA, and novel genetic associations of VEGFA, DENND1B and PLAT with this disease, Clin. Microbiol. Infect. 20 (2014) O960–O968.
[55] N.L. Smith, P. Bowyer, A. Simpson, J. Hankinson, D.W. Denning, A prominent role for IL1 pathway and IL15 in susceptibility to chronic cavitary pulmonary aspergillosis, Clin. Microbiol. Infect. 20 (8) (2014) O480–O488.
[56] A. Tai, H. Tran, M. Roberts, N. Clarke, A.M. Gibson, S. Vidmar, et al., Outcomes of childhood asthma to the age of 50 years, J. Allergy Clin. Immunol. 133 (6) (2014), 1572-+.
[57] M. Holm, E. Omenaas, T. Gislason, C. Svanes, R. Jogi, E. Norrman, et al., Remission of asthma: a prospective longitudinal study from northern Europe (RHINE study), Eur. Respir. J. 30 (1) (2007) 62–65.
[58] D.W. Denning, C. Pashley, D. Hartl, A. Wardlaw, C. Godet, S. Del Giacco, et al., Fungal allergy in asthma-state of the art and research needs, Clin. Transl. Allergy 4 (2014), 14-.

Please cite this article in press as: D. Lowes, et al., Development of chronic pulmonary aspergillosis in adult asthmatics with ABPA, Respiratory Medicine (2015), http://dx.doi.org/10.1016/j.rmed.2015.09.007