UC Davis
Dermatology Online Journal

Title
Schnitzler syndrome in a patient with a family history of monoclonal gammopathy

Permalink
https://escholarship.org/uc/item/41x7q1z5

Journal
Dermatology Online Journal, 24(1)

Authors
Wilmas, Kelly
Aria, Alexander
Torres-Cabala, Carlos A
et al.

Publication Date
2018-01-01

License
CC BY-NC-ND 4.0

Peer reviewed

eScholarship.org Powered by the California Digital Library
University of California

Volume 24 Number 1 | January 2018
24 (1): 5

Schnitzler syndrome in a patient with a family history of monoclonal gammopathy

Kelly Wilmas[1,2] BS, Alexander Aria[1,2] BS, Carlos A Torres-Cabala[3] MD, Huifang Lu[4] MD, Madeleine Duvic[2] MD

Affiliations:

[1]University of Texas Health Science Center, McGovern Medical School, Houston, Texas, [2]Department of Dermatology, The University of Texas MD Anderson Cancer Center, Houston, Texas, [3]Department of Pathology, The University of Texas MD Anderson Cancer Center, Houston, Texas, [4]Department of General Internal Medicine, The University of Texas MD Anderson Cancer Center, Houston, Texas

Corresponding Author: Kelly Wilmas, University of Texas Health Science Center, McGovern Medical School, 6431 Fannin Street, Houston, Texas, 77030, Tel: (682) 225-4986, Email: Kelly.M.Wilmas@uth.tmc.edu

Abstract

Schnitzler syndrome is a rare disease characterized by chronic urticaria and a monoclonal gammopathy, most commonly IgM with light chains of the kappa type. There are currently no known risk factors associated with development of the disease. We report a case of Schnitzler syndrome in a 48-year-old man with a family history of monoclonal gammopathies. The patient's disease has been well controlled with anakinra therapy. Our case may contribute to a better understanding of the etiology of Schnitzler syndrome as his history could suggest a hereditary predisposition for the disease. Further studies are necessary to determine whether a genetic component of Schnitzler syndrome exists, as first-degree relatives of patients with monoclonal gammopathies may be at risk for the development of the disease.

Keywords: Schnitzler syndrome, monoclonal gammopathy, Waldenström macroglobulinemia, multiple myeloma

Introduction

Schnitzler syndrome is a rare disease characterized by painful, chronic urticaria and a monoclonal gammopathy, most commonly IgM with kappa light chains; median age of onset is 55 years and there is a slight male predominance [1-3]. {de Koning, 2007 #49} The urticaria in Schnitzler syndrome is non-pruritic in more than half of cases [1]. Symptoms can be debilitating and include recurrent fevers, lymphadenopathy, bone pain, and arthralgias [1]. Hepatomegaly and splenomegaly occur less commonly [1]. It is associated with abnormal bone morphology and inflammatory markers such as an elevated erythrocyte sedimentation rate (ESR), C-reactive protein (CRP), and leukocytosis [2]. Schnitzler syndrome is thought to be an acquired auto-inflammatory disorder mediated by the cytokine interleukin-1 (IL-1). However, the exact pathogenesis and link to the monoclonal gammopathy has yet to be fully understood [2, 3].

Case Synopsis

We report a 48-year-old man with no significant past medical history who presented to his primary care physician with painful, non-pruritic urticaria on the anterior trunk and proximal extremities in addition to body aches that occurred while completing a course of trimethoprim-sulfamethoxazole for an upper respiratory infection. The urticaria resolved when his primary care physician initially treated him with a prednisone injection, but it slowly reappeared days later. Oral prednisone ranging from dosages of 15 to 50 mg was prescribed, but the urticaria recurred with tapering.

Nine months after clinical onset, he presented to our clinic with faintly erythematous papules coalescing into plaques on the trunk and proximal extremities (**Figure 1**). The patient was taking 15 mg of prednisone and 50 mg of dapsone daily. A lesional skin biopsy of the left flank showed a superficial perivascular and interstitial infiltrate with neutrophils (**Figure 2**). Immunohistochemistry showed accentuation of IgM at the dermal-epidermal junction (**Figure 3**). Serum laboratory results demonstrated an elevated ESR of

Volume 24 Number 1 | January 2018
24 (1): 5

Figure 1. *A) Erythematous urticarial papules coalescing into plaques of the anterior trunk.*

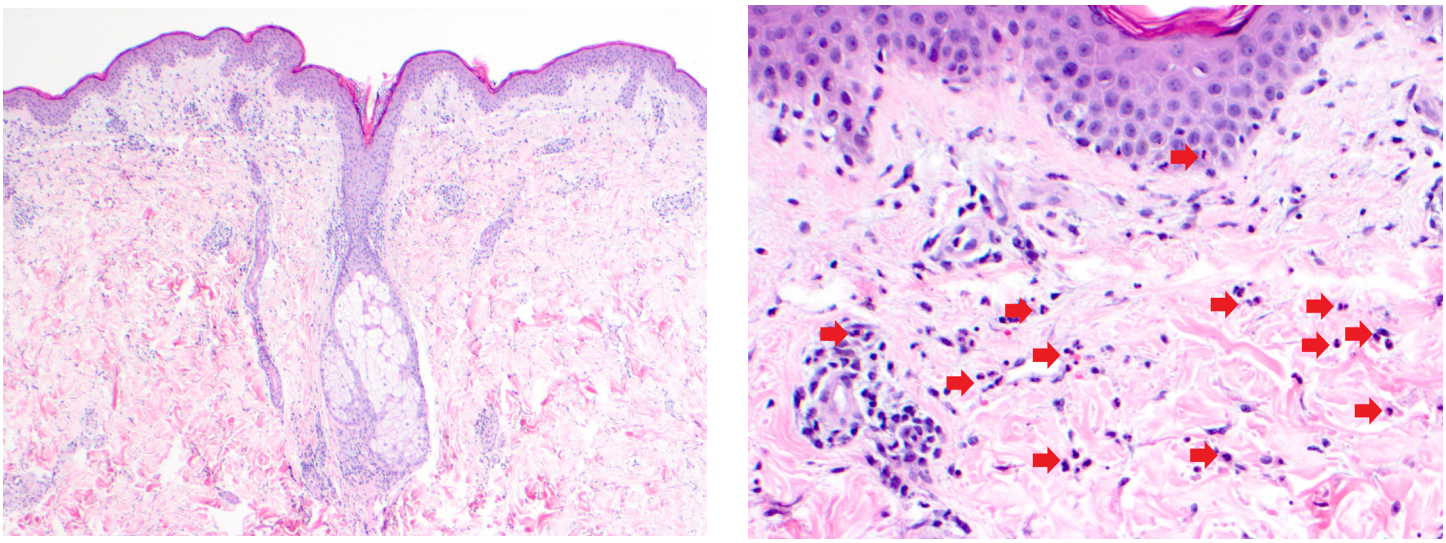

Figure 2. *A) A skin biopsy from the left flank demonstrated a mild superficial and interstitial perivascular infiltrate. H&E, 40%. B) The infiltrate was composed of mononuclear cells and numerous neutrophils (arrows). H&E, 200%.*

33, leukocytosis of 25.1, an IgM spike of 0.5 grams/dL, an elevated total IgM of 1347, normal range kappa light chains at 16.62, increased lambda light chains at 21.96, and a kappa to lambda ratio of 0.58. Anti-nuclear antibody, thyroid peroxidase antibody, and HIV testing were negative. Flow cytometry identified no aberrant T-cell population and bone marrow biopsy showed no morphologic evidence of lymphoma. CT chest, abdomen, and pelvis were negative. The patient's family history was significant for a diagnosis of Waldenström macroglobulinemia (WM) in his father and multiple myeloma in his cousin.

Owing to his chronic urticaria, IgM monoclonal gammopathy, history of recurrent fever, body aches, leukocytosis, and elevated inflammatory markers, a diagnosis of Schnitzler syndrome was made. He was instructed to discontinue dapsone, continue

Volume 24 Number 1 | January 2018
24 (1): 5

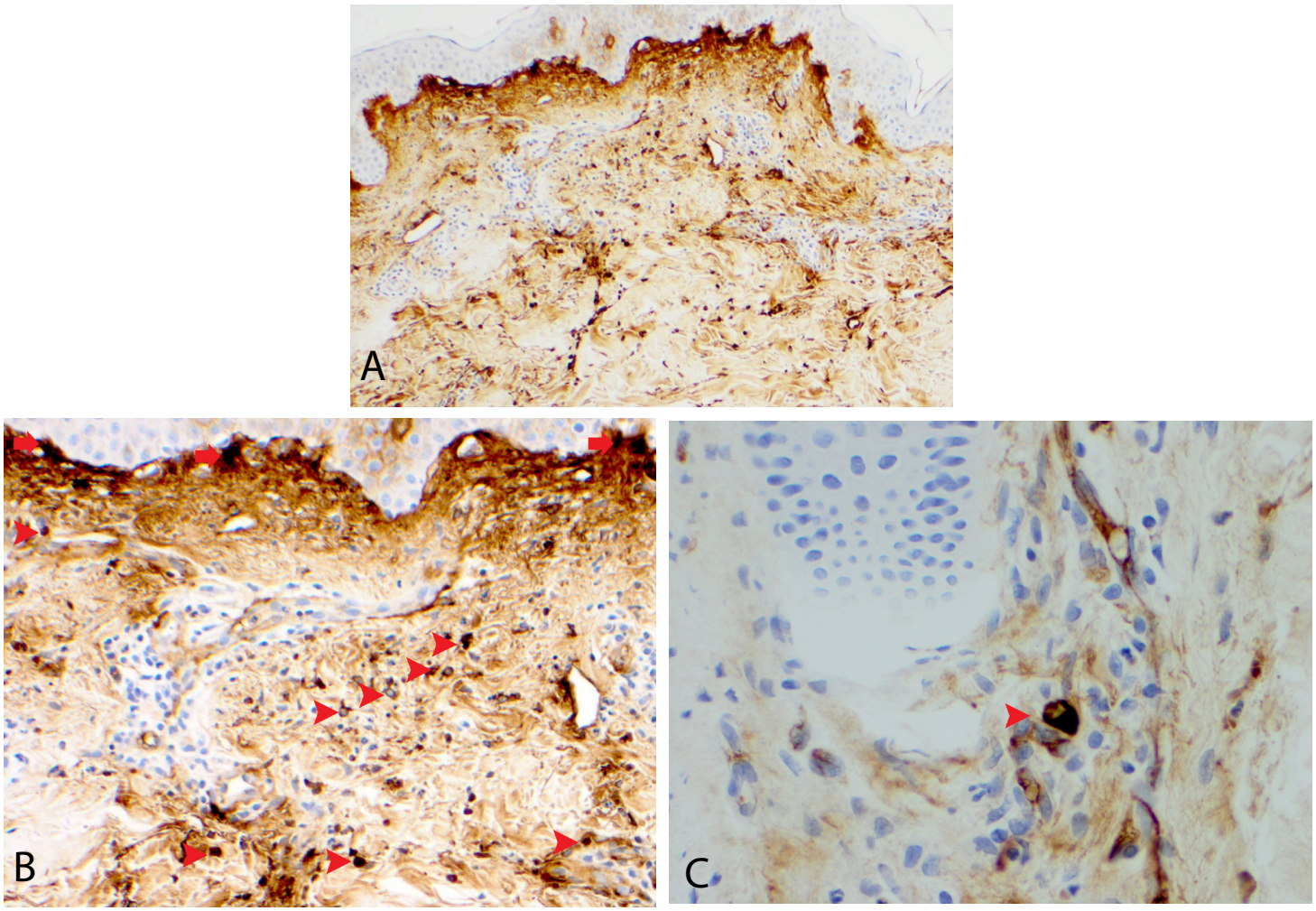

Figure 3. *A) Low magnification view of an immunohistochemical study for IgM (immunoperoxidase, 10%). B) Higher magnification reveals deposits of IgM at the dermal-epidermal junction (arrows) and scattered IgM-positive plasma cells (arrow heads, immunoperoxidase, 200%). C) An IgM-positive plasma cell (arrow head, immunoperoxidase, 400%)*

Table 1.

Lipsker Diagnostic Criteria	Strasbourg Diagnostic Criteria
Urticaria and monoclonal IgM plus 2 of the following criteria:	Chronic urticaria AND Monoclonal IgM and 2 of the following criteria OR monoclonal IgG with 3 of the following criteria:
Fever	Recurrent fever
Abnormal bone morphologic studies	Abnormal bone morphologic studies with or without bone pain
Leukocytosis	Leukocytosis and/or elevated CRP
Elevated ESR	Neutrophilic dermal infiltrate on skin histology
Bone pain	
Arthralgia/arthritis	
Hepatomegaly or splenomegaly	
Lymphadenopathy	

to taper prednisone, and start triamcinolone 0.1% cream twice daily. With tapering, the patient had a flare with a worsening rash on his trunk associated with fever and body aches. The combination of 100 mg of subcutaneous anakinra every other day with oral prednisone resolved the urticaria. He remained free of skin lesions while on anakinra. The patient felt well and denied fever, arthralgias, myalgias, urticaria, numbness, tingling, uveitis, and other symptoms while on the medication.

After taking anakinra for four years without recurrence of symptoms, the patient discontinued the medication. Four days later, he developed systemic inflammation with generalized body aches, stiffness, and painful urticaria. At that time, his serum protein electrophoresis showed an IgM monoclonal gammopathy unchanged from his initial presentation. The kappa light chains had increased to 21.96 and the lambda light chains increased to 40.25, but the kappa to lambda ratio was comparable at 0.55. His symptoms resolved with re-initiation of therapy; thus, continuous use of the medication was deemed necessary. To date, the patient's disease has been well controlled with anakinra therapy.

Case Discussion

Schnitzler syndrome can be difficult to diagnose due to non-specific symptoms and lack of disease awareness amongst caregivers, causing a five-year delay in treatment on average [4]. Treatment with anakinra induces remission of symptoms and signs of inflammation [5]. Anakinra is the recombinant form of interleukin 1 receptor antagonist (IL1-Ra) that blocks the pro-inflammatory effects of the cytokine IL-1 by binding to the IL-1 receptor. The drug is administered as a prefilled subcutaneous injection of 100 mg and is typically administered once daily for therapeutic effectiveness. Despite treatment with anakinra, the monoclonal gammopathy persists, posing the question of whether the monoclonal gammopathy is the cause or product of the disease process [3]. Hematologic disorders such as Waldenström macroglobulinemia or secondary amyloidosis can be seen later in Schnitzler syndrome [2, 3].

Our patient met both the Strasbourg and Lipsker diagnostic criteria for Schnitzler syndrome (**Table 1**). In a study of 42 patients with Schnitzler syndrome, Gusdorf et al. found a sensitivity of 81% and a specificity of 100% for the Strausbourg criteria of definite diagnosis as well as a sensitivity of 100% and specificity of 97% for the Lipsker criteria [6]. These two sets of criteria appear to be reliable for the diagnosis of Schnitzler syndrome. There have been around 300 cases of Schnitzler syndrome described in the literature [7]. Our patient's lambda light chain-predominant IgM monoclonal gammopathy is uncommon, as the vast majority of cases are kappa light chain-predominant [8].

There are currently no risk factors or indications that Schnitzler syndrome is a familial disorder. However, the disease is uncommon and the availability of data is limited. If an inheritance pattern is found for a family of patients in whom Schnitzler syndrome is suspected, cryopyrin-associated periodic syndrome (CAPS) should be considered. Schnitzler syndrome has been described as an acquired autoimmune disorder without familial inheritance [2]. CAPS is caused by an autosomal dominant mutation in *NLRP3* (NACHT, LRR and PYD domains-containing protein 3), along with an inflammasome that triggers an inflammatory response through the activation of caspase-1 and release of IL-1β [9]. The mutation leads to spontaneous activation of the inflammasome and uncontrolled secretion of IL-1β. Similar to Schnitzler syndrome, it is a disorder characterized by recurrent fever, urticaria with a neutrophilic infiltrate on biopsy, and an increase in CRP [2]. CAPS also responds well to daily injections of anakinra [5]. Differences between Schnitzler syndrome and CAPS include a lack of monoclonal paraproteinemia in CAPS as well as the average age of onset (greater 50 years in Schnitzler syndrome versus less than 50 years in CAPS). De Koning et al described the unique phenomenon of somatic mosaicism of *NLRP3* in the myeloid lineage of two patients with variant (IgG) Schnitzler syndrome [10]. The authors conjectured that there is a possibility that late-onset sporadic diseases such as Schnitzler syndrome may have a genetic basis.

The presence of WM in our patient's father and multiple myeloma in his cousin is quite interesting, since other monoclonal gammopathies share a certain degree of familial inheritance. Treon et al. found that 18.7% of patients (n = 257) with WM had at least one first-degree relative with WM or another

B-cell disorder [11]. Additionally, a Swedish study of 2144 lymphoplasmacytic lymphoma/Waldenström macroglobulinemia (LPL/WPW) patients found that first-degree relatives of these patients had a 20-fold increased risk of developing LPL/WM [12]. WM is almost always a manifestation of LPL, a mature B cell lymphoma. One retrospective review of 94 patients with Schnitzler syndrome reported one other patient with a family history of monoclonal gammopathy in his father [1]. It is possible that our patient had a hereditary predisposition for the development of Schnitzler syndrome and patients with Schnitzler syndrome should be included in future studies on the inheritance of monoclonal gammopathies.

Conclusion

Because urticaria is a fairly common entity in a dermatology clinic, the coexistence of painful urticaria, fever, and elevated inflammatory markers should raise a suspicion of Schnitzler syndrome and lead to further workup with serum immuno-electrophoresis. The effectiveness of anakinra therapy for this rare disorder cannot be overemphasized and it may be necessary for patients to take anakinra indefinitely to prevent recurrence of disease. Further studies are necessary to determine whether a genetic component of Schnitzler syndrome exists, as first-degree family members of patients with Schnitzler syndrome, Waldenström macroglobulinemia, or other monoclonal gammopathies may be at risk for this disease.

References

1. de Koning HD, Bodar EJ, van der Meer JW, Simon A, Schnitzler Syndrome Study G. Schnitzler syndrome: beyond the case reports: review and follow-up of 94 patients with an emphasis on prognosis and treatment. *Semin Arthritis Rheum*. 2007;37(3):137-48. Epub 2007/06/26. [PMID: 17586002].
2. Gusdorf L, Lipsker D. Schnitzler Syndrome: a Review. *Curr Rheumatol Rep*. 2017;19(8):46. Epub 2017/07/19. [PMID: 28718061].
3. Lipsker D. Monoclonal gammopathy of cutaneous significance: review of a relevant concept. *J Eur Acad Dermatol Venereol*. 2017;31(1):45-52. Epub 2016/08/09. [PMID: 27501129].
4. Lipsker D. The Schnitzler syndrome. *Orphanet J Rare Dis*. 2010;5:38. Epub 2010/12/15. [PMID: 21143856].
5. Kalliolias GD, Liossis SN. The future of the IL-1 receptor antagonist anakinra: from rheumatoid arthritis to adult-onset Still's disease and systemic-onset juvenile idiopathic arthritis. *Expert Opin Investig Drugs*. 2008;17(3):349-59. Epub 2008/03/07. [PMID: 18321234].
6. Gusdorf L, Asli B, Barbarot S, Neel A, Masseau A, Puechal X, Gottenberg JE, Grateau G, Blanchard-Delaunay C, Rizzi R, Lifermann F, Kyndt X, Aubin F, Bessis D, Boye T, Gayet S, Rongioletti F, Sauleau E, Fermand JP, Lipsker D. Schnitzler syndrome: validation and applicability of diagnostic criteria in real-life patients. *Allergy*. 2017;72(2):177-82. Epub 2016/08/27. [PMID: 27564982].
7. de Koning HD. Schnitzler's syndrome: lessons from 281 cases. *Clin Transl Allergy*. 2014;4:41. Epub 2014/01/01. [PMID: 25905009].
8. Lagana B, Podesta E, Picchianti Diamanti A, Salerno G, Di Rosa R, D'Amelio R. Schnitzler's syndrome with biclonal gammopathy successfully treated with hydroxychloroquine and low dose steroids. *Clin Exp Rheumatol*. 2008;26(6):1161. Epub 2009/02/13. [PMID: 19210890].
9. Hughes FM, Jr., Kennis JG, Youssef MN, Lowe DW, Shaner BE, Purves JT. The NACHT, LRR and PYD Domains-Containing Protein 3 (NLRP3) Inflammasome Mediates Inflammation and Voiding Dysfunction in a Lipopolysaccharide-Induced Rat Model of Cystitis. *J Clin Cell Immunol*. 2016;7(1). Epub 2016/04/12. [PMID: 27066297].
10. de Koning HD, van Gijn ME, Stoffels M, Jongekrijg J, Zeeuwen PL, Elferink MG, Nijman IJ, Jansen PA, Neveling K, van der Meer JW, Schalkwijk J, Simon A. Myeloid lineage-restricted somatic mosaicism of NLRP3 mutations in patients with variant Schnitzler syndrome. *J Allergy Clin Immunol*. 2015;135(2):561-4. Epub 2014/09/23. [PMID: 25239704].
11. Treon SP, Hunter ZR, Aggarwal A, Ewen EP, Masota S, Lee C, Santos DD, Hatjiharissi E, Xu L, Leleu X, Tournilhac O, Patterson CJ, Manning R, Branagan AR, Morton CC. Characterization of familial Waldenstrom's macroglobulinemia. *Ann Oncol*. 2006;17(3):488-94. Epub 2005/12/17. [PMID: 16357024].
12. Kristinsson SY, Bjorkholm M, Goldin LR, McMaster ML, Turesson I, Landgren O. Risk of lymphoproliferative disorders among first-degree relatives of lymphoplasmacytic lymphoma/Waldenstrom macroglobulinemia patients: a population-based study in Sweden. *Blood*. 2008;112(8):3052-6. Epub 2008/08/16. [PMID: 18703425].