ARTICLE IN PRESS

Journal of Immunological Methods xxx (xxxx) xxx–xxx

Contents lists available at ScienceDirect

Journal of Immunological Methods

journal homepage: www.elsevier.com/locate/jim

Research paper

An optimized protocol for the analysis of house dust mite (*Dermatophagoides farinae*)-induced neutrophil-dominant airway inflammation

Tomoko Wada[a,1], Kiyoshi Hirahara[a,b,1], Ami Aoki[a], Yuki Morimoto[a,c], Masahiro Kiuchi[a], Jin Kumagai[a], Mikiko Okano[a], Kota Kokubo[a], Miki Kato[a], Chiharu Fukano[d], Katsuyo Ohashi-Doi[d], Toshinori Nakayama[a,e,*]

[a] Department of Immunology, Graduate School of Medicine, Chiba University, 1-8-1 Inohana, Chuo-ku, Chiba 260-8670, Japan
[b] AMED-PRIME, AMED, 1-8-1 Inohana, Chuo-ku, Chiba 260-8670, Japan
[c] Department of Otorhinolaryngology, Head and Neck Surgery, Graduate School of Medicine, Chiba University, 1-8-1 Inohana, Chuo-ku, Chiba 260-8670, Japan
[d] Research Laboratory, Torii Pharmaceutical Co. Ltd, Sakura, Chiba, Japan
[e] AMED-CREST, AMED, 1-8-1 Inohana, Chuo-ku, Chiba 260-8670, Japan

ARTICLE INFO

Keywords:
House dust mites (HDMs)
D. farina
Neutrophil-dominant airway inflammation
Cell clusters

ABSTRACT

House dust mites (HDMs), *Dermatophagoides* sp., are one of the most widespread aeroallergens worldwide and cause various allergic diseases, including asthma. The pathophysiology of asthma has been intensively investigated using murine models of allergic airway inflammation induced by exposure to *D. pteronyssinus*. However, the pathogenic roles of *D. farinae* in the allergic airway inflammation remains unclear. We herein report that repetitive exposure to *D. farinae* resulted in neutrophil-dominant airway inflammation together with fibrotic changes and the formation of lymphoid clusters. Both type 1 and type 2 inflammatory cytokines were induced. The pathogenic changes in the airway were dependent on both the frequency and dose of *D. farinae* exposure. Our study provides novel procedures and insight into the pathogenesis of *D. farinae*-induced airway inflammation in vivo.

1. Introduction

Allergic asthma is characterized by chronic airway inflammation that induces mucus hyperproduction, airway hyperresponsiveness (AHR), airway remodeling and variable airway obstruction (Lambrecht and Hammad, 2015). A number of environmental antigens cause allergic reactions in the mucosal tissue, including the respiratory tract. The house dust mite (HDM) is a major perennial indoor allergen that is globally ubiquitous in a living environment and induces a number of allergic inflammatory diseases, such as allergic asthma (Calderon et al., 2015).

Approximately 85% of asthmatics are typically allergic to HDMs (Nelson Jr. et al., 1996). The use of the antigen ovalbumin accompanied by adjuvant has been switched to use of HDM extract in murine models of allergic airways disease for asthma research. HDMs contain a variety of allergens, such as proteases, immunogenic epitopes, lipopolysaccharide (LPS) and polysaccharide chitin, that can activate both the innate and acquired immune systems and induce potent type 2 immune response (Gregory and Lloyd, 2011). Both adaptive and innate immunity are involved in the inflammatory responses induced by exposure to HDM extract (Hammad et al., 2009; Coquet et al., 2015; Hondowicz et al., 2016; Ballesteros-Tato et al., 2016; Ito et al., 2017). HDMs induce airway inflammatory responses via various types of receptors, such as Toll-like receptor (TLR) 2, TLR4, Dectin-1 and Dectin-2 (Gregory and Lloyd, 2011; Hammad et al., 2009; Ito et al., 2017; Norimoto et al., 2014). HDM exposure induces HDM-specific tissue-resident memory $CD4^+$ T cells that are sufficient to induce inflammatory responses during HDM-induced allergic inflammation (Hondowicz et al., 2016). HDMs also induce T helper 17 (Th17) cells and T follicular helper (Tfh) cells in allergic airway inflammation (Coquet et al., 2015).

More than 50,000 species of HDM have been identified (Gregory

Abbreviations: HDMs, House dust mites; AHR, airway hyperresponsiveness; *D. farina*, *Dermatophagoides farina*; BAL, bronchoalveolar lavage; MHC class II, major histocompatibility complex class II; *Muc5ac*, *Mucin-5 subtype AC*; *Col1a1*, *Collagen type 1 alpha 1*; iBALT, Inducible bronchus-associated lymphoid tissue; FDCs, follicular dendritic cells; DCs, dendritic cells; HEVs, high endothelial venules

* Corresponding author at: 1-8-1 Inohana, Chuo-ku, Chiba-shi, Chiba 260-8670, Japan.
E-mail address: tnakayama@faculty.chiba-u.jp (T. Nakayama).

[1] These authors are equally contributed to this work.

https://doi.org/10.1016/j.jim.2018.12.003
Received 12 October 2018; Received in revised form 8 December 2018; Accepted 10 December 2018
0022-1759/ © 2018 Elsevier B.V. All rights reserved.

and Lloyd, 2011). *Dermatophagoides pteronyssinus* and *D. farinae* are the major species of HDM that induce allergic responses. *D. pteronyssinus* and *D. farinae* have similar life cycles; they reach adulthood within four weeks of hatching and spend another four to six weeks as adult mites (Calderon et al., 2015). During their lifetime, HDMs will produce a large number of both fecal particles and partially digested enzyme-covered dust particles (van Bronswijk and Sinha, 1971). The pathogenic roles of *D. pteronyssinus* and its allergen the Der p family have been intensively investigated; however, the roles of *D. farinae* and its allergen the Der f family in the induction of allergic airway inflammation remains unclear. Furthermore, *D. farinae* have been detected more frequently than *D. pteronyssinus* in household living environments in the United States, Japan and continental Europe (Calderon et al., 2015). Thus, it is crucial to determine the pathogenic roles of *D. farinae* and its allergen Der f in the induction of allergic airway inflammation.

In the present study, repetitive exposure to *D. farinae* induced airway inflammation characterized by neutrophil-dominant infiltration in the bronchoalveolar lavage (BAL) fluid along with increased mucus production and fibrotic changes around the bronchi. We also found that airway inflammation induced by repetitive exposure to *D. farinae* allergen manifested in a dose-dependent manner. Taken together, our results provide evidence that *D. farinae* induces allergic airway inflammation and findings that will prove useful for establishing an appropriate protocol for investigating the asthmatic responses induced by *D. farinae*.

2. Material and methods

2.1. Mice

BALB/c mice were purchased from CLEA Japan (Tokyo, Japan). All mice were used at five to eight weeks of age and maintained under specific-pathogen-free conditions. All animals used in this study were female. Female littermates were randomly assigned to experimental groups. The research proposals were reviewed by the ethics committee for animals at Chiba University (registration number: 29-98, 29-99).

2.2. Induction of lung inflammation via the intranasal administration of D. farinae

To induce allergic airway inflammation, 3-day consecutive intranasal administration with *D. farinae* (50 μg) was performed in BALB/c mice for 1, 2, or 3 weeks. In other experiments, 3-day consecutive intranasal administration with *D. farinae* (0.5, 5, or 50 μg) was performed in BALB/c mice for 3 weeks. Assays were performed 24 h after the last antigen administration. The extracts of *D. farinae* were provided by Torii Pharmaceutical Co., Ltd. (Tokyo, Japan).

2.3. Histology and immunofluorescence

Pathological changes were evaluated by hematoxylin & eosin (H&E), Sirius-Red staining, and immunofluorescent staining as previously described (Hirahara et al., 2008; Shinoda et al., 2016). The quantification of fibrotic changes was performed as described previously (Morimoto et al., 2018). The area of peribronchial Sirius Red staining in a paraffin-embedded lung was outlined and quantified using a light microscope (BIOREVO; KEYENCE Corp., Osaka, Japan) attached to an image-analysis system (Photoshop; Adobe Systems Inc., San Jose, CA, USA). The results are expressed as the area of Sirius Red staining per micrometer length of the basement membrane of bronchioles with a 100-μm internal diameter. Cryostat sections of lungs were stained and mounted with Fluorescent mounting medium (DakoCytomation, Glostrup, Denmark). All immunofluorescent histological analyses were carried out with a confocal laser microscope (LSM710; Carl Zeiss, Oberkochen, Germany). Anti-CD4 (RM4-5, 20-0042-U100, TONBO Biosciences, CA, USA; and GK1.5, 12-0041-85, eBioscience, CA, USA), anti-MHC class ll (2G9, 553623; BD, NJ, USA) were used for staining lung samples.

2.4. Quantitative real-time polymerase chain reaction

Total RNA isolation, cDNA synthesis, and quantitative real-time polymerase chain reaction (PCR) was performed as described previously (Onodera et al., 2017). Primers and Roche Universal probes were purchased from Sigma (MO, USA) and Roche (Basel, Switzerland), respectively. Primers and TaqMan probes were purchased from Applied Biosystems (CA, USA). Gene expression was normalized with the *Hprt* mRNA signals.

2.5. Measurement of the airway hyperresponsiveness

The airway function was assessed by measuring the changes in lung resistance in response to increasing doses of inhaled methacholine, as described previously (Hirahara et al., 2008).

2.6. Statistical analyses

Data were analyzed with the GraphPad Prism software program (version 7; CA, USA). Comparisons of two groups were made with an unpaired *t*-test or two-way analysis of variance (ANOVA) with Bonferroni's multiple comparisons test. Differences with *p*-values below 0.05 were considered significant.

3. Results

3.1. Repetitive exposure to D. farinae allergen induces a neutrophil-dominant type of airway inflammation accompanied by airway fibrotic responses

The pathogenic roles of the *D. farinae* allergen during airway inflammation have been unclear. The degree of airway inflammation was therefore assessed in groups of mice that had received 1, 2, or 3 daily administrations of *D. farinae* allergen for 3 consecutive days followed by 4 days off-treatment (Fig. 1A). *D. farinae* allergen exposure three times resulted in a significant increase in the infiltration of inflammatory cells, especially neutrophils, in the BAL fluid ($p < .0001$, 2-way ANOVA) (Fig. 1B). In contrast, *D. farinae* allergen exposure once or twice induced only the slight infiltration of inflammatory cells in the BAL fluid (Fig. 1B). Consistent with these results, the intra-nasal administration of *D. farinae* allergen once or twice resulted in the slight infiltration of inflammatory cells around the bronchi (Fig. 1C and D).

However, the intra-nasal administration of *D. farinae* allergen for 3 weeks resulted in the massive infiltration of inflammatory cells around the bronchi (Fig. 1C and D). Furthermore, mice that had received the intra-nasal administration of *D. farinae* allergen three times showed mucus hyperplasia accompanied by increased fibrotic changes (Fig. 2A and B). A histological analysis of the lungs of mice that had received the intra-nasal administration of *D. farinae* allergen for 3 weeks showed the formation of lymphoid clusters containing $CD4^+$ T cells as well as MHC class ll^+ cells and $B220^+$ cells (Fig. 2C and D). Thus, exposure to *D. farinae* allergen three times caused the induction of a neutrophil-dominant type of airway inflammation accompanied by airway fibrotic responses and the formation of lymphoid clusters.

3.2. Repetitive exposure to D. farinae allergen induces the enhanced expression of cytokines in the lung along with enhanced airway hyperresponsiveness

The lungs from mice administered *D. farinae* allergen exhibited the elevated expression of effector cytokines and neutrophil-recruiting chemokines, such as *Ifng*, *Il4*, *Il5*, *Il13*, *Il17*, *Cxcl1*, *Cxcl2*, and *Cxcl3*, along with the enhanced expression of *Mucin-5 subtype AC* (*Muc5ac*)

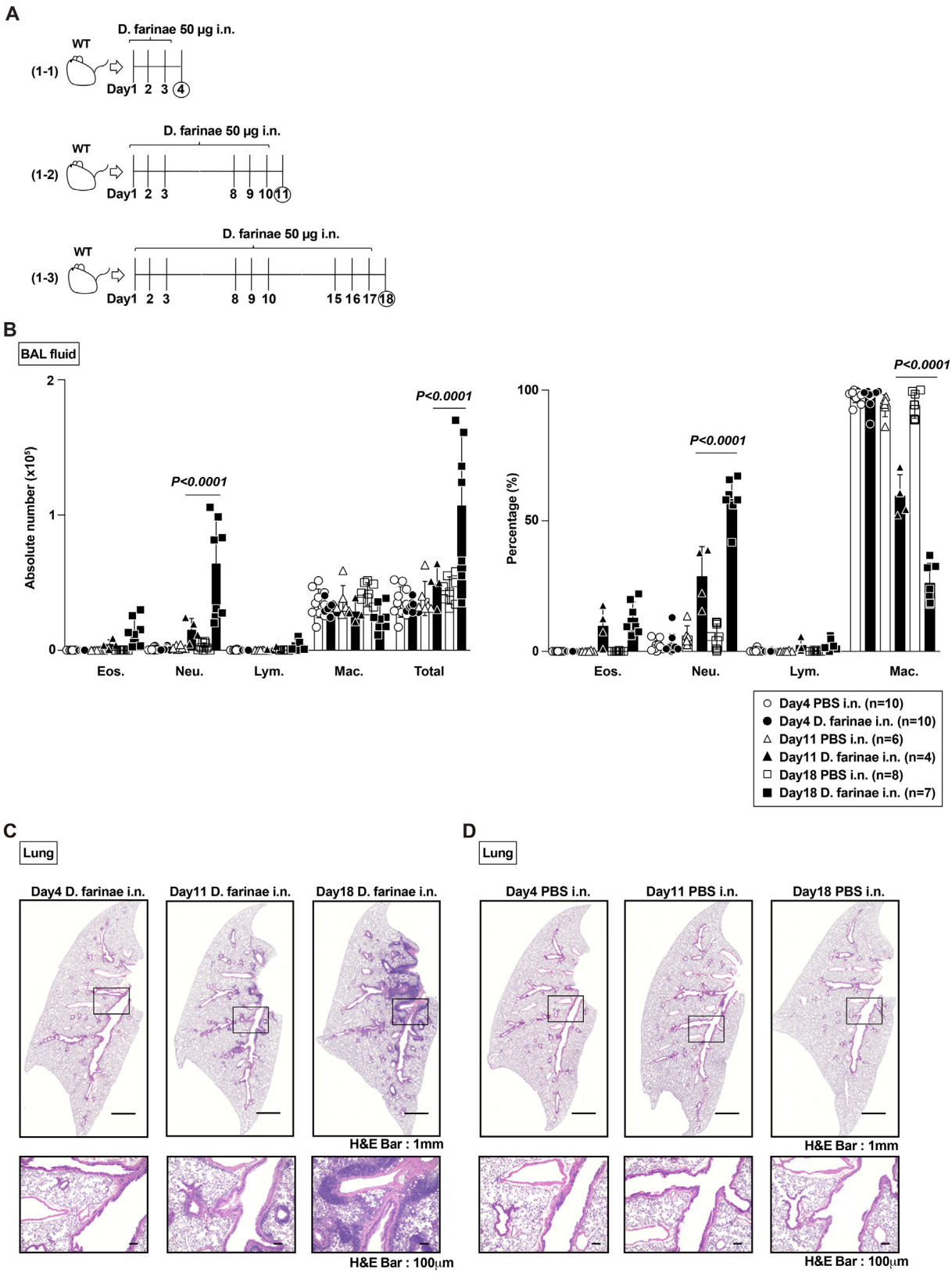

Fig. 1. Repetitive exposure to *D. farinae* allergen resulted in a neutrophil-dominant type of airway inflammation. (A) An experimental schematic illustration for the exposure to *D. farinae* allergen is depicted. (B) The absolute cell number (left) and percentage (right) of eosinophils (Eos.), neutrophils (Neu.), lymphocytes (Lym.), macrophages (Mac.), and total cells (Total) in the BAL fluid from PBS-exposed mice (PBS i.n.) or *D. farinae*-exposed mice (*D. farinae* i.n.) (n = 4–10 mice per group). (C) Representative histological sections of lungs on days 4, 11, or 18 stained with Hematoxylin and Eosin from *D. farinae*-exposed mice (*D. farinae* i.n.). Scale bars represent 1 mm (top) or 100 μm (bottom). (D) Representative histological sections of lungs on days 3, 10, or 17 stained with Hematoxylin and Eosin from PBS-exposed mice (PBS i.n.) on days 4, 11, and 18. Scale bars represent 1 mm (top) or 100 μm (bottom). Data are shown as the mean ± SD in B. *P*-values were calculated with a two-way ANOVA with Bonferroni's multiple comparisons test in B.

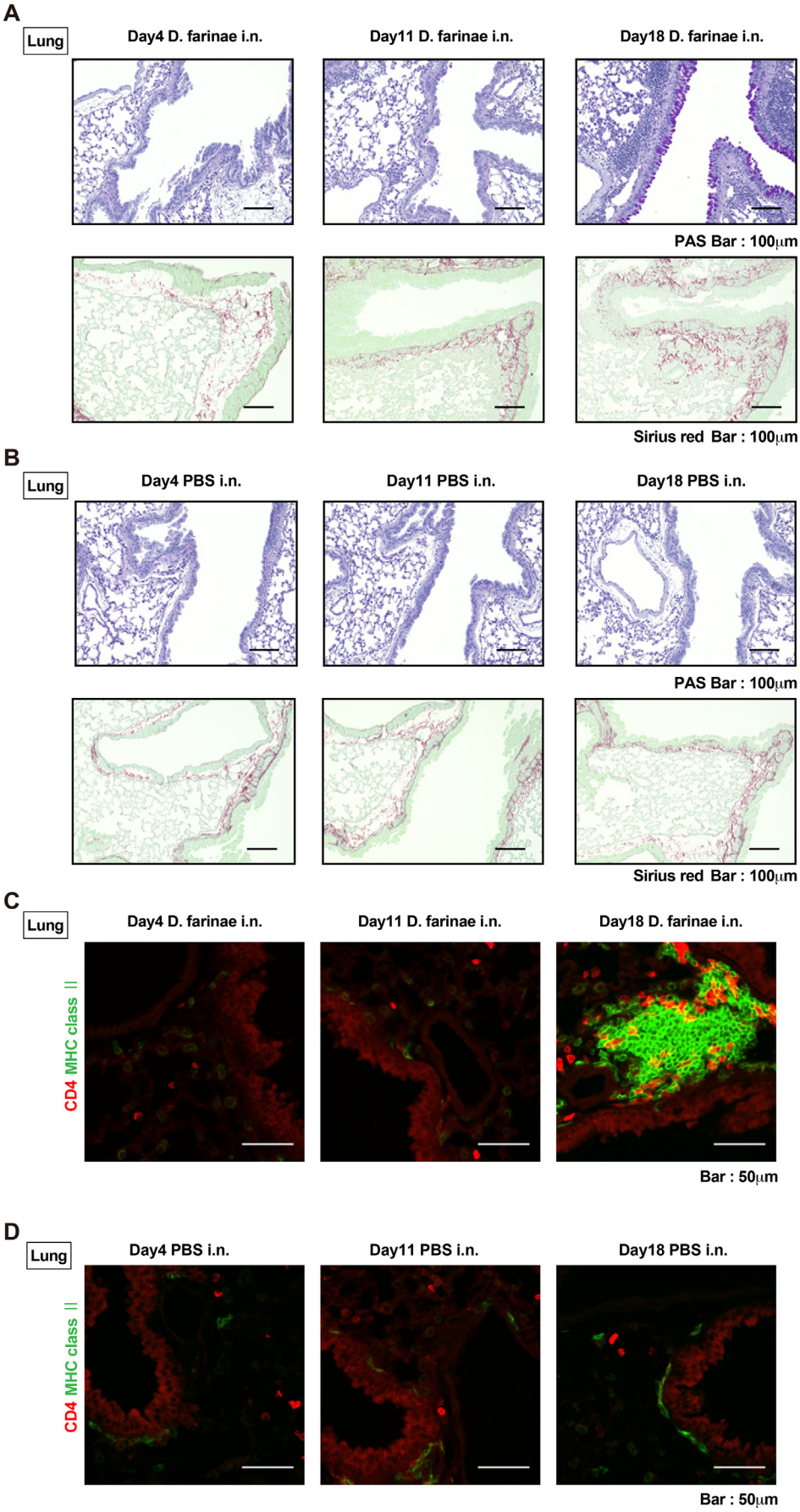

Fig. 2. Repetitive exposure to *D. farinae* allergen induced the formation of cell clusters. (A) Representative histological sections of lungs on days 4, 11, or 18 stained with PAS staining (top) and Sirius Red staining (bottom) from *D. farinae*-exposed mice (*D. farinae* i.n.). Scale bars represent 100 μm. (B) Representative histological sections of lungs on days 4, 11, or 18 stained with PAS staining (top) and Sirius Red staining (bottom) from PBS-exposed mice (PBS i.n.). Scale bars represent 100 μm. (C) Representative confocal micrograph of lung stained with anti-CD4 (red) and anti-MHC class ll (green) from *D. farinae*-exposed mice (*D. farinae* i.n.) on days 4, 11, or 18. (D) Representative confocal micrograph of lung stained with anti-CD4 (red) and anti-MHC class ll (green) from PBS-exposed mice (PBS i.n.) on days 4, 11, or 18. (For interpretation of the references to colour in this figure legend, the reader is referred to the web version of this article.)

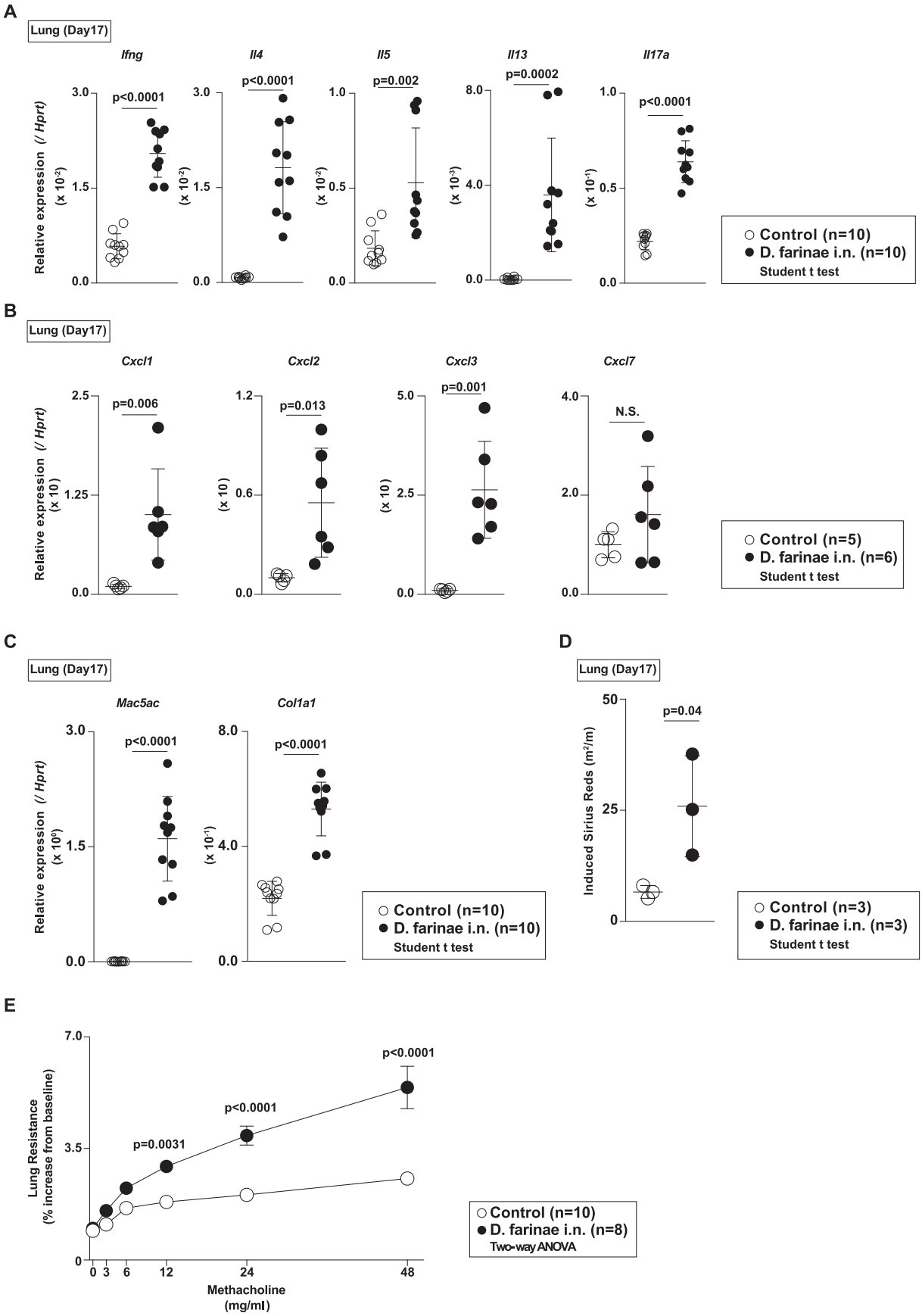

(caption on next page)

Fig. 3. *D. farinae* allergen induced an increased inflammatory cytokine expression accompanied by enhanced AHR. (A, B, C) A quantitative RT-PCR analysis for the indicated genes from the lung of control mice (control) or *D. farinae*-exposed mice (*D. farinae* i.n.) (n = 10 mice per group). (D) Shown are the ratios of areas of randomly selected regions stained with Sirius Red surrounding bronchi versus the areas of associated basement membranes (right). Three mice per group were analyzed. (E) Airway hyperresponsiveness (AHR) was assessed by increased airway resistance with increasing doses of methacholine. *P*-values were calculated with an unpaired *t*-test in A to D or two-way ANOVA with Bonferroni's multiple comparisons test in E.

and *Collagen type 1 alpha 1* (*Col1a1*) (Fig. 3A, B and C). At the same time, collagen deposition in the lungs was significantly enhanced in mice administered *D. farinae* allergen (Fig. 3D). Further, the intra-nasal administration of *D. farinae* allergen also induced enhanced airway hyperresponsiveness (Fig. 3E).

3.3. D. farinae allergen induces neutrophilic airway inflammation in a dose-dependent manner

We next examined whether or not exposure to *D. farinae* allergen resulted in the induction of airway inflammation in a dose-dependent manner. Mice were administered *D. farinae* intranasally with 3 different doses (0.5, 5, or 50 μg) (Fig. 4A). Mice administered 0.5 or 5 μg of *D. farinae* allergen showed small increases in infiltrated inflammatory cells in the BAL fluid (Fig. 4B). However, the intranasal administration of 50 μg *D. farinae* allergen induced a significant increase in the infiltrated inflammatory cells in the BAL fluid ($p < .0001$, 2-way ANOVA) (Fig. 4B). The intra-nasal administration of 50 μg of *D. farinae* allergen also resulted in the infiltration of inflammatory cells around the bronchi, whereas that of 0.5 or 5 μg only induced slight infiltration of inflammatory cells into the lung parenchyma (Fig. 4C). The intra-nasal administration of 50 μg of *D. farinae* allergen also induced hyper mucus production accompanied by the enhanced deposition of collagen (Fig. 4D).

An immunohistological analysis of the lungs of the mice that had been intratracheally administered 50 μg of *D. farinae* allergen revealed the accumulation of MHC class II^+ cells and $CD4^+$ T cells near the bronchioles and blood vessels accompanied by the formation of lymphoid clusters (Fig. 4E). Taken together, these findings show that *D. farinae* allergen induced airway inflammation in a dose-dependent manner.

4. Discussion

In the present study, we investigated the pathogenic roles of *D. farinae* allergen during allergic airway inflammation. We found that the intra-nasal exposure to *D. farinae* allergen three times for three weeks resulted in the induction of neutrophil-dominant infiltration of inflammatory cells in the BAL fluid, hyper mucus production, and collagen deposition around the bronchi accompanied by the formation of lymphoid clusters. Furthermore, the exposure to *D. farinae* allergen three times for three weeks induced an increased type 1 and type 2 cytokine expression accompanied by enhanced airway hyperresponsiveness. We also found that the induction of airway inflammation by exposure to *D. farinae* allergen three times was dose-dependent.

In humans, HDMs, including *D. pteronyssinus* and *D. farinae*, cause various types of allergic diseases, such as asthma, rhinitis, rhino-conjunctivitis, and atopic dermatitis (Calderon et al., 2015; Gavino et al., 2008; Kemp, 2009). *D. farinae* and *D. pteronyssinus* are very similar and share many allergens in common. However, there are several differences in allergens between these two organisms. The exposure to each house dust mite in childhood results in a distinct clinical phenotype; the exposure to Der f1 is associated with the elevation of serum antigen specific IgE, while the exposure to Der p1 is associated with wheezing and asthma after six years of age (Casas et al., 2015). In addition, the exposure to *D. pteronyssinus* allergen two times for four weeks results in eosinophil-dominant airway inflammation in a mouse model of asthma (Choi et al., 2018), while we found that exposure to *D. farinae* allergen three times for three weeks resulted in neutrophil-dominant airway inflammation. In fact, only *D. farinae* has Der f 16 (Gelsolin), Der f 17 (EF-hand Ca^{2+}-binding protein), Der f 22 (Lipid-binding protein), and Der f 24 (Ubiquinol-cytochrome C reductase-binding protein homolog) (Calderon et al., 2015). Thus, those allergens might be responsible for differences in immune responses.

Investigating the quantitative relationship between the exposure to HDM allergens and symptoms in asthmatics has been difficult, because patients are usually exposed to a number of different allergens. However, the symptoms in patients with asthma are likely to be more severe with increasing allergen exposure (Calderon et al., 2015). Our experimental results clearly showed that the induction of allergic responses by exposure to *D. farinae* was both frequency- and dose-dependent.

Ectopic lymphoid structures are known to be induced in non-lymphoid organs in response to inflammation caused by various stimuli, including infectious organisms and inhaled fine particles (Kuroda et al., 2016). Inducible bronchus-associated lymphoid tissue (iBALT), which develops in the lung, consists of separate B and T cell areas, with the presence of follicular dendritic cells (FDCs), resident dendritic cells (DCs), high endothelial venules (HEVs), and lymphatics (Shinoda et al., 2016). iBALT formation has been identified in the inflamed tissue of cases of chronic inflammatory disease, such as chronic obstructive pulmonary diseases and asthma (Shinoda et al., 2016; Hogg et al., 2004; John-Schuster et al., 2016). We previously showed that iBALT plays a crucial role in the maintenance of memory Th2 cells in OVA-induced allergic airway inflammation (Shinoda et al., 2016). In the present study, we observed the formation of lymphoid clusters that contained the accumulated $CD4^+$ T cells within the lung parenchyma in our *D. farinae*-induced lung inflammation model (Figs. 2C and 4E). We found that 3 sets of exposure to *D. farinae* allergen (50 μg) induced the formation of lymphoid clusters. The lymphoid clusters induced by exposure to *D. farinae* consisted of $CD4^+$ T cells and MHC class II^+ cells (Figs. 2C and 4E), but we were unable to detect any FDCs stained with CD21 in the lymphoid clusters (data not shown). We therefore concluded that the lymphoid clusters induced by exposure to *D. farinae* at day 18 were different from the previously reported iBALT. Patients with severe persistent asthma often show airway remodeling with structural alterations of the airway wall, such as peri-bronchial fibrotic responses (Foster et al., 2017; Lambrecht and Hammad, 2012). Chronic exposure to *D. pteronyssinus* induces peri-bronchial fibrotic changes in a mouse model of asthma (Doherty et al., 2011). We also showed that exposure to *D. farinae* allergen (50 μg) three times resulted in the induction of fibrotic changes in the peri-bronchial region (Figs. 2A and 4D). Thus, our experimental system with exposure to *D. farinae* seems to be a useful experimental model for the investigation of lymphoid clusters along with the induction of fibrotic changes in the lungs.

In summary, we demonstrated the pathogenic roles of *D. farinae* allergen in inducing neutrophilic allergic airway inflammation accompanied by the formation of lymphoid clusters and the induction of fibrotic changes in the lung. Our results will aid researchers in investigating the asthmatic responses against *D. farinae* in vivo.

Author contributions

T.W., K.H. and T.N. designed the experiments. T.W., K.H., A.A., Y.M., M.K., J.K., M.O., K.K., performed the experiments. T.W., K.H., M.K., C.F., K.O-D. and T.N. analyzed and interpreted the data. T.W., K.H. and T.N. wrote the paper.

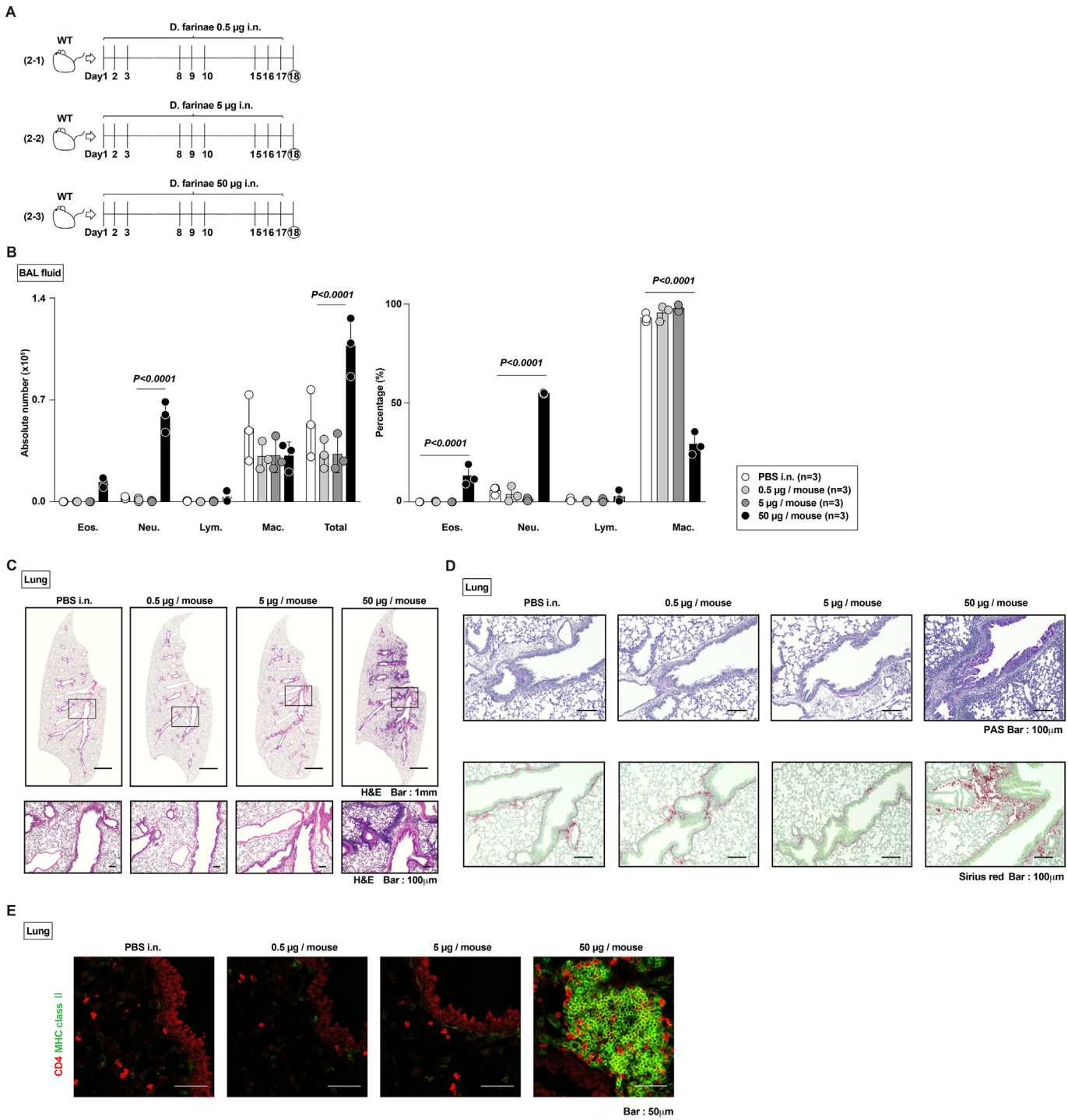

Fig. 4. *D. farinae* allergen induced airway inflammation in a dose dependent manner. (A) An experimental schematic illustration for the exposure to *D. farinae* allergen is depicted. BALB/c mice were administered *D. farinae* (0.5, 5, or 50 μg) intranasally for 3 weeks. (B) Absolute cell number (left) and percentage (right) of eosinophils (Eos.), neutrophils (Neu.), lymphocytes (Lym.), macrophages (Mac.), and total cells (Total) in BAL fluid from PBS-exposed mice (PBS i.n.) or *D. farinae*-exposed mice (*D. farinae* i.n.) (n = 3 mice per group). (C) Representative histological sections of lungs on day 18 stained with Hematoxylin and Eosin from PBS-exposed mice (PBS i.n.) or *D. farinae*-exposed mice (*D. farinae* i.n.). Scale bars represent 1 mm (top) or 100 μm (bottom). (D) Representative histological sections of lungs on day 18 stained with PAS staining (top) and Sirius Red staining (bottom) from PBS-exposed mice (PBS i.n.) or *D. farinae*-exposed mice (*D. farinae* i.n.). Scale bars represent 100 μm. (E) Representative confocal micrograph of lung stained with anti-CD4 (red) and anti-MHC class ll (green) from *D. farinae*-exposed mice on day 18. Scale bars represent 50 μm. Data are shown as the mean ± SD in B. P-values were calculated with a two-way ANOVA with Bonferroni's multiple comparisons test in B. (For interpretation of the references to colour in this figure legend, the reader is referred to the web version of this article.)

Funding statement

This work was supported by the following grants: Ministry of Education, Culture, Sports, Science and Technology (MEXT Japan) Grants-in-Aid for Scientific Research (S) 26221305, (C) 17K08876; Practical Research Project for Allergic Diseases and Immunology (Research on Allergic Diseases and Immunology) from the Japan Agency for Medical Research and Development, AMED (No.

JP18ek0410030, JP18ek0410045); AMED-CREST, AMED (No. JP18gm1210003); AMED-PRIME, AMED (No. JP18gm6110005); The Mochida Memorial Foundation for Medical and Pharmaceutical Research and Takeda Science Foundation.

Data availability statement

The data used to support the finding of this study are available for the corresponding author upon request.

Acknowledgments

We thank Toshihiro Ito, and Kaoru Sugaya for their excellent technical assistance.

References

Ballesteros-Tato, A., Randall, T.D., Lund, F.E., Spolski, R., Leonard, W.J., Leon, B., Follicular Helper, T., 2016. Cell plasticity shapes pathogenic T helper 2 cell-mediated immunity to inhaled house dust mite. Immunity 44, 259–273.

van Bronswijk, J.E., Sinha, R.N., 1971. Pyroglyphid mites (Acari) and house dust allergy. J. Allergy 47, 31–52.

Calderon, M.A., Linneberg, A., Kleine-Tebbe, J., De Blay, F., Hernandez Fernandez De Rojas, D., Virchow, J.C., Demoly, P., 2015. Respiratory allergy caused by house dust mites: what do we really know? J. Allergy Clin. Immunol. 136, 38–48.

Casas, L., Sunyer, J., Tischer, C., Gehring, U., Wickman, M., Garcia-Esteban, R., Lehmann, I., Kull, I., Reich, A., Lau, S., Wijga, A., Anto, J.M., Nawrot, T.S., Heinrich, J., Keil, T., Torrent, M., 2015. Early-life house dust mite allergens, childhood mite sensitization, and respiratory outcomes. Allergy 70, 820–827.

Choi, J.P., Jeon, S.G., Kim, Y.K., Cho, Y.S., 2018. Role of house dust mite-derived extracellular vesicles in a murine model of airway inflammation. Clin. Exp. Allergy. https://doi.org/10.1111/cea.13295.

Coquet, J.M., Schuijs, M.J., Smyth, M.J., Deswarte, K., Beyaert, R., Braun, H., Boon, L., Karlsson Hedestam, G.B., Nutt, S.L., Hammad, H., Lambrecht, B.N., 2015. Interleukin-21-producing CD4(+) T cells promote type 2 immunity to house dust mites. Immunity 43, 318–330.

Doherty, T.A., Soroosh, P., Khorram, N., Fukuyama, S., Rosenthal, P., Cho, J.Y., Norris, P.S., Choi, H., Scheu, S., Pfeffer, K., Zuraw, B.L., Ware, C.F., Broide, D.H., Croft, M., 2011. The tumor necrosis factor family member LIGHT is a target for asthmatic airway remodeling. Nat. Med. 17, 596–603.

Foster, P.S., Maltby, S., Rosenberg, H.F., Tay, H.L., Hogan, S.P., Collison, A.M., Yang, M., Kaiko, G.E., Hansbro, P.M., Kumar, R.K., Mattes, J., 2017. Modeling TH 2 responses and airway inflammation to understand fundamental mechanisms regulating the pathogenesis of asthma. Immunol. Rev. 278, 20–40.

Gavino, A.C., Needham, G.R., High, W.A., 2008. Atopic dermatitis, patch testing, and house dust mites: a brief review. Dermatitis 19, 121–128.

Gregory, L.G., Lloyd, C.M., 2011. Orchestrating house dust mite-associated allergy in the lung. Trends Immunol. 32, 402–411.

Hammad, H., Chieppa, M., Perros, F., Willart, M.A., Germain, R.N., Lambrecht, B.N., 2009. House dust mite allergen induces asthma via Toll-like receptor 4 triggering of airway structural cells. Nat. Med. 15, 410–416.

Hirahara, K., Yamashita, M., Iwamura, C., Shinoda, K., Hasegawa, A., Yoshizawa, H., Koseki, H., Gejyo, F., Nakayama, T., 2008. Repressor of GATA regulates TH2-driven allergic airway inflammation and airway hyperresponsiveness. J. Allergy Clin. Immunol. 122, 512–520 (e511).

Hogg, J.C., Chu, F., Utokaparch, S., Woods, R., Elliott, W.M., Buzatu, L., Cherniack, R.M., Rogers, R.M., Sciurba, F.C., Coxson, H.O., Pare, P.D., 2004. The nature of small-airway obstruction in chronic obstructive pulmonary disease. N. Engl. J. Med. 350, 2645–2653.

Hondowicz, B.D., An, D., Schenkel, J.M., Kim, K.S., Steach, H.R., Krishnamurty, A.T., Keitany, G.J., Garza, E.N., Fraser, K.A., Moon, J.J., Altemeier, W.A., Masopust, D., Pepper, M., 2016. Interleukin-2-dependent allergen-specific tissue-resident memory cells drive asthma. Immunity 44, 155–166.

Ito, T., Hirose, K., Norimoto, A., Tamachi, T., Yokota, M., Saku, A., Takatori, H., Saijo, S., Iwakura, Y., Nakajima, H., 2017. Dectin-1 plays an important role in house dust mite-induced allergic airway inflammation through the activation of CD11b+ dendritic cells. J. Immunol. 198, 61–70.

John-Schuster, G., Gunter, S., Hager, K., Conlon, T.M., Eickelberg, O., Yildirim, A.O., 2016. Inflammaging increases susceptibility to cigarette smoke-induced COPD. Oncotarget 7, 30068–30083.

Kemp, A.S., 2009. Allergic rhinitis. Paediatr. Respir. Rev. 10, 63–68.

Kuroda, E., Ozasa, K., Temizoz, B., Ohata, K., Koo, C.X., Kanuma, T., Kusakabe, T., Kobari, S., Horie, M., Morimoto, Y., Nakajima, S., Kabashima, K., Ziegler, S.F., Iwakura, Y., Ise, W., Kurosaki, T., Nagatake, T., Kunisawa, J., Takemura, N., Uematsu, S., Hayashi, M., Aoshi, T., Kobiyama, K., Coban, C., Ishii, K.J., 2016. Inhaled fine particles induce alveolar macrophage death and interleukin-1alpha release to promote inducible bronchus-associated lymphoid tissue formation. Immunity 45, 1299–1310.

Lambrecht, B.N., Hammad, H., 2012. The airway epithelium in asthma. Nat. Med. 18, 684–692.

Lambrecht, B.N., Hammad, H., 2015. The immunology of asthma. Nat. Immunol. 16, 45–56.

Morimoto, Y., Hirahara, K., Kiuchi, M., Wada, T., Ichikawa, T., Kanno, T., Okano, M., Kokubo, K., Onodera, A., Sakurai, D., Okamoto, Y., Nakayama, T., 2018. Amphiregulin-producing pathogenic memory T helper 2 cells instruct eosinophils to secrete osteopontin and facilitate airway fibrosis. Immunity 49, 134–150 (e136).

Nelson Jr., R.P., Dinicolo, R., Fernandez-Caldas, E., Seleznick, M.J., Lockey, R.F., Good, R.A., 1996. Allergen-specific IgE levels and mite allergen exposure in children with acute asthma first seen in an emergency department and in nonasthmatic control subjects. J. Allergy Clin. Immunol. 98, 258–263.

Norimoto, A., Hirose, K., Iwata, A., Tamachi, T., Yokota, M., Takahashi, K., Saijo, S., Iwakura, Y., Nakajima, H., 2014. Dectin-2 promotes house dust mite-induced T helper type 2 and type 17 cell differentiation and allergic airway inflammation in mice. Am. J. Respir. Cell Mol. Biol. 51, 201–209.

Onodera, A., Kiuchi, M., Kokubo, K., Kato, M., Ogino, T., Horiuchi, S., Kanai, U., Hirahara, K., Nakayama, T., 2017. Menin controls the memory Th2 cell function by maintaining the epigenetic integrity of Th2 cells. J. Immunol. 199, 1153–1162.

Shinoda, K., Hirahara, K., Iinuma, T., Ichikawa, T., Suzuki, A.S., Sugaya, K., Tumes, D.J., Yamamoto, H., Hara, T., Tani-Ichi, S., Ikuta, K., Okamoto, Y., Nakayama, T., 2016. Thy1+IL-7+ lymphatic endothelial cells in iBALT provide a survival niche for memory T-helper cells in allergic airway inflammation. Proc. Natl. Acad. Sci. U. S. A. 113, E2842–E2851.