# Journal Pre-proof




Pediatric Eosinophilic Bronchiolitis Successfully Treated with Mepolizumab.

Talia Arceri, M.D., Geoffrey Kurland, M.D., Miguel Reyes-Múgica, M.D., Allyson Larkin, M.D.

PII: S2213-2198(21)01255-1

DOI: https://doi.org/10.1016/j.jaip.2021.10.064

Reference: JAIP 3949

To appear in: *The Journal of Allergy and Clinical Immunology: In Practice*

Received Date: 23 July 2021

Revised Date: 14 October 2021

Accepted Date: 27 October 2021

Please cite this article as: Arceri T, Kurland G, Reyes-Múgica M, Larkin A, Pediatric Eosinophilic Bronchiolitis Successfully Treated with Mepolizumab., *The Journal of Allergy and Clinical Immunology: In Practice* (2021), doi: https://doi.org/10.1016/j.jaip.2021.10.064.

This is a PDF file of an article that has undergone enhancements after acceptance, such as the addition of a cover page and metadata, and formatting for readability, but it is not yet the definitive version of record. This version will undergo additional copyediting, typesetting and review before it is published in its final form, but we are providing this version to give early visibility of the article. Please note that, during the production process, errors may be discovered which could affect the content, and all legal disclaimers that apply to the journal pertain.

© 2021 Published by Elsevier Inc. on behalf of the American Academy of Allergy, Asthma & Immunology

Journal Pre-proof

**Title: Pediatric Eosinophilic Bronchiolitis Successfully Treated with Mepolizumab.**

**Authors**

Talia Arceri, M.D. [1]
Geoffrey Kurland, M.D. [2]
Miguel Reyes-Múgica, M.D. [3]
Allyson Larkin, M.D. [4]

Author affiliations:
UPMC Children's Hospital of Pittsburgh, Pediatric Residency Program (1), Division of Pulmonary Medicine (2), Division of Pediatric Pathology (3) and Division of Allergy and Immunology (4).

Corresponding Author:
Allyson Larkin, MD
Division of Allergy and Immunology
UPMC Children's Hospital of Pittsburgh
Administrative Office Building, Ste. 3300
4401 Penn Avenue
Pittsburgh, PA 15224
USA

Telephone: 412-692-7885

Fax: 412-692-8499

Email: Allyson.Larkin@chp.edu

Journal Pre-proof

Journal Pre-proof

**Disclosures:** The Authors have no disclosures.

**Clinical Implications:** This is the first reported case of a pediatric patient with biopsy-confirmed eosinophilic bronchiolitis (EB). A severe asthma phenotype responsive only to oral steroids with marked peripheral and BAL eosinophilia should prompt consideration of EB.

EB is a rare disease characterized in adults by: 1) blood hypereosinophilia >1 $G \cdot L^{-1}$ and/or BAL eosinophilia >25% 2) airflow obstruction not improved by inhaled bronchodilators and corticosteroids 3) direct signs of bronchiolitis on imaging or lung biopsy [1,2]. Individuals with EB present with severe persistent asthma as well as clinical characteristics of hypereosinophilic syndromes (3). EB is challenging from a diagnostic standpoint because the need for a tissue diagnosis may be overshadowed by a positive response to systemic steroids. Mepolizumab, which targets IL-5 and prevents its binding to eosinophils has been successfully used in an adult case of EB [4]. To our knowledge, this is the first reported pediatric patient with EB.

The patient, a dizygotic twin, was born at 35 weeks gestation and required supplemental oxygen without mechanical ventilation during a three week NICU stay. He developed wheezing by 6 months of age and presented to our hospital 3 months later with respiratory distress only responsive to oral steroids. Because of continued respiratory symptoms, he underwent a flexible bronchoscopy with

Journal Pre-proof

bronchoalveolar lavage (BAL) at 11 months. The airway exam revealed diffuse mucoid secretions and mild left bronchomalacia. The BAL revealed 60% neutrophils and 23% eosinophils (Figure 1), both of which were markedly elevated for his age (5). He was receiving a course of oral steroids at the time and his peripheral eosinophil count was 0.1 x 10^9/L.

He required monthly oral steroid courses in his early toddler years despite treatment with low dose fluticasone/ salmeterol. At 34 months, while not receiving oral steroids, he underwent further evaluation that included: peripheral eosinophil count of 0.59 x 10^9/L, normal IgA, IgG, IgM and IgE, normal sweat test, dust mite IgE 0.22 KU/L and testing for other common aeroallergens was undetectable. A chest CT showed multifocal lobar and sub-segmental atelectasis with associated segmental bronchial narrowing and superimposed bronchiolitis in the right upper lung. Three months later, while not receiving oral steroids, he underwent a second bronchoscopy with BAL which demonstrated 24% eosinophils.

At age four, he was referred to our Severe Asthma Clinic. Despite increases in his inhaled fluticasone/salmeterol dose he continued to experience cough, wheeze and required oral steroids. At age 5, his eosinophil count ranged from 0.68 -1.87 10^9/L while he was not receiving oral steroids. Evaluations for hypereosinophilic syndrome (HES), Eosinophilic Granulomatosis with Polyangiitis (EGPA) and primary immunodeficiency were unremarkable. A bone marrow biopsy was notable for increased eosinophils, normal red and white blood cell

Journal Pre-proof

precursors, and no chromosomal translocations. Lymphocyte proliferation was normal as was a neutrophil oxidative burst assay. Rheumatologic evaluation was unremarkable (ESR 9, ANA <80, CH50 normal, ANCA negative, alpha-1antitrypsin 133). His T/B/NK cells were normal and his tetanus,and pneumococcal titers all boosted after revaccination. Whole exome sequencing was unrevealing. His troponin and echocardiogram were normal. Serum IgG testing was negative to Toxocara and Strongyloides, and HIV testing was negative. A morning cortisol level was normal and a repeat chest CT was notable for mild bronchiectasis and bronchiolar wall thickening.

Ultimately, transthoracic video-assisted thoracoscopic (VATS) lung biopsy was done at age 5. He was not on oral steroids at the time. Pathologic analysis revealed intense eosinophilic peri-bronchiolitis with increased mast cells in the right middle lobe (Figure 2). The eosinophils infiltrated the bronchiolar lamina propria and the connective tissue surrounding the bronchiolar smooth muscle layer. Many of these infiltrating eosinophils showed active degranulation. He continued to have elevated peripheral eosinophils while not on oral steroids (1.450 10^9/L and 1.870 10^9/L). Prior to starting mepolizumab, he had a fixed airway obstruction with an FEV1 pre bronchodilator of 49% predicted. Treatment with oral steroids improved his FEV1 to 112% predicted.

The patient was diagnosed with EB given his severe persistent asthma symptoms, peripheral eosinophilia, BAL eosinophilia, and biopsy results. He was treated with daily oral steroids and monthly mepolizumab (40mg

Journal Pre-proof

subcutaneously). At the time of diagnosis, FDA approval for mepolizumab was limited to individuals age 12 and older. Because of this, informed consent for the innovative off label use of mepolizumab was obtained from his mother and approved by our hospital Innovative Use Committee. He was titrated off all oral steroids in 9 weeks, continued on his high dose ICS/LABA, and was noted to have rapid improvement in both objective (FEV1 stayed primarily above 90% predicted and absolute eosinophil count has stayed below 0.30 X10E+09/L) and subjective (cough and wheeze) findings. Our patient has now had over 1 year of therapy with mepolizumab and has not required oral steroids. He continues to receive high dose ICS/LABA and his FEV1 ranges from 103%-110% predicted. In 2013, a case series reported 6 adults with EB who presented with chronic dyspnea, airway obstruction, blood and BAL eosinophilia who improved with oral but not inhaled steroids (1,2). In 2017 Sato et al reported another case of EB (6) and in 2020, Takashita demonstrated the successful treatment of EB with mepolizumab in an adult patient (4). Mepolizumab is a humanized monoclonal antibody directed against interleukin-5, which interferes with the binding of IL-5 to the alpha sub-unit of the IL-5 receptor on eosinophils Our patient is the first pediatric patient to successfully receive this medication for EB.

We surmise that pediatric EB is an underrecognized entity, often misclassified and/or complicated by asthma given the overlapping presenting symptoms. Although there is limited evidence concerning the most effective treatment for EB, the use of prolonged oral steroids places patients at risk for adverse longterm

Journal Pre-proof

Journal Pre-proof

effects of chronic steroid therapy. Since our patient has done so well, attempts to discontinue the mepolizumab have not been made, but may be considered in the future. To our knowledge, this is the first reported case in the literature of a young child with a diagnosis of biopsy proven EB**.** In a pediatric patient presenting with clinical symptoms consistent with severe asthma but unresponsive to high dose ICS who also has persistent BAL and peripheral eosinophilia, it is appropriate to consider EB. Further studies are needed to determine the natural history of the disease and alternative treatment options.

Fig1: Bronchioalveolar lavage showing a significant increase in the number of eosinophils combined with alveolar macrophages and occasional neutrophils. Many of the eosinophils were degranulating (Wright-Giemsa stain, original magnification = 1000X).

Fig2: Lung biopsy showing a bronchiole with an intense eosinophilic infiltrate involving the lamina propria and outside of the muscular layer. Many of the numerous eosinophils feature degranulation (H&E, original magnification = 400X).

Journal Pre-proof

## **References**

1. Cordier J-F, Cottin V, Khouatra C, Revel D, Proust C, Freymond N, et al. Hypereosinophilic obliterative bronchiolitis: A distinct, unrecognized syndrome. European Respiratory Journal. 2013;41(5):1126–34.

2. Poletti V. Eosinophilic bronchiolitis: Is it a new syndrome? European Respiratory Journal. 2013;41(5):1012–3.

3. Curtis C, Ogbogu P. Hypereosinophilic syndrome. Clinical Reviews in Allergy & Immunology. 2015;50(2):240–51.

Journal Pre-proof

4. Takeshita Y, Nobuyama S, Kanetsuna Y, Tanaka A, Adachi M, Sato T, et al. Eosinophilic bronchiolitis successfully treated with mepolizumab. The Journal of Allergy and Clinical Immunology: In Practice. 2020;8(3).

5. Midulla F, Villani A, Merolla R, Bjermer L, Sandstrom T, Ronchetti R. Bronchoalveolar Lavage Studies in children without parenchymal lung disease: Cellular constituents and protein levels. Pediatric Pulmonology. 1995;20(2):112–8.

6. Sato H, Okada F, Matsumoto S, Ono A, Nakayama T, Mori H, et al. Eosinophilic bronchiolitis. Journal of Thoracic Imaging. 2017;32(6).
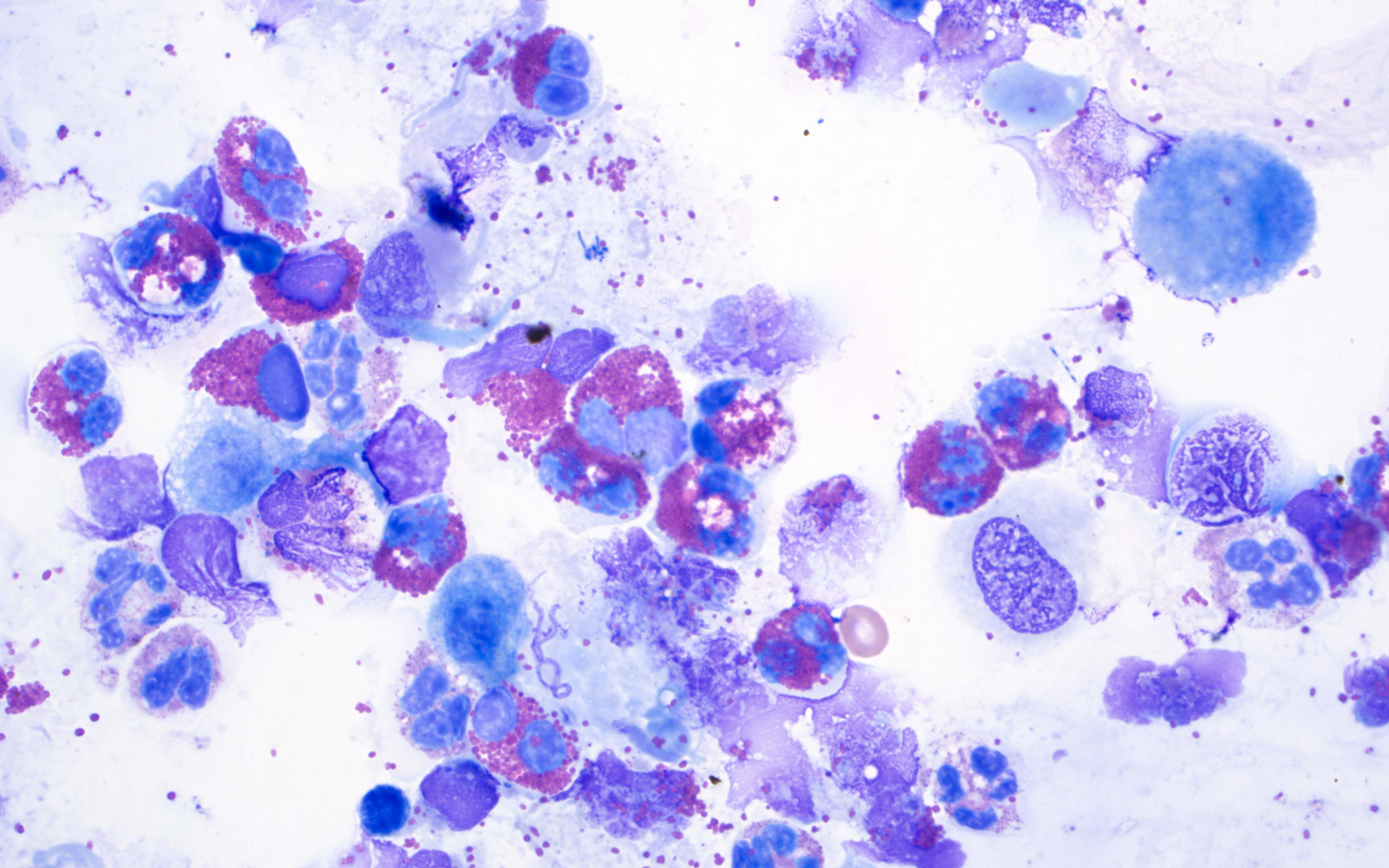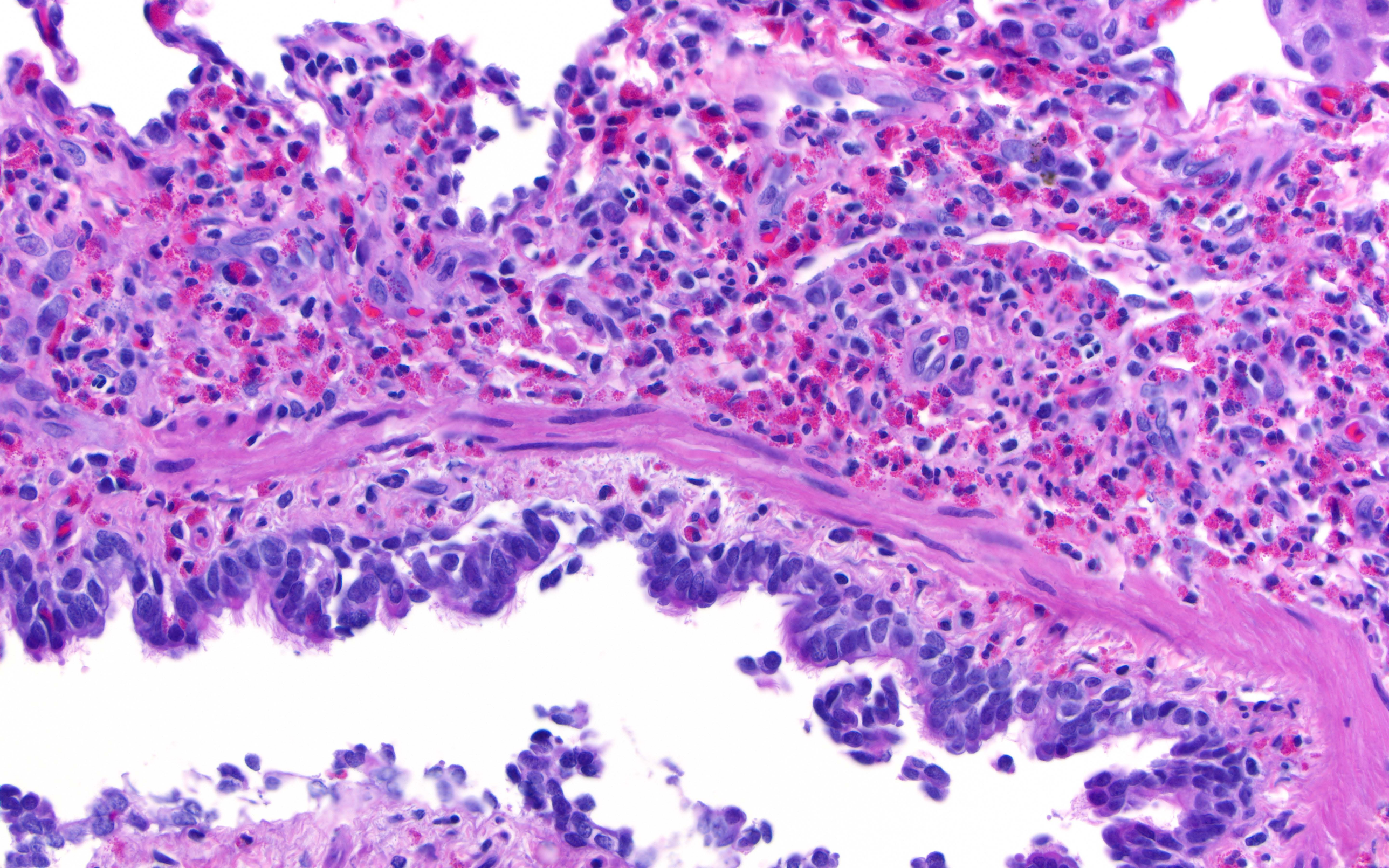
Journal Pre-proof