Check for updates

Received: 8 June 2021 | Accepted: 8 June 2021

DOI: 10.1111/pai.13623

SUPPLEMENT ARTICLE

WILEY

Rapid response to dupilumab treatment in children with moderate-to-severe atopic dermatitis: A case series

Martina Votto[1] | Francesco Delle Cave[1] | Maria De Filippo[1] | Alessia Marseglia[1] | Gian Luigi Marseglia[1,2] | Valeria Brazzelli[3] | Amelia Licari[1,2]

[1]Pediatric Clinic, Fondazione IRCCS Policlinico San Matteo, Pavia, Italy

[2]Department of Clinical-Surgical, Diagnostic and Pediatric Sciences, University of Pavia, Pavia, Italy

[3]Department of Clinical-Surgical, Diagnostic, and Paediatric Science, Dermatology Clinic, Foundation I.R.C.C.S. Policlinico San Matteo and University of Pavia, Pavia, Italy

Correspondence
Amelia Licari, Pediatric Clinic, Department of Pediatrics, Fondazione IRCCS Policlinico San Matteo, University of Pavia, viale Golgi 19, 27100 Pavia, Italy.
Email: amelia.licari@unipv.it

Editor: Michele Miraglia Del Giudice

Abstract

Atopic dermatitis (AD) is a chronic, relapsing, inflammatory skin disease characterized by itch and clinical heterogeneity regarding the age of onset, morphology, distribution, and severity of lesions. Severe AD has a significant impact on the quality of life of affected children and their caregivers. Children with moderate-severe AD inadequately controlled with topical therapy have limited treatment options, such as systemic corticosteroids or phototherapy, often prescribed as off-label treatments, often with unfavorable benefit-to-risk ratio adverse events. Dupilumab is a fully human monoclonal antibody with proven effectiveness and a relatively safe adverse effect profile in patients with type 2 inflammatory diseases, including AD. We report three pediatric cases of severe AD successfully treated with dupilumab.

KEYWORDS
allergy, atopic dermatitis, children, dupilumab

1 | INTRODUCTION

Atopic dermatitis (AD) is a chronic inflammatory skin disease characterized by intense itching and recurrent eczematous lesions. AD affects any part of the body but typically shows age-related morphology and distribution. Diagnosis relies exclusively on these clinical features. The estimated prevalence is about 15%–20% in children, while severe AD accounts for up to 8%.[1] In children with moderate-to-severe AD, skin lesions often involve a large body surface area. Moreover, the related itch increased risk of bacterial and viral skin infections, sleep deprivation, activity restriction, poor school performance, depression, and anxiety, significantly impacting the quality of life (QoL) of patients and their caregivers. Unfortunately, children with moderate-to-severe AD inadequately controlled with topical therapies have limited treatment options, such as systemic corticosteroids and/or phototherapy often prescribed off-label; their use is often associated with unfavorable benefit-to-risk ratio and multiple adverse events[2-4]

Dupilumab is a fully human monoclonal IgG4 antibody that blocks the alpha-chain of the receptors for IL-4 and IL-13, inducing the downregulation of type 2 (Th2) inflammation.[5] Several studies reported that dupilumab significantly improved the outcomes in children with severe AD inadequately controlled with standard therapy, including signs, symptoms, and QoL, with an acceptable safety profile.[6,7]

We reported a case series of three pediatric patients affected by severe AD, unresponsive to standard treatments, who showed a rapid clinical improvement after the first administrations of dupilumab (Table 1).

Martina Votto and Francesco Delle Cave equally contributed as co-first author.

This is an open access article under the terms of the Creative Commons Attribution-NonCommercial-NoDerivs License, which permits use and distribution in any medium, provided the original work is properly cited, the use is non-commercial and no modifications or adaptations are made.
© 2022 The Authors. *Pediatric Allergy and Immunology* published by European Academy of Allergy and Clinical Immunology and John Wiley & Sons Ltd.

2 | CASE I

A 12-year-old Caucasian male patient was evaluated to our for severe AD that required hospitalization for bacterial skin infection. His family history was positive for atopy. Since childhood, he had a history of allergic rhinitis and Despite the initial first-line treatment with topical therapy and the subsequent need for systemic corticosteroids, the child suffered from multiple exacerbations of AD that severely limited his school activities and sleep. The severity of clinical features, measured by the disease activity scores (EASI) confirmed the clinical picture of severe AD. Therefore, treatment with dupilumab (200 mg subcutaneously [SC] every two weeks) was started with a rapid improvement in signs, symptoms, and quality of life (QoL) after the first administrations (Figure S1). To date, the child underwent ten administrations, presenting a great and constant improvement of the disease and his QoL. There were no adverse effects during the treatment.

Key Messages

Children with severe atopic dermatitis (AD), inadequately controlled with topical therapies, have limited treatment options with poor quality of life. Dupilumab is the first biological therapy proven to be effective in patients with uncontrolled moderate-to-severe AD with an acceptable safety profile.

3 | CASE II

We evaluated a 12-year-old South Asian male patient, for severe AD with skin lesions involving a large body surface area, including neck, genital area, trunk, back, and limbs, with a significant nocturnal itch, highly limiting his ability to sleep. The child developed several

TABLE 1 Patient's characteristics

	Case I	Case II	Case III
Age at AD onset, years	8	5	1
Sex	Male	Male	Female
Ethnicity	Caucasian	South Asian	Turkish
Coexisting allergic diseases	Asthma, food allergy, and allergic rhinitis	Allergic rhinitis	Allergic rhinitis
Skin prick tests[a]	Sensitization to dust mites, cat, kiwi, and shrimp	Sensitization to dust mites	Sensitization to dust mites and nuts and peanuts
Total serum IgE,[a] KU/L	>5000	3458	>5000
Blood eosinophil count,[a] cells/ mm^3	2090	150	1080
Previous treatment for AD	Galenic formulation of topical steroids and moisturizing creams. Brief cycles of systemic corticosteroids.	Galenic formulation of topical steroids and moisturizing creams. Brief cycles of systemic corticosteroids.	Galenic formulation of topical steroids and moisturizing creams. Brief cycles of systemic corticosteroids. Phototherapy. Oral Cyclosporine.
Pretreatment scores[b]			
EASI	42.6	47.1	65.6
PO-SCORAD	101.8	72.5	101.8
IGA	5/5	3-4/5	5/5
POEM	25/28	24/28	28/28
DLQI	18/30	16/30	20/30
Post-treatment scores[b]			
EASI	10.7	1.6	1.8
PO-SCORAD	33.9	13	27
IGA	1/5	1/5	1/5
POEM	6/28	0/28	1/28
DLQI	2/30	0/30	2/30
Side effects to dupilumab	None	None	None

Abbreviations: DLQI, Dermatology Life Quality Index; EASI, Eczema Area and Severity Score; IGA, Investigator Global Assessment; POEM, Patient-Oriented Eczema Measure; SCORAD, Severity Scoring of Atopic Dermatitis.

[a]At baseline.

[b]The severity of clinical features was measured by the disease activity scores at baseline ad after every administration of dupilumab.

exacerbations of his AD after every discontinuation of topical steroids. The disease remained poorly controlled, and the patient had a poor quality of life. Considering the lack of response to standard therapy, he was treated with dupilumab (200 mg SC every two weeks) with a rapid and significant improvement of the skin lesions and QoL (Figure S2). Currently, the patient has received six administrations of dupilumab, presenting a great and constant remission of his disease without adverse effects.

4 | CASE III

Since the first year of life, a 9-year-old Pakistani female patient presented severe AD that required several hospitalizations for viral (*herpes simplex virus*) and bacterial (*Staphylococcus aureus*) skin infections. The child presented diffuse eczematous lesions with hyperkeratosis and excoriations. She experienced constant itch limiting her daily activities and school performance (Table 1). First-line therapy with topical therapies was started. After every discontinuation of topical steroids, AD severely relapsed. Therefore, she also underwent a brief cycle of phototherapy without improvement. Then, three cycles of oral cyclosporine A were prescribed with the improvement of her AD. However, after three months of therapy, she developed diffuse hypertrichosis and gingival hyperplasia with gingivitis; thus, cyclosporine was stopped. Her disease remained poorly controlled with extensive eczema, dry skin, and intense itch. Biological therapy with dupilumab (200 mg SC every two weeks) was started with a rapid improvement of the skin lesions and QoL. (Figure S3). To date, she underwent seventeen administrations, presenting a great and constant improvement of the disease and her QoL. No side effects were reported during the treatment.

5 | CONCLUSION

We report a case series of three patients successfully treated with dupilumab, supporting its use in children with moderate-to-severe AD. AD is a chronic, relapsing, inflammatory skin disease. Due to its chronic nature and frequent relapses, living with AD can be a burden, particularly for those requiring long-term, systemic treatment. Moreover, most available treatments may often complicate toxicities and side effects, also compromising the QoL of patients and their families.[3] Dupilumab is the first biologic with proven effectiveness and a relatively safe adverse effect profile in children and adults with Th2 inflammatory diseases, including AD and asthma.[5,8] So far, dupilumab has proven effective in patients with uncontrolled moderate-to-severe AD with an acceptable safety profile.[6,7]

CONFLICT OF INTEREST

Authors declare they have no conflict of interests.

AUTHOR CONTRIBUTIONS

Martina Votto contributed to conceptualization (equal) and writing—original draft (equal). **Francesco Delle Cave** contributed to writing—original draft (equal). **Maria De Filippo** contributed to writing—review and editing (equal). **Alessia Marseglia** contributed to conceptualization (equal); writing—review and editing (equal). **Gian Luigi Marseglia** contributed to supervision (lead); writing—review and editing (equal). **Valeria Brazzelli** contributed to conceptualization (equal); supervision (lead); and writing—review and editing (equal). **Amelia Licari** contributed to conceptualization (equal); supervision (lead); and writing—review & editing (equal).

ORCID

Martina Votto https://orcid.org/0000-0002-4271-8649
Maria De Filippo https://orcid.org/0000-0003-2900-9642
Gian Luigi Marseglia https://orcid.org/0000-0003-3662-0159
Valeria Brazzelli https://orcid.org/0000-0001-5898-6448
Amelia Licari https://orcid.org/0000-0002-1773-6482

REFERENCES

1. Weidinger S, Novak N. Atopic dermatitis. *Lancet*. 2016;387:1109-1122.
2. Wollenberg A, Barbarot S, Bieber T, et al. Consensus-based European guidelines for the treatment of atopic eczema (atopic dermatitis) in adults and children: part I. *J Eur Acad Dermatol Venereol*. 2018;32:657-682.
3. Wollenberg A, Barbarot S, Bieber T, et al. Consensus-based European guidelines for treatment of atopic eczema (atopic dermatitis) in adults and children: part II. *J Eur Acad Dermatol Venereol*. 2018;32:850-878.
4. Licari A, Ruffinazzi G, De Filippo M, et al. A starch, glycyrrhetinic, zinc oxide and bisabolol based cream in the treatment of chronic mild-to-moderate atopic dermatitis in children: a three-center, assessor blinded trial. *Minerva Pediatr*. 2017;69:470-475.
5. Licari A, Castagnoli R, Marseglia A, et al. Dupilumab to treat type 2 inflammatory diseases in children and adolescents. *Paediatr Drugs*. 2020;22:295-310.
6. Paller AS, Siegfried EC, Thaçi D, et al. Efficacy and safety of dupilumab with concomitant topical corticosteroids in children 6 to 11 years old with severe atopic dermatitis: a randomized, double-blinded, placebo-controlled phase 3 trial. *J Am Acad Dermatol*. 2020;83:1282-1293.
7. Cork MJ, Thaçi D, Eichenfield LF, et al. Dupilumab provides favourable long-term safety and efficacy in children aged ≥6 to <12 years with uncontrolled severe atopic dermatitis: results from an open-label phase IIa study and subsequent phase III open-label extension study. *Br J Dermatol*. 2021;184:857-870.
8. Votto M, De Filippo M, Licari A, et al. Biological therapies in children and adolescents with severe uncontrolled asthma: a practical review. *Biologics*. 2021;15:133-142.

SUPPORTING INFORMATION

Additional supporting information may be found in the online version of the article at the publisher's website.

How to cite this article: Votto M, Delle Cave F, De Filippo M, et al. Rapid response to dupilumab treatment in children with moderate-to-severe atopic dermatitis: A case series. *Pediatr Allergy Immunol*. 2022;33(Suppl. 27):31–33. https://doi.org/10.1111/pai.13623

Supplementary material

Figure S1 Case I. Pretreatment: 1A, 1B, 1C, 1D, 1E. After 10 administrations of dupilumab: 1F, 1G, 1H, 1I.

Figure S2 Case II. Pretreatment: 2A, 2B, 2C, 2D. After 6 administrations of dupilumab: 2E, 2F, 2G, 2H.

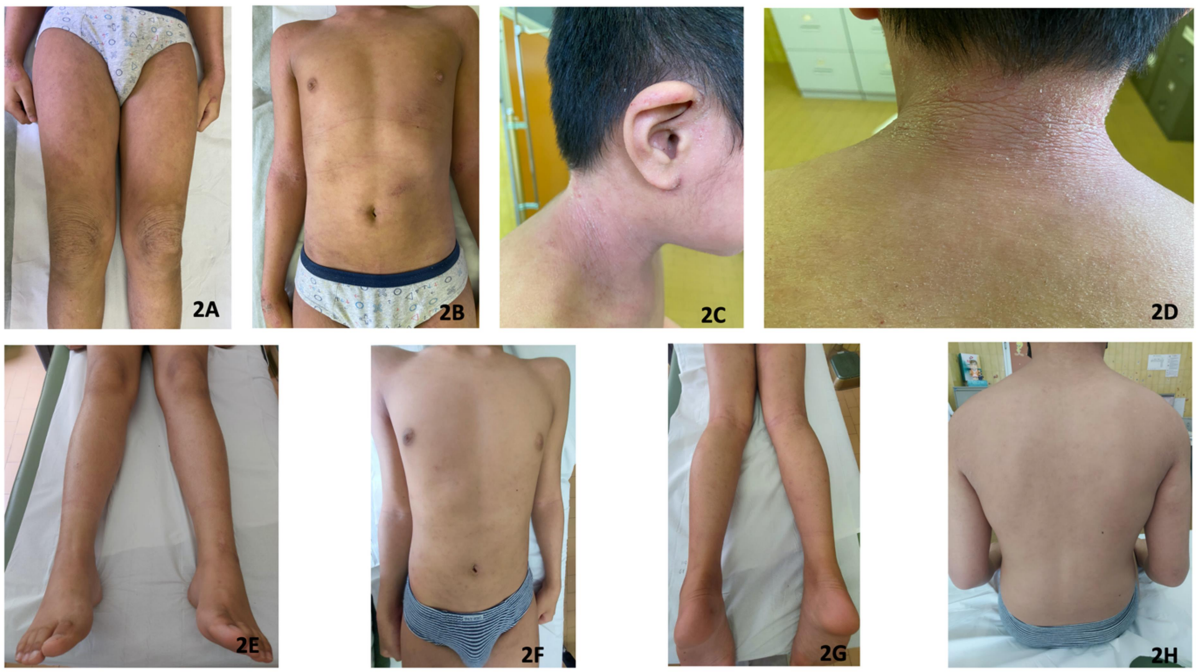

Figure S3 Case III. Pretreatment: 3A, 3B, 3C, 3D, 3E. After 17 administrations of dupilumab: 3F, 3G, 3H, 3I.