AHEAD OF PRINT - ARTICLE IN PRESS

Primary Care Respiratory Journal (2009); **18**(X): XXX-XXX

Primary Care RESPIRATORY JOURNAL
www.thepcrj.org

CASE REPORT

An endobronchial lipoma mimicking asthma and malignancy

***Farzan Irani[a], Bijender Kumar[a], Prashanth Reddy[a], Rawan Narwal-Chadha[a], Rahil Kasmani[a], James Tita[b]**

[a] Department of Internal Medicine, St Vincent Mercy Medical Center, Toledo, Ohio, USA
[b] Department of Pulmonary & Critical care Medicine, St Vincent Mercy Medical Center, Toledo, Ohio, USA

Received 5th April 2009; revised version received 22 June 2009; accepted 22nd September 2009

Abstract

Endobronchial lipomas are rare benign tumours of the lung. Bronchial occlusion may lead to a misdiagnosis of asthma or malignancy. We describe a 52-year-old man treated for asthma for several years, who presented with non-resolving right upper lobe pneumonia. Bronchoscopy proved to be diagnostic and therapeutic. Clinical characteristics of this unique entity are discussed.

© 2009 General Practice Airways Group. All rights reserved.

F Irani *et al. Prim Care Resp J* 2009; **18**(X): XXX-XXX
doi:10.4104/pcrj.2009.00070

Keywords Bronchial neoplasms; lipoma; asthma

Copyright Primary Care Respiratory Society UK
Reproduction prohibited

Introduction

Benign tumours of the lung and endobronchial tree are uncommon. Endobronchial lipomas account for only 0.1-0.5% of all benign tumours[1] and need to be differentiated from malignant lesions. Despite their low incidence and benign nature, more than half of all patients with endobronchial lipomas undergo radical procedures such as lobectomy and pneumonectomy due to their post-obstructive changes.[2] We report here a 52-year-old man previously diagnosed with asthma due to a chronic cough and intermittent shortness of breath. His presentation with a non-resolving pneumonia led to the diagnosis of an endobronchial lipoma, thus highlighting the insidious nature of this rare entity.

Case history

A 52-year-old man was admitted with right-sided pleuritic chest pain, shortness of breath and rigors of one-week duration. He did not have cough or haemoptysis. He had been diagnosed with asthma several years before, based on symptoms of an intermittent dry cough and shortness of breath. No lung function tests were available for review. His prescribed bronchodilators did not seem to provide any relief. He had a 7.5 pack-year history of smoking. Examination revealed an obese man, with dullness to percussion and coarse crepitations at the right upper chest. Laboratory examination demonstrated neutrophilic leucocytosis.

Chest radiographs revealed a patchy density in the right upper lobe (see Figure 1). Antibiotics for community-acquired pneumonia were initiated. Non-resolution of symptoms necessitated a computerised tomography (CT) scan of the chest that demonstrated a fat tissue density in the right main stem bronchus with consolidation of the posterior segment of the right upper lobe (Figure 2).

Flexible bronchoscopy showed a total obstruction of the right upper lobe bronchus by several fleshy yellowish polypoid masses arising from the segmental bronchi of the right upper lobe (Figure 3). Histopathological examination of the biopsies confirmed benign adipose tissue covered by bronchial mucosa and normal respiratory epithelium with no evidence of malignancy, indicating a lipoma (Figure 4). Rigid bronchoscopy for complete excision was scheduled as an outpatient. The patient continued to remain asymptomatic when reviewed at 6-month follow-up.

* **Corresponding author:** Dr Farzan Irani, Department of Internal Medicine, St Vincent Mercy Medical Center, 2213 Cherry Street, Toledo, Ohio, USA 43608 Tel: +1-202-906-0401 Fax: +1-419-251-6750 E-mail: farzan_i@yahoo.com

Copyright PCRS-UK, reproduction prohibited

AHEAD OF PRINT - ARTICLE IN PRESS

Figure 1. Chest X-ray revealing streaky density in the right upper zone. [Arrow]

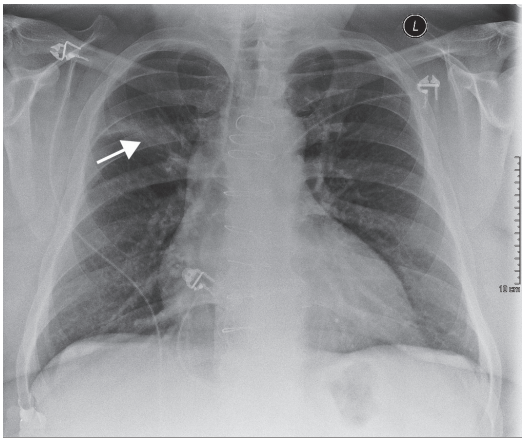

Figure 2. CT chest demonstrating fat tissue densities in right main stem bronchus [Arrows]

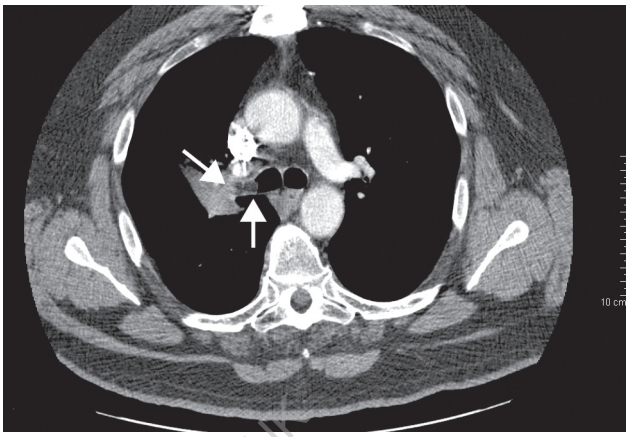

Figure 3. Endobronchial lipomas visualised as fleshy yellowish polypoid masses arising from the segmental bronchi of right upper lobe on bronchoscopy [Arrows]

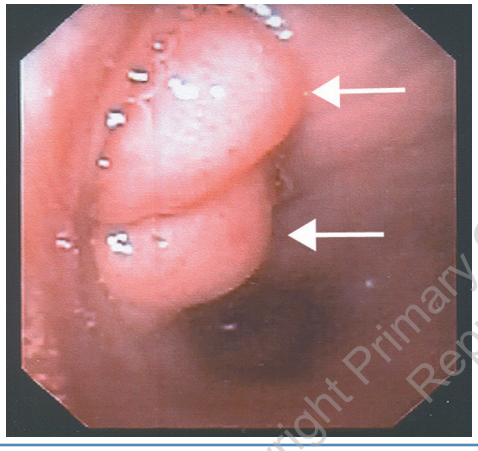

Figure 4. Lipoma specimens with H& E stain 20X. Adipose tissue covered by normal respiratory epithelium

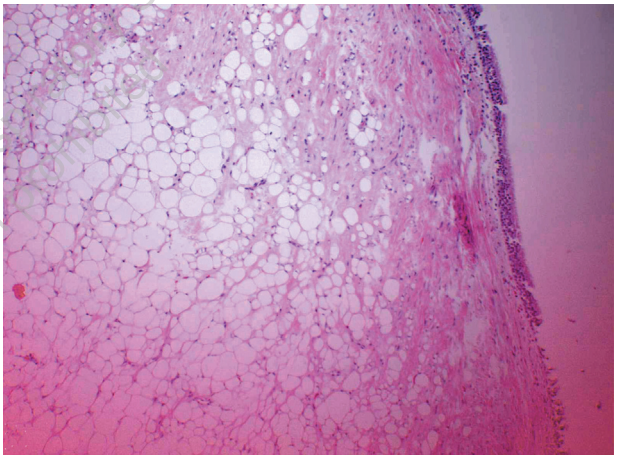

Copyright Primary Care Respiratory Society UK
Reproduction Prohibited

Discussion

Endobronchial lipomas are extremely unusual and occur more commonly in males in their 5th or 6th decades. Obesity and smoking are risk factors. Symptoms occur late because of the indolent nature of the lesions[1] and depend on the degree of airway obstruction. Cough is the most common presenting complaint, occurring in 86% of cases.[2] Recurrent pneumonias, wheeze and dyspnoea are also common. Haemoptysis is unusual due to the avascular nature of these tumours. Intermittent, low-grade respiratory symptoms can often be misdiagnosed as asthma.[2]

Endobronchial lipomas favour the right main or lobar bronchi, with the majority arising from fat tissue in the sub-mucosal layer.[1] Transbronchial extension is rare. Chest radiography is abnormal in 80% of cases, but is generally non-diagnostic. A fat tissue density without contrast enhancement on CT scan of the lungs is diagnostic. Magnetic resonance imaging is equally promising in detecting these fat density lesions.[3] Bronchoscopy remains indispensable, as it identifies the lesion location and facilitates collection of tissue for histopathology.[1] However, the accuracy of transbronchial biopsy in obtaining a biopsy is rather low. A recent retrospective study by Nassiri *et al.* suggested that rigid bronchoscopy is superior to flexible bronchoscopy for definitive diagnosis, as it provides larger specimens through mechanical debulking.[4]

Differentiation from malignancy is imperative. Macroscopically, lipomas appear as yellow-grey masses with firm capsules. They may be pendunculated or sessile, and can have a growth that resembles an iceberg.[4,5] Histologically, they are composed of mature adipocytes, with a stroma containing lymphocytes and histiocytes and lined by respiratory epithelium. Squamous metaplasia in the surface epithelium is uncommon.[2]

Copyright PCRS-UK, reproduction prohibited

AHEAD OF PRINT - ARTICLE IN PRESS

Learning Points:

- Endobronchial lipomas are rare, benign tumours of the lung.
- They may be clinically significant, mimicking malignant neoplasms, asthma or chronic obstructive pulmonary disease.
- Early bronchoscopy is diagnostic, therapeutic, and may prevent progression to irreversible, distal lung parenchymal damage.

Our patient had been diagnosed with asthma for the past few years, which did not respond to conventional inhaler therapy. Retrospectively, his intermittent dyspnoea may have been due to subtotal bronchial occlusion by the lipoma.

Bronchoscopic resection is considered the treatment of choice. The use of rigid bronchoscopic techniques has been favoured, as it results in complete resection of the lipoma with preservation of lung parenchyma.[4] In our patient, inability to grasp the lipoma necessitated the use of a rigid bronchoscope. YAG laser and cautery have also been described as alternative therapeutic modalities.[4,5] Aggressive surgical resection may be required if it is difficult to exclude malignancy, if the presence of extra-bronchial growth or sub-pleural lipomatous disease is noted, if evident peripheral irreversible lung parenchymal changes are noted, or if technical difficulties during bronchoscopic resection are expected.[6]

In conclusion, clinicians should be aware of this rare entity that can clinically mimic other common pulmonary pathology. Early resection may avert significant morbidity due to distal lung parenchymal damage.

Source of Support
Nil

Conflicts of Interest:
Nil

Disclosures
Nil

Contributions
Dr B. Kumar and Dr. P. Reddy took care of the patient and wrote the case report. Dr. F. Irani and Dr. R. Kasmani wrote the discussion and edited the manuscript. Dr. R. Narwal-Chadha and Dr. J. Tita were responsible for patient follow-up and assisted with revision of the manuscript.

References

1. Muraoka M, Oka T, Akamine S, *et al*. Endobronchial lipoma: Review of 64 cases reported in Japan. *Chest* 2003;**123**:293-6. http://dx.doi.org/10.1378/chest.123.1.293
2. Yokozaki M, Kodama T, Yokose T, *et al*. Endobronchial lipoma: A report of three cases. *Jpn J Clin Oncol* 1996;**26**:53-7.
3. Rodriguez E, Pombo F, Gallego C, Otero I. Endobronchial lipoma. Computed tomography and magnetic resonance. *Chest* 1994;**105**:1628.
4. Nassiri AH, Dutau H, Breen D, *et al*. A multicenter retrospective study investigating the role of interventional bronchoscopic techniques in the management of endobronchial lipomas. *Respiration* 2008;**75**:79-84.
5. Huisman C, van Kralingen KW, Postmus PE, Sutedja TG. Endobronchial lipoma: A series of three cases and the role of electrocautery. *Respiration* 2000;**67**:689-92. http://dx.doi.org/10.1159/000056302
6. Filosso PL, Giobbe R, Mossetti C, Ruffini E, Oliaro A. Hemoptysis caused by an endobronchial lipoma. *J Thorac Cardiovasc Surg* 2008;**135**:954-5. http://dx.doi.org/10.1016/j.jtcvs.2007.10.049

Available online at **http://www.thepcrj.org**

Copyright Primary Care Respiratory Society UK
Reproduction prohibited

Copyright PCRS-UK, reproduction prohibited