Dermatology Online Journal
UC Davis

Peer Reviewed

Title:
Indolent systemic mastocytosis: a case and review of the current available treatment options

Journal Issue:
Dermatology Online Journal, 19(6)

Author:
Lee, Yvonne, Princess Alexandra Hospital, Brisbane, Queensland, Austrailia
Wood, Peter, Princess Alexandra Hospital, Brisbane, Queensland, Austrailia
Soyer, H Peter, Princess Alexandra Hospital, Brisbane, Queensland, Austrailia

Publication Date:
2013

Publication Info:
Dermatology Online Journal

Permalink:
http://escholarship.org/uc/item/8n015001

Acknowledgements:
We thank Dr Nick Mellick (Sullivan and Nicholaides Pathology) for reporting and photographing the histopathology slides and Dr Scott Webber and Dr Parastu Banan for provision of photos from 2010 for comparative purposes.

Keywords:
Medicine

Local Identifier:
doj_18562

Abstract:
Mastocytosis denotes a heterogeneous group of disorders characterized by abnormal growth and accumulation of mast cells. Cutaneous mastocytosis is characterized by skin-limited disease and is the most common subtype. Systemic mastocytosis has extracutaneous organ involvement with variable symptomatology and prognosis. Clinical manifestations are secondary to mediator release or direct organ infiltration of mast cells. Current available treatment for systemic mastocytosis is non-curative with conventional symptom-directed therapy for all subtypes. Cytoreductive agents are available for those with refractory symptoms or extensive extracutaneous disease. To date, clinical responses remain mixed and systemic mastocytosis is still an incurable condition.

eScholarship
University of California

eScholarship provides open access, scholarly publishing services to the University of California and delivers a dynamic research platform to scholars worldwide.

Copyright Information:

Copyright 2013 by the article author(s). This work is made available under the terms of the Creative Commons Attribution-NonCommercial-NoDerivs3.0 license, http://creativecommons.org/licenses/by-nc-nd/3.0/

eScholarship
University of California

eScholarship provides open access, scholarly publishing services to the University of California and delivers a dynamic research platform to scholars worldwide.

Volume 19 Number 6
June 2013

Case Report

Indolent systemic mastocytosis: a case and review of the current available treatment options

Yvonne Lee MBBS, Peter Wood MBBS MD MRCP FRACP FRCPA, H Peter Soyer MD FACD

Dermatology Online Journal 19 (6): 7

Princess Alexandra Hospital, Brisbane, Queensland, Austrailia

Correspondence:
Yvonne Lee, MBBS, dryvonnelee@hotmail.com
Princess Alexandria Hospital
Brisbane, Queeensland, Austrailia

Abstract

Mastocytosis denotes a heterogeneous group of disorders characterized by abnormal growth and accumulation of mast cells. Cutaneous mastocytosis is characterized by skin-limited disease and is the most common subtype. Systemic mastocytosis has extracutaneous organ involvement with variable symptomatology and prognosis. Clinical manifestations are secondary to mediator release or direct organ infiltration of mast cells. Current available treatment for systemic mastocytosis is non-curative with conventional symptom-directed therapy for all subtypes. Cytoreductive agents are available for those with refractory symptoms or extensive extracutaneous disease. To date, clinical responses remain mixed and systemic mastocytosis is still an incurable condition.

Introduction

Mastocytosis is a heterogeneous group of disorders defined by clonal proliferation of abnormal mast cells in one or more organ systems. Based on the 2008 World Health Organization (WHO) classification, it can be divided into cutaneous and systemic variants (Table 1) [1]. Cutaneous mastocytosis is more common in children than adults and represents a benign group of skin-limited disease [2]. Most adult patients present with systemic mastocytosis (SM), the extent of skin involvement depending upon the subtype. From a dermatological perspective, cutaneous mastocytoses and indolent SM are important conditions to recognize because these subtypes a characterized by skin manifestations. Other variants of SM including SM with associated clonal hematological non-mast-cell-lineage disease (SM-AHNMD) and aggressive SM typically lack skin lesions and are characterized by symptomatic involvement of bone marrow, lymph nodes, spleen, liver, and the gastrointestinal tract. Prognosis among the different SM subtypes is highly variable and ranges from those with indolent clinical course and a normal life expectancy to aggressive multi-organ disease with poor long-term survival. Currently available therapies target mediator-related symptoms and may include cytoreductive agents when clinically indicated [1,2].

4 MAJOR TYPES OF SYSTEMIC MASTOCYTOSIS

1. Indolent systemic mastocytosis
2. Systemic mastocytosis accompanied by an associated haematological non-mast cell disorder (SM-AHNMD)
3. Aggressive systemic mastocytosis and variant lymphadenopathic mastocytosis with eosinophilia
4. Mast cell leukemia

Diagnosis of SM requires 1 major and 1 minor criterion or 3 minor criteria		OUR PATIENT FULFILLS
Major	Multifocal dense infiltrates of mast cells in tissue sections	✓
Minor	>25% spindled, immature or atypical mast cells in tissue sections or bone marrow aspirate smears	✓
	Detection of KIT D816 V mutation	✓
	Expression of CD2 and/or CD25 in mast cells	X
	Serum total tryptase persistently exceeds 20ng/mL	✓

Table 1: 4 major types of systemic mastocytosis. Diagnostic criteria for systemic mastocytosis

Case Report

A 33-year-old man presented to Queensland Institute of Dermatology in early 2010 with a 13-year-history of generalized erythematous eruption, which started on his neck and slowly became progressive in the 2 years prior to presentation. The eruption wa largely asymptomatic but was occasionally associated with heat- and exercise-induced pruritus. Systemically, the patient experienced a variety of symptoms including intermittent dizziness, abdominal discomfort, fatigue, mood swings, and problems with short term memory. He had no bone pain, history of fracture, weight loss, or night sweats. He had an unremarkable medical and medication history.

On examination, there were multiple monomorphic red-brown macules and papules, which were most numerous on his trunk and proximal extremities and noticeably spared his face, palms, and soles (Figure 1-5). Darier's sign was negative. Abdominal examination was unremarkable and there was no palpable peripheral lymphadenopathy.

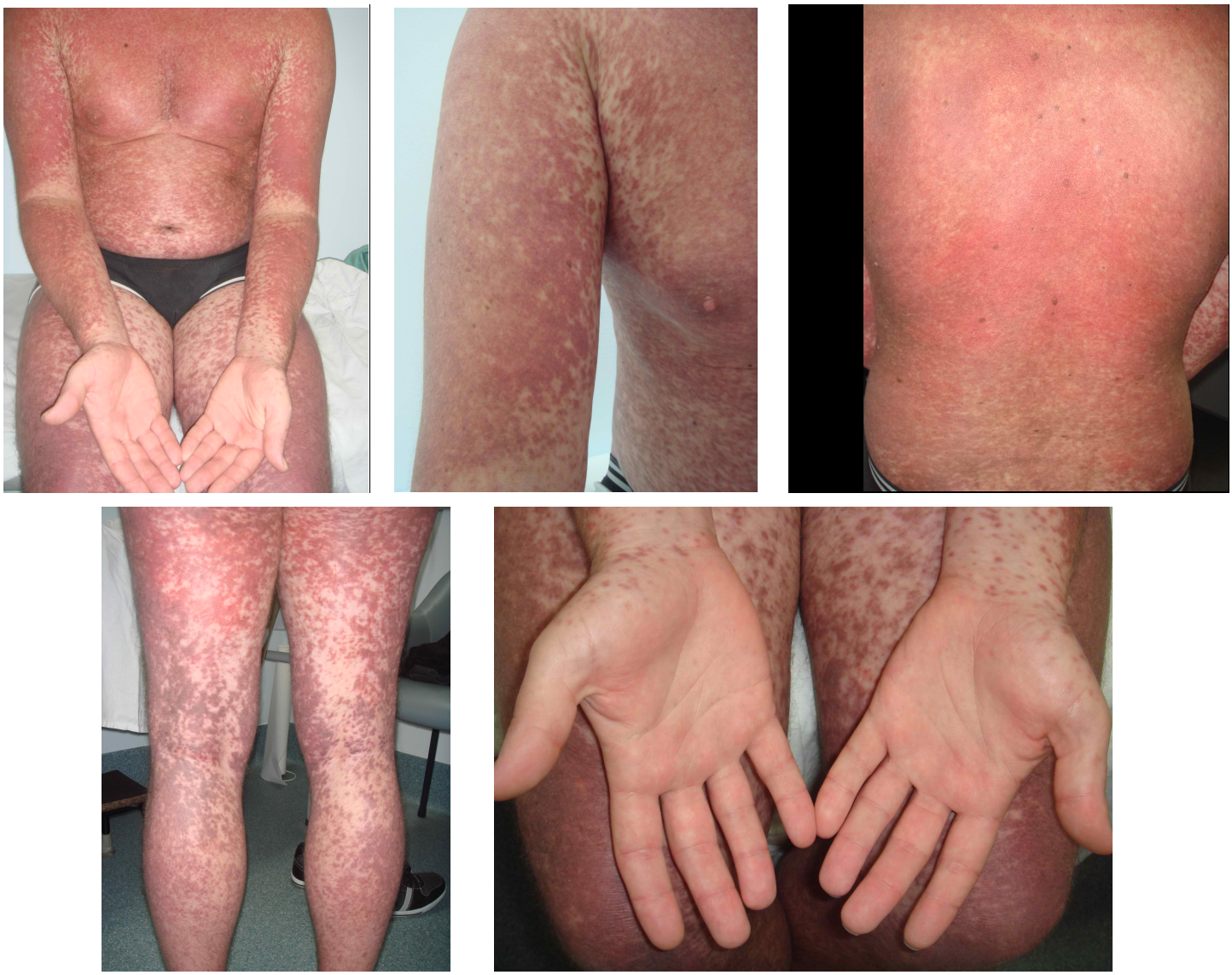

Figure 1 – 5: Widespread urticaria pigmentosa with confluent urticated erythematous maculopapules. There is obvious sparing of palmar surface

Histopathologically, lesional biopsies from the trunk stained with routine Hematoxylin and Eosin showed some spindle cells within the upper reticular dermis as well as scattered cells within the papillary dermis exhibiting basophilic cytoplasmic granules (Figure 6 and 7). Further stains with Toluidine blue, Leder and CD117 confirmed the presence of mast cells and our clinical diagnosis of urticaria pigmentosa (Figure 8 and 9).

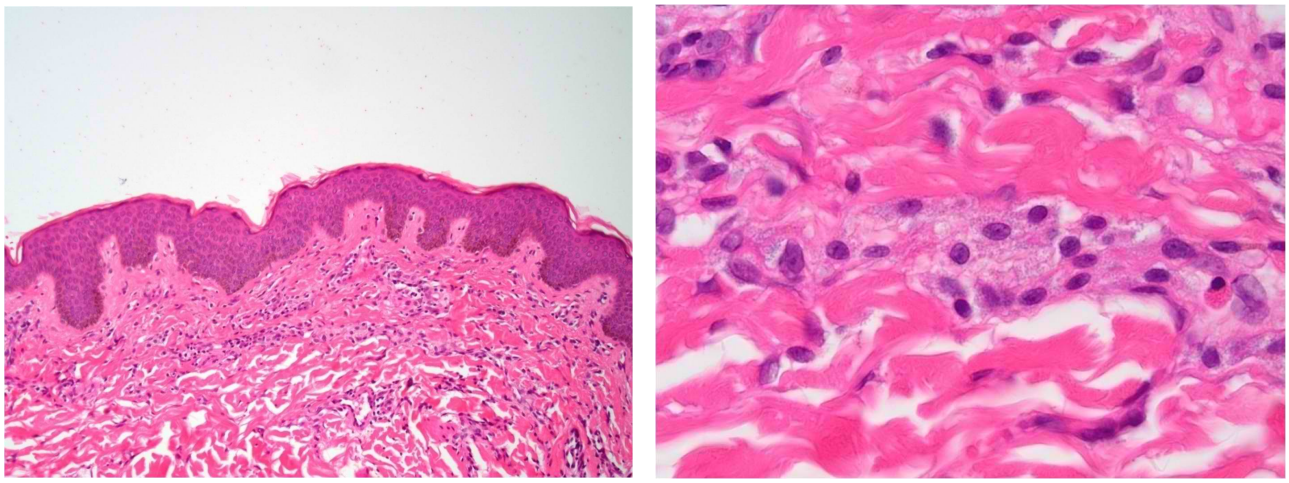

Figure 6: Biopsy stained with Hematoxylin and Eosin shows an unremarkable epidermis with scattered cells within papillary and reticular dermi

Figure 7: With higher magnification, hematoxylin and eosin stain reveals numerous mast cells characterised by basophilic cytoplasmic granules

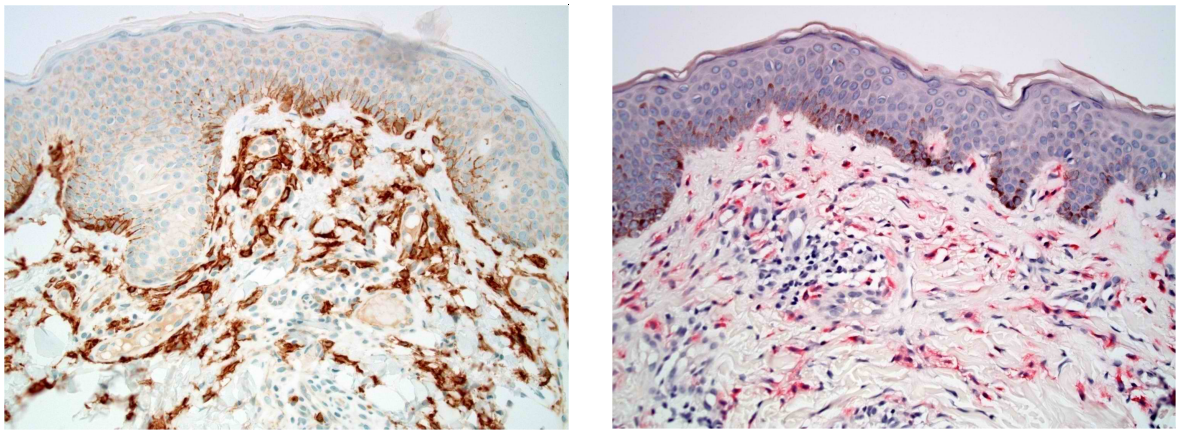

Figure 8: CD117 stain confirms the presence of mast cells (brown)

Figure 9: Leder stain confirms the presence of mast cells (pink)

Preliminary blood tests revealed an elevated serum tryptase level (140ng/ml) with normal full blood count, renal function, liver function, and serum electrophoresis. Ongoing care was subsequently transferred to a Dermatology department of a public tertiary hospital in which Hematology department colleagues were consulted for additional investigations to assess for extracutaneous involvement. Investigations that ensued included an abnormal bone marrow trephine. Toluidine blue staining and immunohistochemistry with CD117 demonstrated multifocal dense infiltrates of mast cells. The majority of the mast cells demonstrated a spindled morphology and comprised 5-10% of total cells present. Flow cytometry of the bone marrow aspirate was performed but was unable to detect a mast cell population (defined by strong CD45/highSS/CD117+); the cells may not have been aspirated, thereby resulting in negative findings despite the presence of mast cells in the bone marrow trephine. Further investigation included cytogenetic studies undertaken from the bone marrow aspirate, which revealed a positive A2447T (D816V) mutation in exo 17 of the KIT gene. CT screening showed only reactive cervical lymphadenopathy. Based on all investigations, a diagnosis of indole SM with urticaria pigmentosa was reached.

The patient was counselled regarding avoidance of triggers of mast cell activation as well as the need for a medical alert bracelet and Epi-Pen. His treatment included high dose combination H1 and H2 antihistamines, moderately potent topical corticosteroids, and vitamin D and calcium for bone protection. Narrowband UVB phototherapy was not considered given the patient's past history of sk cancer and likely prolonged treatment duration. Over the ensuing 2 years, his serum tryptase level progressively increased (186ng/ml in May 2012) whilst his health slowly deteriorated with physical fatigue, mental clouding, frequent abdominal discomfort, unpredictable bouts of dizziness, and a widespread pruritic cutaneous eruption (Figure 10). The patient was eventually unable to sustain full-time work. Despite the availability of tyrosine kinase inhibitors, which aim to decrease the mast cell burden, several attempts at obtaining these investigational agents were unsuccessful, including our latest application in September 2012 for midostaurin. Although our patient has mast cell disease with extensive skin manifestation and bone marrow involvement, he did not qualify for these newer medications because he does not have evidence of cytopenia, hepatomegaly, or splenomegaly, which would indicate more extensive systemic involvement and therefore a more advanced subtype of systemic mastocytosis. Therapies such as interferon-α were considered inappropriate given its potential side effects.

Discussion

The WHO diagnostic criteria for diagnosis of SM requires either 1 major criterion and 1 minor criterion or 3 minor criteria (Table 1) [1]. Our patient fulfilled the major criterion and 3 out of 4 minor criteria required for a diagnosis of SM. Mast cell immunophenotyping (CD2 and CD25) was unable to be determined owing to false negative flow cytometry of the bone marrow aspirate. Our patient lacked clearly defined markers of systemic involvement ("C findings") because he had no cytopenia, pathologic fracture, malabsorption with hypoalbuminemia and weight loss, hepatomegaly with ascites, or splenomegaly with hypersplenism [4]. Because his extracutaneous involvement is limited only to bone marrow, he fulfils the current criteria for the indolent variant of SM a opposed to aggressive SM, which is characterized by the presence of "C findings," or mast cell leukemia which requires >20% of ma cells on bone marrow smear [4].

The most common genetic abnormality in patients with sporadic mastocytosis involves codon 816 of the c-KIT gene [3]. KIT (CD117) is the protein product of proto-oncogene *c-KIT* located on chromosome 4q12, belonging to the type III tyrosine kinase receptor family. Activation of KIT induces cellular growth and enhances mast cell survival and proliferation by preventing apoptosis Our patient was found to have a point mutation involving Asp816Val (D816V) at exon 17 of the c-KIT gene. This is in fact the most common mutation and is detectable in more than 80% of adult SM, irrespective of the subtype [2]. Other less common amino acid substitutions include D816K, D816Y, D816F, D816H, and V560G [4].

Most patients with indolent SM typically have a stable clinical course with a favorable prognosis. However this does not apply to all cases as demonstrated by our patient's progressive cutaneous disease and systemic symptoms. Despite the majority having a normal life expectancy, lifelong surveillance is recommended for all patients because there is a 3% risk of disease progression to a more aggressive subtype [2]. Aggressive mast cell neoplasms including aggressive SM and mast cell leukemia confer poor prognosis and remain incurable at present [2].

Treatment of SM is highly individualized. It can be broadly divided into mast cell degranulation symptom control, mast cell burden reduction (cytoreductive therapy), and supportive measures including red blood cell transfusion and osteoporosis prevention [2]. Conventional therapies integral to management include avoidance of triggers of mast cell degranulation, adrenalin, and combination H1 and H2 antihistamines. Skin directed therapies such as topical corticosteroids and oral psoralen and UVA may provide transient relief of pruritus [5,6]. Systemic corticosteroids can be useful for recurrent and more severe mediator-related symptoms but are not long term options [7]. Whilst oral cromolyn sodium is most beneficial for gastrointestinal symptoms, leukotriene antagonists can be used for respiratory and cutaneous manifestations [8,9]. Omalizumab, a humanized murine monoclonal antibody, which selectively binds to human Immunoglobulin E, has been shown to be beneficial for those with syncopal episodes associated with unprovoked anaphylaxis [10].

Cytoreductive therapy is typically reserved for aggressive SM and is rarely considered for indolent SM unless symptomatically sever as in the case of our patient. Interferon-α with or without corticosteroids is often considered first line cytoreductive therapy in symptomatic systemic mastocytosis, although it is not uniformly effective and is frequently complicated by side effects including flu-like symptoms, hypothyroidism, cytopenia, and depression [4]. Cladribine, a nucleoside analogue, has activity in all systemic mastocytosis subtypes and is useful for rapid mast cell debulking or in cases refractory to or intolerant of IFN-a [4]. Potential toxiciti include myelosuppression and increased infection risks.

Since 2006, there have been ongoing trials for tyrosine kinase inhibitors reported to inhibit c-kit activity. In general, this group of medications has very good side effect profiles, although they have only achieved modest clinical efficacy. Thus far, nilotinib and multikinase inhibitors such as midostaurin and dasatinib have shown variable efficacy against various KIT mutations including D816V [4,11]. Imatinib mesylate is the most widely recognized compound. Its use, however, is limited to those who do not have the D816V KIT mutation [12,13].

Our case raises 2 important issues for discussion. Firstly, despite its name, "indolent" SM can be functionally debilitating and behave in a non-indolent fashion. Our patient suffered significant systemic symptoms and demonstrated progressively worsening cutaneous eruption as evident by the serial photographs. Secondly, we had restricted therapeutic options for our patient because his level of functional impairment was not mirrored by his limited extracutaneous involvement, being only that of bone marrow. Despite an elevated tryptase level at 186ng/ml and an increased bone marrow mast cell burden at 10%, he is still categorized at the benign end o the SM spectrum and was therefore not eligible to receive these potentially beneficial newer kinase inhibitors presently under clinica trials.

Figure 10: Comparative photographs showing progression of cutaneous disease from 2010 (A) to 2012 (B)

Conclusion

Mastocytosis represents a spectrum of clinical disorders characterized by abnormal proliferation and accumulation of mast cells. Disease severity ranges from indolent with isolated cutaneous involvement to aggressive systemic manifestations. We present a patient with indolent systemic mastocytosis characterized by severe skin manifestation in addition to elevated serum tryptase level, bone marrow involvement, and proven c-KIT mutation. During a 2-year observation period, progression of cutaneous and systemic symptoms was noted without progression of extracutaneous disease. Specific treatment with targeted therapies, such as tyrosine kinase/ multikinase inhibitors, may be clinically useful. However, these have yet to be initiated owing to approval restrictions.

Reference

1. George TI, Horny HP. Systemic mastocytosis. Haematol Oncol Clin N Am. 2011; 25(5): 1067-83.
2. Sperr WR, Valent P. Diagnosis, progression patterns and prognostication in mastocytosis. Expert Rev. Hematol. 2012; 5(3): 261-74.
3. Kim KH, Tefferi A, Lasho TL, Finke C, Patnaik M, Butterfield J, McClure R, Li C, Pardanani A. Systemic mastocytosis in 342 consecutive adults: survival studies and prognostic factors. Blood 2009; 113: 5727-36.
4. Pardanani A. Systemic mastocytosis in adults: 2012 update of diagnosis, risk stratification, and management. Am J Hematol. 2012; 87(4): 401-11.
5. Lark J, McCrossin I. Systemic mastocysis: a case report. Aust. J. Dermatol. 1982; 23(1): 35-8.
6. Hartmann K, Henz BM. Mastocytosis: recent advances in defining the disease. Br J Dermatol. 2001; 144(4): 682-95.
7. Akin C, Metcalfe DD. Systemic mastocytosis. Annu. Rev. Med. 2004; 55:419-32.
8. Horan RF, Sheffer AL, Austen KF. Cromolyn sodium in the management of systemic mastocytosis. J Allergy Clin. Immunol 1990; 85(5): 852-55.
9. Tolar J, Tope WD, Neglia JP. Leukotriene-receptor inhibition for the treatment of systemic mastocytosis. N Engl J Med. 2004; 350(7): 735-6.
10. Carter M, Robyn J, Bressler P, Walker J, Shapiro G, Metcalfe D. Omalizumab for the treatment of unprovoked anaphylaxis i patients with systemic mastocytosis. J Allergy Clin Immunol. 2007; 119(6): 1550-1.
11. El-Agamy DS. Targeting c-kit in the therapy of mast cell disorders: Current update. Eur. J. Pharmacol. 2012; 690: 1-3.
12. Ma Y, Zeng S, Metcalfe DD, Akin C, Dimitrijevic S, Butterfield J, McMahon G, Longley B. The c-KIT mutation causing human mastocytosis is resistant to STI571 and other KIT kinase inhibitors; kinases with enzymatic site mutations show different inhibitor sensitivity profiles than wild-type kinases and those with regulatory-type mutations. Blood 2002; 99(5): 1741-4.
13. Ustun C, DeRemer DL, Akin C. Tyrosine kinase inhibitors in the treatment of systemic mastocytosis. Leuk Res. 2011; 35(9) 1143-52.