Characterization of bacterial and fungal biofilms in chronic rhinosinusitis

Andrew Foreman, B.M.B.S. (Hons.), Alkis James Psaltis, Ph.D., M.B.B.S., Lor Wai Tan, Ph.D., and Peter-John Wormald, M.D.

ABSTRACT

Background: *Conclusive evidence exists that biofilms are present on the mucosa of chronic rhinosinusitis (CRS) patients. Less is known about the species constituting these biofilms. This study developed a fluorescence* in situ *hybridization (FISH) protocol for characterization of bacterial and fungal biofilms in CRS.*

Methods: *Fifty CRS patients and 10 controls were recruited. Bacteria FISH probes for* Staphylococcus aureus, Haemophilus influenzae, *and* Pseudomonas aeruginosa *and a universal probe for fungi were applied to sinus mucosal specimens and then analyzed using confocal scanning laser microscopy.*

Results: *Thirty-six of 50 CRS patients had biofilms present in contrast to 0/10 controls, suggesting a role for biofilms in the pathogenesis of this disease.* S. aureus *was the most common biofilm-forming organism. Eleven of 50 CRS patients had characteristic fungal biofilms present.*

Conclusion: *This is the largest study of biofilms in CRS. It has validated mucosal tissue cryopreservation for delayed biofilm analysis. Fungal biofilms have been identified and the importance of* S. aureus *biofilms in the polymicrobial etiology of CRS is highlighted.*

(Am J Rhinol Allergy 23, 556–561, 2009; doi: 10.2500/ajra.2009.23.3413)

Key words: Bacteria, biofilms, CRS, cryopreservation, FISH, fungi, pathogenesis, *S. aureus*

Although chronic rhinosinusitis (CRS) places a significant socioeconomic burden on the community,[1] its etiopathogenesis remains largely unknown. It is presumed to result from a complex interaction between intrinsic host-related factors and extrinsic environment-related factors. A role has been proposed for external etiologic agents such as chronic bacterial infection,[2] chronic osteitis,[3] fungi,[4] and staphylococcal superantigens,[5,6] among others. In the recent literature, a potential role for bacterial biofilms in the etiology of CRS has been suggested.[7–11]

A bacterial biofilm is defined as a microbially derived sessile community characterized by cells that are irreversibly attached to a surface (live or inert), embedded in a self-produced extracellular polymeric substance matrix.[12] In assuming the biofilm phenotype, bacteria undergo a programmed switch in gene expression resulting in a down-regulated metabolic state and suppressed growth rate. These genotypic and phenotypic changes culminate in a range of features that differentiate biofilm-mediated diseases from planktonically driven acute infections. Biofilm-mediated diseases typically show a relapsing and remitting course, have variable bacterial culture rates, and show extreme antibiotic resistance.[13] There is an expanding understanding of the role of biofilms in otolaryngologic diseases such as otitis media with effusion,[14] chronic tonsillitis,[15] and tympanostomy tube otorrhea.[16] CRS has many features in common with other biofilm-mediated diseases and therefore it is not surprising that the biofilm paradigm has been applied to CRS and that a search for biofilms in these patients has been undertaken.

Numerous detection methods have been used to identify biofilms in CRS patients, including scanning electron microscopy,[7,17] Transmission electron microscopy,[8] and fluorescence *in situ* hybridization (FISH).[18,19] The work from our department has shown that the use of fluorescent nucleic acid probes, available in the BacLight staining kit (Invitrogen Corp., Grand Island, NY), with confocal scanning laser microscopy analysis is the most specific method for biofilm detection on sinonasal mucosal specimens.[11] However, an inherent limitation of this technique is that it does not allow the identification of the individual microbial species that comprise a biofilm in our CRS patients. Therefore, we set out to reevaluate the usefulness of FISH in the species documentation of CRS biofilms and to determine the most common species isolated in this chronic disease.

METHODS

Study Design and Population

This prospective, controlled, blinded study was undertaken in the tertiary referral rhinology practice of the senior author (P.J.W.) based in Adelaide, South Australia, Australia. The institution's Human Ethics Committee approved the study and all patients provided their consent to participate in the study. The disease group consisted of 50 consecutive patients with CRS, as diagnosed using the criteria outlined by the Rhinosinusitis Task Force in 2003,[20] undergoing endoscopic sinus surgery. Ten patients with no clinical or radiological evidence of sinus disease, undergoing endoscopic procedures such as transsphenoidal hypophysectomy, optic nerve decompression, and cerebrospinal fluid leak repair were recruited for the control group. Posterior ethmoid and sphenoid sinus tissue normally harvested and discarded as part of the surgical approach for these procedures was used. Exclusion criteria consisted of age <18 years, pregnancy, immune-compromised patients, and impairment in mucociliary function (*e.g.*, cystic fibrosis or Kartagener's syndrome).

Preoperative data collection included symptom scores, allergy status, paranasal sinus CT scores, medical history, presence of specific allergies, smoking status, and nasal endoscopy findings. A standard symptom scoring system was used, whereby the treating surgeon would record the severity of the patient's sinonasal symptoms, as described by the patient (*i.e.*, patient generated and surgeon recorded). Specifically, nasal obstruction, rhinorrhea, headache/facial pain, altered smell, and postnasal drip was assessed on a scale of 1–5 (absent, mild, moderate, severe, or extreme), giving a total symptom score out of 25. Allergy status was determined using a modified

From the Department of Surgery–Otorhinolaryngology, Head and Neck Surgery, University of Adelaide and Flinders University, Adelaide, Australia

Presented at the American Rhinologic Society Annual Meeting, San Diego, California, October 3, 2009

Financial support was provided by the Garnett Passe and Rodney Williams Memorial Foundation

Address correspondence and reprint requests to P.J. Wormald, M.D., Department of Otorhinolaryngology, Head and Neck Surgery, The Queen Elizabeth Hospital, 28 Woodville Road, Woodville, SA 5011, Australia

E-mail address: peterj.wormald@adelaide.edu.au

Copyright © 2009, OceanSide Publications, Inc., U.S.A.

radioallergosorbent test (RAST) for common environmental allergens and total serum IgE level. No patients had taken antibiotics, antifungals, or steroids in the 3 weeks before their surgery. Intraoperative data, such as presence of polyps, pus, or eosinophilic mucus (EM), was recorded. All patients had tissue sent for histological analysis to facilitate subclassification into CRS and EM-CRS and when clinically indicated, patients had microbiology swabs sent for bacterial and fungal cultures.

Tissue Collection and Transport

All CRS patients had sinus mucosal tissue harvested from the maxillary sinus or ethmoid cavity during their procedure. In control patients, sinus tissue was harvested from the posterior ethmoid and sphenoid sinuses. Tissue was immediately stored in Dulbecco's modified Eagle medium (Gibco, Invitrogen Corp., Grand Island, NY), without antibiotics or amphotericin B, and transported on ice for FISH analysis. Tissue was washed thoroughly in three separate beakers of MilliQ water (Millipore, Billerica, MA) to remove any planktonic bacteria and frozen to −80°C for FISH analysis at a later time. All samples were deidentified by the person collecting the specimens and labeled numerically from 1 to 60 to ensure observers assessing the FISH-stained mucosa were blinded to the clinical status of the patient.

FISH Protocol

The selection of our four FISH probes (*Staphylococcus aureus*, *Pseudomonas aeruginosa*, *Haemophilus influenza*, and universal fungal probe) was based on a literature review of the most important pathogenic bacteria in CRS and our own anecdotal evidence of the importance of *S. aureus*. Probes for *S. aureus* and *P. aeruginosa*, as well as a universal fungal probe, were commercially available (AdvanDx, Woburn, MA). No *H. influenza* was commercially available and therefore a novel probe was developed in our laboratory from published sequences.[21] Positive and negative control slides, using plated bacteria, were also analyzed.

The AdvanDx FISH protocol was followed as per the manufacturer's instructions. Briefly, single 5 × 5-mm pieces of sinus mucosal tissue for each of the four probes were heat fixed to individual glass slides, dehydrated in 90% alcohol, and air-dried. The probe was applied to the tissue and hybridization at 55°C occurred for 90 minutes. In addition, the *H. influenza* tissue was prehybridized with BET-42 (Sigma-Aldrich, St. Louis, MO) for 30 minutes to reduce nonspecific binding of the *H. influenza* probe. Slides were then washed in the manufacturer's wash solution for 30 minutes at 55°C and air-dried before analysis.

Tissue Cryopreservation Validation

The previous biofilm analysis in our department has been performed on fresh sinus mucosal tissue specimens. However, in contrast to the BacLight protocol, FISH is time-consuming. Therefore, we have investigated the possibility of cryopreservation of mucosal tissue for biofilm analysis at a later time. To do this, we parallel processed the first 15 patients; *i.e.*, the FISH protocol was performed on fresh tissue as well as performed at a later time using tissue that had been frozen at −80°C. We found that cryopreservation of tissue did not distort the biofilm architecture and it did not result in bacterial contamination of the tissue. The results of the fresh and frozen tissue analysis were identical.

Tissue Analysis and Biofilm Determination

The posthybridization slides were transported to Adelaide Microscopy for analysis using the Leica TCS SP5 Confocal Scanning Laser Microscope (Leica Microsystems, Wetzlar, Germany). Using the Leica Application Suite Advanced Fluorescence (Leica Microsystems), the entire tissue area and depth were scanned by an investigator blinded to the disease status of the patient. Imaging was performed at various magnifications (×20–80), to appreciate the overall structure of the biofilm as well as to accurately determine the size of the brightly fluorescing areas. Axial stacks taken in the Z plane, with a slice thickness of 0.5 μm, were taken through areas representative of biofilm. Bacterial biofilms were defined as areas of clustered fluorescence with elements of bacterial size (0.5–3 μm) and shape, arranged in a characteristic three-dimensional structure. A less intense "blush" surrounding the areas of discrete brightly fluorescing areas (*i.e.*, the bacteria) was deemed to represent the exopolysaccharide matrix of the biofilm. Fungal biofilms were declared present when brightly fluorescing areas were contained within a typical fungal biofilm structure consisting of hyphae, with or without surrounding areas of fluorescence. Fluorescence not consistent with this definition was not recorded in this study, but may represent other fungal elements. After acquisition of this data, two independent, blinded observers then analyzed all of the images using the guidelines set out previously.

Statistical Analysis

The results of this study were analyzed using GraphPad Prism 5.0 software (GraphPad Software, San Diego, CA). For our analysis, median and interquartile ranges were used because of the nonparametric nature of the data. Values of $\alpha = 5\%$, $\beta = 20\%$, and p values were considered significant for $p \leq 0.05$. Fisher's exact test was used for dichotomous data and the Mann-Whitney U test was used for ordinal data. To assess interrater variability between the two image observers, Cohen's κ-statistic was calculated using Minitab 15 Statistical Software (Minitab, Inc., State College, PA).

RESULTS

A total of 60 patients, 50 CRS and 10 controls, were recruited for this study. A summary of the relevant results is contained in Table 1.

Table 1. **Results summary comparing chronic rhinosinusitis (CRS) subgroups with controls**

	Biofilm positive CRS	Biofilm negative CRS	Control
Number	36	14	10
Age (median and IQR)	48 (37–56)	53 (38–59)	44 (32.75–62.75)
Gender (M:F)	21:14	7:7	2:8
Revision surgery	21/36	9/14	0/10
Symptom scores	18 (16–20)	16 (14.75–18.25)	0
L-M score	16 (10–21.5)	13.5 (9.75–18)	0
Presence of polyps	17/36 (47%)	5/14 (36%)	N/A
Presence of EM	23/36 (64%)	6/14 (43%)	N/A
Positive bacterial culture	19/36 (53%)	11/14 (79%)	N/A

IQR = Inter-quartile range; L-M = Lund-MacKay; EM = Eosinophilic mucus.

Demographic Data

The CRS group comprised 29 men and 21 women, with a mean age of 47.62 ± 12.74 years. The control group was made up of two men and eight women with a mean age of 44.70 ± 16.16 years. Of the 10 control patients, 8 were undergoing transsphenoidal hypophysectomy, 1 was undergoing optic nerve decompression, and 1 was undergoing a cerebrospinal fluid leak repair.

Preoperative Data

Of the CRS group, 22 had a history of asthma and 6 were regular cigarette smokers at the time of their surgery. In this group, 17 had reported drug allergies and 23 tested positive to at least one allergen, as assessed using a modified RAST. Of the environmental allergens tested, allergy to molds was the most common among this group. The mean symptom score for the CRS patients was 17.41 ± 2.63. Nasal obstruction was the most troubling symptom for these patients with a mean score of 3.77 ± 0.82. Most patients had pansinusitis on CT scanning. Thirty of 50 (66%) of the CRS patients were undergoing revision surgery, reflecting the tertiary nature of this practice.

In contrast to these, the control group consisted of only one patient who had asthma, one patient who was a smoker, and one patient with a drug allergy. None of the control group had positive modified RAST testing. As per the inclusion and exclusion criteria, none of the control group reported any symptoms or radiological evidence of sinus disease.

Intraoperative Data

Twenty-two of 50 (44%) of the patients enrolled in this study had CRS with nasal polyposis. The remaining 28 patients had no evidence of polyposis at the time of surgery. On histological examination, 28/50 (56%) of the CRS patients could be classified as EM-CRS. Results of allergy testing and fungal culture allowed further subclassification of the EM-CRS group as follows: allergic fungal sinusitis, 3 patients; allergic fungal sinusitis–like, 7 patients, nonallergic fungal eosinophilic sinusitis, 1 patient; and the remaining 17 patients had chronic eosinophilic sinusitis. Four patients had positive fungal cultures at the time of surgery with two culturing *Aspergillus fumigatus*, one *Bipolaris australiensis*, and one *Penicillium* species.

Forty-two of 50 (84%) CRS patients had evidence of mucosal infection and microbiology swabs sent from the site. Thirty of 42 (71%) CRS patients had positive microbiology swabs, with 3 of these patients growing more than one organism on culture (Table 2). The multiple organism combinations were *S. aureus–Prevotella oris*, *S. aureus–Enterobacter aerogenes*, and *Klebsiella pneumonia*–group G *Streptococcus*. *S. aureus* was the most commonly isolated organism at the time of surgery and was seen in 12/30 (40%) positive swabs. *P. aeruginosa*, *H. influenza*, *Moraxella catarrhalis*, *Streptococcus pneumonia*, and coagulase-negative *Staphylococcus* were other species that were cultured in more than one patient.

Table 2. **Intraoperative bacterial culture results**

Species	Number of patients
Swab not sent	8
No growth on swab	12
S. aureus	12
P. aeruginosa	4
H. influenza	3
Coagulase-negative *Staphylococcus*	3
S. pneumonia	2
M. catarrhalis	2
K. pneumonia	1
Group G *Streptococcus*	1
P. oris	1
A. baumannii	1
E. coli	1
P. mirabilis	1
Enterobacter	1

Biofilm Data

Of the patients in the control group, 0/10 had biofilms present on the surface of their sinonasal mucosa. In contrast to this, 36/50 (72%) of the CRS patients had biofilms present. Representative examples of all four probes are shown in Fig. 1. These images show the characteristic biofilm morphology of brightly fluorescing organisms (bacterial and fungal) surrounded by a less intense matrix haze. Of the 36 biofilm-positive CRS patients, 17 patients had a single bacterial or fungal species present, 15 had two species present, and 4 patients had three species present (Table 3). *S. aureus* was the most frequently identified biofilm-forming organism, shown in 50% of the CRS group. Subgroup analysis investigating prevalence of biofilms in CRS with and without nasal polyposis, CRS with and without EM, and primary versus revision surgery did not yield statistically significant results. This is probably related to the small numbers in each subgroup.

In terms of interrater variability, a direct correlation was seen in 97.5% of the images between the two observers. Obviously, when analyzing images and producing dichotomous data, there is a 50% chance of achieving the same result by chance. Thus, Cohen's κ-statistic was calculated to correct for this possibility. Using that test, the interrater variability was 0.9292. This is >0.81 and therefore is considered to be in almost perfect agreement.[22]

DISCUSSION

This study represents the largest study to date investigating the role of biofilms in CRS. Using a validated FISH protocol, we have identified biofilms in 36/50 (72%) CRS patients compared with 0/10 control subjects. Although our study design can not exclude biofilms formed by other bacterial species in these control patients, at the very least, we have shown that the biofilm-forming organisms in disease are different from those in health. The absence of biofilms in our control patients is consistent with previous work from our department, using the nonspecific BacLight probe.[11] Using FISH, we have identified *S. aureus* as the most common biofilm-forming organism in our CRS patients—present in 50% of this study group. Furthermore, we have highlighted the polymicrobial nature of CRS by showing that over one-half of our CRS patients had biofilms formed by more than one organism (Table 3). Given the nature of FISH and the limited number of species probes used, this figure may actually be an underestimation of the true extent of polymicrobial disease in CRS.

Using a variety of imaging techniques, biofilms have been identified on the sinonasal mucosa of CRS patients.[8,11,18,19,23] Furthernore, the presence of biofilms has been associated with clinically more severe sinus disease.[11,24,25] These findings are replicated in the current study in which we found that biofilm-positive CRS patients had significantly worse symptom scores than the nonbiofilm cohort (Mann Whitney U test, $p = 0.0202$). However, there was no difference between Lund-MacKay CT scores (Mann Whitney U test, $p = 0.3518$), again reinforcing the lack of correlation between symptom scores and radiological assessment of disease severity.[26,27]

Studies using the BacLight protocol have identified biofilms in 44 and 48% of CRS patients, respectively.[11,25] There may be a number of reasons for the difference between these previous studies and the results of our current study. First, these two studies have investigated bacterial biofilms only and therefore patients with fungal biofilms would not have been included in the data analysis. Second, the burden of disease may differ. Finally, the sensitivity and specificity of the two techniques—FISH and BacLight—may be different. This is currently unknown and warrants additional research to confirm or refute this hypothesis.

The results of this study have confirmed our own empiric obser-

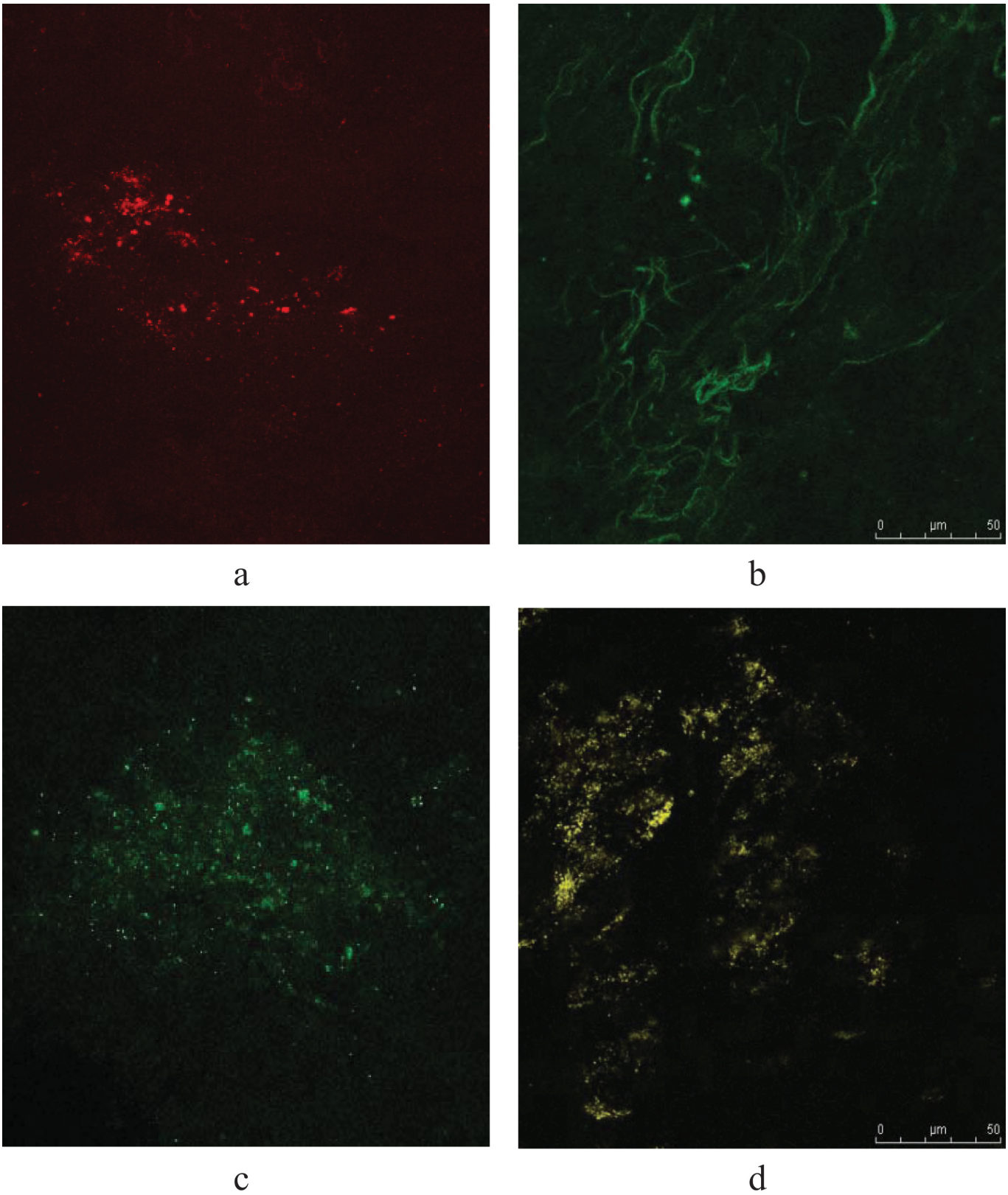

Figure 1. *(a)* Pseudomonas. aeruginosa *fluorescence in situ hybridization (FISH) probe tagged with Texas red, analyzed with confocal scanning laser microscopy at 20× magnification. Brightly fluorescing dots (representing bacteria) surrounded by a less intense exopolysaccharide blush (representing the matrix). Both components of the biofilm are easily differentiated from the surrounding tissue. (b) Universal fungal FISH probe tagged with Alexa 488 at 80× magnification. Characteristic densely matted hyphae irreversibly attached to the mucosal surface with surrounding exopolysaccharide substance forming a fungal biofilm. (c)* Staphylococcus aureus *FISH probe tagged with Alexa 488, analyzed with confocal scanning laser microscopy at 80× magnification. (d)* Haemophilus influenza *FISH probe tagged with Cy3 analyzed at 80× magnification.*

Table 3. **Distribution of species among single-species and multiple-species biofilms in the 36 biofilm positive chronic rhinosinusitis (CRS) patients. *S. aureus* is the most common biofilm-forming organism and over half the biofilm positive CRS patients have polymicrobial biofilms**

Species	Single Species (n = 17)	2 species biofilm (n = 15)	3 species biofilm (n = 4)	Total (n = 36)
S. aureus	9	13	3	25 (50%)
P. aeruginosa	1	5	3	11 (22%)
H. influenza	5	6	3	14 (28%)
Fungal	2	6	3	11 (22%)
Total biofilm organisms	17	30	12	59

vations about the importance of *S. aureus* in the pathogenesis of CRS and that from other CRS studies.[28,29] *S. aureus* was frequently seen in polymicrobial biofilm formation patterns. Seven of nine *P. aeruginosa* biofilm–positive patients also had *S. aureus* biofilms. This association has also been suggested by observations of biofilm-forming capacity of bacteria recovered from CRS patients.[30] *S. aureus* was also frequently seen colocalized with fungal biofilms (see later in text). The relative abundance of *S. aureus* biofilms is in contrast to previous studies that have used FISH to identify biofilms in CRS patients. Two studies from the same group have identified *H. influenza* as their most common biofilm-forming organism.[18,19] These studies found *H. influenza* biofilms in 14/18 (78%) and in 9/11 (81%) CRS patients. Interestingly, they also identified *H. influenza* biofilms in 2/5 and 3/3 control patients. The possible explanations for this difference include geographical as well as methodological differences (*i.e.*, specimen washing and preparation, probe design, microscopy technique, and biofilm definition).

Fungi are increasingly recognized as able to adopt a biofilm phenotype both on live and abiotic surfaces. Much of the work in fungal biofilm research has focused on *Candida* species involved in indwelling medical device infection.[31,32] Although vast ranges of fungal species are isolated from CRS patients, *Candida* species are rarely seen.[33] *A. fumigatus*, however, is a frequent sinonasal pathogen and is known to form biofilms on bronchial epithelium.[34] In models of *Candida* biofilms, yeast cells adhere to a live or inert surface and initially maintain a yeast-like morphological form. As the fungal biofilm matures, yeast-like growth is repressed and hyphal growth expands.[35] As the hyphae spread across the surface, an extracellular matrix is secreted and surrounds the fungal biofilm, thereby gluing the hyphae together.[36] The expanded hyphal growth and surrounding matrix can therefore be considered characteristic features of fungal biofilms.

Using these previous findings, we have confidently shown the characteristic morphology of fungal biofilms in 11/50 patients. The predominantly unidirectional orientation of the hyphae shown in Fig. 1 *b* is characteristic of fungal biofilm growth and is said to increase the strength of the biofilm.[36] The only other description of fungi and biofilms in rhinology-specific literature is by Healy *et al.*[18] They identified fungal elements associated with bacterial biofilms in 7/7 EM-CRS patients and 4/5 CRS patients. However, they note that the characteristic morphology of fungus (and therefore fungal biofilm) was not identified in any of their specimens. The difference between the reporting of these two studies may be merely definition. Certainly in the current study, we excluded any fungal elements that did not exist in the biofilm form previously described. Nevertheless, how fungi, either in robust biofilm form or otherwise, contribute to the pathogenesis of CRS remains unknown but certainly warrants further investigation.

An interesting finding of this study is the symbiosis of fungal and bacterial biofilms in CRS patients, predominantly *S. aureus*. This may represent a similar phenomenon to that described by Healy *et al.*[18] Of the 11 patients in whom we identified robust fungal biofilms, 7 also demonstrated *S. aureus* biofilms. Two patients had fungal–*H. influenza* biofilms present and the remaining two were solely fungal. This phenomenon is not new with mixed species bacterial–fungal biofilms previously reported in device-related infections[37,38] and specifically with *S. aureus* in atrophic denture stomatitis.[39] It has been suggested that the symbiotic interactions of bacterial and fungal cohabitation, such as that seen in our patients, augments biofilm survival by enhancing interspecies transfer of antimicrobial resistance traits, assisting surface adherence and improving the protection provided by the exopolysaccharide matrix.[40]

Finally, there has been some concern raised regarding the possibility of FISH probes binding nonspecifically to mast cell degranulation products in CRS patients. It is thought that these probed mast cell products may appear as clustered fluorescing areas of bacterial size and then be confused with bacterial biofilms. Although this may be a possibility, for a number of reasons we feel this is unlikely, given the results we have observed in our study. First, no control patients had areas of fluorescence suggesting biofilm or indeed mast cell products. However, given they are control patients, they may not have degranulated mast cells that typically accompany the inflammatory milieu of CRS. Equally, not all CRS patients may have mast cell activation and degranulation, therefore potentially explaining the negative results in a subset of CRS patients. However, in those CRS patients in whom mast cells were activated and had degranulated, we would expect these products to bind all probes applied to the same tissue. This was not the case in any patient and therefore we conclude this is indeed a true result with the areas of fluorescence representing bacteria within biofilms rather than host mast cell products.

CONCLUSION

This study is the largest of its kind and has used an FISH protocol combined with confocal scanning laser microscopy to show biofilms on the sinus mucosa of CRS patients. We have validated the cryopreservation of sinus mucosal tissue for delayed biofilm analysis. Our protocol has identified *S. aureus* as the most common biofilm-forming organism and highlighted the polymicrobial nature of this disease. We have also shown a symbiosis between *S. aureus* and fungi in CRS that may be relevant to unlocking the pathogenesis of this poorly understood disease. Fungal biofilms are poorly understood compared with their bacterial counterparts and represent an expanding area of research, both within otorhinolaryngology and the wider microbiological community. As we further our understanding of bacterial and fungal biofilms, so too our understanding of the etiopathogenesis of CRS will improve.

ACKNOWLEDGMENTS

The authors thank Dr. John Field for assistance with Cohen's κ-statistics.

REFERENCES

1. Slavin RG. Management of sinusitis. J Am Geriatr Soc 39:212–217, 1991.
2. Brook I. The role of bacteria in chronic rhinosinusitis. Otolaryngol Clin North Am 38:1171–1192, 2005.

3. Chiu AG. Osteitis in chronic rhinosinusitis. Otolaryngol Clini North Am 38:1237–1242, 2005.
4. Lanza DC, Dhong HJ, Tantilipikorn P, et al. Fungus and chronic rhinosinusitis: From bench to clinical understanding. Ann Otol Rhinol Laryngol 196:27–34, 2006.
5. Bachert C, Zhang N, Patou J, et al. Role of staphylococcal superantigens in upper airway disease. Curr Opin Allergy Clin Immunol 8:34–38, 2008.
6. Seiberling KA, Grammer L, and Kern RC. Chronic rhinosinusitis and superantigens. Otolaryngol Clinics North Am 38:1215–1236, 2005.
7. Ramadan HH, Sanclement JA, and Thomas JG. Chronic rhinosinusitis and biofilms. Otolaryngol Head Neck Surg 132:414–417, 2005.
8. Ferguson BJ, and Stolz DB. Demonstration of biofilm in human bacterial chronic rhinosinusitis. Am J Rhinol 19:452–457, 2005.
9. Palmer JN. Bacterial biofilms: Do they play a role in chronic sinusitis? Otolaryngol Clin North Am 38:1193–1201, 2005.
10. Hunsaker DH, and Leid JG. The relationship of biofilms to chronic rhinosinusitis. Curr Opin Otolaryngol Head Neck Surg 16:237–241, 2008.
11. Psaltis AJ, Ha KR, Beule AG, et al. Confocal scanning laser microscopy evidence of biofilms in patients with chronic rhinosinusitis. Laryngoscope 117:1302–1306, 2007.
12. Donlan RM, and Costerton JW. Biofilms: Survival mechanisms of clinically relevant microorganisms. Clin Microbiol Rev 15:167–193, 2002.
13. Costerton JW, Stewart PS, and Greenberg EP. Bacterial biofilms: A common cause of persistent infections. Science 284:1318–1322, 1999.
14. Ehrlich GD, Veeh R, Wang X, et al. Mucosal biofilm formation on middle-ear mucosa in the chinchilla model of otitis media. JAMA 287:1710–1715, 2002.
15. Chole RA, and Faddis BT. Anatomical evidence of microbial biofilms in tonsillar tissues: A possible mechanism to explain chronicity. Arch Otolaryngol Head Neck Surg 129:634–636, 2003.
16. Oxley KS, Thomas JG, and Ramadan HH. Effect of ototopical medications on tympanostomy tube biofilms. Laryngoscope 117:1819–1824, 2007.
17. Palmer J. Bacterial biofilms in chronic rhinosinusitis. Anns Otol Rhinol Laryngol 196:35–39, 2006.
18. Healy DY, Leid JG, Sanderson AR, and Hunsaker DH. Biofilms with fungi in chronic rhinosinusitis. Otolaryngol Head Neck Surg 138:641–647, 2008.
19. Sanderson AR, Leid JG, and Hunsaker D. Bacterial biofilms on the sinus mucosa of human subjects with chronic rhinosinusitis. Laryngoscope 116:1121–1126, 2006.
20. Benninger MS, Ferguson BJ, Hadley JA, et al. Adult chronic rhinosinusitis: Definitions, diagnosis, epidemiology, and pathophysiology. Otolaryngol Head Neck Surg 129:S1–S32, 2003.
21. Hogardt M, Trebesius K, Geiger AM, et al. Specific and rapid detection by fluorescent in situ hybridization of bacteria in clinical samples obtained from cystic fibrosis patients. J Clin Microbiol 38:818–825, 2000.
22. Landis JR, and Koch GG. The measurement of observer agreement for categorical data. Biometrics 33:159–174, 1977.
23. Cryer J, Schipor I, Perloff JR, and Palmer JN. Evidence of bacterial biofilms in human chronic sinusitis. ORL J Otorhinolaryngol Relat Spec 66:155–158, 2004.
24. Bendouah Z, Barbeau J, Hamad WA, and Desrosiers M. Biofilm formation by *Staphylococcus aureus* and *Pseudomonas aeruginosa* is associated with an unfavorable evolution after surgery for chronic sinusitis and nasal polyposis. Otolaryngol Head Neck Surg 134:991–996, 2006.
25. Psaltis AJ, Weitzel EK, Ha KR, and Wormald PJ. The effect of bacterial biofilms on post-sinus surgical outcomes. Am J Rhinol 22:1–6, 2008.
26. Basu S, Georgalas C, Kumar BN, and Desai S. Correlation between symptoms and radiological findings in patients with chronic rhinosinusitis: An evaluation study using the Sinonasal Assessment Questionnaire and Lund-Mackay grading system. Eur Arch Otorhinolaryngol 262:751–754, 2005.
27. Stewart MG, and Johnson RF. Chronic sinusitis: Symptoms versus CT scan findings. Curr Opin Otolaryngol Head Neck Surg 12:27–29, 2004.
28. Niederfuhr A, Kirsche H, Deutschle T, et al. *Staphylococcus aureus* in nasal lavage and biopsy of patients with chronic rhinosinusitis. Allergy 63:1359–1367, 2008.
29. Videler WJ, van Drunen CM, Reitsma JB, and Fokkens WJ. Nebulized bacitracin/colimycin: A treatment option in recalcitrant chronic rhinosinusitis with *Staphylococcus aureus*? A double-blind, randomized, placebo-controlled, cross-over pilot study. Rhinology 46:92–98, 2008.
30. Prince AA, Steiger JD, Khalid AN, et al. Prevalence of biofilm-forming bacteria in chronic rhinosinusitis. Am J Rhinol 22:239–245, 2008.
31. Kojic EM, and Darouiche RO. Candida infections of medical devices. Clin Microbiol Rev 17:255–267, 2004.
32. Ramage G, Martinez JP, and Lopez-Ribot JL. *Candida* biofilms on implanted biomaterials: A clinically significant problem. FEMS Yeast Res 6:979–986, 2006.
33. Collins MM, Nair SB, and Wormald PJ. Prevalence of noninvasive fungal sinusitis in South Australia. Am J Rhinol 17:127–132, 2003.
34. Seidler MJ, Salvenmoser S, and Muller FM. *Aspergillus fumigatus* forms biofilms with reduced antifungal drug susceptibility on bronchial epithelial cells. Antimicrob Agents Chemother 52:4130–4136, 2008.
35. Blankenship JR, and Mitchell AP. How to build a biofilm: A fungal perspective. Curr Opin Microbiol 9:588–594, 2006.
36. Beauvais A, Schmidt C, Guadagnini S, et al. An extracellular matrix glues together the aerial-grown hyphae of *Aspergillus fumigatus*. Cell Microbiol 9:1588–1600, 2007.
37. Marrie TJ, and Costerton JW. Scanning and transmission electron microscopy of in situ bacterial colonization of intravenous and intraarterial catheters. J Clin Microbiol 19:687–693, 1984.
38. Crump JA, and Collignon PJ. Intravascular catheter-associated infections. Eur J Clin Microbiol Infect Dis 19:1–8, 2000.
39. Baena-Monroy T, Moreno-Maldonado V, Franco-Martinez F, et al. *Candida albicans*, *Staphylococcus aureus*, and *Streptococcus mutans* colonization in patients wearing dental prosthesis. Med Oral Patol Oral Cir Bucal 10(suppl 1):E27–E39, 2005.
40. Lynch AS, and Robertson GT. Bacterial and fungal biofilm infections. Annu Rev Med 59:415–428, 2008. □

Reproduced with permission of the copyright owner. Further reproduction prohibited without permission.