Effect of diethylcarbamazine citrate and omega-3 fatty acids on trimellitic anhydride-induced rat skin allergy

Mahmoud Abdel Latif, Manal Abdul-Hamid and Sanaa R. Galaly

Summary

Background: **Diethylcarbamazine citrate (DEC) is the drug most widely used in the treatment of lymphatic filariasis. Omega-3 fatty acids (ω -3 FAs) are essential polyunsaturated fatty acids and commonly found in marine oils. Both have been applied in treatment of inflammatory diseases but anti-allergic effects should be investigated.**

Objective: **The present study was performed to test the effect of both DEC and ω -3 FAs on Trimellitic anhydride (TMA) - induced rat skin allergy.**

Methods: **In vivo experiment was executed in white albino rats using 100 and 600 mg/ Kg body weight of DEC and ω-3 FAs, respectively in treatment. Ear thickness of sensitized rats to TMA was monitored after challenge. Blood eosinophilia was determined using differential leukocyte count while the appearance of mast cells, eosinophils and collagen fibers in skin tissue were investigated using specific stains. Colorimetric assay of NO was performed in homogenized ears, while expression of inducible nitric oxide synthase (iNOS) was detected using immunohistochemistry.**

Results: **Ear thickness showed a significant ($p < 0.05$) reduction in both of DEC and ω-3 FAs-treated groups. Blood eosinophilia and skin eosinophils were significantly ($p < 0.001$) decreased by DEC and ω-3 FAs, while the decrease of skin mast cells was only significant ($p < 0.01$) when ω-3 FAs applied. The expression of iNOS and intensity of stained collagen fibers were decreased obviously by ω-3 FAs but less by DEC treatment. Histopathological observations were more normal in ω-3 FAs than DEC treated groups.**

Conclusion: **ω-3 FAs was more potent anti-allergic substance against TMA-induced dermatitis than DEC.** ***(Asian Pac J Allergy Immunol 2015;33:33-41)***

Keywords: *diethylcarbmazine citrate, trimellitic anhydride, omega-3 fatty acids, skin allergy, skin histopathology*

Introduction

TMA, an acid anhydride widely used in the plastics industry, was successful to induce skin allergy in mice and rats through accumulation of eosinophils, mast cells and T cells.[1,2] The skin, the largest organ of the human body, plays a critical role in the development of allergic diseases, such as atopic dermatitis. The epidermis also contains keratinocytes and Langerhans cells, a major dendritic cell of the skin that can acquire antigen.[3]

DEC is the drug most widely used in the treatment of lymphatic filariasis since 1947.[4] DEC also has anti-inflammatory properties as a result of its interference with the arachidonic acid metabolism, which includes lipoxygenase and cyclooxygenase enzymes.[5] It was demonstrated that DEC has important role in blocking the pulmonary eosinophilic inflammation in mice sensitized with ovalbumin.[6] Nevertheless, the tropical application of DEC on *Onchocerca*-induced dermatitis could recruit large numbers of eosinophils and increase the expression of eotaxin.[7]

The fish oil is rich in ω -3 FAs, specifically eicosapentaenoic acid (EPA) and docosahexaenoic acid (DHA), could help to minimize the postshock inflammatory responses. These fatty acids have been reported to modulate inflammation and have been used clinically for that purpose.[8] These fatty acids have been already used for treatment of children atopic dermatitis because the metabolization of EPA and DHA could lead to dampening of skin inflammation.[9]

From Department of Zoology, Faculty of Science, Beni-Suef University, Egypt.
Corresponding author: Mahmoud Abdel Latif
E-mail: mahmoud_1232000@yahoo.com
Submitted date: 8/4/2014
Accepted date: 16/7/2014

Downloaded from http://apjai.digitaljournals.org. For personal use only. No other uses without permission.

In the current study, DEC and ω -3 FAs have been used to test their effects on TMA- induced skin allergy in albino white rat. The results indicated a more potent suppressing effect of ω-3 FAs than DEC.

Methods

Animals and Experimental Design

Twenty five female albino rats, weighing approximately 180–200 gm, were housed in an air-conditioned room with a 12 h light/dark cycle. They were allowed free access to food and tap water. Rat sensitization, challenges with TMA and treatment were performed as previously described.[2] For the induction of skin hypersensitivity, rats were divided into five groups (5 each): control, TMA, DEC, ω-3 FAs and prednisolone (Pred) groups. All animal experiments were approved in accordance with the guidelines of the Beni-Suef University Laboratory Animal Management Committee.

Induction of allergic skin inflammation

Rats were sensitized with 50 µL of 5% TMA in solvent on shaved flank skin on day 0. Challenges with 10 µL of 5%TMA in solvent (acetone) on the dorsum of both ears were performed on day 5. Animals received challenges on the ears with 10 µL of 2% TMA in solvent on days 6-15. A solvent control group was exposed to acetone throughout the duration of the experiment. In the treatment groups, DEC (100 mg/kg B.W.), ω-3 FAs (0.6 g/ Kg B.W.) and Pred (positive control; 30 mg/kg B.W.) were administered orally 1 h before the challenges. Each of these doses was chosen according to previous reports and performed on days 9-15.[2,12,13] Ear thickness during the time course was determined with a custom-built micrometer (Schering AG, Germany).

At the end of the experiment, blood was taken and rats were killed by cervical dislocation. Three blood smears were made for each of the animals and allowed to air-dry. All slides were later stained with Wright's stain. A single blood smear was evaluated via light microscopy (Nikon Optiphod Transmitted Light Microscope) for each of five animals within the five groups under study. The purpose of the evaluation was to quantify each cell of the leukocyte species; namely lymphocytes, monocytes, neutrophils, basophils and eosinophils; counting up to one hundred leukocytes per slide in a total of three zones.

Ears were excised, minced and mechanically homogenized in phosphate buffer saline (pH 7.2) as 200 mg /ml, centrifuged at 25,000 *g* for 30 min at 4°C.

Nitrite assay

Nitrite concentration in the ear tissue homogenates was assayed by the Griess reaction.[11] Nitrite concentration was calculated with reference to a standard curve obtained using $NaNO_2$. Mean ± SD was calculated from four independent experiments.

Histological preparation and histochemical staining

Ear tissues were taken from different groups and fixed in 10% neutral buffer formalin for 24 hours, washed in tap water, dehydrated in serial dilutions of ethyl alcohol, cleared in xylene and embedded in paraffin. Tissue blocks were prepared for sectioning at 4 µm thicknesses by microtome, collected on glass slides, deparaffinized, stained by hematoxylin &eosin stain for routine examination then examination was done through the light electric microscope for histopathological studies.

Masson's trichrome was also used for demonstration of collagen fibers.[14] For mast cell detection, acidified toluidine blue (TB) staining was used to observe the occurrence of mast cells, their distribution and degranulation.[15] Carbol Chromotrope 2R (Sigma, St. Louis, USA)was used previously to identify eosinophils.[16] The mast cells and eosinophils of skin dermal region were counted per 10 high power fields (HPF) according to the classical method described.[17]

Immunohistochemistry using streptavidin biotin immunoperoxidase detection

The ear sections were processed for iNOS detection as previously described.[18] Rabbit anti-rat iNOS primary antibody was purchased from PharMingen (San Diego, CA), while biotinylated goat anti-rabbit antibody was purchased from Serotec (Oxford, UK).

Statistical analysis

Data were expressed as mean ± SEM for each group. One-way ANOVA with post hoc Dunnett's tests was used to test for significant difference between the rat groups. Analysis was performed by the usage of IBM SPSS statistics (Version 20, New York, USA).

Downloaded from http://apjai.digitaljournals.org. For personal use only. No other uses without permission.

Results

Effect of DEC and ω-3 FAs on TMA-induced increase in ear thickness

DEC and ω-3 FAs decreased ear thickness significantly ($p < 0.05$) at day 15 post challenge with TMA (Figure 1). The positive control group indicated an obvious decrease ($p < 0.01$) compared to TMA group. The difference in thickness between the tested treatments and TMA started at day 12, while the difference between the positive control and TMA groups started at day 10.

Histopathological observations

There was normal histological appearance of ear epidermis and dermis in control group (Figure 2a). In TMA treated group, focal haemorrhage was noticed with inflammatory cell infiltration in the dermal as well as in the musculature (Figure 2c), while the deep layer of the dermis showed perivascular infiltration with inflammatory cells surrounding the severe dilated and congested blood vessels (Figure 2d). The epidermal layers were disorganized with deeply stained pyknotic nuclei while some keratinocytes appeared shrunken with widening of intercellular spaces and proliferative response (Figure 2e). In prednisolone-treated group which served as a positive control, histological structures of skin appeared normal (Figure 2b). In ω-3 FAs group, most of the epidermal cells revealed their normal appearance with mild congestion in the blood vessels of the dermal layer (Figure 2f). DEC revealed normal appearance for the epidermal cells, while the subcutaneous adipose tissue showed less inflammatory cell infiltration (Figure 2g).

Effect of DEC and ω-3 FAs on TMA-induced eosinophil and mast cells accumulation

Induction of allergic skin using TMA could lead to an increase in blood eosinophilia (Figure 3a). DEC and ω-3 FAs could show a significant decrease ($p < 0.001$) compared to TMA group. Treatment with DEC and ω-3 FAs could significantly ($p < 0.001$) reduce the TMA- induced accumulation of eosinophils in skin tissue (Figure 3b). Specific staining with chromotrope 2R indicated increased number of the cells in TMA group (Figure 3e) compared to control (Figure 3c). The cells were decreased after treatment with ω-3 FAs and DEC (Figure 3 f,g). Mast cells were identified by their purple-colored cytoplasmic granules and their oval or round nucleus. Only the treatment with ω-3 FAs could significantly ($p < 0.01$) decrease the infiltrated mast cells (Figure 4a). Staining with TB could show an increased number and intensely stained mast cells in the dermis of TMA (Figure 4d) compared to the

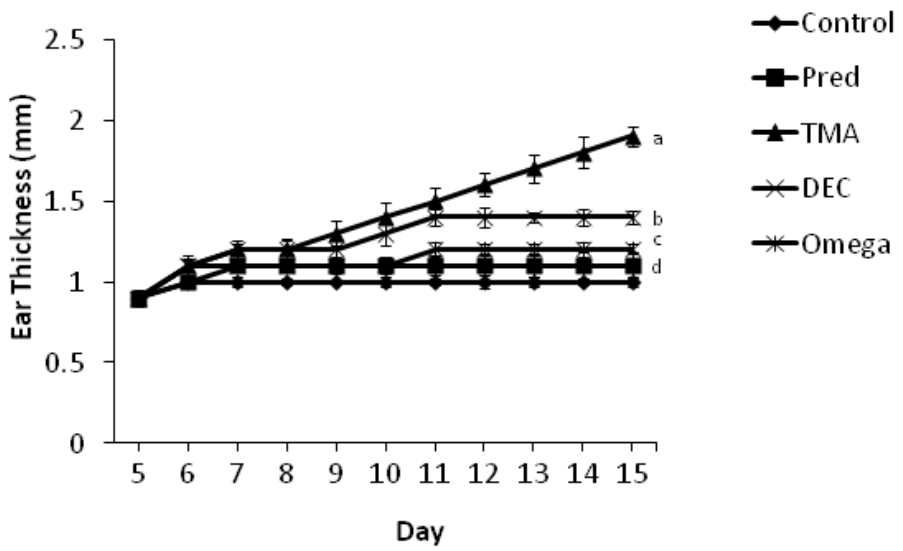

Figure 1. Effect of DEC and ω-3 FAs on the ear thickness of TMA- challenged rat group after day 5. DEC, ω-3 FAs and Pred treatments indicated significant decrease on day 15. Data are shown as the mean ± SD. Statistical difference between a and either b or c is $p < 0.05$ while a and d was $p < 0.01$.

Downloaded from http://apjai.digitaljournals.org. For personal use only. No other uses without permission.

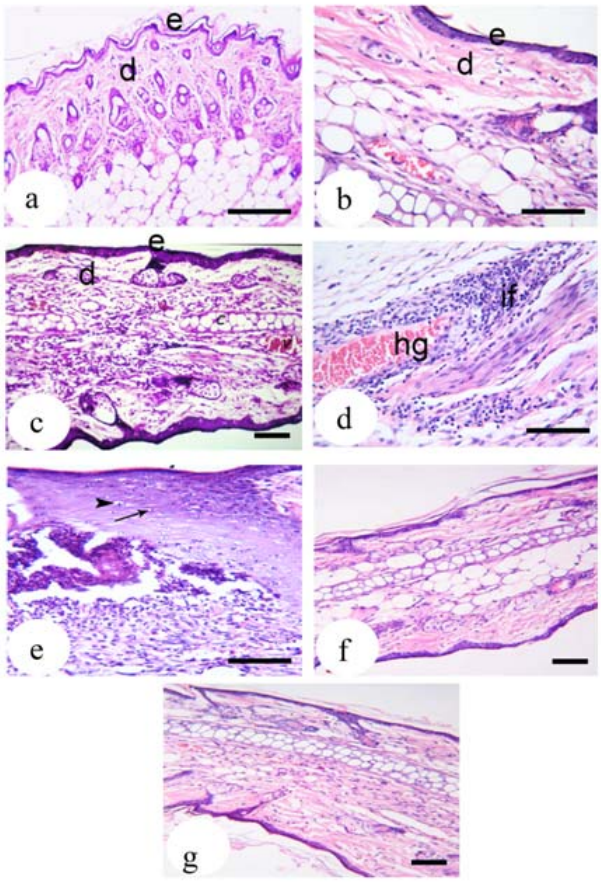

Figure 2. Histopathology of the rat ear sections stained with haematoxlin and eosin showing alterations in TMA group (c, d and e) compared to normal (a) and positive control (b) groups. These alterations were decreased after treatment by ω-3 FAs (f) and DEC (g), although focal inflammatory cells were still present in the later group. epidermis (e), dermis (d), focal haemorrhage of blood vessel (hg), focal inflammatory cells infiltration (if). The epidermal layers were disorganized with deeply stained pyknotic nuclei (arrow) while some keratinocytes appeared shrunken with widening of intercellular spaces (arrow head). Scale bar represents 5μm.

control group which showed few and slightly stained cells (Figure 4b). Treatment with either ω-3 FAs or DEC revealed less number and slightly stained mast cells in the dermis (Figure 4e, f). In the positive control group, eosinophils and mast cells did not appear in the skin tissue (Figure 3d and 4c, respectively).

Effect of DEC and ω-3 FAs on TMA-induced NO production and increased collagen fibers in the ear skin

Neither DEC nor ω-3 FAs did show a significant decreasing effect on the content of NO in skin tissue homogenates (Figure 5a), while the positive control group (Pred) did show a significant ($p < 0.05$) decreasing effect. Immunohistochemical staining for iNOS in TMA group revealed an increased reaction in the form of fine brown granules (Figure 5d) compared to weak reactions in the control groups (Figure 5b, c). Treatment with ω-3 FAs revealed a decreased expression of iNOS (Figure 5e), while DEC treatment indicated less obviously decreased expression (Figure 5f).

In control group, blue-stained collagen fibers showed a normal appearance and arrangement. Below the basal lamina, collagen fiber aggregates were seen. They appeared as a network of more abundant and thick irregular bundles in the dermal layer (Figure 6a). In TMA group, the content of collagen fibers increased and appeared as irregularly arranged dense bundles in both papillary and reticular layers of the dermis and around the hair follicles (Figure 6c). Treatment with prednisolone and ω-3 FAs showed normal contents of collagen fibers (Figure 6b and d), while DEC treatment showed less normal appearance (Figure 6e).

Discussion

Inflammatory responses induced by TMA were evident by infiltration of the immune cells. In addition, the epidermal thickening was attributed to the TMA-induced proliferative response in the keratinocytes. This has also been observed using the mouse as a model.[2] DEC was less capable of reducing cell infiltration in skin tissue than ω-3 FAs. The mechanism of action for both DEC and ω-3 FAs on skin may be referred to the effective inhibition for lipoxygenase pathway and generation of regulatory T cells, respectively.[5,19] In addition, the effect of ω-3 FAs to reverse skin histopathological alterations was compatible with previous reports about the need for essential fatty acids to improve cutaneous health.[20]

In this study, we investigated if both DEC and ω-3 FAs could have a significant effect on allergic responses induced by TMA challenge in rat skin. From the results, it was apparent that both of DEC and ω-3 FAs could have a significantly depressing effect on blood and skin eosinophil count. This has also been observed previously in asthmatic children

Downloaded from http://apjai.digitaljournals.org. For personal use only. No other uses without permission.

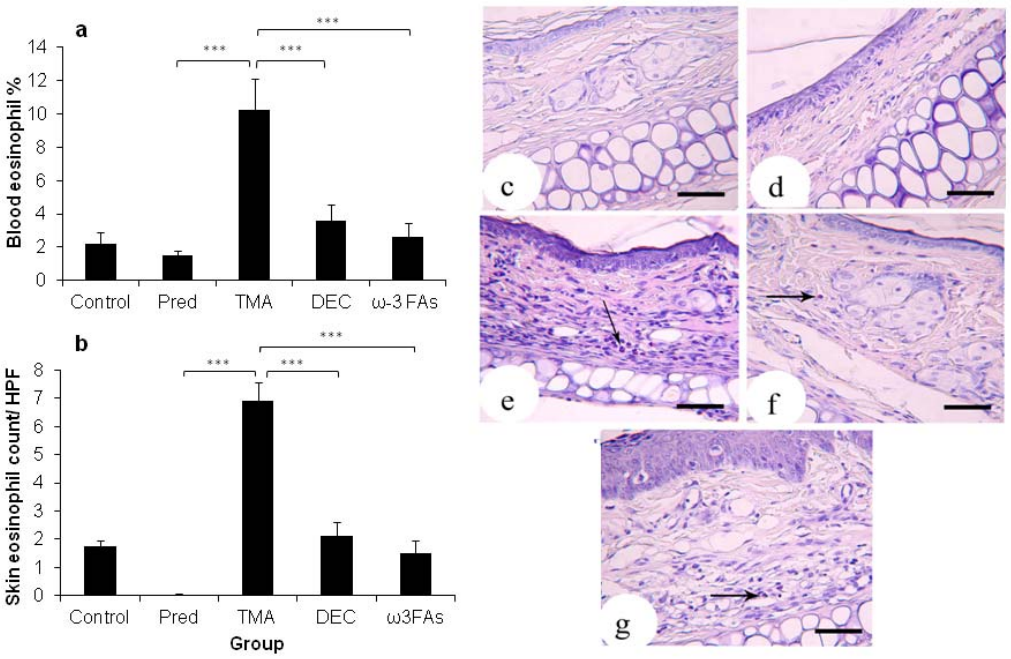

Figure 3. Effect of DEC and ω-3 FAs on TMA-induced increase of blood eosinophilia and eosinophil infiltration in the ear. Data represent mean ± SEM of five rats where a highly significant ($p < 0.001$; ***) decrease was observed after Pred, DEC and ω-3 FAs treatments compared to TMA group (a and b). Sections stained with chromotrope 2R demonstrated increased infiltration in TMA group (e) compared to normal (c) and positive (d) controls while ω-3 FAs (f) and DEC (g) showed decreased occurrence. Scale bar represents 5μm.

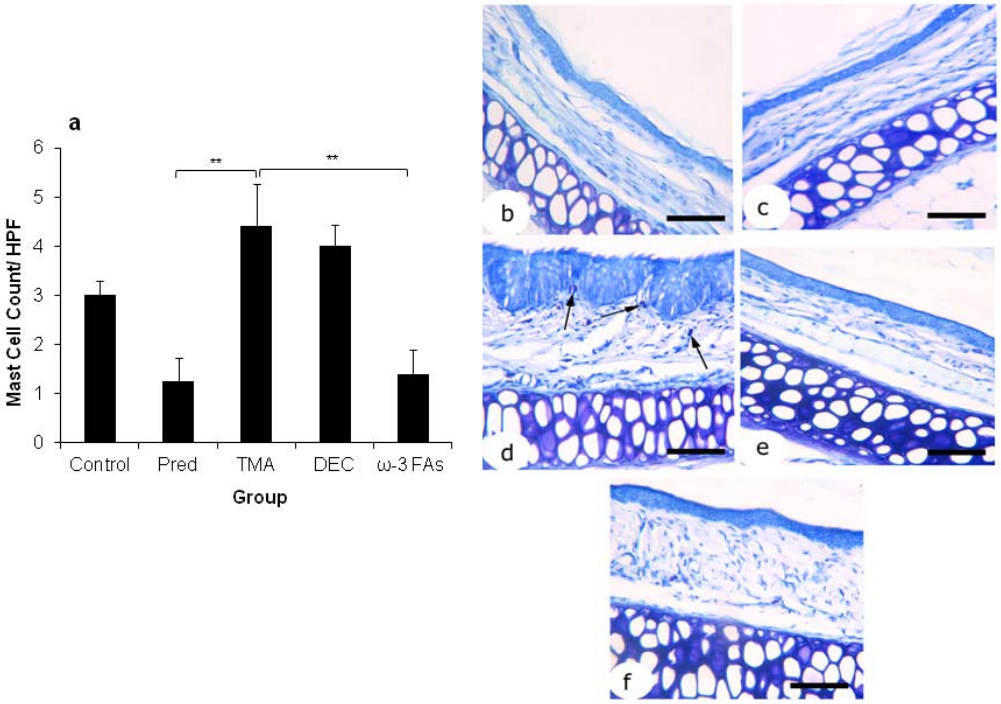

Figure 4. Effect of DEC and ω-3 FAs on TMA-induced increase of mast cell infiltration in the ear tissue. Data represent mean ± SEM of five rats where a significant ($p < 0.01$; **) decrease was observed after Pred and ω-3 FAs treatments compared to TMA group (a). Sections stained with TB demonstrated increased infiltration and intensely stained mast cells in TMA group (d) compared to normal (b) and positive (c) controls, while treatment with either ω-3 FAs or DEC revealed less and slightly stained mast cells in the dermis (e and f, respectively). Scale bar represents 5μm.

Downloaded from http://apjai.digitaljournals.org. For personal use only. No other uses without permission.

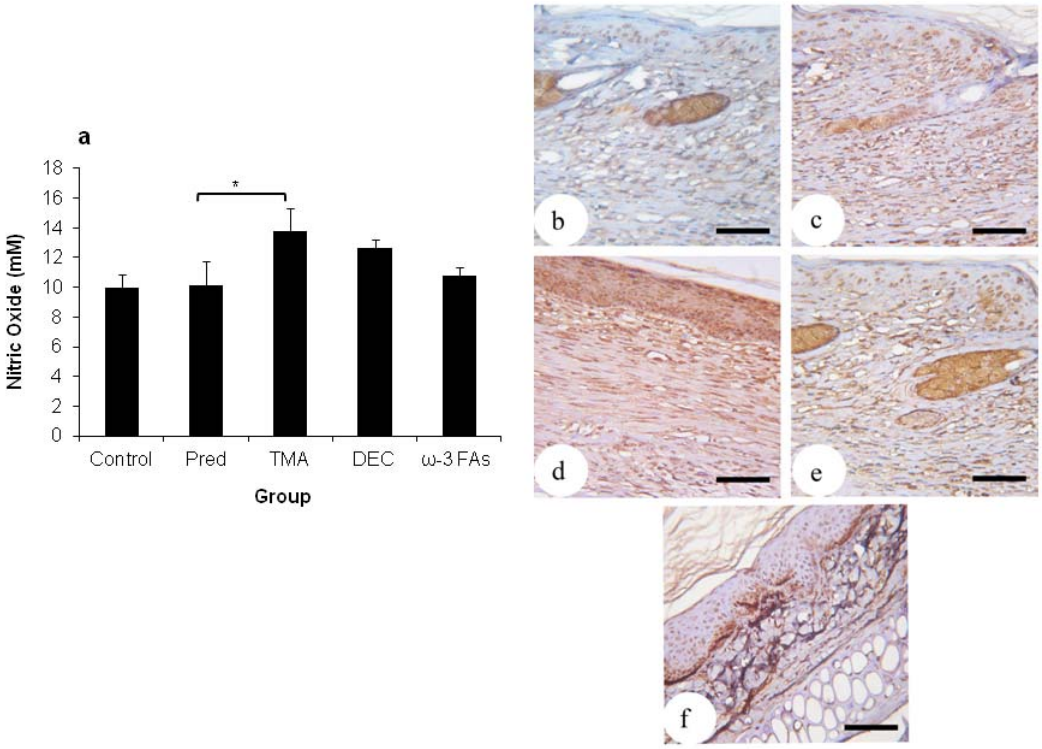

Figure 5. Effect of DEC and ω-3 FAs on TMA-induced increase of NO production in the ear tissue. Data represent mean ± SEM of five rats where a significant ($p < 0.05$; *) decrease was observed after Pred treatment compared to TMA group (a). Immunohistochemical staining for iNOS show increased reaction in the form of fine brown granules in TMA group (d) compared to normal and positive control groups (b and c). Treatment with ω-3 FAs and DEC revealed a less decrease in iNOS expression (e and f). Scale bar represents 5μm.

blood.[21] Omega-3 FAs were shown to increase apoptosis and decrease the eotaxin chemotactic effect in eosinophils.[22] DEC was found to have a suppressing effect on bone marrow eosinophil lineage, pulmonary eosinophil accumulation and IL-5-dependent eosinophilopoiesis.[6] DEC was also effective in inhibition of chronic hepatic inflammation induced by alcohol in mice.[23]

Only treatment with ω-3 FAs was able to significantly decrease the number of mast cells compared to DEC. The decrease in purple color intensity in both of ω-3 FAs and DEC was attributed to decreased content of cytoblasmic granules and cell activity.[24] This may be related to the ability of both DEC and ω-3 FAs to change the content of cell fatty acids (including arachidonic acid) which are responsible for the release of inflammatory mediators.[25,26] In mouse model of allergic skin induced by 2,4-dinitrofluorobenzene, ω-3 FAs derived mediator could reduce many of inflammatory responses like accumulation of mast cells, eosinophils and T cells in skin lesions.[27] In mammary tumor tissues, ω- 3 FAs were found previously to decrease the mast cell infiltration.[28] This has been attributed to the suppressing effect of ω-3 FAs on Th2 cytokines by inhibiting of GATAs which are essential transcription factors for mast cell activation.[29] Treatment of human onchocerciasis by DEC could increase the mast cell infiltration and degranulation only after 1.5 hr posttreatment.[30] This may interpret the non-significant decrease of mast cell infiltration by DEC in our study. Increased content of densely arranged thick collagen fibers in the dermis of TMA-treated rats was associated with the increased numbers of mast cells. This can be explained by the fact that mast cells can affect the fibroblast functional behavior and, consequently, the fibrosis process, by releasing pre-formed mediators– such as histamine, proteoglycans, proteolytic enzymes and cytokines.[31] In addition, the density degree of stained fibers in both of ω-3 FAs and

Downloaded from http://apjai.digitaljournals.org. For personal use only. No other uses without permission.

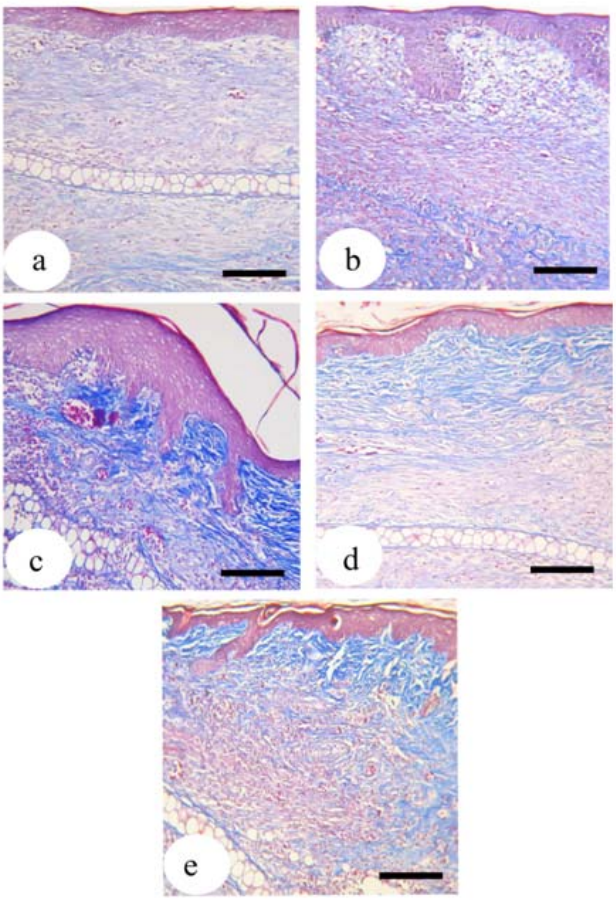

Figure 6. Intensity distribution of collagen fibers in rat ear tissue stained with Masson's trichrome. More condensed fibers were observed in TMA group (c) than normal and positive control groups (a and b). Treatment with ω-3 FAs showed normal contents of collagen fibers (e), while DEC treatment showed less normal collagen fibers (f). Scale bar represents 5μm.

DEC-treated groups were coincident with the observed mast cell numbers.

Monitoring of the ear thickness after TMA challenge indicated a decrease in positive control as well as treatment groups. The data of ear thickness represent strong evidence for the suppressing effect of DEC and ω-3 FAs on skin allergy with observable higher effectivity for the later. These data of ear thickness were compatible with those of infiltrated cells, however, ω-3 FAs did not reduce calve ear thickness in response to phytohemagglutinin-P.[32] DEC and ω-3 FAs decreased the levels of NO in skin, however, this effect was not significantly different compared to TMA group. In consistence, previous study on the effect of these fatty acids at lower concentrations on NO production from rat neutrophils did not show a significant effect.[33] DEC was previously shown to decrease the NO production due to its inhibitory effect on arachidonic acid metabolites which participate in NO production.[34] A significant and protective role of ω-3 FAs against NO sources like L-arginine and sodium nitroprusside were previously indicated.[35] In the current study, the non-significant effect of DEC and ω-3 FAs on NO in allergic skin may be referred to the different organ used and not other previously investigated tissues. In addition, higher concentrations might be needed to show a significant decrease. Investigation for expression of iNOS which is a precursor for NO synthesis revealed a decrease in immunostaining after treatment by both ω-3 FAs and DEC. However, the presence of stained foci in both sections may interpretate the non-significant effect in nitrite assay. This has also been observed in decreased mRNA expression of iNOS in rat liver after pre-feeding with ω-3 FAs.[13] The slight appearance of thick collagen fibers in DEC group and its disappearance in ω-3 FAs treated group was related to the expression of iNOS in the skin tissue as previously described.[36] Dermal fibroblasts were found to produce NO as a result of stimulation with allergic metals.[37] NO has been identified as a modulator for mouse skin allergy because injection of its inhibitor could reduce the severity of contact hypersensitivity reaction.[38] The application of different allergens including TMA and 2,4-dinitrochlorobenzene indicated the increase in NO production from Langerhans cell and keratinocytes.[39, 40] The precise mode of action for NO in allergic reaction is still not clear but its increase is coincident with elevated allergic responses.

In conclusion, DEC was less effective than ω-3 FAs to reduce the TMA- induced allergy in the skin. This was apparent since DEC was not able to reduce NO production or mast cell infiltration in the skin. In addition, the histopathological investigation in the skin revealed still accumulated cells. However, DEC was effective to reduce blood and skin eosinophilia. Although DEC is effective inhibitor for arachidonic acid metabolism and suppressant for eosinophilopoiesis, its application in human allergic diseases is not advisable when compared to ω-3 FAs.

Downloaded from http://apjai.digitaljournals.org. For personal use only. No other uses without permission.

Acknowledgments

The authors are grateful for pathology departments of Faculty of Veterinary Medicine, Beni-Suef University and National Cancer Center, Cairo University for great help in taking photos for the stained tissue sections.

References

1. Andius P, Arakawa H, Mölne J, Pullerits T, Skoogh BE, Lötvall J. Inflammatory responses in skin and airways after allergen challenge in brown Norway rats sensitized to trimellitic anhydride. Allergy 1996;51:556-62.
2. Bae MJ, Shin HS, Choi DW, Shon DH. Antiallergic effect of Trigonella foenum-graecum L. extracts on allergic skin inflammation induced by trimellitic anhydride in BALB/c mice. J Ethnopharmacol. 2012;144:514–22.
3. Callard RE, Harper JI. The skin barrier, atopic dermatitis and allergy: a role for Langerhans cells?. Trends Immunol. 2007;28:294–8.
4. Hewitt RIS, Kushner HW, Stewart E, White WS, Wallace Y. Experimental chemotherapy of filariasis III. Effect of 1-diethylcarbamazine-4- methylpiperazine hydrochloride against naturally acquired filarial infections in cotton rats and dogs. J Lab Clin Med. 1947;32:1314–29.
5. Maizels RM, Denham DA. Diethylcarbamazine (DEC): immunopharmacological interactions of an anti-filarial drug. Parasitol. 1992;105:849–60.
6. Queto T, Xavier P, Gardel MA, Luca B, Barradas M, Masid D, et al. Inducible nitric oxide synthase/CD95L-dependent suppression of pulmonary and bone marrow eosinophilia by Diethylcarbamazine. Am J Respir Crit Care Med. 2010;181:429–37.
7. Pearlman E, Toé L, Boatin BA, Gilles AA, Higgins AW, Unnasch TR. Eotaxin expression in Onchocerca volvulus-induced dermatitis after topical application of diethylcarbamazine. J Infect Dis. 1999;180:1394-7.
8. Novak TE, Babcock TA, Jho DH, Helton WS, Espat NJ. NF-kappa B inhibition by omega-3 fatty acids modulates LPS-stimulated macrophage TNF-alpha transcription. Am J Physiol Lung Cell Mol Physiol. 2003;284:L84-9.
9. Rahman M, Beg S, Ahmad MZ, Kazmi I, Ahmed A, Rahman Z, et al. Omega-3 fatty acids as pharmacotherapeutics in psoriasis: current status and scope of nanomedicine in its effective delivery. Curr Drug Targets. 2013;14:708-722.
10. Leiro JM, Alvarez E, Arranz JA, Siso IG, Orallo F. In vitro effects of mangiferin on superoxide concentrations and expression of the inducible nitric oxide synthase, tumour necrosis factor-alpha and transforming growth factor-beta genes. Biochem Pharmacol. 2003; 65:1361-71.
11. Green LC, Wagner DA, Glogowski J, Skipper PL, Wishnok JS, Tannenbaum SR. Analysis of nitrate, nitrite and [15N] nitrate in biological fluids. Anal Biochem. 1982;126:131-8.
12. Mitsui Y, Takamura N, Fujimaki Y, Yamaguchi T, Kitagawa T, Aoki Y. Development of a competitive enzyme-linked immunosorbent assay for diethylcarbamazine. Trop Med Int Health. 1996;1:528-34.
13. Yang R, Harris WS, Vernon K, Thomas AM, Qureshi N, Morrison DC, et al. Prefeeding with ω-3 fatty acids suppresses inflammation following hemorrhagic shock. JPEN J Parenter Enteral Nutr. 2010;34:496-502.
14. Banchroft JD, Stevens A. Theory and practice of histolological techniques. 4th ed. Churchil Livingstone, Edinburg. 1996; p. 148.
15. Rezzani R, Rodella L, Tartaglia GM, Paganelli C, Sapelli P, Bianchi R. Mast cells and the inflammatory response to different implanted biomaterials. Arch Histol Cytol. 2004;67:211–7.
16. Morse B, Sypek JP, Donaldson DD, Haley KJ, Lilly CM. Effects of IL-13 on airway responses in the guinea pig. Am J Physiol Lung Cell Mol Physiol. 2002;282:L44-49.
17. Alkhabuli JO, High AS. Significance of eosinophil counting in tumor associated tissue eosinophilia (TATE). Oral Oncol. 2006;42:849-50.
18. Greenacre SA1, Rocha FA, Rawlingson A, Meinerikandathevan S, Poston RN, Ruiz E, et al.. Protein nitration in cutaneous inflammation in the rat: essential role of inducible nitric oxide synthase and polymorphonuclear leukocytes. Br J Pharmacol. 2002;136:985-94.
19. Han SC, Kang GJ, Ko YJ, Kang HK, Moon SW, Ann YS, et al. Fermented fish oil suppresses T helper 1/2 cell response in a mouse model of atopic dermatitis via generation of CD4+CD25+Foxp3+ T cells. BMC Immunol. 2012;13:44.
20. Nicolaou A. Eicosanoids in skin inflammation. Prostaglandins Leukot Essent Fatty Acids. 2013;88:131-8.
21. Hodge L, Salome CM, Hughes JM, Liu-Brennan D, Rimmer J, Allman M, et al. Effect of dietary intake of omega-3 and omega-6 fatty acids on severity of asthma in children. Eur Respir J. 1998;11:361-5.
22. Tanigai T, Ueki S, Kihara J, Kamada R, Yamauchi Y, Sokal A, et al. Docosahexaenoic acid exerts anti-inflammatory action on human eosinophils through peroxisome proliferator-activated receptor-independent mechanisms. Int Arch Allergy Immunol. 2012;158:375-86.
23. Santos Rocha SW, Silva BS, Gomes FO, Soares e Silva AK, Raposo C, Barbosa KP, et al. Effect of diethylcarbamazine on chronic hepatic inflammation induced by alcohol in C57BL/6 mice. Eur J Pharmacol. 2012;689:194-203.
24. Menétrey D, Dubayle D. A one-step dual-labeling method for antigen detection in mast cells. Histochem Cell Biol. 2003;120:435-342.
25. Calder PC. Omega-3 fatty acids and inflammatory processes. Nutrients 2010;2:355-74.
26. Peters SP, Jr MacGlashan DW, Schleimer RP, Hayes EC, Jr Adkinson NF, Lichtenstein LM. The pharmacologic modulation of the release of arachidonic acid metabolites from purified human lung mast cells. Am Rev Respir Dis. 1985;132:367-73.

Downloaded from http://apjai.digitaljournals.org. For personal use only. No other uses without permission.

27. Kim TH, Kim GD, Jin YH, Park YS, Park CS. Omega-3 fatty acid-derived mediator, Resolvin E1, ameliorates 2, 4-dinitrofluorobenzene-induced atopic dermatitis in NC/Nga mice. Int Immunopharmacol. 2012;14:384-91.
28. Mukutmoni-Norris M, Hubbard NE, Erickson KL. Modulation of murine mammary tumor vasculature by dietary n-3 fatty acids in fish oil. Cancer Lett. 2000;150:101-9.
29. Park BK, Park S, Park JB, Park MC, Min TS, Jin M. Omega-3 fatty acids suppress Th2-associated cytokine gene expressions and GATA transcription factors in mast cells. J Nutr Biochem. 2013;24:868-76.
30. Ackerman SJ, Kephart GM, Francis H, Awadzi K, Gleich GJ, Ottesen EA. Eosinophil degranulation. An immunologic determinant in the pathogenesis of the Mazzotti reaction in human onchocerciasis. J Immunol. 1990;144:3961-9.
31. Kupietzky A, Levi-Schaffer F. The role of mast cell derived histamine in the closure of an in vitro wound. Inflamm Res. 1996;45:176-80.
32. Ballou MA1, DePeters EJ.Supplementing milk replacer with omega-3 fatty acids from fish oil on immunocompetence and health of Jersey calves. J Dairy Sci. 2008; 91:3488-500.
33. Paschoal VA, Vinolo MA, Crisma AR, Magdalon J, Curi R. Eicosapentaenoic (EPA) and docosahexaenoic (DHA) acid differentially modulate rat neutrophil function in vitro. Lipids 2013;48:93-103.
34. Espinoza E, Pérez-Arellano JL, Vicente B, Muro A. Cytoplasmic signalling pathways in alveolar macrophages involved in the production of nitric oxide after stimulation with excretory/secretory antigens of Toxocara canis. Parasite Immunol. 2002;24:535-44.
35. Khan MW, Priyamvada S, Khan SA, Khan S, Naqshbandi A, Yusufi AN. Protective effect of ω-3 polyunsaturated fatty acids (PUFAs) on sodium nitroprusside-induced nephrotoxicity and oxidative damage in rat kidney. Hum Exp Toxicol. 2012;31:1035-49.
36. Hsu YC, Hsiao M, Wang LF, Chien YW, Lee WR. Nitric oxide produced by iNOS is associated with collagen synthesis in keloid scar formation. Nitric Oxide 2006;14:327-34.
37. Kuroishi T1, Bando K, Endo Y, Sugawara S. Metal allergens induce nitric oxide production by mouse dermal fibroblasts via the hypoxia-inducible factor-2α-dependent pathway. Toxicol Sci. 2013;135:119-28.
38. Morita H1, Hori M, Kitano Y. Modulation of picryl chloride-induced contact hypersensitivity reaction in mice by nitric oxide. J Invest Dermatol. 1996;107:549-52.
39. Valstar DL1, Schijf MA, Stelekati E, Nijkamp FP, Bloksma N, Henricks PA. Trimellitic anhydride-conjugated serum albumin activates rat alveolar macrophages in vitro. J Occup Med Toxicol. 2006;1:13.
40. Lee CS1, Yi EH, Kim HR, Huh SR, Sung SH, Chung MH, Ye SK. Anti-dermatitis effects of oak wood vinegar on the DNCB-induced contact hypersensitivity via STAT3 suppression. J Ethnopharmacol. 2011; 135: 747-53.

Downloaded from http://apjai.digitaljournals.org. For personal use only. No other uses without permission.