Archivum Immunologiae et Therapiae Experimentalis
https://doi.org/10.1007/s00005-018-0521-y

REVIEW

Systemic Treatment for Severe Atopic Dermatitis

Mara Giavina-Bianchi[1] · Pedro Giavina-Bianchi[1]

Received: 16 April 2018 / Accepted: 10 August 2018
© L. Hirszfeld Institute of Immunology and Experimental Therapy, Wroclaw, Poland 2018

Abstract
Atopic dermatitis (AD) is a chronic inflammatory, relapsing disease of the skin, characterized by intense pruritus, maculopapular or vesicular erythematous lesions and scaling, sometimes accompanied by oozing, crusts and/or lichenification that has a negative impact on patients' quality of life. Prevalence is higher in children, around 15%, and approximately 5% in adults. Before introducing systemic therapy, it is mandatory to review patients' adherence to the correct use of topical treatments (corticosteroids, calcineurin inhibitors or cresoborole) and/or phototherapy. Ensure that environmental measures are being taken care of, irritant or proven allergic substances are not in use and even if the diagnostic is correct. If all is being done and topical treatment with corticosteroid, emollients and phototherapy have not been sufficient to achieve a good control in AD of adults or children patients, it is time to consider systemic agents. Up to now, most of systemic treatments were based on immunosuppressive therapies, being cyclosporine A, the usually first choice for moderate-to-severe AD. Recently, biologic drugs have been developed and approved for AD, as dupilumab, and a whole new group of drugs is giving much hope for patients to have a better control of the disease with less side effects.

Keywords Systemic treatment · Atopic dermatitis · Review · Immunosuppressive agents · Biologic agents

Abbreviations

AD	Atopic dermatitis
CyA	Cyclosporine A
SCS	Systemic corticosteroids
MTX	Methotrexate
AZA	Azathioprine
MMF	Mycophenolate mofetil
EC-MPS	Enteric-coated mycophenolate sodium
JAK	Janus-associated kinase
TSLP	Thymic stromal lymphopoietin

Introduction

Atopic dermatitis (AD) is a chronic inflammatory, relapsing disease of the skin, characterized by intense pruritus, maculopapular or vesicular erythematous lesions and scaling, sometimes accompanied by oozing, crusts and/or lichenification. It is also frequent to have superinfection of the lesions either with virus or bacteria. Prevalence is higher in children, around 15%, and most patients develop the pathology by 5 years of age (Bantz et al. 2014; Kay et al. 1994). Prevalence in adults is approximately 5% (Hanifin and Reed 2007; Shaw et al. 2011; Silverberg and Hanifin 2013; Weidinger and Novak 2016) and recent studies have shown that it has been increasing in both children and adults over time, especially in low-income areas such as Africa an East Asia (Bieber 2008; Flohr and Mann 2014; Garmhausen et al. 2013; Katsarou and Armenaka 2011; Napolitano et al. 2016). Symptoms correlate positively with altitude and negatively with annual outdoor temperature (Flohr and Mann 2014). Due to its chronicity and frequent relapses, living with AD can be a burden, especially in those who require long-time systemic treatment, which can lead to severe toxicity in many organs. Pruritus and skin lesions can cause sleep disturbance, anxiety, depression and low self-esteem (Sánchez-Pérez et al. 2013; Simpson et al. 2016; Wollenberg et al. 2016). The poor patients' quality of life can extend also to the family or those who cohabite with them. Pathogenesis of AD includes a dysfunctional skin barrier, sometimes associated with filaggrin gene mutations, increased *Staphylococcus aureus* colonization and intense Th2 immune response, leading to allergen sensitization, elevated IgE levels and

✉ Pedro Giavina-Bianchi
pbianchi@usp.br

[1] Division of Clinical Immunology and Allergy, University of São Paulo School of Medicine, Artur Ramos 178 ap.211A, Jd. América, São Paulo, SP CEP: 01454-904, Brazil

Published online: 22 August 2018

blood eosinophilia. Usual treatment includes emollients and anti-inflammatory topical therapies, such as corticosteroids and calcineurin inhibitors. Novel therapies targeting AD pathogenesis aiming to be more efficacious and less harmful are coming to the market, as dupilumab, and will probably change our approach to moderate-to-severe AD patients. Our goal in this article is to review ancient systemic agents used for AD as well as discuss about new emerging therapies, which are in accordance with the precision medicine and can be the beginning of a new era of AD treatment.

Systemic Therapy

Before introducing systemic therapy, it is mandatory to review patients' adherence to the correct use of topical treatments (corticosteroids, calcineurin inhibitors or cresoborole, emollients) and/or phototherapy. Ensure that environmental measures are being taken care of, irritant or proven allergic substances are not in use and even if the diagnostic is correct. If all is being done and topical treatment with corticosteroid, emollients and phototherapy (especially narrow band UVB or UVA1 band) has not been sufficient to achieve a good control in AD of adults or children patients, it is time to consider systemic agents (Fig. 1).

Immunosuppressive Agents

Table 1 summarizes the immunosuppressors most commonly used in the treatment of moderate-to-severe atopic dermatitis.

Systemic Corticosteroids

Corticosteroids affect the transcription of several mediators involved in the pathogenesis of AD, as cytokines, chemokines and adhesion molecules, by binding to receptors of many regulatory genes, leading to inhibition of cell proliferation, vasoconstriction and decreasing inflammation (Simon and Bieber 2014). Systemic corticosteroids (SCS) have a rapid onset of action, as cyclosporine A (CyA), and it is commonly used in acute exacerbations for 3 days-to-3 weeks (Megna et al. 2017). It should not be used for a long period of time due to largely unfavorable side effects (Ring et al. 2012; Simon and Bieber 2014; Werfel et al. 2009). They include diabetes, hypertension, glaucoma, gastric ulcer, osteoporosis and Cushing syndrome. A common regimen for short course treatment is methylprednisolone at dose of 0.5 mg/kg/day for 1–2 weeks and then tapper it over a 1-month period. If SCS tapering is not done, there is a high risk of relapse or rebound of the disease (Schmitt et al. 2010). Controlled clinical trials in children and adults are lacking, but broad experience from clinical use demonstrates its efficacy (Megna et al. 2017).

Cyclosporine A

Now, it is commonly used as first choice for adults and children with severe AD refractory to regular therapy, because it is the only approved drug in many countries and it has a rapid onset of action (Ring et al. 2012). Although not approved for children and pregnant women, it has been used with good results. It is a calcineurin inhibitor that inhibits interleukin (IL)-2 and lymphocyte T activation, decreasing

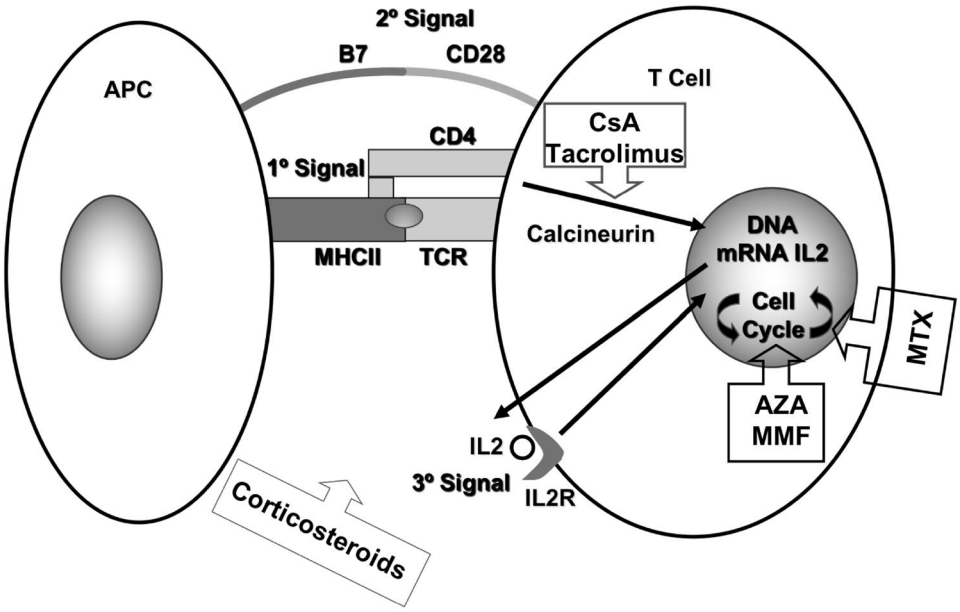

Fig. 1 Systemic immunosuppressive agents: mechanism of action. *APC* antigen-presenting cell, *CSA* ciclosporine A, *AZA* azathioprine, *MMF* mycophenolate mofetil, *MTX* methotrexate

Table 1 Immunosuppressors most commonly used in the treatment of moderate-to-severe atopic dermatitis

	Corticosteroid	Cyclosporine A	Methotrexate	Azathioprine	Mycophenolic acid
Starting dose adult	Variable Prednisolone 0.2–0.5 mg/kg/day	5 mg/kg/day	5 mg/week	50 mg/day	MMF: 1000–2000 mg/day; EC-MPA: 1440 mg/day
Maintenance dose adult	As little as possible, 2.5–10 mg/day	2.5–3 mg/kg/day	Increase 2.5–5 mg/week until maximum 25 mg/week	2–3 mg/kg/day	MMF: 2000 mg/day; EC-MPA: 1440 mg/day
Starting dose children	Variable Prednisolone 0.2–0.5 mg/kg/day	5 mg/kg/day	5 mg/week	50 mg/day	MMF: 1000–2000 mg/day; EC-MPA: 1440 mg/day
Maintenance dose adult	As little as possible	2.5–3 mg/kg/day	Increase 2.5–5 mg/week until effect	2–3 mg/kg/day	MMF: 2000 mg/day; EC-MPA: 1440 mg/day
Time for response	Days	2 weeks	12 weeks	8–12 weeks	12 weeks
Adverse effects	Diabetes, hypertension, gastric ulcer, osteoporosis, glaucoma and Cushing syndrome	Nephrotoxicity, hypertension, tremors, headache, paresthesia, nausea, diarrhea, myalgia, hyperkalemia, hypomagnesemia, hyperlipidemia, hypertrichosis, gingival hyperplasia	Liver dysfunction, gastrointestinal complaints, hematological abnormalities, pulmonary toxicity, fatigue, headache	Gastrointestinal disturbances, liver dysfunction and leucopenia	Gastrointestinal disturbances, fatigue, liver dysfunction, hematological abnormalities, flu-like syndrome
Laboratory control	Blood count, blood glucose	Blood count, creatinine, urea, cholesterol, triglycerides, electrolytes	Blood count, liver enzymes	Leukocyte count, liver enzymes	
Time for relapsing	Days	< 2 weeks	> 12 weeks	> 12 weeks	> 12 weeks
Pregnancy	Possible	Possible	Absolutely contra-indicated	Strict indication	Conflict data
Fathering	Possible	Possible	Strict indication	Strict indication	Strict indication

the immunoreactivity (Haeck et al. 2011). The dose for adults is 3–5 mg/kg/day divided into two takes (morning and evening). Some authors use a regimen of starting with 2.5 mg/kg/day and increase 0.5–1 mg/kg/day at intervals of 2–4 weeks, until the maximum dose of 5 mg/kg/day (Megna et al. 2017). Others prefer to start with the highest dose (5 mg/kg/day) for 6 weeks and then reduce it by 0.5–1.0 mg/day every week until 2.5–3.0 mg/kg/day (Haeck et al. 2011). In 2006, a meta-analysis study of 602 patients in 15 controlled and uncontrolled trials estimated a 55% relative effectiveness for 6–8 weeks of therapy (Schmitt et al. 2007). CyA can be used either for short-term treatment (3 months), as for uninterrupted use. Maximum time is up to 2 years to avoid complications, but intermittent short-term treatment has lower cumulative dose and may be used for longer time (Kim et al. 2015; Wollenberg et al. 2018). Some patients tolerate much longer low dose very well (Van Der Schaft et al. 2015). Side effects are infection, nephrotoxicity, hypertension, hepatotoxicity, paresthesia, tremors, headaches, nausea, diarrhea, myalgias, imbalance of electrolytes, hyperlipidemia, gingival hyperplasia and hypertrichosis (Roekevisch et al. 2014). Blood pressure and signs of renal dysfunction should be carefully monitored (Van Der Schaft et al. 2015). Exams should be taken at baseline, 2, 8, 12, 36 and 60 weeks after (Irvine et al. 2018). Rare cases of T-cell lymphoma, non-Hodgkin's lymphoma and lymphoid papulomatoid papules have been described with the use of CyA (Kirby et al. 2002; Laube et al. 2005; Sinha et al. 2004). Topical treatment combined with cyclosporine has shown to reduce cumulative dose of cyclosporine, with better results and longer remission in 60 patients (Schmitt et al. 2007). Because of its immunosuppression nature, one should not associate phototherapy with cyclosporine due to the increased risk of skin malignancies (Ring et al. 2012).

Methotrexate

Methotrexate (MTX) is a dihydrofolate reductase inhibitor that suppress DNA and RNA synthesis and T-cell functioning, decreasing inflammatory process and immune system reactivity (Notaro and Sidbury 2015). In children, MTX is the third choice of treatment, after CyA and azathioprine (AZA) in Europe (Irvine et al. 2018). Several studies show efficacy in the treatment of moderate-to-severe AD, but it is still used off label (Goujon et al. 2006; Lyakhovitsky et al. 2010; Politiek et al. 2016; Schram et al. 2011; Weatherhead et al. 2007). Patients improved 52% from baseline in a study of 24-week treatment with a median dose of 15 mg/week of MTX. Dose can range 7.5–25 mg/week in adults and 10–20 mg/m^2/week in children. Start low and titrating to the minimum effective dose is advisable to minimize gastrointestinal side effects. Maximum clinical efficacy is achieved after 8–12 weeks. Although delayed action, MTX has a more durable response once it is discontinued (El-Khalawany et al. 2013). It is available for oral and subcutaneous use and it has about the same efficacy as AZA (Schram et al. 2011). Side effects include infections, liver and bone marrow toxicity, nausea, fatigue, headache, pulmonary toxicities and drug interactions. Exams should be taken at baseline, 1 week after, monthly until 12 weeks and every 8 weeks after that (Irvine et al. 2018). Teratogenesis also limits its use and child-bearing potential women must use contraception method (Goujon et al. 2006; Lyakhovitsky et al. 2010; Weatherhead et al. 2007). Folic acid should be taken after each cycle of MTX at dose of 1 mg/day (Sidbury et al. 2014a).

Azathioprine

It is a purine analog precursor that inhibits lymphocyte proliferation (Notaro and Sidbury 2015). AZA has a slow onset, as MTX, and reaches clinical results in 8–12 weeks. It is used off label for severe AD. In adults, the dose recommended is 50 mg/day for 1–2 weeks and, if side effects are tolerable, it can be increased up to 2–3 mg/kg/day. For children, the usual dose is 1–4 mg/kg/day, gradually increased (Sidbury et al. 2014b). In two double-blind controlled studies, it proved to be more efficacious than placebo with an improvement of 26 and 37% in clinical scales after 3 months (Berth-Jones et al. 2002; Meggitt et al. 2006). It is comparable to MTX to treat patients with severe AD (Berth-Jones et al. 2002; Meggitt et al. 2006; Schram et al. 2011). Adverse reactions include infection, gastrointestinal disturbances, liver dysfunction and leucopenia (Berth-Jones et al. 2002). It is advisable to have a baseline thiopurine methyltransferase (TMTP) activity level measured, so that AZA dose can be adjusted to limit its myelotoxicity (Meggitt et al. 2006; Sidbury et al. 2014a). It can increase the risk of non-melanoma skin cancers and lymphoma in inflammatory bowel disease patients (Khan et al. 2013; Peyrin-Biroulet et al. 2011). In pregnant women, the use should be by strict indication only.

Mycophenolate Mofetil and Enteric-Coated Mycophenolate Sodium

Mycophenolate mofetil (MMF) is a prodrug of mycophenolic acid (MPA) and enteric-coated mycophenolate sodium (EC-MPS) is a different formulation of MPA created to minimize gastrointestinal adverse events (Sollinger 2005). They are derived from *Penicillium echinulatum* and are an antimetabolite that inhibit inosine monophosphate dehydrogenase and selectively block B- and T-cell proliferation (Megna et al. 2017; Notaro and Sidbury 2015). They are used off label in severe AD patients, children (Heller et al. 2007; Waxweiler et al. 2011) or adults unresponsive to cyclosporine (Sidbury et al. 2014b). Efficacy is comparable to

cyclosporine; the onset of action is longer, but the results are more durable (Wollenberg and Bieber 2009). For children, the dose for MMF is 600–1200 mg/m^2/day or 40–50 mg/kg/day in young children or in 30–40 mg/kg/day in adolescents. EC-MPS had the same efficacy of low-dose cyclosporine in AD maintenance treatment in adults (Haeck et al. 2011). Main side effects reported were nausea, fatigue, flu-like syndrome and liver enzyme alterations (Balal et al. 2005; Grundmann-Kollmann et al. 2001; Nguyen and Cruz 2014). As with other immunosuppressive agents, there is a potential increased risk for infections and malignancies. MMF can be used in children, MMF and EC-MPS are teratogenic and child-bearing potential women must use contraception method. An interesting approach could be using cyclosporine as an inductor of remission and MMF as a maintenance drug, especially for children (Notaro and Sidbury 2015).

Biologics

Biologics are a class of pharmacological drugs engineered to target specific mediators of inflammation. This novel approach blocking the pathways involved in the pathogenesis of AD has a great potential for more effective and less harmful therapy (Fig. 2). Dupilumab was the first biologic drug recently approved by Food and Drug Administration (FDA). Table 2 shows biologic drugs tested or in trials for treatment of moderate-to-severe atopic dermatitis.

Dupilumab

Dupilumab is a fully human monoclonal antibody direct against the shared α-subunit of the interleukin (IL0-4 receptor, blocking IL-4 and IL-13) actions. These two cytokines induce and promote a Th2 immune response, leading to allergen sensitization, inflammation, and impairing the skin barrier structure and function (Leung et al. 2004). Dupilumab reduces the Th2 immune response, modifying gene expression in AD lesions (Hamilton et al. 2014). In two phase-III trials of identical design, involving 1,379 adults with moderate-to-severe AD who were not adequately controlled with topical treatment, dupilumab improved patients' symptoms and signals, including pruritus, eczema, anxiety and depression, besides quality of life. Skin infections were significantly lower in the active group versus placebo. The two regimens tested, 300 mg subcutaneous every week or 300 mg subcutaneous every other week, for 16 weeks, were equally effective and safe. Side effects described more frequent than in the placebo group were injection site reactions and conjunctivitis (Simpson et al. 2017). This drug was considered a breakthrough therapy for AD for adult having moderate-to-severe disease inadequately controlled

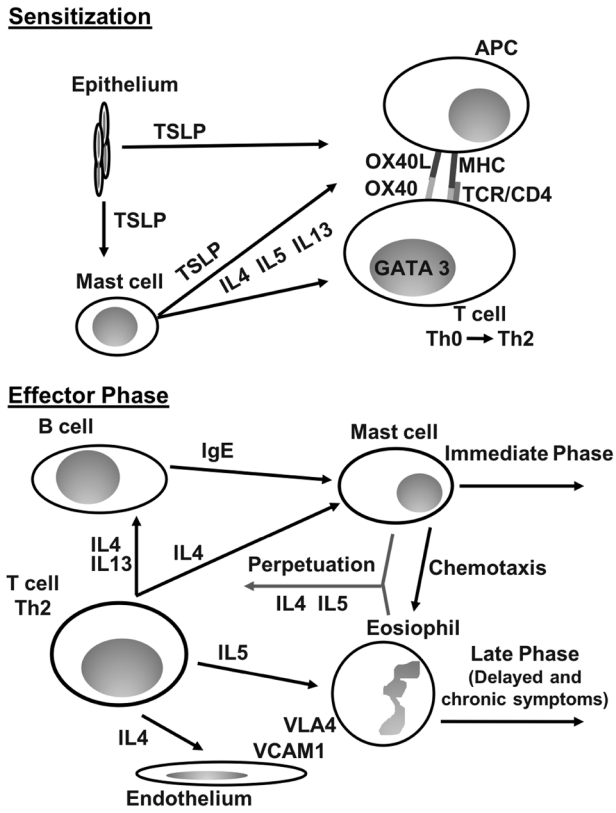

Fig. 2 Scheme of type 2 immune response phases. *APC* antigen-presenting cell, *TSLP* thymic stromal lymphopoietin

(Gooderham et al. 2017). It was approved in USA by FDA in March 2017 and by European Medicine Agency in July 2017 for the treatment of adult patients with moderate-to-severe AD not adequately controlled with topical therapies or phototherapy. New trials are now looking for the efficacy and safety of dupilumab in children, as well as the efficacy of other monoclonal antibodies, tralokinumab and lebrikizumab, which target only IL-13 (Moreno et al. 2016).

Apremilast

It is an oral small molecule inhibitor of phosphodiesterase-4 (PDE4). PDE4 is involved in multiple inflammatory pathways, especially in those related to tumor necrosis faktor, IL-12, IL-2, interferon γ, IL-5, IL-8, leukotriene B4, and adhesion molecule CD18/CD11b (Samrao et al. 2012). The drug has been studied for different diseases, such as asthma and chronic obstructive pulmonary disease, and it was approved by FDA in 2014 for psoriatic arthritis and moderate-to-severe plaque psoriasis (Fala 2015). Two studies have investigated the effect of this medication in adult AD patients (Samrao et al. 2012; Volf et al. 2012). Both studies showed an improvement in pruritus and Dermatology Life Quality Control Index, but apremilast seems

Table 2 Biologic drugs tested or in trials for moderate-to-severe atopic dermatitis

Immunologic target	Agent	Dosage	Side effects	Laboratory monitoring	Route of administration
IL-4Rα	Dupilumab	300 mg every 2 weeks	Increased risk of infection, conjunctivitis, site of injection reactions, gastrointestinal disturbances, headache	Blood count, liver enzymes	Subcutaneous
IgE	Omalizumab	150–600 mg every 2–4 weeks	Increased risk of infection, site of injection reactions, headache	Blood count, IgE count, liver enzymes	Subcutaneous
IL-12/23	Ustekinumab	45 mg for patients ≤ 100 kg; 90 mg for patients > 100 kg at week 0 and 4 and then every 12 weeks	Increased risk of infection, site of injection reactions, headache, fatigue, myalgia	Blood count, liver enzymes, purified protein derivative skin test for tuberculosis annually	Subcutaneous
Anti-CD20	Rituximab	500–1000 mg two cycle infusion 2 weeks apart	Headache, fever, nausea, diarrhea, weakness, flushing, muscle or joint pain, increased risk of infection, hematological abnormalities	Blood count, immunoglobulin levels	Intravenous
Anti-PDE4	Apremilast	20–30 mg twice a day	Nausea, diarrhea, headache	None	Oral
Anti-CD4	Alefacept	30 mg weekly for 16 weeks	Increased risk of infection and cancer, site of injection reactions, nausea, cough, dizziness, sore throat, myalgia, liver failure, pruritus	Blood count, liver enzymes	Intramuscular
JAK inhibitor	Tofacitinib	5 mg twice a day for 8–29 weeks	None	None	Oral

less effective in AD when compared to psoriasis. Further studies are needed to clearly assess its efficacy in moderate-to-severe AD (Megna et al. 2017).

Ustekinumab

It is a monoclonal antibody targeting IL-12 and IL-23 that was approved for psoriasis treatment. One case report showed that a single dose of 45 mg of ustekinumab induced a substantial clinical improvement in a patient with AD after 2 weeks, including improvement of pruritus. After 1 month, repeated doses of 45 mg were administered every 12 weeks and the benefit was sustained (Puya et al. 2012). Other two studies published in 2014 and 2016 failed to demonstrate significant improvement (Fernández-Antón Martínez et al. 2014; Samorano et al. 2016). In Japan, a recent phase-II study did not show significant improvement in the Eczema Area and Severity Index score at week 12 (Saeki et al. 2017). In conclusion, ustekinumab has a low potential as treatment for moderate-to-severe AD.

Omalizumab

Omalizumab is a monoclonal antibody against IgE, approved for severe asthma and urticaria treatment. It reduces IgE levels in serum, decrease expression of the high-affinity IgE receptor (FcεRI) and suppresses dendritic cell activation in the epithelium (Notaro and Sidbury 2015). Patients who were taken omalizumab to treat their asthma also improved from their AD (Kim et al. 2013). Eight children with severe AD underwent a randomized clinical trial with doses of 150–375 mg every 2–4 weeks and, although SCORAD index got better, the clinical improvements were similar to the control group (Iyengar et al. 2013). The limited effect showed with omalizumab was observed mainly in patients with filaggrin gene mutations (Hotze et al. 2014). Further trials are needed for evaluation of dose, safety and efficacy. Two other anti-IgE antibodies—ligelizumab for subcutaneous use and MEDI4212 for subcutaneous and intravenous administration—are being tested for atopic diseases (Arm et al. 2014; Sheldon et al. 2016).

Rituximab

Rituximab is a monoclonal antibody against the protein CD20, which is expressed mostly on the surface of B cells. These cells participate in the development of AD. There is only limited evidence for using rituximab in adults with AD, based on case reports and series (Sedivá et al. 2008; Simon et al. 2008). The best result was observed using a dose of 1000 mg by intravenous infusion, 2 weeks apart from each other (Simon et al. 2008).

Mepolizumab

It is a humanized monoclonal antibody that targets IL-5. In murine models knocked-out to IL-5, it reduced eosinophils and epidermal thickening after exposition to allergens, which could be helpful in AD (Spergel et al. 1999). Despite the reduction of 60% in the blood eosinophilia, anti-IL-5 did not decrease disease severity or pruritus in AD patients (Oldhoff et al. 2005).

Alefacept

Alefacept is a fully human LFA-3/IgG1 fusion protein that inhibits T-cell activation and selectively reduces memory T cells, which was tested in the treatment of AD in adults. It was well tolerated by the patients, but only two out of nine responded to the treatment in an open-label study of 16 weeks with 30 mg intramuscular per week (Moul et al. 2008).

Drugs Targeting Janus-Associated Kinase Signaling Axis

IL-4, IL-5, IL-13 and thymic stromal lymphopoietin (TSLP) signal through their respective receptors to induce downstream signaling events through the Janus-associated kinase (JAK)/STAT pathway, including the reduction of filaggrin gene expression (Howell et al. 2007). JAK inhibitors provide the opportunity to prevent this downstream activation of multiple Th2 cytokines are currently being evaluated for moderate-to-severe AD (Moreno et al. 2016). Oral tofacitinib showed promising results in six patients. They decreased disease activity in 66% with no serious adverse effects (Levy et al. 2015). Another drug of this class in study is baricitinib, targeting JAK1 and JAK2 (Moreno et al. 2016).

Drugs Targeting TSLP

TSLP, a Th2-associated epithelial cytokine, is produced by an epithelial cell line in response to trauma or microbes and it is elevated in AD lesions (Soumelis et al. 2002; Wang and Liu 2009). Trough sensory neurons, TSLP has been shown to direct induce itching (Wilson et al. 2013). There are two subcutaneous administrated drugs—tezepelumab and MK8226, targeting TSLP/TSLP receptor—being evaluated for moderate-to-severe AD (Moreno et al. 2016).

Alitretinoin

This is a teratogenic retinoid agent with anti-inflammatory and anti-proliferative actions (Ring et al. 2012). It is effective in atopic hand eczema, as has been shown by one large clinical trial and small case series using the standard dose of 30 mg daily for 12 weeks (Grahovac et al. 2010; Ruzicka et al. 2008). It can be considered for those adult AD patients with prominent involvement of the hands and who are resistant to topical treatment. Adverse effects include headache, thyroid-stimulating hormone and lipids serum elevation. Women of child-bearing age must have strict birth control (Ruzicka et al. 2008).

Oral Antihistamines

Pruritus is a major symptom that reduces quality of life of AD patients. Because scratching aggravates dermatitis, infection diseases and ocular complications, pruritus control is very important. Many studies in Japan support (Saeki et al. 2016) the use of antihistamines in these patients, but there are many negative reports in Europe and USA regarding its use in AD (Hoare et al. 2000; Klein and Clark 1999). Sedating antihistamines are useful for better sleep for some patients, due to their effect on pruritus and drowsiness, but control of AD by other management measures should be prioritized.

Allergen-Specific Immunotherapy

It is currently not recommended as a general treatment option for AD, according to the newest European guidelines for treatment of AD. It might be considered for patients who are sensitized to house dust mite, birch or grass pollen if there is a positive history of exacerbation after exposure to such allergen or a positive corresponding atopy patch test (Wollenberg et al. 2018).

Vitamins and Probiotics

Recently, in addition to its classical role in calcium homeostasis, vitamin D has been recognized for its effect on immunomodulation (Mutgi and Koo 2013). Studies did not find a beneficial role for vitamin D supplementation in

AD (Benson et al. 2012; Hata et al. 2014; Javanbakht et al. 2011). A Join Task Force Practice Parameter suggests supplementation for those patients with documented low level or poor intake of vitamin D (Eichenfield et al. 2017). There is some evidence that supplementation of probiotics would decrease by 20% the chance of AD onset in children (Doege et al. 2012; Pelucchi et al. 2012), but there are doubts when, how and how long these probiotics should be administered (Wollenberg et al. 2016).

Systemic Antimicrobials

AD patients have a high rate of infectious complications, resulting from *S. aureus*, herpes virus and *Malassezia* species infections. Systemic antibiotics can be recommended for use in patients with evidence of bacterial infection. Systemic antivirals in the treatment of *Eczema herpeticum* and antifungal agents are recommended if direct test with potassium hydroxide (KOH) or culture for fungus confirms the diagnosis of this pathology (Eichenfield et al. 2017).

Conclusion

Most patients with AD can achieve good disease control using exclusive topical treatment or in association with phototherapy. The moderate-to-severe cases that do not get good control with this treatment may benefit from systemic therapy. Several immunosuppressive agents have been used with this purpose, but most of them have a bad adverse events profile. With the advent of new emerging therapies, dupilumab, which is already approved by the FDA and several others which are currently in development, a new era of AD treatment is just starting, hopefully achieving better disease control with less adverse reactions for the patient.

References

Arm JP, Bottoli I, Skerjanec A et al (2014) Pharmacokinetics, pharmacodynamics and safety of QGE031 (ligelizumab), a novel high-affinity anti-IgE antibody, in atopic subjects. Clin Exp Allergy 44:1371–1385

Balal M, Demir E, Paydas S et al (2005) Uncommon side effect of MMF in renal transplant recipients. Ren Fail 27:591–594

Bantz SK, Zhu Z, Zheng T (2014) The atopic March: progression from atopic dermatitis to allergic rhinitis and asthma. J Clin Cell Immunol 5:202

Benson AA, Toh JA, Vernon N et al (2012) The role of vitamin D in the immunopathogenesis of allergic skin diseases. Allergy 67:296–301

Berth-Jones J, Takwale A, Tan E et al (2002) Azathioprine in severe adult atopic dermatitis: a double-blind, placebo-controlled, cross-over trial. Br J Dermatol 147:324–330

Bieber T (2008) Atopic dermatitis. N Engl J Med 358:1483–1494

Doege K, Grajecki D, Zyriax BC et al (2012) Impact of maternal supplementation with probiotics during pregnancy on atopic eczema in childhood—a meta-analysis. Br J Nutr 107:1–6

Eichenfield LF, Ahluwalia J, Waldman A et al (2017) Current guidelines for the evaluation and management of atopic dermatitis: a comparison of the Joint Task Force Practice Parameter and American Academy of Dermatology guidelines. J Allergy Clin Immunol 139:S49–S57

El-Khalawany MA, Hassan H, Shaaban D et al (2013) Methotrexate versus cyclosporine in the treatment of severe atopic dermatitis in children: a multicenter experience from Egypt. Eur J Pediatr 172:351–356

Fala L (2015) Otezla (Apremilast), an oral PDE-4 inhibitor, receives FDA approval for the treatment of patients with active psoriatic arthritis and plaque psoriasis. Am Health Drug Benefits 8:105–110

Fernández-Antón Martínez MC, Alfageme Roldán F, Ciudad Blanco C et al (2014) Ustekinumab in the treatment of severe atopic dermatitis: a preliminary report of our experience with 4 patients. Actas Dermosifiliogr 105:312–313

Flohr C, Mann J (2014) New insights into the epidemiology of childhood atopic dermatitis. Allergy 69:3–16

Garmhausen D, Hagemann T, Bieber T et al (2013) Characterization of different courses of atopic dermatitis in adolescent and adult patients. Allergy 68:498–506

Gooderham M, Lynde CW, Papp K et al (2017) Review of systemic treatment options for adult atopic dermatitis. J Cutan Med Surg 21:31–39

Goujon C, Bérard F, Dahel K et al (2006) Methotrexate for the treatment of adult atopic dermatitis. Eur J Dermatol 16:155–158

Grahovac M, Molin S, Prinz JC et al (2010) Treatment of atopic eczema with oral alitretinoin. Br J Dermatol 162:217–218

Grundmann-Kollmann M, Podda M, Ochsendorf F et al (2001) Mycophenolate mofetil is effective in the treatment of atopic dermatitis. Arch Dermatol 137:870–873

Haeck IM, Knol MJ, Ten Berge O et al (2011) Enteric-coated mycophenolate sodium versus cyclosporin A as long-term treatment in adult patients with severe atopic dermatitis: a randomized controlled trial. J Am Acad Dermatol 64:1074–1084

Hamilton JD, Suárez-Fariñas M, Dhingra N et al (2014) Dupilumab improves the molecular signature in skin of patients with moderate-to-severe atopic dermatitis. J Allergy Clin Immunol 134:1293–1300

Hanifin JM, Reed ML (2007) A population-based survey of eczema prevalence in the United States. Dermatitis 18:82–91

Hata TR, Audish D, Kotol P et al (2014) A randomized controlled double-blind investigation of the effects of vitamin D dietary supplementation in subjects with atopic dermatitis. J Eur Acad Dermatol Venereol 28:781–789

Heller M, Shin HT, Orlow SJ et al (2007) Mycophenolate mofetil for severe childhood atopic dermatitis: experience in 14 patients. Br J Dermatol 157:127–132

Hoare C, Li Wan Po A, Williams H (2000) Systematic review of treatments for atopic eczema. Health Technol Assess 4:1–191

Hotze M, Baurecht H, Rodríguez E et al (2014) Increased efficacy of omalizumab in atopic dermatitis patients with wild-type filaggrin status and higher serum levels of phosphatidylcholines. Allergy 69:132–135

Howell MD, Kim BE, Gao P et al (2007) Cytokine modulation of atopic dermatitis filaggrin skin expression. J Allergy Clin Immunol 120:150–155

Irvine AD, Jones AP, Beattie P et al (2018) A randomised controlled trial protocol assessing the effectiveness, safety and cost-effectiveness of methotrexate versus ciclosporin in the treatment of severe atopic eczema in children: the treatment of severe Atopic

eczema Trial (TREAT). Br J Dermatol. https://doi.org/10.1111/bjd.16717
Iyengar SR, Hoyte EG, Loza A et al (2013) Immunologic effects of omalizumab in children with severe refractory atopic dermatitis: a randomized, placebo-controlled clinical trial. Int Arch Allergy Immunol 162:89–93
Javanbakht MH, Keshavarz SA, Djalali M et al (2011) Randomized controlled trial using vitamins E and D supplementation in atopic dermatitis. J Dermatol Treat 22:144–150
Katsarou A, Armenaka M (2011) Atopic dermatitis in older patients: particular points. J Eur Acad Dermatol Venereol 25:12–18
Kay J, Gawkrodger DJ, Mortimer MJ et al (1994) The prevalence of childhood atopic eczema in a general population. J Am Acad Dermatol 30:35–39
Khan N, Abbas AM, Lichtenstein GR et al (2013) Risk of lymphoma in patients with ulcerative colitis treated with thiopurines: a nationwide retrospective cohort study. Gastroenterology 145:1007–1015.e3
Kim DH, Park KY, Kim BJ et al (2013) Anti-immunoglobulin E in the treatment of refractory atopic dermatitis. Clin Exp Dermatol 38:496–500
Kim JE, Kim HJ, Lew BJ et al (2015) Consensus guidelines for the treatment of atopic dermatitis in Korea (Part II): systemic treatment. Ann Dermatol 27:578–592
Kirby B, Owen CM, Blewitt RW et al (2002) Cutaneous T-cell lymphoma developing in a patient on cyclosporin therapy. J Am Acad Dermatol 47(2 Suppl):S165–S167
Klein PA, Clark RA (1999) An evidence-based review of the efficacy of antihistamines in relieving pruritus in atopic dermatitis. Arch Dermatol 135:1522–1525
Laube S, Stephens M, Smith AG et al (2005) Lymphomatoid papulosis in a patient with atopic eczema on long-term ciclosporin therapy. Br J Dermatol 152:1346–1348
Leung DY, Boguniewicz M, Howell MD et al (2004) New insights into atopic dermatitis. J Clin Invest 113:651–657
Levy LL, Urban J, King BA (2015) Treatment of recalcitrant atopic dermatitis with the oral Janus kinase inhibitor tofacitinib citrate. J Am Acad Dermatol 73:395–399
Lyakhovitsky A, Barzilai A, Heyman R et al (2010) Low-dose methotrexate treatment for moderate-to-severe atopic dermatitis in adults. J Eur Acad Dermatol Venereol 24:43–49
Meggitt SJ, Gray JC, Reynolds NJ (2006) Azathioprine dosed by thiopurine methyltransferase activity for moderate-to-severe atopic eczema: a double-blind, randomised controlled trial. Lancet 367:839–846
Megna M, Napolitano M, Patruno C et al (2017) Systemic treatment of adult atopic dermatitis: a review. Dermatol Ther 7:1–23
Moreno AS, McPhee R, Arruda LK et al (2016) Targeting the T helper 2 inflammatory axis in atopic dermatitis. Int Arch Allergy Immunol 171:71–80
Moul DK, Routhouska SB, Robinson MR et al (2008) Alefacept for moderate to severe atopic dermatitis: a pilot study in adults. J Am Acad Dermatol 58:984–989
Mutgi K, Koo J (2013) Update on the role of systemic vitamin D in atopic dermatitis. Pediatr Dermatol 30:303–307
Napolitano M, Megna M, Patruno C et al (2016) Adult atopic dermatitis: a review. Dermatol Venereol 151:403–411
Nguyen RH, Cruz PD Jr (2014) Hepatitis due to mycophenolate mofetil used to treat atopic dermatitis and allergic contact dermatitis. Dermatitis 25:284–285
Notaro ER, Sidbury R (2015) Systemic agents for severe atopic dermatitis in children. Paediatr Drugs 17:449–457
Oldhoff JM, Darsow U, Werfel T et al (2005) Anti-IL-5 recombinant humanized monoclonal antibody (mepolizumab) for the treatment of atopic dermatitis. Allergy 60:693–696
Pelucchi C, Chatenoud L, Turati F et al (2012) Probiotics supplementation during pregnancy or infancy for the prevention of atopic dermatitis: a meta-analysis. Epidemiology 23:402–414
Peyrin-Biroulet L, Khosrotehrani K, Carrat F et al (2011) Increased risk for nonmelanoma skin cancers in patients who receive thiopurines for inflammatory bowel disease. Gastroenterology 141:1621–1628 **(e1–5)**
Politiek K, van der Schaft J, Coenraads PJ et al (2016) Drug survival for methotrexate in a daily practice cohort of adult patients with severe atopic dermatitis. Br J Dermatol 174:201–203
Puya R, Alvarez-López M, Velez A et al (2012) Treatment of severe refractory adult atopic dermatitis with ustekinumab. Int J Dermatol 51:115–116
Ring J, Alomar A, Bieber T et al (2012) Guidelines for treatment of atopic eczema (atopic dermatitis) Part II. J Eur Acad Dermatol Venereol 26:1176–1193
Roekevisch E, Spuls PI, Kuester D et al (2014) Efficacy and safety of systemic treatments for moderate-to-severe atopic dermatitis: a systematic review. J Allergy Clin Immunol 133:429–438
Ruzicka T, Lynde CW, Jemec GB et al (2008) Efficacy and safety of oral alitretinoin (9-cis retinoic acid) in patients with severe chronic hand eczema refractory to topical corticosteroids: results of a randomized, double-blind, placebo-controlled, multicentre trial. Br J Dermatol 158:808–817
Saeki H, Nakahara T, Tanaka A et al (2016) Clinical practice guidelines for the management of atopic dermatitis 2016. J Dermatol 43:1117–1145
Saeki H, Kabashima K, Tokura Y et al (2017) Efficacy and safety of ustekinumab in Japanese patients with severe atopic dermatitis: a randomized, double-blind, placebo-controlled, phase II study. Br J Dermatol 177:419–427
Samorano LP, Hanifin JM, Simpson EL et al (2016) Inadequate response to ustekinumab in atopic dermatitis—a report of two patients. J Eur Acad Dermatol Venereol 30:522–523
Samrao A, Berry TM, Goreshi R et al (2012) A pilot study of an oral phosphodiesterase inhibitor (apremilast) for atopic dermatitis in adults. Arch Dermatol 148:890–897
Sánchez-Pérez J, Daudén-Tello E, Mora AM et al (2013) Impact of atopic dermatitis on health-related quality of life in Spanish children and adults: the PSEDA study. Actas Dermosifiliogr 104:44–52
Schmitt J, Schmitt N, Meurer M (2007) Cyclosporin in the treatment of patients with atopic eczema—a systematic review and meta-analysis. J Eur Acad Dermatol Venereol 21:606–619
Schmitt J, Schäkel K, Fölster-Holst R et al (2010) Prednisolone vs. ciclosporin for severe adult eczema. An investigator-initiated double-blind placebo-controlled multicentre trial. Br J Dermatol 162:661–668
Schram ME, Roekevisch E, Leeflang MM et al (2011) A randomized trial of methotrexate versus azathioprine for severe atopic eczema. J Allergy Clin Immunol 128:353–359
Sedivá A, Kayserová J, Vernerová E et al (2008) Anti-CD20 (rituximab) treatment for atopic eczema. J Allergy Clin Immunol 121:1515–1516
Shaw TE, Currie GP, Koudelka CW et al (2011) Eczema prevalence in the United States: data from the 2003 National Survey of Children's Health. J Invest Dermatol 131:67–73
Sheldon E, Schwickart M, Li J et al (2016) Pharmacokinetics, pharmacodynamics, and safety of MEDI4212, an anti-IgE monoclonal antibody, in subjects with atopy: a phase I study. Adv Ther 33:225–251
Sidbury R, Davis DM, Cohen DE et al (2014a) Guidelines of care for the management of atopic dermatitis: Sect. 3. Management and treatment with phototherapy and systemic agents. J Am Acad Dermatol 71:327–349

Sidbury R, Tom WL, Bergman JN (2014b) Guidelines of care for the management of atopic dermatitis: Sect. 4. Prevention of disease flares and use of adjunctive therapies and approaches. J Am Acad Dermatol 71:1218–1233

Silverberg JI, Hanifin JM (2013) Adult eczema prevalence and associations with asthma and other health and demographic factors: a US population-based study. J Allergy Clin Immunol 132:1132–1138

Simon D, Bieber T (2014) Systemic therapy for atopic dermatitis. Allergy 69:46–55

Simon D, Hösli S, Kostylina G et al (2008) Anti-CD20 (rituximab) treatment improves atopic eczema. J Allergy Clin Immunol 121:122–128

Simpson EL, Bieber T, Eckert L et al (2016) Patient burden of moderate to severe atopic dermatitis (AD): insights from a phase 2b clinical trial of dupilumab in adults. J Am Acad Dermatol 74:491–498

Simpson EL, Akinlade B, Ardenalu M (2017) Two phase 3 trials of dupilumab versus placebo in atopic dermatitis. N Engl J Med 376:1090–1091

Sinha A, Velangi S, Natarajan S (2004) Non-Hodgkin's lymphoma following treatment of atopic eczema with cyclosporin A. Acta Derm Venereol 84:327–328

Sollinger HW (2005) Enteric-coated mycophenolate sodium—current and future use in transplant patients. Expert Rev Clin Immunol 1:203–211

Soumelis V, Reche PA, Kanzler H et al (2002) Human epithelial cells trigger dendritic cell mediated allergic inflammation by producing TSLP. Nat Immunol 3:673–680

Spergel JM, Mizoguchi E, Oettgen H et al (1999) Roles of TH1 and TH2 cytokines in a murine model of allergic dermatitis. J Clin Invest 103:1103–1111

Van der Schaft J, van Zuilen AD, Deinum J et al (2015) Serum creatinine levels during and after long-term treatment with cyclosporine A in patients with severe atopic dermatitis. Acta Derm Venereol 95:963–967

Volf EM, Au SC, Dumont N et al (2012) A phase 2, open-label, investigator-initiated study to evaluate the safety and efficacy of apremilast in subjects with recalcitrant allergic contact or atopic dermatitis. J Drugs Dermatol 11:341–346

Wang YH, Liu YJ (2009) Thymic stromal lymphopoietin, OX40-ligand, and interleukin-25 in allergic responses. Clin Exp Allergy 39:798–806

Waxweiler WT, Agans R, Morrell DS (2011) Systemic treatment of pediatric atopic dermatitis with azathioprine and mycophenolate mofetil. Pediatr Dermatol 28:689–694

Weatherhead SC, Wahie S, Reynolds NJ et al (2007) An open-label, dose-ranging study of methotrexate for moderate-to-severe adult atopic eczema. Br J Dermatol 156:346–351

Weidinger S, Novak N (2016) Atopic dermatitis. Lancet 387:1109–1122

Werfel T, Aberer W, Augustin M et al (2009) [Atopic dermatitis: S2 guidelines]. J Dtsch Dermatol Ges 7(Suppl 1):S1–S46

Wilson SR, Thé L, Batia LM et al (2013) The epithelial cell-derived atopic dermatitis cytokine TSLP activates neurons to induce itch. Cell 155:285–295

Wollenberg A, Bieber T (2009) Proactive therapy of atopic dermatitis—an emerging concept. Allergy 64:276–278

Wollenberg A, Oranje A, Deleuran M et al (2016) ETFAD/EADV Eczema task force 2015 position paper on diagnosis and treatment of atopic dermatitis in adult and paediatric patients. J Eur Acad Dermatol Venereol 30:729–747

Wollenberg A, Barbarot S, Bieber T et al (2018) Consensus-based European guidelines for treatment of atopic eczema (atopic dermatitis) in adults and children: part II. J Eur Acad Dermatol Venereol 32:850–878