ARTICLE

Effectiveness of Itraconazole in the Management of Refractory Allergic Fungal Rhinosinusitis

Kwai-Onn Chan, MBBS, FRCS, Krista A. Genoway, BSc, and Amin R. Javer, MD, FRCSC, FARS

ABSTRACT

Objectives: **Conventional management of allergic fungal rhinosinusitis (AFRS) after surgery consists of the use of steroids to immunomodulate the body's response to fungi. However, there are many side effects to prolonged steroid use, and some patients are unresponsive to standard treatment. The role of systemic antifungal drugs in AFRS is still largely unknown. This was a pilot study to evaluate the effectiveness of itraconazole, an oral antifungal drug, in the treatment of refractory AFRS.**

Method: **Thirty-two patients with AFRS who had had surgery and were refractory to prednisone, steroid, and amphotericin B nasal sprays were treated with itraconazole for at least 3 months. They were evaluated with pre- and posttreatment endoscopic examinations, serum immunoglobulin E (IgE), and the 31-Item Rhinosinusitis Outcome Measure (RSOM-31) questionnaires. Monthly liver function tests were done to monitor for the hepatic side effects of itraconazole.**

Results: **Twelve cases had endoscopic improvement. Fifteen had no difference, and five had a worse endoscopic stage after 3 months. One patient had to stop treatment due to abnormal liver function tests. The mean pre- and posttreatment IgE levels were 581 μg/L and 766 μg/L, respectively. Subjectively, 9 patients (28%) reported a significant improvement, 9 (28%) had moderate improvements, and 14 (44%) reported little or no change. There was no correlation between the subjective and the endoscopic changes.**

Conclusion: **Itraconazole may be useful as an adjunct in the management of AFRS. However, more studies, including a prospective randomized clinical trial, are required to determine if itraconazole is effective in the management of AFRS.**

SOMAIRE

Objectif: **Le traitement conventionnel de la rhinosinusite fongique allergique (RSFA) après la chirurgie consiste à utiliser des stéroides pour immomoduler la réponse du corps au fongus. Cependant il y a plusieurs effets secondaires à l'utilisation à long terme et certains patients ne répondent pas à ce traitement. Le rôle des médicaments anti-fongique systémique est encore inconnu dans la RSFA. Voici une étude pilote qui évalue l'efficacité de l'itraconazole, un anti-fongique oral dans la traitement de la RSFA réfractaire.**

Méthode: **Trente-deux patients avec une RSFA traitée par chirurgie mais qui étaient réfractaire à la prednisone et à l'amphotéricine B en vaporisateur nasal ont été traités avec de l'itroconazole pour au moins trois mois. Ils ont été évalués avant et après le traitement avec une endoscopie des sinus, un dosage des IgE sériques et le questionnaire Rhinosinusitis Outcome Measure (RSOM-31). Un suivi mensuel de la fonction hépatique a permis d'évaluer les effets secondaires hépatiques de l'itraconazole.**

Résultats: **Nous avons noté, après trois mois, une amélioration endoscopique chez 12 patients, le statu quo chez 15 et une détérioration chez 5. Un patient a dû arrêter son traitement à cause des effets hépatiques. Les taux sériques moyens d'IgE étaient avant le traitement de 581 et après le traitement de 766 g/L. Subjectivement 9 patients (28%) ont rapporté une amélioration significative, 9 (28%) avaient une amélioration modérée et 14 (44%) n'ont pas rapporté de changement. Il n'y avait pas de corrélation entre l'amélioration endoscopique et l'évaluation subjective.**

Conclusion: **L'itroconazole peut être une addition utile à la prise en charge de la RSFA. Cependant d'autres études, incluant des essais cliniques randomisés, sont nécessaire pour déterminer si l'itroconazole est efficace dans le traitement de la RSFA.**

Key words: *allergic fungal rhinosinusitis, chronic rhinosinusitis, itraconazole*

Kwai-Onn Chan: *Department of Otolaryngology, Changi General Hospital, Singapore; and* Krista A. Genoway *and* Amin R. Javer: *St. Paul's Sinus Centre, St. Paul's Hospital, Vancouver, British Columbia.*

Address reprint requests to: Amin R. Javer, MD, FRCSC, FARS, *St. Paul's Sinus Centre, ENT Clinic, St. Paul's Hospital, 1081 Burrard Street, Vancouver, BC V6Z 1Y6; e-mail: sinussurgeon@drjaver.com.*

DOI 10.2310/7070.2008.OA0195

© *2008 The Canadian Society of Otolaryngology-Head & Neck Surgery*

Allergic fungal rhinosinusitis (AFRS) was described more than 20 years ago by Millar and colleagues and Katzenstein and colleagues.[1,2] To date, controversies and confusion remain with regard to the pathogenesis[3–5] and management of AFRS. Even though there is still no universally accepted protocol, Kuhn and Javer have described useful guidelines for the management of AFRS.[6] Systemic and intranasal steroids form the mainstay of their postoperative treatment protocol. The myriad side effects from prolonged systemic steroids[7] has led to the search for "steroid-sparing" alternatives. Antifungals are an obvious choice, but the role of topical and systemic antifungal agents is still not well established. AFRS is thought to share a similar pathogenesis with allergic bronchopulmonary aspergillosis (ABPA). Given that itraconazole has been shown to be effective in the management of ABPA,[8] it seemed like an obvious proposition to try itraconazole for refractory cases of AFRS as a possible steroid-sparing drug.

Itraconazole is a synthetic triazole antifungal agent. It inhibits the cytochrome P-450-dependent synthesis of ergosterol, which is a vital component of fungal cell membranes. Bent and Kuhn showed that many of the fungi in AFRS have in vitro susceptibility to itraconazole.[9] These include *Aspergillus*, *Bipolaris*, *Alternaria*, and *Curvularia*.

Amphotericin B is a well-established antifungal agent. Traditionally, it was given intravenously for invasive fungal sinusitis. Ponikau and colleagues reported that patients with chronic rhinosinusitis who used intranasal amphotericin B had improvement in subjective, endoscopic, and computed tomographic scan scores.[10] However, they did not have a control group in their study.

This is a retrospective review of our experience with the addition of itraconazole to the treatment regimen in AFRS patients who were refractory to prednisone, amphotericin B, nasal spray, and topical steroid sprays.

Methods and Treatment Protocol

A retrospective chart review of AFRS cases in a tertiary sinus centre over a 9-month period from August 2003 to April 2004 was conducted. Patients were diagnosed with AFRS based on a modification of the Bent and Kuhn criteria (Table 1).[11]

Intraoperatively or in the office, allergic mucin (Figure 1) was sent for fungal cultures and fungal stains. Standard fungal culture techniques were employed. The specimens were planted into inhibitory mould agar (Becton, Dickinson and Company, Franklin Lakes, NJ, USA) and brain-heart infusion agar containing 5% sheep blood, chloramphenicol, and gentamicin. Both media were incubated at 30°C in ambient air for 4 weeks. The slants were observed daily for 1 week and twice or three times per week thereafter. The antibiotics in both media inhibit bacterial flora. Silver stains were used to look for fungi in the allergic mucin specimens. However, the yield for fungal stains and cultures was poor and inconsistent from our laboratory; therefore, this criterion was not considered critical or necessary in making the diagnosis of AFRS.[12]

Table 1. Criteria Used for the Diagnosis of Allergic Fungal Rhinosinusitis

1. Nasal polyposis
2. Characteristic computed tomographic scan features
3. Allergic mucin on histologic examination or characteristic appearance on endoscopic examination
4. Raised total serum immunoglobulin E

All patients who had been diagnosed with AFRS underwent image-guided functional endoscopic sinus surgery (IG-FESS) by the senior author (A.R.J.). Surgery in all cases consisted of either a primary or revision bilateral complete frontosphenoethmoidectomy with meticulous removal of all allergic mucin from the sinus cavities. Postoperatively, patients were seen on day 6 to remove middle meatal spacers and then every 4 to 6 weeks. Postoperative medical management consisted of two puffs of intranasal steroid spray twice daily, atomized amphotericin B nasal spray three times a day, and a slow taper of prednisone over 6 weeks with occasional short bursts as and when needed. Six millilitres of amphotericin B in a

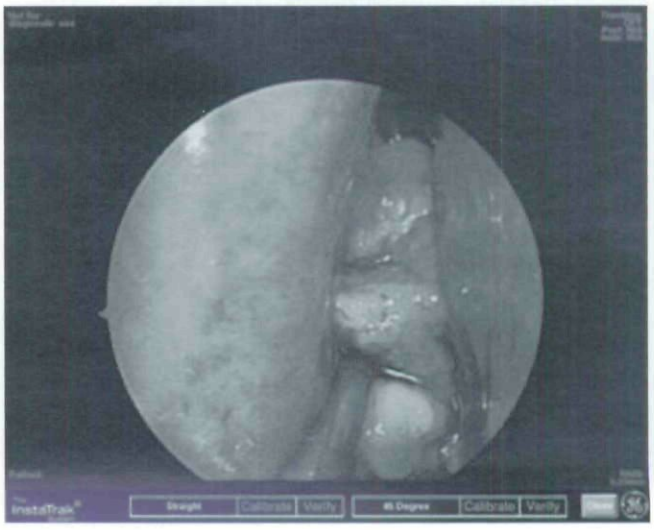

Figure 1. Allergic mucin with polyps.

Table 2. Endoscopic Mucosa Staging System Used

Stage	*Endoscopic Finding*
0	No mucosal edema or allergic mucin
I	Mucosa edema with or without allergic mucin
II	Polypoid edema with or without allergic mucin
III	Sinus polyps with fungal debris or allergic mucin

dose of 50 mg in 500 cc sterile water was sprayed into each nostril using a mucosal atomization device syringe (Wolfe Tory Medical Inc, Salt Lake City, UT) three times a day. The prednisone was started at 40 mg (0.4 mg/kg/d) for 4 days and reduced by 0.1 mg/kg/d in cycles of 4 days to a maintenance dose of 15 mg/d for 4 to 6 weeks before tapering to a stop.

Itraconazole was started on patients who were refractory to treatment with prednisone, intranasal steroids, and topical amphotericin B. Those patients who started having a recurrence as soon as prednisone was tapered began oral itraconazole treatment. Once itraconazole was started, patients discontinued their use of prednisone. Informed consent, with an emphasis on the possibility of hepatic injury secondary to chemical hepatitis, was obtained in all patients. Serum total immunoglobulin E (IgE) and liver function tests (LFTs) were taken prior to commencement of itraconazole and at each follow-up visit. Patients with abnormal LFTs or a history of liver problems were not started on itraconazole. Itraconazole was started at a dose of 300 mg/d (100 mg three times daily) for a month and then reduced to 200 mg/d for at least 2 more months. At each follow-up, an endoscopic examination was performed. The mucosa was staged according to the staging system proposed by Kupferberg and colleagues (Table 2).[13] When the mucosal stage differed for different regions, the worst stage was recorded. For example, if stage 2 disease was noted in the frontal recess but stage 0 in the ethmoid cavity, the mucosa was recorded as stage 2.

After 3 months, patients filled out a 31-Item Rhinosinusitis Outcome Measure (RSOM-31) questionnaire. Itraconazole was stopped if LFTs were abnormal or if patients did not have any subjective and objective improvement at 3 months posttreatment.

Medical records were analyzed for epidemiologic data (age and sex), the number of surgical procedures, pre- and posttreatment IgE levels, pre- and posttreatment mucosa staging, and RSOM-31 scores.

Results

Thirty-two patients, 16 males and 16 females, who had AFRS refractory to treatment with prednisone, amphotericin B nasal spray and intranasal steroids were started on itraconazole. The mean age was 46 years. Twenty patients had primary IG-FESS, and 12 had revision IG-FESS. Those who required revision surgery had a mean of 2.8 previous operations. Only one patient required revision IG-FESS after itraconazole was started. Twenty-five patients (78%) also had asthma.

Twelve cases had an endoscopic improvement. Fifteen had no difference, and five had a worse endoscopic stage after 3 months of treatment with itraconazole. One patient had to stop treatment due to abnormal LFTs. Before starting itraconazole, the mean mucosal stage on the right was 2 and on the left was 2.3. At 1 and 3 months of treatment, the mucosa remained at stage 2.

Mean serum total IgE before itraconazole was 581 IU (933 SD), ranging from 37 to 5098 IU. At 1 month, the mean was 756 IU (1170 SD), ranging from 47 to 5052 IU, and at 3 months, it was 766 IU (1170 SD), ranging from 34 to 5321 IU. This increase in IgE was not statistically significant.

After 3 months, patients completed an RSOM-31 questionnaire. Nine patients (28%) reported significant improvement, 9 (28%) reported moderate improvement, and 14 (44%) said there was little or no change. No correlation was observed between patients who indicated quality of life improvement and those who had an improvement in the endoscopic stage. Change in quality of life as measured by the RSOM-31 can be found in Figure 2. A significant difference ($\alpha = .05$) was observed in

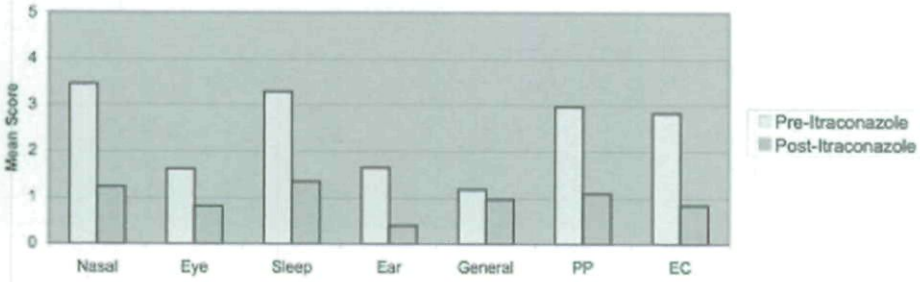

Figure 2. Changes in RSOM-31 scores following the use of itraconazole. PP = practical problems; EC = emotional consequences.

the symptom subgroups of nasal symptoms, sleep symptoms, ear symptoms, practical problems, and emotional consequences (Table 3). All other subgroups did not demonstrate a significant difference.

Six patients (19%) had significant increases in their liver enzymes, and itraconazole had to be stopped for them. One patient developed a chemical hepatitis with jaundice. Her hepatitis developed 2 months after itraconazole had been started. During the initial 2 months of treatment, her LFTs were completely normal. Once itraconazole was stopped, her hepatitis and jaundice resolved spontaneously. The other five had asymptomatic increases in alanine transminase (mean 55 U/L), aspartate transaminase (mean 98 U/L), and γ-glutamyltransferase (mean 105 U/L) that resolved after discontinuation of itraconazole.

Discussion

AFRS is a chronic disease with a very high recurrence rate if not followed closely.[14] Recurrence occurs despite thorough surgical removal of all visible allergic mucin and diseased mucosa. The reasons for recurrence are unclear: it could be due to reexposure to fungi, persistent microscopic fungi, or unrecognized fungal infection of the mucosa or bone.[9] There is also patient-to-patient variation in the response to standard treatment consisting of prednisone, topical steroid sprays, and amphotericin B nasal sprays. Some patients are well controlled with minimal steroids and amphotericin B nasal sprays, whereas others are unresponsive to repeated courses of prednisone, amphotericin B, and topical steroids. Once again, despite many theories put forth in the literature, the reason for this remains unknown.[5,15]

Our results show modest improvement in response to the addition of itraconazole to the treatment regimen. Fifty-six percent of patients reported subjective improvement, and 38% had endoscopic improvement, with no correlation between the subjective and endoscopic groups. Overall, the mean serum IgE levels did not decrease. Once again, the reasons are unclear. It has been theorized that the presence of eosinophilic mucin with polyps may not be a result of one distinct disease entity but may be the end-stage clinical presentation of a wide range of different forms of chronic rhinosinusitis. Collins and colleagues proposed categorizing eosinophilic mucin with nasal polyposis into four groups depending on the fungi and serum IgE status.[15] Classic AFRS may just be one subset of eosinophilic mucin with polyps. Ferguson proposed the term *eosinophilic chronic rhinosinusitis* (ECRS) for all cases of chronic rhinosinusitis with eosinophilia (either serum or tissue).[5] She further divided this group into subcategories: superantigen-induced ECRS, AFRS, nonallergic fungal ECRS, and aspirin-exacerbated ECRS. At the time of our study, we did not differentiate the groups, which may explain why itraconazole was effective in only about half of the cases. The others could have been AFRS-like sinusitis, which resembles AFRS except that fungi cannot be demonstrated or may not be the primary cause of the classic findings. This may also explain why the serum IgE did not reduce in response to itraconazole. Another possible reason for the modest response to itraconazole is that, in AFRS, the fungi are noninvasive and found only in the mucus, and itraconazole may not reach the minimal inhibitory concentration in the mucus when taken systemically.

Rains and Mineck reported using up to 400 mg of itraconazole a day and then tapering down to 200 mg a day over 3 months without any major side effects.[16] They reported only a 4% prevalence of elevated liver enzymes. In our study, a lower dose of itraconazole was used (300 mg/d), and we observed a 19% prevalence of elevated liver enzymes. Five patients had asymptomatic transaminitis, and one patient had overt hepatitis with jaundice. In all six cases, the liver enzymes returned to normal after stopping itraconazole. Itraconazole has been associated with rare cases of hepatotoxicity, including liver failure and death, and it seems that silent transaminitis may be relatively common. Therefore, we recommend monthly monitoring of LFTs while patients are on itraconazole.

Conclusion

Itraconazole may be useful as an adjunct in the management of AFRS. However, more studies, including a prospective randomized clinical trial, are required to determine if itraconazole is effective in the management of AFRS.

Table 3. Significance Scores as Measured by *p* Value for RSOM-31 Subgroups Prior to and Following the Use of Itraconazole

	Nasal	*Eye*	*Sleep*	*Ear*	*General*	*Practical Problems*	*Emotional Consequence*
p Value	.0156	NS	.0156	.0078	NS	.0078	.0078

NS = not significant at an $\alpha = .05$ level; RSOM-31 = 31-Item Rhinosinusitis Outcome Measure.

References

1. Millar JW, Johnston A, Lamb D. Allergic aspergillosis of the maxillary sinuses (Abstract). Thorax 1981;36:710.
2. Katzenstein AL, Sale SR, Greenberger PA. Allergic *Aspergillus* sinusitis: a newly recognized form of sinusitis. J Allergy Clin Immunol 1983;72:89–93.
3. Ponikau JU, Sherris DA, Kern EB, et al. The diagnosis and incidence of allergic fungal sinusitis. Mayo Clin Proc 1999;74:877–84.
4. Ferguson BJ. Eosinophilic mucin rhinosinusitis: a distinct clinicopathological entity. Laryngoscope 2000;110(5 Pt 1), 799–813.
5. Ferguson BJ. Categorization of eosinophilic chronic rhinosinusitis. Curr Opin Otolaryngol Head Neck Surg 2004;12:237–42.
6. Kuhn FA, Javer AR. Allergic fungal rhinosinusitis: perioperative management, prevention of recurrence, and role of steroids and antifungal agents. Otolaryngol Clin North Am 2000;33:419–33.
7. Marple BF. Allergic fungal rhinosinusitis: current theories and management strategies. Laryngoscope 2001;111:1006–19.
8. Wark PA, Hensley MJ, Saltos N, et al. Anti-inflammatory effect of itraconazole in stable allergic bronchopulmonary aspergillosis: a randomized controlled trial. J Allergy Clin Immunol 2003;111:952–7.
9. Bent JP 3rd, Kuhn FA. Antifungal activity against allergic fungal sinusitis organisms. Laryngoscope 1996;106:1331–4.
10. Ponikau JU, Sherris DA, Kita H, et al. Intranasal antifungal treatment in 51 patients with chronic rhinosinusitis. J Allergy Clin Immunol 2002;110:862–6.
11. Bent JP 3rd, Kuhn FA. Diagnosis of allergic fungal sinusitis. Otolaryngol Head Neck Surg 1994;111:580–8.
12. Javer AR, Genoway KA, Gervais M, et al. Fungal cultures in patients with allergic fungal rhinosinusitis: improving the recovery of potential fungal pathogens in the Canadian laboratory. J Otolaryngol 2007;36:1–5.
13. Kupferberg SB, Bent JP 3rd, Kuhn FA. Prognosis for allergic fungal sinusitis. Otolaryngol Head Neck Surg 1997;117:35–41.
14. Kuhn FA, Javer AR. Allergic fungal sinusitis: a four-year follow-up. Am J Rhinol 2000;14:149–56.
15. Collins M, Nair S, Smith W, et al. Role of local immunoglobulin E production in the pathophysiology of noninvasive fungal sinusitis. Laryngoscope 2004;114:1242–6.
16. Rains BM 3rd, Mineck CW. Treatment of allergic fungal sinusitis with high-dose itraconazole. Am J Rhinol 2003;17:1–8.

Copyright of Journal of Otolaryngology -- Head & Neck Surgery is the property of B.C. Decker Inc. and its content may not be copied or emailed to multiple sites or posted to a listserv without the copyright holder's express written permission. However, users may print, download, or email articles for individual use.