Lung
DOI 10.1007/s00408-016-9884-1

Evaluation of Simvastatin and Bone Marrow-Derived Mesenchymal Stem Cell Combination Therapy on Airway Remodeling in a Mouse Asthma Model

Maryam Mohammadian[1] · Hamid Reza Sadeghipour[1] · Iraj Ragerdi Kashani[2] · Gila Pirzad Jahromi[3] · Amene Omidi[2] · Amir Kavian Nejad[4] · Ravie Golchoobian[1] · Mohammad Hossein Boskabady[5]

Received: 14 January 2016 / Accepted: 22 April 2016
© Springer Science+Business Media New York 2016

Abstract
Introduction The effect of bone marrow-derived mesenchymal stem cells (BMSCs) on asthma treatment was shown in our previous study. Several studies have shown the effect of statins on BMSC preservation and migration to sites of inflammation. In this study, the effects of simvastatin and BMSC combination therapy in an ovalbumin-induced asthma model in mouse were examined.
Methods Four groups of BALB/c mice were studied including control group (animals were not sensitized), asthma group (animals were sensitized by ovalbumin), asthma + simvastatin group (asthmatic animals were treated with simvastatin), and asthma + BMSC + simvastatin group (asthmatic animals were treated with simvastatin and BMSCs). BMSCs were isolated, characterized, labeled with BrdU, and transferred into asthmatic mice. BMSC migration, airways histopathology, and total and differential white blood cell (WBC) count in bronchoalveolar lavage (BAL) fluid were evaluated.
Results A significant increase in the number of BrdU-BMSCs was found in the lungs of mice treated with simvastatin + BMSCs compared to mice treated with BMSCs. The histopathological changes, BAL total WBC counts, and the percentage of neutrophils and eosinophils were increased in asthma group compared to the control group. Treatment with simvastatin significantly decreased airway inflammation and inflammatory cell infiltration. Combination therapy improved all measured parameters higher than simvastatin. Goblet cell hyperplasia and subepithelial fibrosis were also decreased in combination therapy group.
Conclusion These results indicated that simvastatin and BMSC combination therapy was superior to simvastatin therapy and BMSC therapy alone in reduction of airway remodeling and lung inflammation in the ovalbumin-induced asthma model in mouse.

Keywords Simvastatin · Stem cells · Airway remodeling · Mouse asthma model

✉ Mohammad Hossein Boskabady
boskabadymh@mums.ac.ir

1 Department of Physiology, Faculty of Medicine, Tehran University of Medical Sciences, Tehran, Iran

2 Department of Anatomy, Faculty of Medicine, Tehran University of Medical Sciences, Tehran, Iran

3 Chemical Injuries Research Center, Baqiyatallah University of Medical Sciences, Tehran, Iran

4 Department of Emergency Medical Services, Faculty of Nursing and Midwifery, Shahid Beheshti University of Medical Sciences, Tehran, Iran

5 Neurogenic Inflammation Research Center and Department of Physiology, School of Medicine, Mashhad University of Medical Sciences, Mashhad, Iran

Introduction

Asthma is characterized by airway inflammation, reversible airway obstruction, and airway structural changes [1, 2]. Airway remodeling led to airway narrowing and airflow limitation [3] which indicate that treatment of remodeling is important to control and prevent asthma exacerbation.

Bone marrow-derived mesenchymal stem cells (BMSCs) are the multi-potent progenitor cells [4] that regulate immune and inflammatory responses [5]. In the previous study, intravenously administered bone marrow-derived mesenchymal stem cells were localized in the lung and inhibited airway inflammation in ovalbumin-induced asthma in mouse [6]. BMSCs may also exert therapeutic

Published online: 09 May 2016

effects in asthma by induction of T-regulatory cells and T-helper type 2 to T-helper type 1 shift [7–9] which was shown to be dose dependent [10, 11]. However, promotion of BMSC migration into the inflamed area may augment their therapeutic effects, because their migration from the vascular system into the tissues is low and only 4.5–8.4 % [11, 12].

The effects of statins on migration of BMSCs to sites of inflammation [13–15] and their potential therapeutic effect on asthma were shown previously [16, 17].

Therefore, in the present study, the effect of simvastatin and BMSC combination therapy on airway remodeling in an ovalbumin-induced asthma model in mouse was examined.

Materials and Methods

Experimental Animals

Eighteen male BALB/c mice (6–8 weeks old) were divided into four groups: control group (non-sensitized animals, $n = 4$), asthma group (sensitized by OVA, $n = 4$), asthma + simvastatin (treated sensitized animals with simvastatin, $n = 6$), and asthma + simvastatin + BMSC (treated sensitized animals with simvastatin and BMSCs, $n = 4$). Animals were obtained from Pasteur Institute, Iran. Mice were maintained in regular cages under the controlled environmental conditions (20 ± 2 °C and 12 h light–dark cycle) and allowed free access to standard lab chow and water in the animal laboratory of Tehran University of Medical Science. Animal care and the general protocols for animal use were approved by the Animal Ethics Community of Tehran University of Medical Sciences.

Sensitization and Inhalational Exposure

The mice were sensitized by intraperitoneal injection of OVA (10 mg) (OVA, Sigma grade 5) and aluminum hydroxide (2 mg) on day 0 and 14. Animals then exposed to aerosolized OVA (3 %) in a closed chamber (dimensions $40 \times 40 \times 70$ cm^3) using a nebulizer (Omron CX3, Japan, particle size 3–5 µm and output of 5 l/min) for 30 min/day, 3 days/week form weeks 3–11 [18]. Animals in asthma + simvastatin and asthma + simvastatin + BMSC groups were treated with daily intraperitoneal injection of simvastatin (40 mg/kg) on the last week of challenge and those of asthma + simvastatin + BMSC group received single intravenous injection of BMSCs (1×10^6) on the last week of challenge. Animals of control group received normal saline instead of OVA (Fig. 1).

Simvastatin Preparation

Simvastatin (Arasto Pharmaceutical Chemical Inc, Tehran-Iran, SIM-F8-24-88) was prepared as a 4 mg/ml stock by dissolving 40 mg of simvastatin in 1 ml of ethanol with 1.5 ml of 0.1 N NaOH and incubated at 50 °C for 2 h. Then 7.5 ml PBS was added and pH was adjusted to 7.2, and the stock solution was diluted to the appropriate concentration in sterile PBS immediately prior to use [19].

BMSC Preparation

Male Balb/c mice (aged 6–8 weeks) were sacrificed, and the tibias and the femurs were dissected away from attached muscle and connective tissue. Under aseptic conditions, the ends of the bones were removed and the bone marrow was extruded with 1 ml culture medium using a 31G needle. The cell pellet containing hematopoietic cells and bone marrow stromal cells was suspended in growth medium containing Dulbecco's modified Eagle's medium (DMEM; Invitrogen, Burlington, Ontario, Canada) with 15 % fetal bovine serum (FBS; Invitrogen), penicillin (100 u/ml), streptomycin (100 µg/ml), and amphotericin B (25 ng/ml) (Sigma). The harvested cells were seeded on a 25-cm^2 flask (Nunc, Roskilde, Denmark) at 37 °C and 5 % CO_2 in an incubator for 24 h. The flasks were then washed with PBS to remove the hematopoietic cells and were incubated for 2–3 days, until the cells reached 70–80 % confluency and were harvested with Trypsin–EDTA solution (0.25 % Trypsin, 0.5 mM EDTA; Sigma) for 5–10 min at 37 °C to obtain a single-cell suspension. Nucleated marrow cells were counted using a cytometer to ensure adequate cell numbers for transplantation. This cycle was repeated four times (passage 1, 2, 3, and 4, respectively). At the 3rd passage, the cells were checked for BMSC purity using antibody staining as described later [19].

BMSC Characterization and Purification

After the initial plating of the primary culture, mouse BMSCs within 3–5 passages were harvested by trypsinization and were fixed in neutralized 2 % paraformaldehyde solution (Sigma, USA) for 30 min. The fixed cells were washed twice with PBS (Sigma, USA) and incubated with antibodies to the following antigens: CD31, CD45, CD90, and CD44 (all from Chemicon, CA) for 30 min. Primary antibodies were directly conjugated with FITC. Flow cytometry was performed with a FAC Scan flow cytometer (Becton–Dickinson, CA) [20].

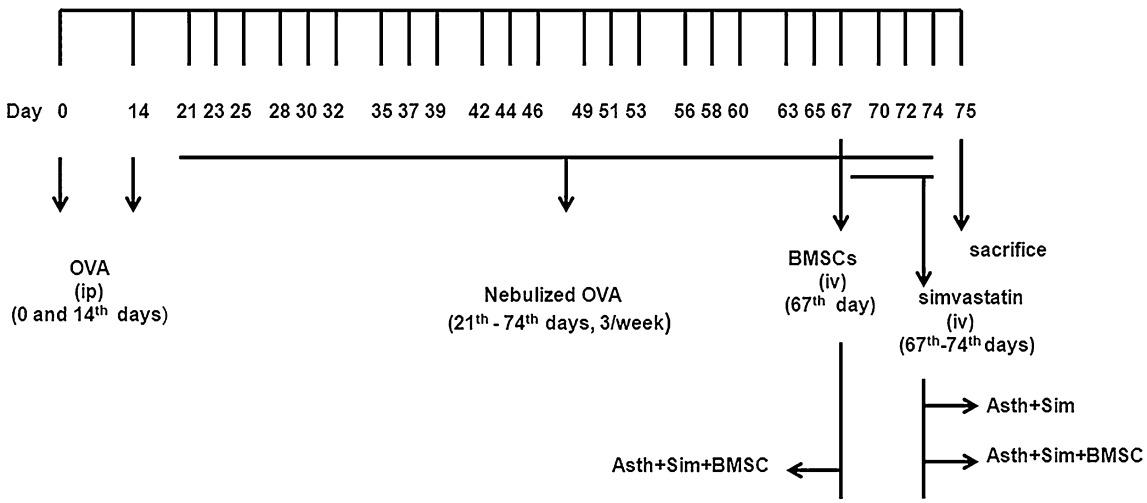

Fig. 1 Time table for mouse model of asthma and treatment with BMSCs and simvastatin

Adipogenic and Osteogenic Differentiation

Cultured stem cells of passage 2 were disseminated at a density of 5000 cells/cm and maintained in growth medium for 3 days and medium was replaced by differentiation medium (contained αMEM, 10 % FBS, 2 mM L-glutamine, 100 U/ml penicillin, and 100 mg/ml streptomycin and additionally either 10 nM dexamethasone, 50 mg/ml L-ascorbic acid and 10 mM b-glycerophosphate [osteogenic differentiation] or 10 nM dexamethasone, 200 mg/ml indomethacin, 5 mg/ml insulin and 0.5 mM IBMX [adipogenic differentiation]) with slight modifications. After 21 days, osteogenic deposits and adipocytes were visualized by alizarin red and oil red O staining, respectively [21].

Osteogenesis was confirmed by Alizarin Red S staining (highlights extracellular matrix calcification) by washing cells in flasks (25 cm^2) with phosphate-buffered saline (PBS) and fixing in 10 % (v/v) formaldehyde (Sigma-Aldrich). After 15 min, ARS 2 % (pH 4.1) was added to each flask. The flasks were incubated at room temperature for 20 min and were washed four times with dH_2O while being shaken for 5 min [22].

At day 10 after the induction of adipogenesis, the 24-well plates containing cultured BMSC were washed with PBS three times, fixed with 10 % formalin, sealed to prevent dehydration, and stored at 4 °C. The fixative was aspirated and the individual wells were stained with 600 µl of freshly prepared 0.3 % Oil Red O staining solution for 20 min and washed five times with water. [23].

BMSC Labeling with Bromodeoxyuridine (BrdU)

Determination of transplanted on BMSC migration was done by BMSC labeling with BrdU. After 3rd passage, BMSCs were transferred to a 250-ml flask. When 40 percent of the confluency was achieved, 5 mM BrdU was added to the medium. After every 72 h, the medium was changed and 5 mM BrdU was added each time, until 70–80 percent cells were confluent [24].

Lung Lavage and Its White Blood Cells Count

Mice were anesthetized 1 day after the last challenge and lungs were lavaged with three 0.3 ml sterile phosphate-buffered saline. Total cell number for each animal was determined by neobar lam; differential cell analysis was performed on slides stained with Wright and Giemsa solutions [25].

Pathological Evaluation

Left lungs were fixed in formalin and embedded in paraffin blocks and were sectioned at 4 µm thickness and were stained with hematoxylin-eosin (H&E) solution, periodic acid schiff (PAS), and Masson's trichrome, respectively. For each mouse, the ratio of PAS-positive cells/total cells in five randomly distributed airway sections were analyzed, and their average scores were calculated. The grading system was 0, no goblet cells; 1, <15 %; 2, 15–30 %; 3, 30–45 %; 4, 45–60 %; and 5, >60 % [25]. The scoring system of peribronchiolar inflammation was 0, no cells; 1, a few cells; 2, a ring of cells 1 cell layer deep; 3, a ring of cells 2–4 cells deep; 4, a ring of cells 4–6 cells deep; and 5, a ring of cells >6 cells deep [26]. Subepithelial fibrosis was asses using the Digimizer software. The area of collagen deposition (AC) and the perimeter of basement membrane of bronchioles (Pbm) were expressed as the area of AC per the perimeter of basement membrane of bronchioles (AC/Pbm $\mu m^2/\mu m$) as follows: 0, <5 AC/Pbm($\mu m^2/\mu m$); 1,

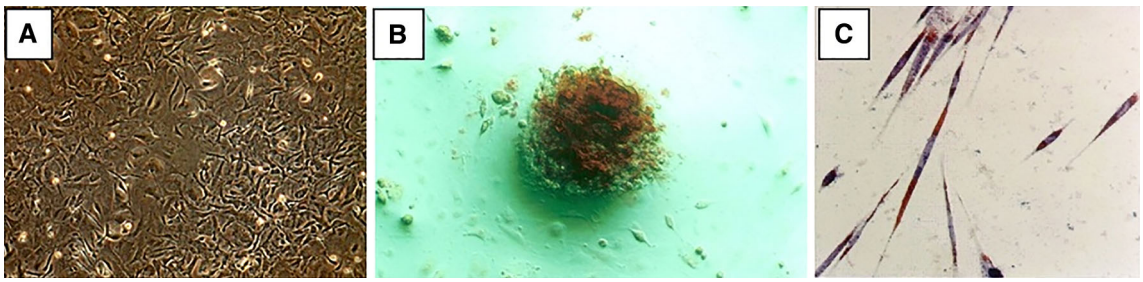

Fig. 2 Undifferentiated BMSCs (**a**) indicating a flattened fibroblast-like morphology under phase contrast microscopy. Alizarin red staining of mineralized bone tissue and oil red O-positive intracellular lipid droplets indicates that BMSCs can be differentiated into osteoblasts (**b**) and adipocytes (**c**), respectively

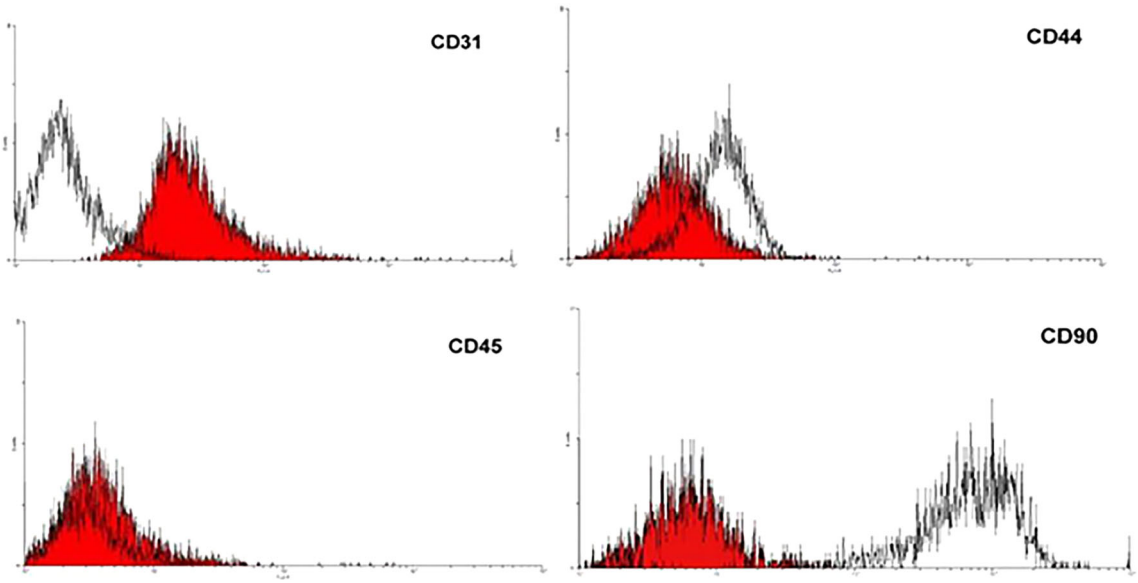

Fig. 3 BMSC conformation using flow cytometric analysis, since CD44 and CD90 were positive and CD31 and CD45 were negative

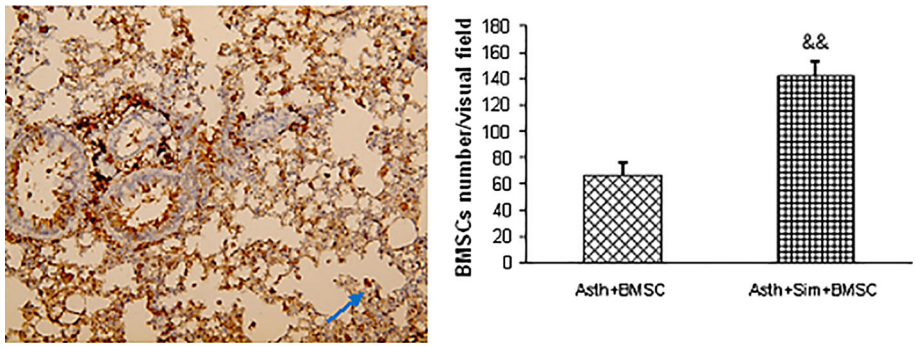

Fig. 4 BMSC migration into the lung tissue in OVA-induced asthma in BALB-c mice treated with BMSCs (Asth + BMSC) and simvastatin + BMSCs (Asth + Sim + BMSC). *Thin blue arrow* shows BrdU-positive cell (magnification ×20). &&; $P < 0.01$ compared to Asth + BMSC group

5–10 AC/Pbm($\mu m^2/\mu m$); 2, 10–15 AC/Pbm($\mu m^2/\mu m$); 3, 15–20 AC/Pbm($\mu m^2/\mu m$); 4, 20–25 AC/Pbm($\mu m^2/\mu m$); and 5, > 25 AC/Pbm($\mu m^2/\mu m$) [26].

In order to analyze the migration of BMSCs to the lung tissue, light microscopic evaluation was made by a blinded investigator.

Statistics

Data are presented as the mean ± SEM and were analyzed with the unpaired t test and analysis of variance (ANOVA) followed by the Tukey test. A probability value of < 0.05 was considered as statistically significant.

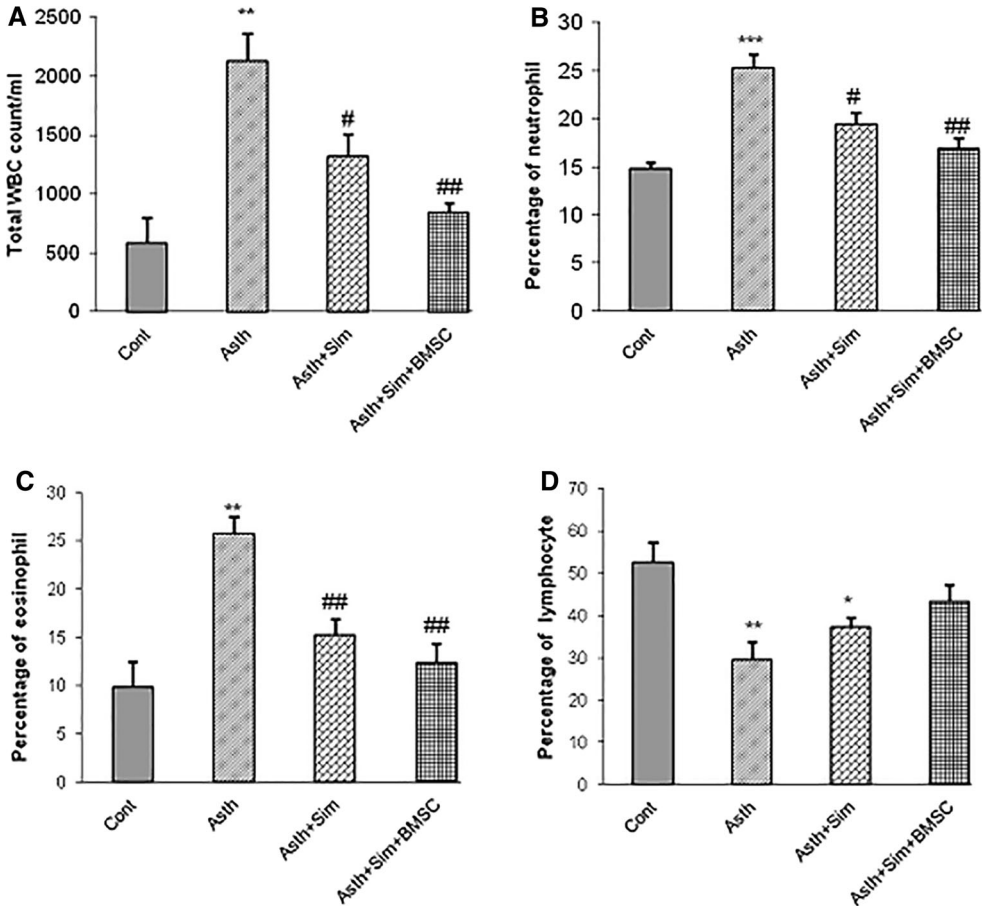

Fig. 5 Total WBC counts (**a**) and the percentage of neutrophils (**b**), eosinophils (**c**), and lymphocytes (**d**) in the BAL fluid in control animals (Cont, $n = 4$), OVA-induced asthma model (Asth, $n = 4$), asthmatic animals treated with simvastatin (Asth + Sim, $n = 6$), and asthmatic animals treated with simvastatin and BMSCs (Asth + Sim + BMSC, $n = 4$). Statistical comparison between groups was performed using analysis of variance followed by the Tukey test. $^{*}P < 0.05$, $^{**}P < 0.01$, $^{***}P < 0.001$ compared to control group, $^{\#}P < 0.05$, $^{\#\#}P < 0.01$ compared to asthma group

Results

BMSC Characterization

The BMSCs appeared as a monolayer of large, fibroblast-like flattened cells which were able to adopt an osteogenic or adipogenic phenotype under appropriate conditions (Fig. 2).

Flow cytometric analysis of BMSCs within 3–5 passages showed that BMSCs significantly expressed CD44 and CD90, but were negative for CD31 and CD45 (Fig. 3).

BMSC Migration into the Lung Tissue

The number of BrdU-BMSCs in the lungs of mice treated with simvastatin + BMSCs was significantly higher than in those treated with BMSCs ($P < 0.01$), (Fig. 4).

Total and Differential WBC Count in BAL Fluid

Total WBC counts ($P < 0.01$), the percentage of neutrophils ($P < 0.001$), and eosinophils ($P < 0.01$) were significantly increased, but the percentage of lymphocytes was decreased (29.50 ± 4.38, $P < 0.01$) in BAL fluid of asthmatic animals compared with those of controls.

Simvastatin ($P < 0.05$) and combination ($P < 0.01$) therapy significantly reduced WBC counts compared to asthmatic group and there were no significant differences in total WBC between control group with simvastatin and combination treatment groups (Fig. 5).

Simvastatin and combination therapy also resulted in a significant decrease in neutrophils and eosinophils ($P < 0.01$ for both cases). In addition, the percentage of neutrophils and eosinophils in treated groups did not differ with that of the control group. However, there was no significant differences in lymphocyte percentage between simvastatin and combination treatment groups compared to asthma group (Fig. 5).

Airway Inflammation

Peribronchial inflammatory cell infiltration score was significantly elevated in asthmatic compared to control group ($P < 0.001$). Simvastatin and combination treatment markedly reduced peribronchial inflammatory cell infiltration score versus asthma group ($P < 0.001$ for both cases). In

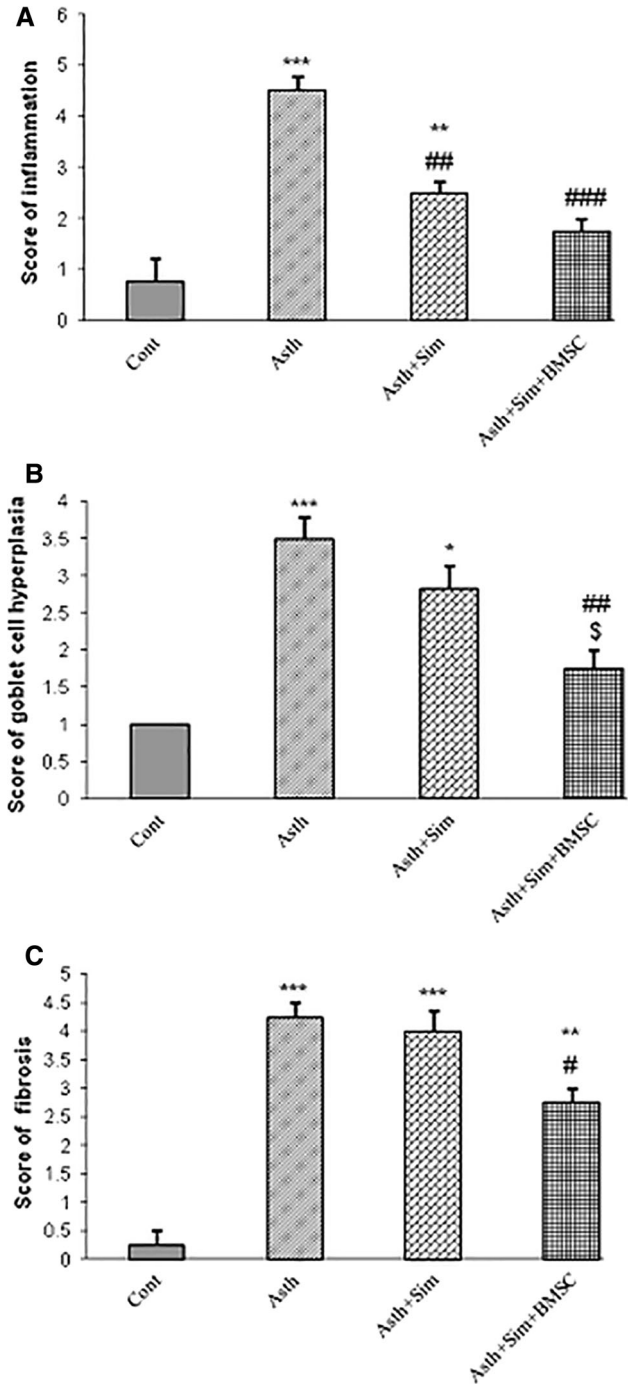

◀**Fig. 6** The peribronchial inflammatory cell infiltration (**a**), the airway goblet cell hyperplasia (**b**), and the subepithelial fibrosis (**c**) in control animals (Cont, $n = 4$), OVA-induced asthma model (Asth, $n = 4$), asthmatic animals treated with simvastatin (Asth + Sim, $n = 6$), and asthmatic animals treated with simvastatin and BMSCs (Asth + Sim + BMSC, $n = 4$). The degree of peribronchiolar inflammation was evaluated by a subjective scale. The scoring system was *0* no cells; *1* a few cells; *2* a ring of cells 1 cell layer deep; *3* a ring of cells 2–4 cells deep; *4* a ring of cells 4–6 cells deep; and *5* a ring of cells >6 cells deep. The degree of goblet cell hyperplasia was reported as the ratio of PAS-positive cells/total cells. The adopted grading system was *0* no goblet cells; *1* <15 %; *2* 15–30 %; *3* 30–45 %; *4* 45–60 %; and *5* >60 %. The degree of fibrosis was expressed as the area of collagen deposition per the perimeter of basement membrane (AC/Pbm $\mu m^2/\mu m$) of bronchioles. The adopted grading system was *0* <5 AC/Pbm($\mu m^2/\mu m$); *1* 5–10 AC/Pbm($\mu m^2/\mu m$); *2* 10–15 AC/Pbm($\mu m^2/\mu m$); *3* 15–20 AC/Pbm($\mu m^2/\mu m$); *4* 20–25 AC/Pbm($\mu m^2/\mu m$); and *5* >25 AC/Pbm($\mu m^2/\mu m$). Statistical comparison between groups was performed using analysis of variance followed by the Tukey test. $^{*}P < 0.05$, $^{**}P < 0.01$, $^{***}P < 0.001$ compared to control group, $^{\#}P < 0.05$, $^{\#\#}P < 0.01$, $^{\#\#\#}P < 0.001$ compared to asthma group, $^{\$}P < 0.05$ compared to asthma + simvastatin group

addition, there was no significant difference in peribronchial inflammatory cell infiltration between combination treatment and control group (Fig. 6).

Goblet Cell Hyperplasia in the Airway

The score of PAS-positive goblet cells was significantly increased in asthmatic compared to control group ($P < 0.001$). Treatment with simvastatin did not significantly changed goblet cells count compared to asthmatic mice. However, asthma + simvastatin + BMSC group showed significantly lower goblet cells numbers compared to asthma group ($P < 0.01$). Furthermore, there was no significant difference in goblet cells count between asthma + simvastatin + BMSC and control groups. There was also a significant difference between asthma + simvastatin and asthma + simvastatin + BMSC groups in this regard (Fig. 6).

Peribronchial Collagen Deposition

Collagen deposition was significantly increased in asthmatic compared to control group ($P < 0.001$). Simvastatin therapy alone could not reduce the extent of collagen deposition compared to asthma group, but combination therapy significantly reduced collagen deposition ($P < 0.05$) (Fig. 6). Photographs of histopathology of lung specimens in different groups were provided in Fig. 7.

Discussion

Significant increase in inflammatory cell infiltration in the BAL fluid and all lung pathological scores in sensitized animals to ovalbumin compared to control group were observed. There was also a high BMSC migration to the lung tissue in asthma + BMSC + simvastatin group. Simvastatin and BMSC combination therapy showed more potent reduction in airway inflammation and inflammatory cell infiltration of sensitized animals than simvastatin alone. Combination therapy also decreased goblet cell hyperplasia and subepithelial fibrosis in sensitized animals.

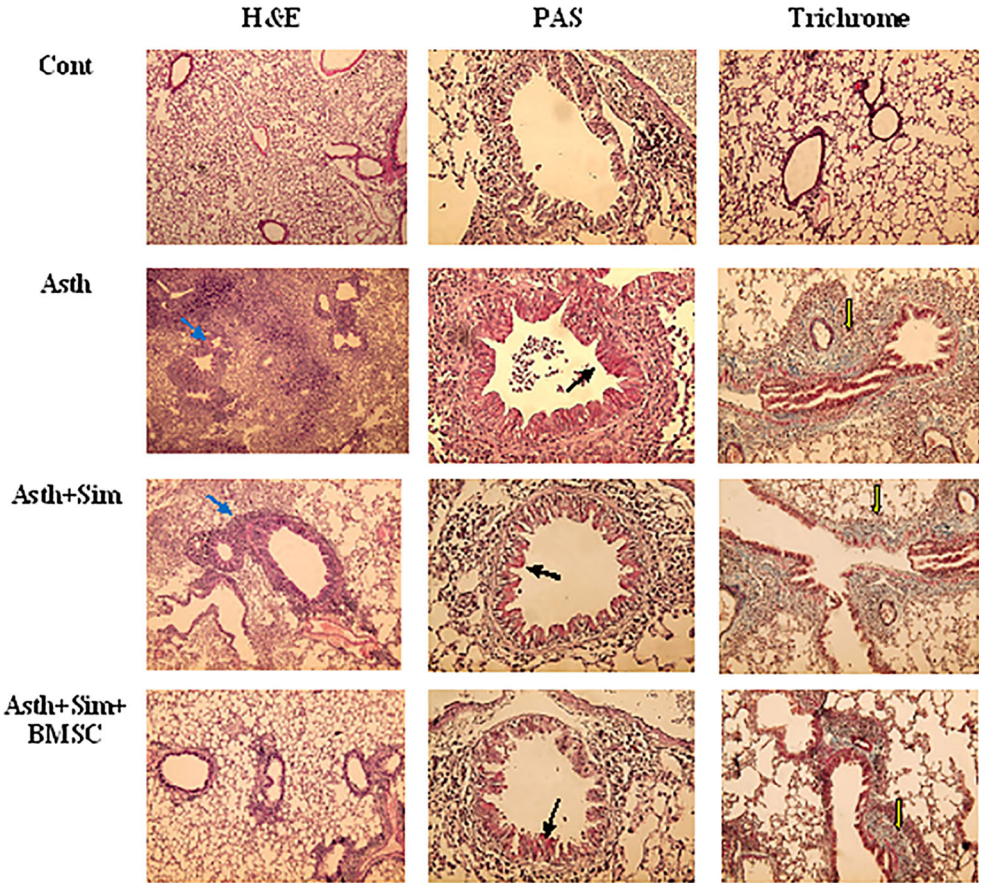

Fig. 7 Histopathological findings of bronchial wall in control animals (Cont), OVA-induced asthma model (Asth), asthmatic animals treated with simvastatin (Asth + Sim), and asthmatic animals treated with simvastatin and BMSCs (Asth + Sim + BMSC). *Blue thin arrows* show inflammatory cell infiltration, *black thin arrows* show goblet cells, *yellow thin arrows* show collagen deposition; staining with hematoxylin-eosin (H&E) solution, periodic acid schiff (PAS), and Masson's trichrome; magnification ×10, ×40, and ×20, respectively

BMSC migration and localization [6] and involvement of stromal cell-derived factor-1 (SDF-1) and its cellular receptor, CXCR4, in MSC migration to the lung [27] in asthmatic mice were demonstrated previously. It has been reported also that the therapeutic effect of these cells is dose dependent [10, 11] and their ability to migrate from the vascular system into the tissues is low [11, 12]. Thus, strategies which promote BMSC migration into the inflamed area may augment their therapeutic effects. The present study showed that administration of BMSCs with simvastatin resulted in a higher migration of BMSCs into the lung tissue in asthma + simvastatin + BMSC group. In fact, recent studies have highlighted the protective effect of statins on MSCs against hypoxia and apoptosis [13, 14]. Statins also significantly increase SDF1 expression in the ischemic brain, CXCR4 expression in BMSCs, and BMSC migration to rat brain [14, 28]. According to the findings of present study, it seems that simvastatin could increase the migration of BMSCs to lung by acting on SDF-1α/CXCR4 axis.

The results of this study showed significant increase in the infiltration of neutrophil and eosinophil to the BAL fluid, lung inflammation, goblet cell hyperplasia, and subepithelial fibrosis in sensitized mice which confirmed the induction of an asthma animal model in mice which also supported by previous studies [2, 29, 30].

Simvastatin decreased the infiltration of neutrophil and eosinophil to the BAL and lung inflammation in asthma + simvastatin group which is supported by previous studies [16, 31–33]. These drugs have shown to reduce inflammatory and allergic responses and improve lung compliance in animal models of asthma [17]. Several potential mechanisms, particularly their anti-inflammatory mechanisms, may contribute to these effects of statins. These effects are thought to be mediated by inhibition of isoprenylation of small G-proteins, prevention of lipid raft formation, pathways involved in cell proliferation, and oxidative stress [34].

Although BMSCs inhibited airway inflammation, goblet cell hyperplasia, and inflammatory cell infiltration to the BAL in sensitized animals, it was unable to reduce subepithelial fibrosis which could be due to the low number of BMSCs migrated into the lung tissue [6]. The present study showed that combination therapy of BMSCs + simvastatin decreased the infiltration of neutrophil and eosinophil to the BAL, airway inflammation, goblet cell hyperplasia and subepithelial fibrosis in sensitized animals. Airway inflammation and inflammatory cell infiltration were also improved in simvastatin-alone-treated group but did not affect goblet cell hyperplasia. However, treatment with BMSCs alone also decreased goblet cell hyperplasia

[6]. In addition, BMSC treatment alone or simvastatin treatment alone did not show any effect on subepithelial fibrosis of sensitized animals. Interestingly, the combination therapy also decreased subepithelial fibrosis possibly by increasing BMSC engraftment to the injured tissue or by enhancing the secretion of BMSC growth factors and cytokines to stimulate tissue repair. The effect of combination therapy was also greater than the effect of BMSCs or simvastatin alone.

Taken together, the results of the present study demonstrate that simvastatin and BMSC combination therapy is more effective for treating OVA-induced asthma model than BMSC or simvastatin alone. The possible mechanism by which BMSC and simvastatin combination therapy could improve subepithelial fibrosis including inflammatory biomarkers such as Th2 cytokines, and evaluating of SDF-1α/CXCR4 axis to identify mechanism for simvastatin action on BMSC migration to the lung should be examined in further studies. In addition, clinical investigations also should be carried out to evaluate this type of therapy in asthmatic patients in further studies.

In conclusion, the results of the present study demonstrated that simvastatin and BMSC combination therapy improved airway remodeling and lung inflammation in the sensitized mice greater than simvastatin or BMSC therapy alone which deserves further studies including clinical investigations.

Acknowledgments This study was financially supported by the Research Department of Tehran University of Medical Sciences. The results described in this paper were a part of Ph.D. student research.

Compliance with Ethical Standards

Conflict of Interest The authors declare that they have no conflict of interest.

References

1. Nakagome K, Nagata M (2011) Pathogenesis of airway inflammation in bronchial asthma. Auris Nasus Larynx 38:555–563
2. Bloemen K, Verstraelen S, Van Den Heuvel R et al (2007) The allergic cascade: review of the most important molecules in the asthmatic lung. Immunol Lett 113:6–18
3. Al-Muhsen S, Johnson JR, Hamid Q (2011) Remodeling in asthma. J Allergy Clin Immunol. 128:451–462
4. Bonnet D (2003) Biology of human bone marrow stem cells. Clin Exp Med 3:140–149
5. Bonfield TL, Caplan AI (2010) Adult mesenchymal stem cells: an innovative therapeutic for lung diseases. Discov Med 9:337–345
6. Mohammadian M, Boskabady MH, Ragerdi Kashani IR et al (2015) Effect of bone marrow derived mesenchymal stem cells on lung pathology and inflammation in ovalbumin- induced asthma in mouse. Iran J Basic Med Sc. 19:55–63
7. Boskabady MH, Keyhanmanesh R, Khamneh S et al (2011) Potential immunomodulation effect of Nigella sativa on ovalbumin sensitized guinea pigs. J Zhejiang Univ Sci B 12:201–209
8. Boskabady MH, Shahmohammadi Mehrjardi S, Rezaee A et al (2013) The impact of Zataria multiflora Boiss extract on in vitro and in vivo Th1/Th2 cytokine (IFN-γ/IL4) balance. J Ethnopharmacpol 150:1024–1031
9. Bayrami G, Boskabady MH, Jalali S et al (2013) The effect of the extract of Crocus sativus on tracheal responsiveness and plasma levels of IL-4, IFN-γ, total NO and nitrite in ovalbumin sensitized Guinea-pigs. J Ethnopharmacol 147:530–535
10. Mahmood A, Lu D, Lu M et al (2003) Treatment of traumatic brain injury in adult rats with intravenous administration of human bone marrow stromal cells. Neurosurgery 53:697–702
11. Muller-Ehmsen J, Krausgrill B, Burst V et al (2006) Effective engraftment but poor mid-term persistence of mononuclear and mesenchymal bone marrow cells in acute and chronic rat myocardial infarction. J Mol Cell Cardiol 41:876–884
12. Borlongan CV, Lind JG, Dillon-Carter O et al (2004) Bone marrow grafts restore cerebral blood flow and blood brain barrier in stroke rats. Brain Res 1010:108–116
13. Zhang Q, Yang YJ, Wang H et al (2012) Autophagy activation: a novel mechanism of atorvastatin to protect mesenchymal stem cells from hypoxia and serum deprivation via AMP-activated protein kinase/mammalian target of rapamycin pathway. Stem Cells Dev 21:1321–1332
14. Zhang Y, Zhang R, Li Y et al (2012) Simvastatin augments the efficacy of therapeutic angiogenesis induced by bone marrow-derived mesenchymal stem cells in a murine model of hindlimb ischemia. Mol Biol Rep 39:285–293
15. Cui X, Chopp M, Zacharek A et al (2009) Chemokine, vascular and therapeutic effects of combination Simvastatin and BMSC treatment of stroke. Neurobiol Dis 36:35–41
16. Ou XM, Wen FQ, Uhal BD et al (2009) Simvastatin attenuates experimental small airway remodelling in rats. Respirology 14:734–745
17. Zeki AA, Franzi L, Last J et al (2009) Simvastatin inhibits airway hyperreactivity: implications for the mevalonate pathway and beyond. Am J Respir Crit Care Med 180:731–740
18. Firinci F, Karaman M, Baran Y et al (2011) Mesenchymal stem cells ameliorate the histopathological changes in a murine model of chronic asthma. Int Immunopharmacol 11:1120–1126
19. Pirzad Jahromi G, Seidi S, Sadr SS et al (2012) Therapeutic effects of a combinatorial treatment of simvastatin and bone marrow stromal cells on experimental embolic stroke. Basic Clin Pharmacol Toxicol 110:487–493
20. Kashani IR, Golipoor Z, Akbari M et al (2011) Schwann-like cell differentiation from rat bone marrow stem cells. Arch Med Sci 7:45–52
21. Song X, Xie S, Lu K et al (2015) Mesenchymal stem cells alleviate experimental asthma by inducing polarization of alveolar macrophages. Inflammation 38:485–492
22. Zaminy A, Kashani IR, Barbarestani M et al (2008) Osteogenic differentiation of rat mesenchymal stem cells from adipose tissue in comparison with bone marrow mesenchymal stem cells: melatonin as a differentiation Factor. Iran Biomed J 12:133–141
23. Pachón-Peña G, Yu G, Tucker A et al (2011) Stromal stem cells from adipose tissue and bone marrow of age-matched female donors display distinct immunophenotypic profiles. J Cell Physiol 226:843–851
24. Qian C, Tio RA, Roks AJ et al (2007) A promising technique for transplantation of bone marrow-derived endothelial progenitor cells into rat heart. Cardiovasc Pathol. 16:127–135
25. Khakzad MR, Mirsadraee M, Mohammadpour A et al (2012) Effect of verapamil on bronchial goblet cells of asthma: an experimental study on sensitized animals. Pulm Pharmacol Ther 25:163–168
26. Cao R, Dong XW, Jiang JX et al (2011) M(3) muscarinic receptor antagonist bencycloquidium bromide attenuates allergic airway

inflammation, hyperresponsiveness and remodeling in mice. Eur J Pharmacol 655:83–90
27. Ou-Yang HF, Huang Y, Hu XB et al (2011) Suppression of allergic airway inflammation in a mouse model of asthma by exogenous mesenchymal stem cells. Exp Biol Med 236: 1461–1477
28. Cui X, Chopp M, Zacharek A et al (2009) Chemokine, vascular and therapeutic effects of combination Simvastatin and BMSC treatment of stroke. Neurobiol Dis 361:35–41
29. Neamati A, Boskabady MH, Mohaghegh Hazrati S, Khakzad MR, Moosavi SH (2013) The effect of natural adjuvants (G2, G2F) on lung inflammation of sensitized guinea pigs. Avicenna J Phytomed 3:364–370
30. Bonfield TL, Koloze M, Lennon DP et al (2010) Human mesenchymal stem cells suppress chronic airway inflammation in the murine ovalbumin asthma model. Am J Physiol 299:760–770
31. Xu L, Dong XW, Shen LL et al (2012) Simvastatin delivery via inhalation attenuates airway inflammation in a murine model of asthma. Int Immunopharmacol 12:556–564
32. Kim DY, Ryu SY, Lim JE et al (2007) Anti-inflammatory mechanism of simvastatin in mouse allergic asthma model. Eur J Pharmacol 557:76–86
33. Kim SE, Thanh Thuy TT, Lee JH et al (2009) Simvastatin inhibits induction of matrix metalloproteinase-9 in rat alveolar macrophages exposed to cigarette smoke extract. Exp Mol Med 41:277–287
34. Braganza G, Chaudhuri R, McSharry C et al (2011) Effects of short-term treatment with atorvastatin in smokers with asthma–a randomized controlled trial. BMC Pulm Med 11:16