UC Davis
Dermatology Online Journal

Title
Two cases of mycosis fungoides diagnosed after treatment non-response to dupilumab

Permalink
https://escholarship.org/uc/item/1133121d

Journal
Dermatology Online Journal, 27(1)

Authors
Newsom, Megan
Hrin, Matthew L
Hamid, Ramiz N
et al.

Publication Date
2021

DOI
10.5070/D3271052041

License
https://creativecommons.org/licenses/by-nc-nd/4.0/ 4.0

Peer reviewed

eScholarship.org Powered by the California Digital Library
University of California

Two cases of mycosis fungoides diagnosed after treatment non-response to dupilumab

Megan Newsom[1] BS, Matthew L Hrin[1] BA, Ramiz N Hamid[1] MD MPH, Lindsay C Strowd[1] MD, Christine Ahn[1,2] MD, Joseph L Jorizzo[1,4] MD, Steven R Feldman[1-3,5] MD PhD

Affiliations: [1]Department of Dermatology, Wake Forest School of Medicine, Winston-Salem, North Carolina, USA, [2]Department of Pathology, Wake Forest School of Medicine, Winston-Salem, North Carolina, USA, [3]Department of Social Sciences & Health Policy, Wake Forest School of Medicine, Winston-Salem, North Carolina, USA, [4]Department of Dermatology, Weill Cornell Medicine, New York, New York, USA, [5]Department of Dermatology, University of Southern Denmark, Odense, Denmark

Corresponding Author: Steven R Feldman, Department of Dermatology, Wake Forest School of Medicine, 4618 Country Club Road, Winston Salem, NC 27104 , Tel: 336-716-7740, Fax: 336-716-7732, Email: sfeldman@wakehealth.edu

Keywords: dupilumab, eczematous, mycosis fungoides

To the Editor:
Atopic dermatitis is a common inflammatory skin disease characterized by skin barrier dysfunction and pruritus [1]. Dupilumab is a monoclonal antibody, targeting the IL4α receptor, indicated for the treatment of moderate-to-severe atopic dermatitis [2]. Mycoses fungoides (MF) is an indolent cutaneous T cell lymphoma that accounts for up to 80% of all cutaneous lymphoma [3]. However, MF is a rare disease with an estimated incidence in the United States of 0.3 to 1.02 new cases per 100,000 persons per year [3]. There is overlap in the clinical appearance of moderate-to-severe atopic dermatitis and MF [1,4]. Additionally, biopsies of MF lesions may fail to be diagnostic [4]. We report two patients, initially treated with dupilumab for severe AD, who were diagnosed with MF after treatment failure.

Case 1

A 48-year-old woman presented to our institution in October 2016 with a diffuse pruritic cutaneous eruption. The eruption first appeared six years prior and slowly spread down from her scalp. Her lesions were unresponsive to topical corticosteroid therapy. Examination demonstrated an exfoliate erythroderma worse on the bilateral legs, back, hands, face, and scalp (**Figure 1**). A lesional biopsy from her forearm was consistent with spongiotic dermatitis. Patch testing did not show evidence of allergic contact dermatitis. She was diagnosed with severe AD. After having minimal improvement on both methotrexate and ultraviolet (UV) light therapy, she was started on dupilumab. After five months of treatment non-response on dupilumab and methotrexate, another skin biopsy specimen was obtained revealing an infiltrate of atypical lymphocytes lining the epidermis (**Figure 2A)**. Immunohistochemistry demonstrated tumor cells that were $CD3^+$, $CD4^+$, $CD5^+$, $CD7^-$, $CD8^-$, $CD20^-$, and $CD30^-$ (**Figure 2B-2E)**. She was diagnosed with MF patch stage 1B.

Case 2

A 55-year-old man, with a five-year history of AD, presented in January 2020 for re-evaluation. He had a history of oropharyngeal cancer treated with radiation to the base of the tongue. Patch testing revealed no contactants and there had been no improvement with topical corticosteroids or UV light therapy. He was started on dupilumab, had no improvement, and discontinued the medication after six months. On physical examination, there

Figure 1. *Erythroderma over bilateral **A)** legs and **B)** back.*

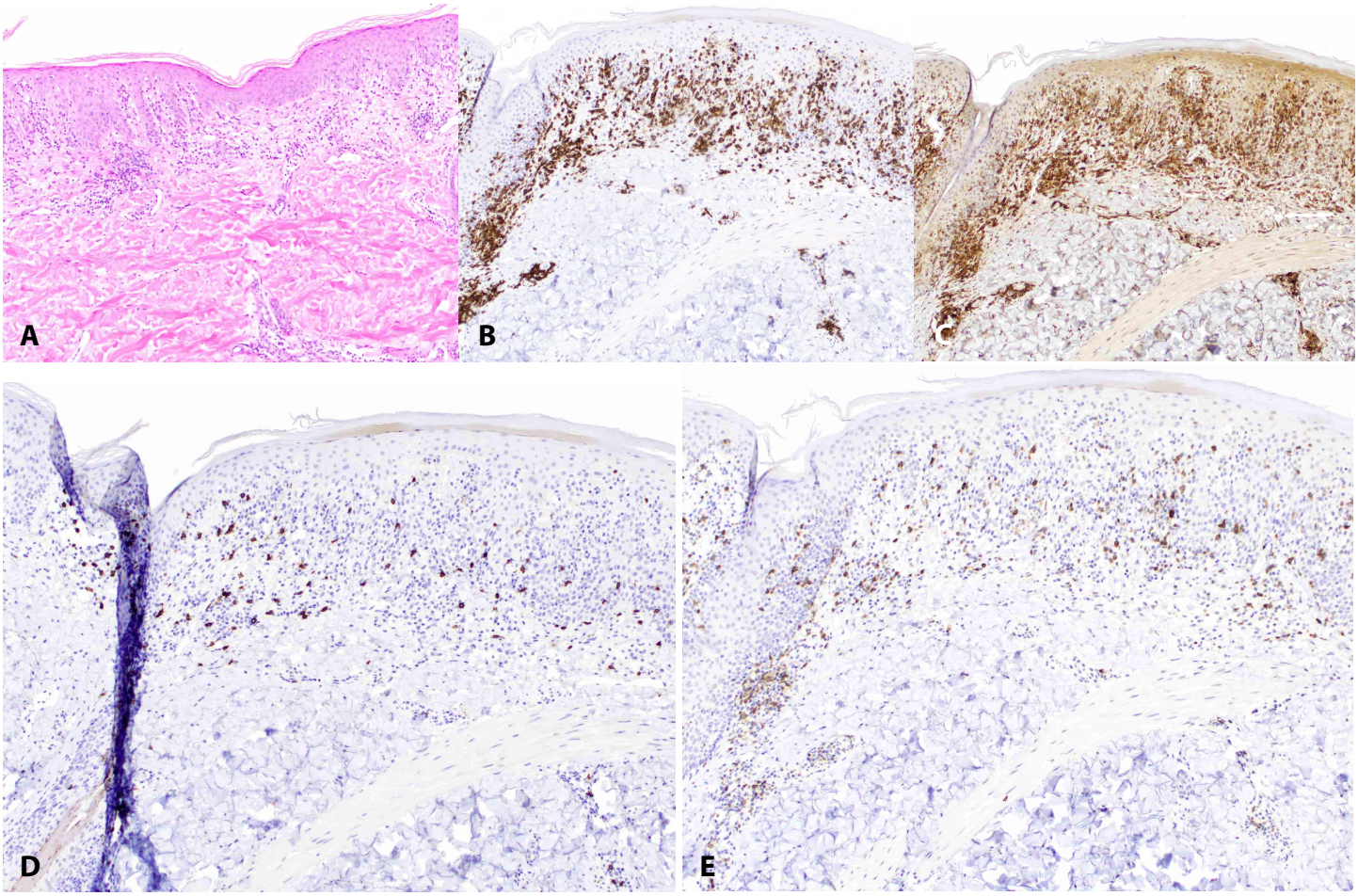

Figure 2. *Vacuolization at the epidermal basement membrane with lymphocytes lining the dermoepidermal junction and present within the epidermis. Superficial dermal infiltrate composed of atypical lymphocytes in a lichenoid and perivascular pattern.* ***A)*** *H&E, 10×.* ***B)*** *The atypical lymphocytes demonstrate strong cytoplasmic expression of CD3.* ***C)***, ***D)*** *Diminished expression of CD8, leading to an increased CD4:CD8 ratio, and* ***E)*** *diminished expression of CD7.*

were widespread hyper and hypopigmented patches (**Figure 3**). A biopsy of lesional skin contained a collection of atypical lymphocytes in the epidermis, fibrosis, and pigment incontinence. The tumor cells were $CD3^+$, $CD5^+$, with an increased CD4:CD8 ratio, decreased CD7 staining. There were rare $CD30^+$ cells, and cells were $CD20^-$ (**Figure 4A**, **B)**. He was diagnosed with stage 1B MF.

Discussion

Mycosis fungoides, the most common cutaneous lymphoma, is a T helper cell malignancy with an indolent clinical course [5]. Early MF presents as patches that evolve into plaques [6]. Later stage disease is characterized by tumors and spread outside of the skin [4].

Diagnosing early MF can be very challenging clinically. Mycosis fungoides lesions are heterogeneous and can imitate several inflammatory dermatoses including psoriasis, atopic dermatitis, parapsoriasis, superficial fungal infection, and many others [4,6]. Additionally, histopathologic specimens can be nonspecific and mimic patterns of inflammation seen in other diseases [4]. Early biopsy specimens are usually not diagnostic [4].

We report two patients with severe eczematous eruptions who failed to improve after five months of treatment with dupilumab. Dupilumab is an immunomodulator that targets a major inflammatory pathway in AD [7]. It is highly effective for atopic dermatitis. If patients with presumed atopic dermatitis are completely refractory to dupilumab, they may not have AD. These patients

Figure 3. *Diffuse hyper and hypopigmented patches over the back.*

highlight the importance of considering cutaneous lymphoma when treating inflammatory dermatoses that are recalcitrant to targeted immunotherapies.

Potential conflicts of interest

Steven Feldman has received research, speaking and/or consulting support from a variety of companies including Galderma, GSK/Stiefel, Almirall, Leo Pharma, Boehringer Ingelheim, Mylan, Celgene, Pfizer, Valeant, Abbvie, Samsung, Janssen, Lilly, Menlo, Merck, Novartis, Regeneron, Sa nofi, Novan, Qurient, National Biological Corporation, Caremark, Advance Medical, Sun Pharma, Suncare Research, Informa, UpToDate and National Psoriasis Foundation. He is founder and majority owner of www.DrScore.com and founder and part owner of Causa Research, a company dedicated to enhancing patients' adherence to treatment. Lindsay Strowd has received grants or support from Galderma, Pfizer, Actelion, and Sanofi Regeneron. The remaining authors have no conflicts to disclose.

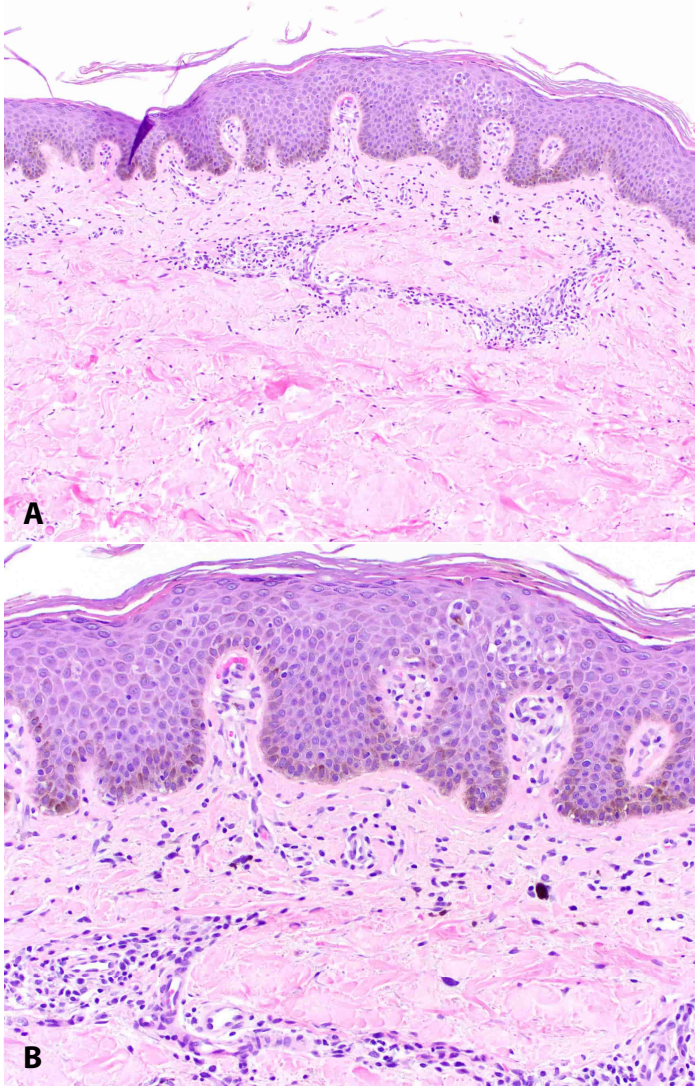

Figure 4. ***A)*** *Mild epidermal hyperplasia with superficial infiltrate composed of atypical, large lymphocytes with epidermotropism. H&E, 10×.* ***B)*** *Collections of atypical lymphocytes (Pautrier microabscesses) within the epidermis, papillary dermal fibrosis and pigmented incontinence. H&E, 20×.*

References

1. Silverberg JI. Atopic Dermatitis in Adults. *Med Clin North Am*. 2020;104:157-176. [PMID: 31757234].
2. Silverberg JI, Simpson EL, Ardeleanu M, et al. Dupilumab provides important clinical benefits to patients with atopic dermatitis who do not achieve clear or almost clear skin according to the Investigator's Global Assessment: a pooled analysis of data from two phase III trials. *Br J Dermatol*. 2019;181:80-87. [PMID: 30791102].
3. Amorim GM, Niemeyer-Corbellini JP, Quintella DC, Cuzzi T, Ramos ESM. Clinical and epidemiological profile of patients with early stage mycosis fungoides. *An Bras Dermatol*. 2018;93:546-552. [PMID: 30066762].

4. Beigi, Mohammad PK. Overview of Disorder. In: Clinician's Guide to Mycosis Fungoides. Beigi, Mohammad PK. Springer Verlag; 2017. p. 7-38.
5. Willemze R, Jaffe ES, Burg G, et al. WHO-EORTC classification for cutaneous lymphomas. *Blood*. 2005;105:3768-3785. [PMID: 15692063].
6. Kelati A, Gallouj S, Tahiri L, Harmouche T, Mernissi FZ. Defining the mimics and clinico-histological diagnosis criteria for mycosis fungoides to minimize misdiagnosis. *Int J Womens Dermatol*. 2017;3:100-106. [PMID: 28560304].
7. Silverberg JI, Kantor R. The Role of Interleukins four and/or 13 in the Pathophysiology and Treatment of Atopic Dermatitis. *Dermatol Clin*. 2017;35:327-334. [PMID: 28577802].