# Neutrophilic Generalized Fixed Drug Eruption Induced by Etoricoxib

Vera A[1], Freih A[2], Múgica MV[1], Vega F[1], Belver MT[1], Blanco C[1]
[1]*Allergy Department, Hospital Universitario de La Princesa; Instituto de Investigación Sanitaria del Hospital La Princesa (IP), Madrid, Spain*
[2]*Pathology Department, Hospital Universitario de La Princesa; Instituto de Investigación Sanitaria (IP) del Hospital La Princesa, Madrid, Spain*

J Investig Allergol Clin Immunol 2021; Vol. 31(6): 517-519
doi: 10.18176/jiaci.0687

Key words: Fixed drug eruption. Generalized bullous fixed drug eruption. Neutrophilic inflammatory infiltrate. Etoricoxib.

Palabras clave: Exantema fijo medicamentoso. Exantema fijo medicamentoso ampolloso generalizado. Infiltrado inflamatorio neutrofílico. Etoricoxib.

Fixed drug eruption (FDE) is a type 4 hypersensitivity reaction involving lymphocytic infiltration of the affected skin. It is characterized by recurrent lesions at the same site after re-exposure to the drug. The generalized bullous presentation of FDE (GBFDE) is a rare variant that is characterized by generalized bullae accompanying the distinctive FDE lesions. It can resemble Stevens-Johnson syndrome (SJS), although it is usually less severe and is not accompanied by systemic symptoms [1].

In recent years, the use of selective COX-2 inhibitor nonsteroidal anti-inflammatory drugs (NSAIDs) has increased worldwide, and FDE induced by selective COX-2 inhibitors has been reported [2-5]. We present 2 cases with specific characteristics that suggest a different kind of potentially severe etoricoxib-induced GBFDE.

The first patient was a 43-year-old woman who developed 2 cutaneous lesions in the form of hyperpigmented plaques with peripheral erythema over her left buttock (5 cm) and right wrist (3 cm) 1 day after the intake of ibuprofen 600 mg and 30 minutes after taking etoricoxib 60 mg, which were administered for a wrist injury. The skin lesions progressed to blisters and resolved after treatment with oral corticosteroids in 2-3 weeks. Two months later, she took etoricoxib 60 mg, and both skin lesions reappeared after 30 minutes, together with 5 new similar lesions on her trunk and upper limbs. The lesions resolved in 10 days with oral corticosteroids, although residual hyperpigmentation remained.

The patient gave her informed consent to undergo an allergy study 2 months after her symptoms had resolved. Patch tests performed with etoricoxib (10% in petrolatum) on both the residual pigmented lesion and healthy skin yielded negative results. A single-blind oral drug challenge test (DCT) with etoricoxib 60 mg was then carried out, and the skin lesions reappeared 30 minutes later, as did new lesions on the neck, trunk, upper and lower limbs, and genital

© 2021 Esmon Publicidad

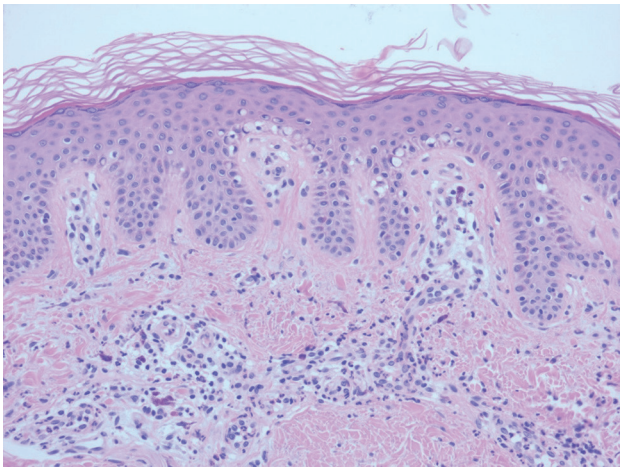

**Figure.** Histopathology of the lesion on the left buttock after a challenge with etoricoxib. Findings include vacuolar alteration of the basal layer, with both superficial and deep dermal neutrophilic inflammatory infiltrate and scattered melanophages. Hematoxylin-eosin, ×400.

area. Skin biopsy revealed a perivascular dermatitis pattern with neutrophilic inflammation of the papillary dermis and scattered melanophages (Figure). The patient was treated with oral corticosteroids, and her lesions improved in 7 days (Supplementary Figure 1). DCT with ibuprofen 600 mg revealed good tolerance. Finally, to confirm selective allergy to etoricoxib, additional DCTs were performed on separate days with acetaminophen 1 g, acetylsalicylic acid 500 mg, and celecoxib 200 mg, all of which yielded negative results.

The second patient was a 48-year-old woman who developed a generalized rash characterized by erythematous-macular lesions on the abdomen, neck, and upper and lower limbs, including the left ankle. These progressed to bullous lesions, with neither mucosal involvement nor systemic symptoms. Skin lesions appeared 1 week after a diclofenac injection and 1-2 hours after oral intake of etoricoxib, which had been administered for shoulder pain. She had previously been treated with both drugs, reporting 1 transient hyperpigmented lesion on her left ankle that she did not think was associated with this treatment. The initial diagnosis was SJS, although the blood test results were within normal limits and a subsequent biopsy showed epithelial erosion with intense neutrophilic inflammation of the papillary dermis. The lesions resolved fully in 10 days with oral corticosteroids.

Once the patient gave her informed consent, patch testing with etoricoxib was performed on the previous lesional and healthy skin. The results were negative. DCTs with ibuprofen (600 mg), diclofenac (50 mg), and celecoxib (200 mg) were also negative. DCT with etoricoxib was not performed because it is contraindicated in the case of GBFDE. The final diagnosis was GBFDE induced by hypersensitivity to etoricoxib. The patient was advised to avoid etoricoxib. Her skin lesions have not recurred to date.

We report on 2 patients with etoricoxib-induced FDE that progressed to GBFDE after re-exposure to the drug. In this case, GBFDE is a selective allergy, since both patients tolerated celecoxib and other NSAIDs. Of note, the rare neutrophilic inflammatory pattern observed in both cases suggests a new condition that differs from classic FDE. The differential diagnosis was made with other bullous disorders and with neutrophilic dermatoses, such as drug-related Sweet syndrome [6].

FDE is characterized by recurrence of lesions at the same site after re-exposure to the drug, without mucosal involvement. The patient's good general status in GBFDE contrasts with the severe systemic toxicity of SJS [1]. Challenge testing is the gold standard diagnostic procedure for FDE, although it is contraindicated in GBFDE, and this is the reason why the second patient in the present study was not challenged with etoricoxib. Patch testing on both affected and healthy skin is a safer alternative for identifying the offending drug, although a negative result—as in the present cases—does not rule out the diagnosis [7].

Biopsy helps to rule out other dermatoses but is not specific. The typical histology of FDE consists of a perivascular lymphocytic infiltrate with melanophages. It is sometimes indistinguishable from SJS, with clinical features being the main diagnostic support [1]. However, both the cases we report involved extensive neutrophil infiltration, a rare FDE pattern that has been previously reported in association with various drugs, but never with selective COX-2 inhibitors [8].

We might postulate that the presence of a neutrophilic infiltrate in an FDE lesion is no more than an early phase of inflammation. However, sequential biopsies after DCT show that the lymphocytic infiltrate is present even in early biopsies, whereas a neutrophilic infiltrate is not present in typical FDE [9]. The latency periods observed in the cases we report were similar to those observed in an immediate reaction (minutes to 1-2 hours), possibly because of the involvement of neutrophils, whereas FDE is usually characterized by a longer latency period.

Of the few previous reports on etoricoxib-induced FDE [2-5], only 1 corresponded to GBFDE [5]. None involved a neutrophilic infiltrate. Nevertheless, etoricoxib-induced FDE may be more frequent than supposed and may be associated with genetic predisposition [10].

Previous articles have reported possible cross-reactivity between etoricoxib and celecoxib based on patch test results. However, DCT showed that etoricoxib did not cross-react with celecoxib and parecoxib in a case of FDE [3]. In line with this result, both patients we report tolerated celecoxib, probably because of the structural differences between these drugs [3,4].

In conclusion, etoricoxib can induce a specific selective and potentially severe form of FDE characterized by a neutrophilic infiltrate that can progress to a generalized form. Given that selective COX-2 inhibitors are increasingly used, more cases of GBFDE due to etoricoxib should be expected.

*Funding*

The authors declare that no funding was received for the present study.

*Conflicts of Interest*

The authors declare that they have no conflicts of interest.

 © 2021 Esmon Publicidad

## References


1. Mitre V, Applebaum DS, Albahrani Y, Hsu S. Generalized bullous fixed drug eruption imitating toxic epidermal necrolysis: a case report and literature review. Dermatol Online J. 2017;23:1-4.
2. Movsisyan M, Fiandor A, González-Muñoz M, Quirce S, Bellón T, Hakobyan A, et al. The Lymphocyte Transformation Test Is Useful in the Diagnosis of Fixed Drug Eruption Induced by Etoricoxib. J Investig Allergol Clin Immunol. 2019;29:307-9.
3. Ponce V, Muñoz-Bellido F, Moreno E, Laffond E, González A, Dávila I. Fixed drug eruption caused by etoricoxib with tolerance to celecoxib and parecoxib. Contact Dermatitis. 2012;66:107-8.
4. Carneiro-Leão L, Rodrigues Cernadas J. Bullous Fixed Drug Eruption Caused by Etoricoxib Confirmed by Patch Testing. J Allergy Clin Immunol Pract. 2019;7:1629-30.
5. Duarte AF, Correia O, Azevedo R, Palmares MC, Delgado L. Bullous fixed drug eruption to etoricoxib further evidence of intraepidermal CD8+ T cell involvement. Eur J Dermatol. 2010;20:236-8.
6. Walker DC, Cohen PR. Trimethoprim-sulfamethoxazole-associated acute febrile neutrophilic dermatosis: case report and review of drug-induced Sweet's syndrome. J Am Acad Dermatol. 1996;34(5):918-23.
7. Andrade P, Brinca A, Gonçalo M. Patch testing in fixed drug eruptions-a 20-year review. Contact Dermatitis. 2011;65:195-201.
8. Suzuki S, Ho J, Rosenbaum M, Bhawan J. Neutrophilic fixed drug eruption: a mimic of neutrophilic dermatoses. Clin Exp Dermatol. 2019;44:236-8.
9. Mizukawa Y, Yamazaki Y, Shiohara T. In vivo dynamics of intraepidermal CD8+ T cells and CD4+ T cells during the evolution of fixed drug eruption. Br J Dermatol. 2008;158:1230-8.
10. Heng YK, Yew YW, Lim DS, Lim YL. An update of fixed drug eruptions in Singapore. J Eur Acad Dermatol Venereol. 2015;29:1539-44.


*Manuscript received November 5, 2020; accepted for publication March 12, 2021.*

**Andrea Vera**
Hospital Universitario de la Princesa
Diego de León, 62
28006 Madrid, Spain
E-mail: andrea.vera.flores1981@gmail.com

© 2021 Esmon Publicidad 

**SUPPLEMENTARY MATERIAL**

**Figure S1.** Case #1, hyperpigmented residual lesion in left butt-cheek, 30 days after DCT with etoricoxib. DCT, drug challenge-test.

 © 2021 Esmon Publicidad
doi: 10.18176/jiaci.0687