Toxicologic Pathology

http://tpx.sagepub.com

Asthma/Allergic Airways Disease: Does Postnatal Exposure to Environmental Toxicants Promote Airway Pathobiology?

Charles G. Plopper, Suzette M. Smiley-Jewell, Lisa A. Miller, Michelle V. Fanucchi, Michael J. Evans, Alan R. Buckpitt, Mark Avdalovic, Laurel J. Gershwin, Jesse P. Joad, Radhika Kajekar, Shawnessy Larson, Kent E. Pinkerton, Laura S. Van Winkle, Edward S. Schelegle, Emily M. Pieczarka, Reen Wu and Dalla M. Hyde

Toxicol Pathol 2007; 35; 97

DOI: 10.1080/01926230601132030

The online version of this article can be found at:
http://tpx.sagepub.com/cgi/content/abstract/35/1/97

Published by:
SAGE Publications
http://www.sagepublications.com

On behalf of:
Society of Toxicologic Pathology

Additional services and information for *Toxicologic Pathology* can be found at:

Email Alerts: http://tpx.sagepub.com/cgi/alerts

Subscriptions: http://tpx.sagepub.com/subscriptions

Reprints: http://www.sagepub.com/journalsReprints.nav

Permissions: http://www.sagepub.com/journalsPermissions.nav

Citations (this article cites 33 articles hosted on the SAGE Journals Online and HighWire Press platforms):
http://tpx.sagepub.com/cgi/content/refs/35/1/97

Downloaded from http://tpx.sagepub.com at Instituto Superiore Di Sanita on June 20, 2008
© 2007 Society of Toxicologic Pathology. All rights reserved. Not for commercial use or unauthorized distribution.

Toxicologic Pathology, 35:97–110, 2007
Copyright © by the Society of Toxicologic Pathology
ISSN: 0192-6233 print / 1533-1601 online
DOI: 10.1080/01926230601132030

Asthma/Allergic Airways Disease: Does Postnatal Exposure to Environmental Toxicants Promote Airway Pathobiology?

CHARLES G. PLOPPER,[1,6] SUZETTE M. SMILEY-JEWELL,[1,6] LISA A. MILLER,[1,6] MICHELLE V. FANUCCHI,[1,6] MICHAEL J. EVANS,[1,6] ALAN R. BUCKPITT,[2,6] MARK AVDALOVIC,[5,6] LAUREL J. GERSHWIN,[3] JESSE P. JOAD,[4] RADHIKA KAJEKAR,[1,6] SHAWNESSY LARSON,[1] KENT E. PINKERTON,[1,4,6] LAURA S. VAN WINKLE,[1,6] EDWARD S. SCHELEGLE,[1,6] EMILY M. PIECZARKA,[1] REEN WU,[1,5] AND DALLA M. HYDE[1,6]

[1]*Department of Anatomy, Physiology, and Cell Biology;* [2]*Molecular Biosciences and* [3]*Pathology Microbiology and Immunology, School of Veterinary Medicine;* [4]*Departments of Pediatrics and* [5]*Medicine, School of Medicine; and* [6]*California National Primate Research Center, University of California, Davis, CA 95616, USA*

ABSTRACT

The recent, dramatic increase in the incidence of childhood asthma suggests a role for environmental contaminants in the promotion of interactions between allergens and the respiratory system of young children. To establish whether exposure to an environmental stressor, ozone (O_3), and an allergen, house dust mite (HDMA), during early childhood promotes remodeling of the epithelial-mesenchymal trophic unit (EMTU) of the tracheobronchial airway wall by altering postnatal development, infant rhesus monkeys were exposed to cyclic episodes of filtered air (FA), HDMA, O_3, or HDMA plus O_3. The following alterations in the EMTU were found after exposure to HDMA, O_3, or HDMA plus O_3: (1) reduced airway number; (2) hyperplasia of bronchial epithelium; (3) increased mucous cells; (4) shifts in distal airway smooth muscle bundle orientation and abundance to favor hyperreactivity; (5) interrupted postnatal basement membrane zone differentiation; (6) modified epithelial nerve fiber distribution; and (7) reorganization of the airway vascular and immune system. Conclusions: cyclic challenge of infants to toxic stress during postnatal lung development modifies the EMTU. This exacerbates the allergen response to favor development of intermittent airway obstruction associated with wheeze. And, exposure of infants during early postnatal lung development initiates compromises in airway growth and development that persist or worsen as growth continues, even with cessation of exposure.

Keywords. Asthma; children; environment; ozone; allergen; Macaca.

INTRODUCTION

Asthma is a health problem affecting both developed and developing countries. As of 2000, it was estimated that 100 to 150 million people have the disease worldwide (World Health Organization, 2000). The economic impact of asthma is quite high. In the United States alone, direct and indirect health care costs have been estimated to be 16.1 billion dollars (American Lung Association, 2005). The disease is characterized by chronic inflammation, impaired airflow, and remodeling of the airways, coupled with breathlessness and wheezing. Asthma often develops in childhood when the lung is still maturing. In the United States, asthma is the most prevalent chronic disorder of children (American Lung Association, 2005). Unfortunately, asthma early in life leads to a deficiency in pulmonary function that may not return to normal in adulthood, even if the asthmatic becomes asymptomatic (Gold et al., 1994). Because of the detrimental effect of asthma, there is a great deal of work being done to understand how it develops. The purpose of this review is to discuss which early life influences may affect airway structure and function and how postnatal exposure to an air pollutant, ozone, may alter airway development leading to the development of asthma.

One of the factors contributing to asthma susceptibility may be the long maturation period of the lung. Although the human lung needs to be sufficiently formed at birth to perform its primary function of gas exchange, lung development continues for an extensive period (8–12 years) after birth (Burri, 1997), and lung function continues to change in adolescence (Gauderman et al., 2004). Driven by increases in body size and associated metabolic demands, multifold increases in overall size, active cellular differentiation, cell division, and alveolar formation all occur during the 8–12 year period of postnatal lung development (Fanucchi and Plopper, 2004).

The growth of the parenchymal gas exchange area has been well characterized during this time period (Massaro and Massaro, 1996; McGowan and Synder, 2004), yet the same is not the case for the conducting airways where asthma manifests itself. Cudmore et al. (1962) and Phalen et al. (1978, 1985) conducted detailed, quantitative studies of lung casts from a limited number of humans at various postnatal ages. Both groups produced linear regressions that suggest that as body size increases there is a corresponding increase in airway diameter and length. The airways consist of epithelium, mucus-producing glands, cartilage, fibroblasts, nerves, interstitial vasculature, extracellular matrix, immune cells, and smooth muscle cells.

As the airways change in size and increase in surface area, there must be active transformation of all of these components

Address correspondence to: Charles G. Plopper, California National Primate Research Center, 1 Shields Avenue, University of California, Davis, CA, 95616 USA; e-mail: cgplopper@ucdavis.edu or smsmiley@ucdavis.edu

Abbreviations: HDMA, house dust mite allergen; EMTU, epithelial-mesenchymal trophic unit; BMZ, basement membrane zone; VEGF, vascular endothelial growth factor; O_3, ozone; FA, filtered air.

Downloaded from http://tpx.sagepub.com at Instituto Superiore Di Sanita on June 20, 2008
© 2007 Society of Toxicologic Pathology. All rights reserved. Not for commercial use or unauthorized distribution.

within the airway wall. The process by which airways grow is not well delineated, especially in regard to the organization of the 3-dimensional architecture and the mesenchymal components of the airway wall. Because asthma involves remodeling of the airway wall, such as thickening of the reticular basement membrane and increases in smooth muscle, it would be helpful if more information was known about how the individual components of the airways develop during childhood and adolescence. This type of information would assist us in understanding how normal developmental events are changed to cause asthma.

For example, while atopic infants with reversible airflow obstruction do not have reticular basement membrane thickening similar to adults (Payne et al., 2003; Saglani et al., 2005), older asthmatic children (6–16 years) do have reticular basement membrane thickening. At what point along the continuum of airway development from infancy to childhood does the basement membrane change and when is the change irreversible and related to compromised airway function?

Asthma is thought to be caused by a combination of ongoing lung development, genes (not discussed here) and environmental factors resulting in the alteration of the normal development and function of the lung (Holt et al., 2004). The longer period of human lung maturation (pre- and postnatally) provides ample time for normal lung development to be challenged and perturbed. Environmental factors associated with disturbing normal postnatal lung growth and development include pathogens, such as the respiratory syncytial virus (Lemanske, 2004); allergens, such as from house dust mites (Sporik et al., 1992; Richardson et al., 2005; Thorne et al., 2005); endotoxin (Thorne et al., 2005); and environmental air pollutants, such as oxidant gases, particles, acid vapor, elemental carbon, and cigarette smoke (Tager et al., 1983; Frischer et al., 1999; Peters et al., 1999a, 1999b). Children, especially those living in urban areas, are often exposed to many, if not all of these factors. Numerous epidemiologic studies have demonstrated an association between children living in major industrialized urban areas (e.g., Los Angeles or Mexico City) and the development of childhood respiratory diseases and decreased lung function (Romieu et al., 1996; Peters et al., 1999a, 1999b; Calderon-Garciduenas et al., 2003; Gauderman et al., 2004). These studies demonstrate that the lung is especially sensitive to noxious stimuli during postnatal lung development.

This review summarizes how we have addressed the following two key questions regarding the potential for the development of allergic airways disease in infants and how polluted air environments may influence susceptibility. First, does repeated exposure to environmental contaminants alter postnatal growth and development? Second, does removal from contaminated air reverse the response?

EXPERIMENTAL MODEL FOR ENVIRONMENTAL POSTNATAL AIRWAYS DISEASE

To define how environmental contaminants may influence the ability of developing lungs to resist the impact of allergens and other contaminants, we developed a model of allergic airways disease in the adult rhesus monkey (Schelegle et al., 2001) that reflects all the criteria used by the National Heart, Lung, and Blood Institute's (NHLBI) National Asthma Education and Prevention Program Clinical Practice Guidelines. Based on the NHLBI definition, we found that asthma can be produced in rhesus monkeys following exposure to house dust mite allergen (HDMA) (Schelegle et al., 2001). The monkeys develop a positive skin test for HDMA, with elevated levels of IgE in the serum and IgE-positive cells within the tracheobronchial airway walls.

The animals exhibit impaired airflow after the inhalation of aerosolized allergen that is associated with cough, rapid shallow breathing, and decreased arterial oxygen saturation, all of which are reversible by treatment with aerosolized albuterol. Further, serum histamine concentrations are elevated in sensitized monkeys after allergen exposure. In sensitized monkeys, shed epithelial cells are detectable in bronchoalveolar lavage immediately after allergen aerosol challenge. As with human asthmatics, the majority of the shed cells are ciliated cells. Immune cells, especially eosinophils, increase markedly in abundance in airway exudates and bronchoalveolar lavage. There are also elevations in CD 25 expression on CD 4+ lymphocytes in both lavage and serum.

The animals develop nonspecific airways responsiveness, which is reflected as a fourfold reduction in the dose of histamine aerosol required to produce a 150% increase in airway resistance. There is marked mucous cell hyperplasia accompanied by general epithelial hypertrophy in both intra- and extrapulmonary conducting airways. The basement membrane zone is markedly thickened in most of the intrapulmonary bronchi. This thickened basement membrane zone appears to be characteristic of conducting airways only in primate asthma models and plays a key role in modulating signaling within the airway wall. There are marked accumulations of eosinophils in both the epithelial and subepithelial matrix compartments as well. All of these histological features are focal and distributed throughout the conducting airway trees.

One of the reasons for choosing the rhesus monkey as a model for these studies is the organization of the tracheobronchial airway tree (Figure 1; Plopper and Harkema, 2005). The branching pattern and distribution of airways in the rhesus monkey are more similar to humans than rodents are to humans. The transition zone between the gas exchange area and the conducting airways is very different in primates, both human and nonhuman, than it is in laboratory rodents. Specifically, the extensive transition zone in primates includes a substantial number of branches with alveolarized tissue on one side for gas exchange and mucociliary epithelium on the other side. In laboratory rodents, this transition occupies only one branch of airway at the most.

The experimental protocol that we have used to evaluate the susceptibility of developing lungs in postnatal rhesus monkeys includes beginning exposure early during the postnatal period (30 days after birth) and ending at approximately 6 months of age (Schelegle et al., 2003b). The standard five month exposure protocol involves repeated cycles of exposure to ozone (O_3), 5 days in succession followed by 9 days in filtered air (FA), at a concentration resembling that of Mexico City (0.5 ppm, 8 hours/day). The allergen exposure, using HDMA, is for approximately 3 days (2 hours per day)

Downloaded from http://tpx.sagepub.com at Instituto Superiore Di Sanita on June 20, 2008
© 2007 Society of Toxicologic Pathology. All rights reserved. Not for commercial use or unauthorized distribution.

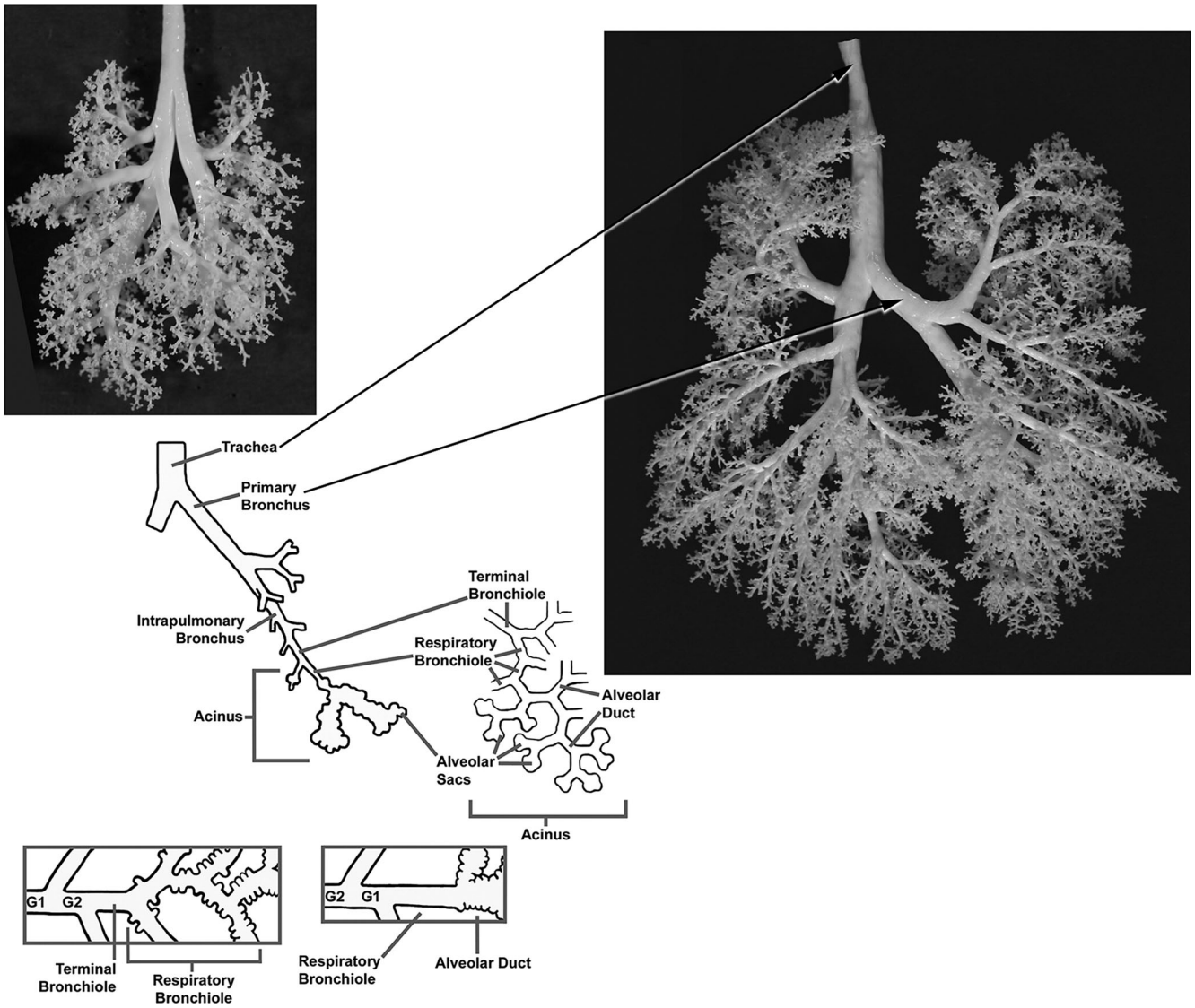

FIGURE 1.—Comparison of the architecture of the airspaces in the mammalian respiratory system, including trachea, primary bronchi, intrapulmonary bronchi, bronchioles, and the acinus. The organization of the tracheobronchial airways as represented by silicon casts of a rat (left) and rhesus monkey (right). In addition to differences in size and branching pattern, the transition zone between the most distal conducting airway, the terminal bronchiole, and the gas exchange area varies between species with an extensive transition zone represented by multiple generations of respiratory bronchioles in primates and a short or single generation of respiratory bronchioles in laboratory rodents. (Adapted from Plopper and Harkema, 2005).

followed by 11 days of FA. The 3 days of allergen exposure are conducted on the last 3 days of O_3 exposure. Animals are housed in a FA environment and then exposed to O_3, HDMA, or a combination for up to 11 cycles.

To evaluate the potential for recovery, we have followed the 5 months of exposure with another 6 months in FA until the monkeys are 12 months of age. Each study has a group of animals that are housed in a FA environment for the entire period of this study.

Physiologic and Immunologic Responses

Infant animals exposed to HDMA alone have increases in baseline airway resistance (Figure 2; Schelegle et al., 2003b). O_3 plus HDMA more than doubles baseline resistance. A similar pattern occurs with nonspecific airways hyperresponsiveness to histamine (Figure 3); the combination of O_3 and HDMA greatly elevates the responsiveness. We have observed increases in eosinophils in bronchoalveolar lavage in response to O_3 but not to HDMA in the infant rhesus monkeys (Schelegle et al., 2003b). However, the combination exposure greatly increases the abundance of eosinophils in bronchoalveolar lavage (Figure 4).

Airway Growth

To evaluate the extent of remodeling, or alterations in airway development and growth, we use a sampling method in which we microdissect open the conducting airway tree in fixed lungs, count each airway branch, and identify each

Downloaded from http://tpx.sagepub.com at Instituto Superiore Di Sanita on June 20, 2008
© 2007 Society of Toxicologic Pathology. All rights reserved. Not for commercial use or unauthorized distribution.

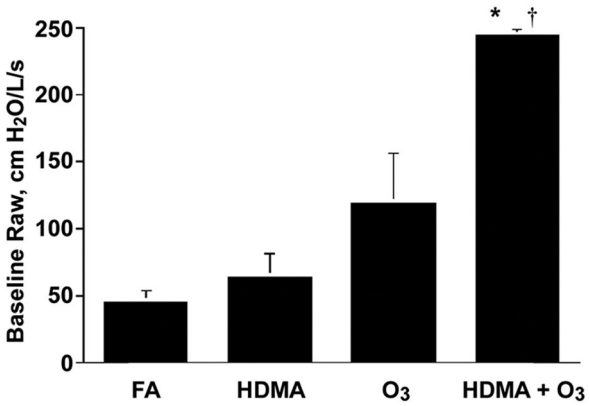

FIGURE 2.—Comparison of baseline airway resistance (Raw) in infant rhesus monkeys (120 days of age) following 6 cycles of exposure to filtered air (FA), house dust mite allergen (HDMA), ozone (O_3) or both (HDMA+O_3). Airway resistance was obtained by the transfer impedance method (Schelegle et al., 2001, 2003). Mean ± S.E. (Adapted from Schelegle et al., 2003.) $^*p < 0.05$ compared to FA. + $p < 0.05$ compared to HDMA.

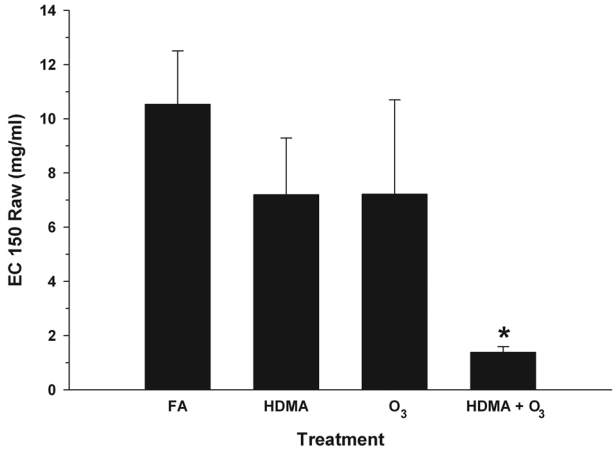

FIGURE 3.—Comparison of the concentration of histamine required to produce a 150% increase in airway resistance (EC 150 Raw) in infant rhesus monkeys (180 days of age) following 10 cycles of exposure to filtered air (FA), house dust mite allergen (HDMA), ozone (O_3) or both (HDMA+O3). Airway resistance was obtained by the transfer impedance method (Schelegle et al., 2001, 2002). Mean ± S.E. (Adapted from Schelegle et al., 2003.) $^*p < 0.05$ compared to FA.

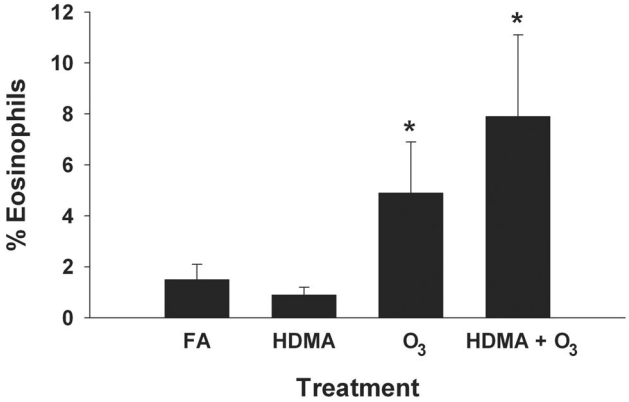

FIGURE 4.—Comparison of the percentage of eosinophils found in bronchoalveolar lavage from infant rhesus monkeys (180 days of age) following 11 cycles of exposure to filtered air (FA), house dust mite allergen (HDMA), ozone (O_3) or both (HDMA+O_3). Mean ± S.E. (Adapted from Schelegle et al., 2003.) $^*p < 0.05$ compared to FA; + $p < 0.05$ compared to HDMA.

sample taken from the lung based on its branching history (Plopper, 1990). One of the most striking features that we have observed with remodeling of the airways in infant rhesus monkeys is changes in normal growth. As illustrated in Figure 5, the airways increase by a third in diameter and by twice in length between 1 month of age and 6 months of age (Tran et al., 2004a). The growth pattern of distal airways is exacerbated to a mild extent by exposure to HDMA alone, but is very markedly changed by exposure to O_3 or a combination of HDMA and O_3. The combination exposure inhibits growth in diameter, yet promotes lengthwise growth.

This combination results in longer, narrower airways with higher intrinsic theoretically calculated resistance. Exposure to O_3 causes infant monkeys to have a decrease in the number of conducting airway generations between the trachea and the gas exchange area, as represented by the location of the most proximal respiratory bronchiole (Fanucchi et al., 2006). We counted the number of generations to the first respiratory bronchiole in 4 different lobes of fixed lungs and found a reduction of as many as 6 generations of conducting airways following exposure to O_3 with or without HDMA (Figure 6). A recovery period of an additional 6 months of FA did not have a substantial impact on recouping the number of airway generations that were lost (Figure 6).

THE EPITHELIAL MESENCHYMAL TROPHIC UNIT (EMTU)

The concept of the epithelial-mesenchymal trophic unit (EMTU) was developed as a framework for defining the cellular and metabolic mechanisms regulating the response to injury in a complex biological structure, such as the tracheobronchial airway tree, and for identifying the mechanisms that regulate airway remodeling in allergic airways disease (Figure 7; Evans et al., 1999; Holgate et al., 2000). The EMTU is made up of several tissue compartments.

The epithelial compartment of the airway wall is comprised of surface epithelium and submucosal glands. The interstitial compartment includes the basement membrane zone, smooth muscle, cartilage and vasculature. The nervous compartment includes the afferent and efferent nerve processes that interdigitate between the smooth muscle, the subepithelial matrix and the epithelium, and the regulating neurons of the ganglia and brain stem. The vascular compartment includes capillaries; arterioles and venules, primarily from the bronchial circulation; and lymphatic vessels. The immune compartment includes both inflammatory cells and migratory cells involved in the regulation of immune responses.

Functionally, the EMTU is based on the assumption that the various compartments of the airway actively interact with each other, i.e., the biological function of cells in one compartment is regulated by the functions of the cell populations in the other compartments, and when one compartment is injured the others also respond. In the steady state, these compartments establish a baseline trophic interaction that is disrupted during acute injury and repair and is reset by successive cycles of injury, inflammation and repair, which is characteristic of chronic airways diseases, such as asthma. In addition, we believe that each airway segment, or generation, within the branching architecture of the tracheobronchial airways is a unique biological entity whose properties may differ

Downloaded from http://tpx.sagepub.com at Instituto Superiore Di Sanita on June 20, 2008
© 2007 Society of Toxicologic Pathology. All rights reserved. Not for commercial use or unauthorized distribution.

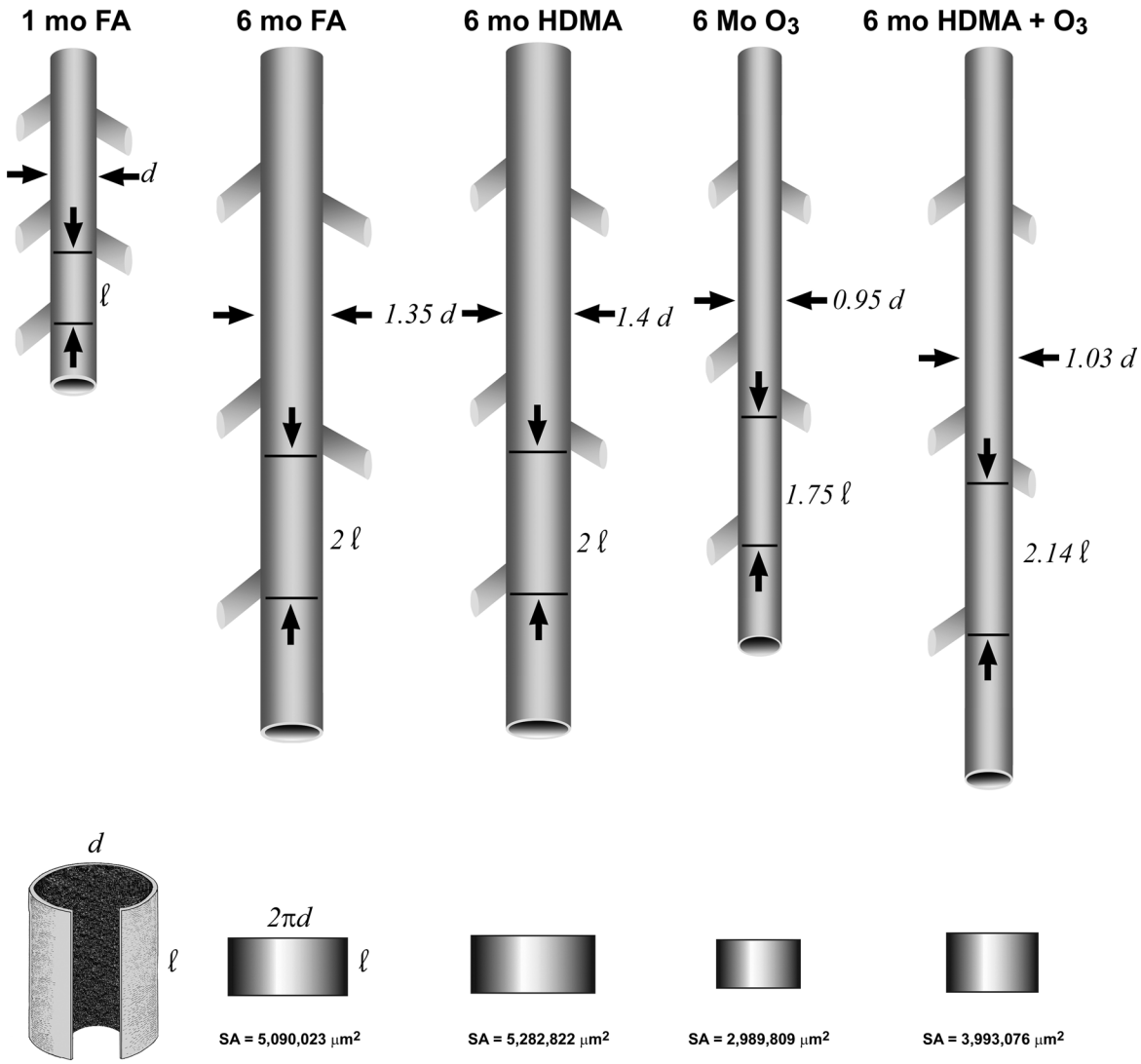

FIGURE 5.—Diagrammatic comparison of differences in the size of one generation of distal bronchiole in the left cranial lobe of infant rhesus monkeys (180 days of age) following 11 cycles of exposure to filtered air (FA), house dust mite allergen (HDMA), ozone (O_3) or both (HDMA+O_3). The airway measured is the bronchiole proximal to the terminal bronchiole in the axial airway path of the caudal segment of the left cranial lobe of each animal. Relative scaling for length (l) and diameter (d) is based on setting the value for 30-day-old animals (the time when the exposures started) equal to"1." Luminal surface area (SA) was calculated from the values measured directly on airway to sections.

from those of neighboring branches and that all the components of the airway wall, both cellular and acellular, play a role in both injury and repair responses.

Airway Epithelium

The epithelium of tracheobronchial airways in rhesus monkeys develops both prenatally and postnatally (Plopper and Harkema, 2005). Epithelial development includes increases in the phenotypes of cells that are present, transitioning from a simple columnar epithelium filled with glycogen to a ciliated and nonciliated epithelium, and finally to an epithelium that includes a basal cell population. While most of this differentiation occurs prenatally, a substantial part of the mucous cell differentiation, particularly in distal airways, occurs postnatally (Plopper and Harkema, 2005).

Exposure of infant monkeys to O_3 and HDMA from 1 to 6 months of age modifies the conducting airway epithelium by increasing the number and size of mucous cells and by incorporation of a large number of eosinophils into the luminal epithelium (Figure 8). If these same animals are subsequently exposed to FA for 6 months, the now 12-month-old animals reestablish an almost steady-state mucous cell composition in proximal airways, but the organization of the airway epithelium is significantly disrupted (Figure 9). In more distal airways (Figure 10), there is a dramatic increase in mucous cell abundance in response to exposure to O_3, HDMA, or O_3 and HDMA, (Schelegle et al., 2003b). There is also mucous and nonmucous cell hyperplasia in respiratory bronchioles and a disruptive change in the relationship between alveolar tissue and nonalveolarized aspects of the airway wall (Fanucchi et al., 2006).

Downloaded from http://tpx.sagepub.com at Instituto Superiore Di Sanita on June 20, 2008
© 2007 Society of Toxicologic Pathology. All rights reserved. Not for commercial use or unauthorized distribution.

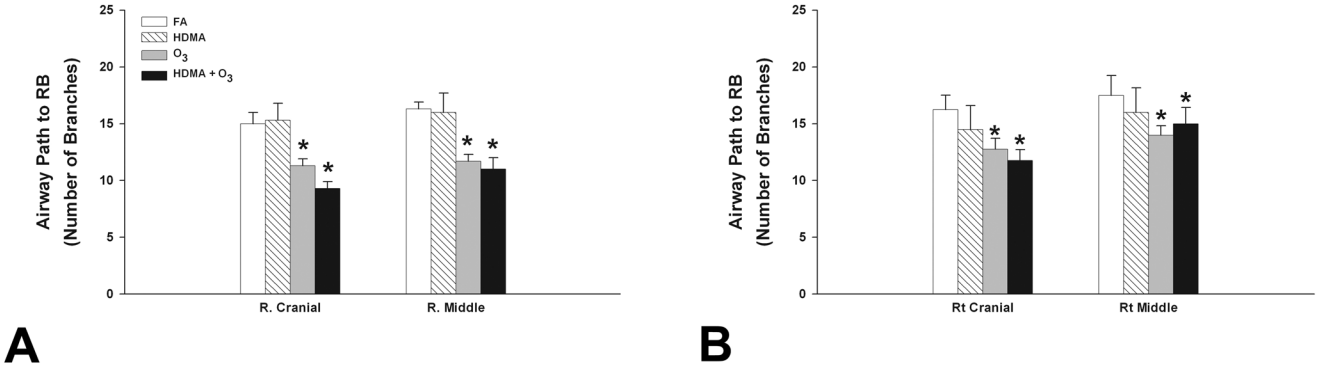

FIGURE 6.—Comparison of the number of generations of branching from the trachea to the respiratory bronchiole (RB) in infant rhesus monkeys. The axial path of the intrapulmonary airways in the right cranial (R. Cranial) and right middle (R. Middle) lobes were exposed by microdissection and the branching counted directly in the fixed lung. (A) Rhesus monkeys (180 days of age) following 11 cycles of exposure to filtered air (FA), house dust mite allergen (HDMA), ozone (O_3) or both (HDMA+O3). (B) Rhesus monkeys (1 year of age) after 6 months exposure to filtered air subsequent to 11 cycles of exposure to filtered air (FA), house dust mite allergen (HDMA), ozone (O_3) or both (HDMA+O_3). Mean ± 1 standard deviation. $^*p < 0.05$ compared to FA.

Basement Membrane Zone

The basement membrane zone (BMZ) of the tracheobronchial airway wall organizes and develops postnatally (Evans et al., 2002). At the time of birth of the rhesus monkey, the BMZ beneath the tracheobronchial epithelium is a thin sheet representing the basal lamina. During the first 6 months to 1 year of life, this zone grows and changes with the addition of new matrix components and an increase in the overall thickness. As illustrated in Figure 11, exposure to HDMA for 5 months beginning when the infant monkeys are 1 month old accelerates the rate at which BMZ material, such as collagen I, is deposited. Following HDMA exposure, the epithelial contact surface is a smooth uniform boundary for attachment of basal and columnar cells, but the side facing the attenuated fibroblast layer becomes highly irregular.

There is also a marked change in the chemical composition of the BMZ and in the types of signaling molecules that are stored there. Exposure to O_3 and HDMA completely disrupts the differentiation of the BMZ, with many areas being highly thickened and irregular, such as occurs with exposure to HDMA alone, and other areas being extremely thin as observed after exposure to O_3 alone (Figure 11). Between 6 and 12 months of age, the BMZ of the rhesus monkey doubles in size and increases in complexity. Six months of exposure to

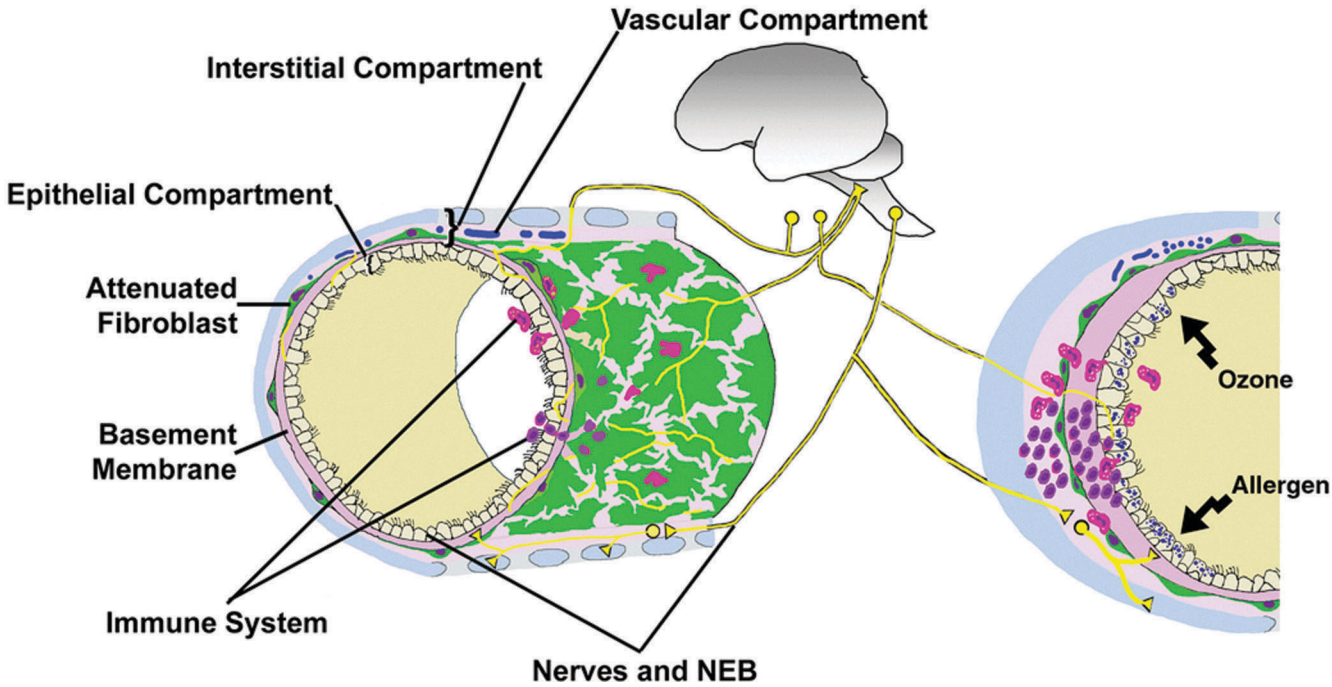

FIGURE 7.—Diagrammatic representation of the epithelial mesenchymal trophic unit of the airway wall illustrating the compartments, including epithelium, interstitium, vasculature, immune cells and nerves. The basement membrane zone is bordered by the attenuated fibroblasts and epithelium. All of these compartments are altered in airway remodeling associated with chronic allergic and inflammatory processes in the airways.

Downloaded from http://tpx.sagepub.com at Instituto Superiore Di Sanita on June 20, 2008
© 2007 Society of Toxicologic Pathology. All rights reserved. Not for commercial use or unauthorized distribution.

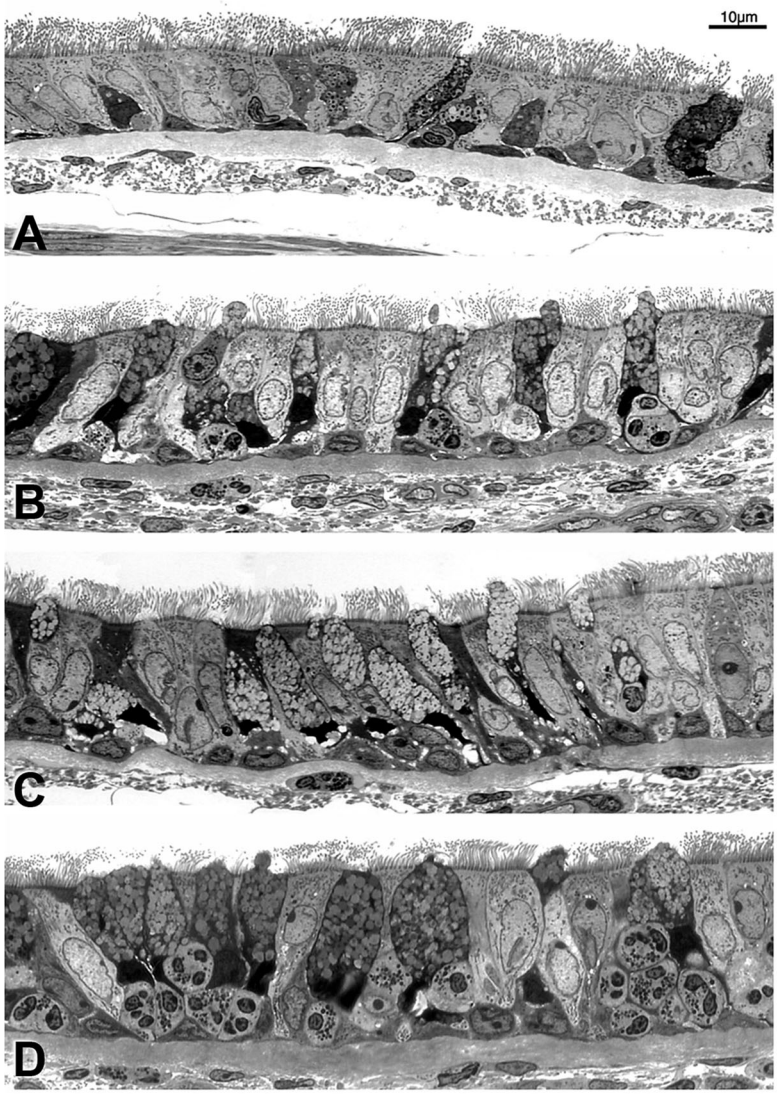

FIGURE 8.—Histological comparison of the mucosal surface in the proximal bronchi of infant rhesus monkeys (180 days of age) following 11 cycles of exposure to filtered air (A), house dust mite allergen (B), ozone (C) or both (D). Compared to filtered air animals (A), the epithelium in exposed animals is taller, contains more cells, larger mucous goblet cells, and more inflammatory cells. The greatest changes occurred in the group exposed to both allergen and ozone (D).

FA subsequent to a 5-month exposure to O_3, HDMA or both does not provide sufficient time for the normal developmental and growth processes of the BMZ to compensate for the previous disruption (Evans et al., 2004).

Epithelial Innervation

In midlevel airways in the rhesus monkey, innervation of the epithelial compartment is a postnatal event. Soon after birth, components of the wall that express markers for nervous tissue consist primarily of neuroendocrine-like cells. By 6 months of age, this changes, and a fine arborization of nerve processes can be detected (Figure 12) (Larson et al., 2004). Five months of exposure to O_3, HDMA or both results in a marked reduction in the density and distribution of nerve fibers and an elevation of neuroendocrine-like cells (Figure 12). The normal process of growth and development after 6 months of age is for the density of the nerve fibers to be reduced as the airways increase in size (Kajekar et al., 2006). Six months of exposure to FA subsequent to a 5-month exposure to O_3, HDMA or both results in a more than doubling of the density of the nerve fibers within the epithelium and an increase in the neuroendocrine-like cells as compared with unexposed animals (Kajekar et al., 2006).

Airway Smooth Muscle

The growth, differentiation, and organization of smooth muscle fibers within the tracheobronchial airway wall involves a significant number of changes during the postnatal period (Tran et al., 2004a). As the airways grow, the number of smooth muscle fibers and the bundles into which they are organized increase dramatically. This results in a uniform density of bundles within the airway wall regardless of airway size. Another major feature of airway growth is changes in the 3-dimensional orientation of the smooth muscle bundles.

Downloaded from http://tpx.sagepub.com at Instituto Superiore Di Sanita on June 20, 2008
© 2007 Society of Toxicologic Pathology. All rights reserved. Not for commercial use or unauthorized distribution.

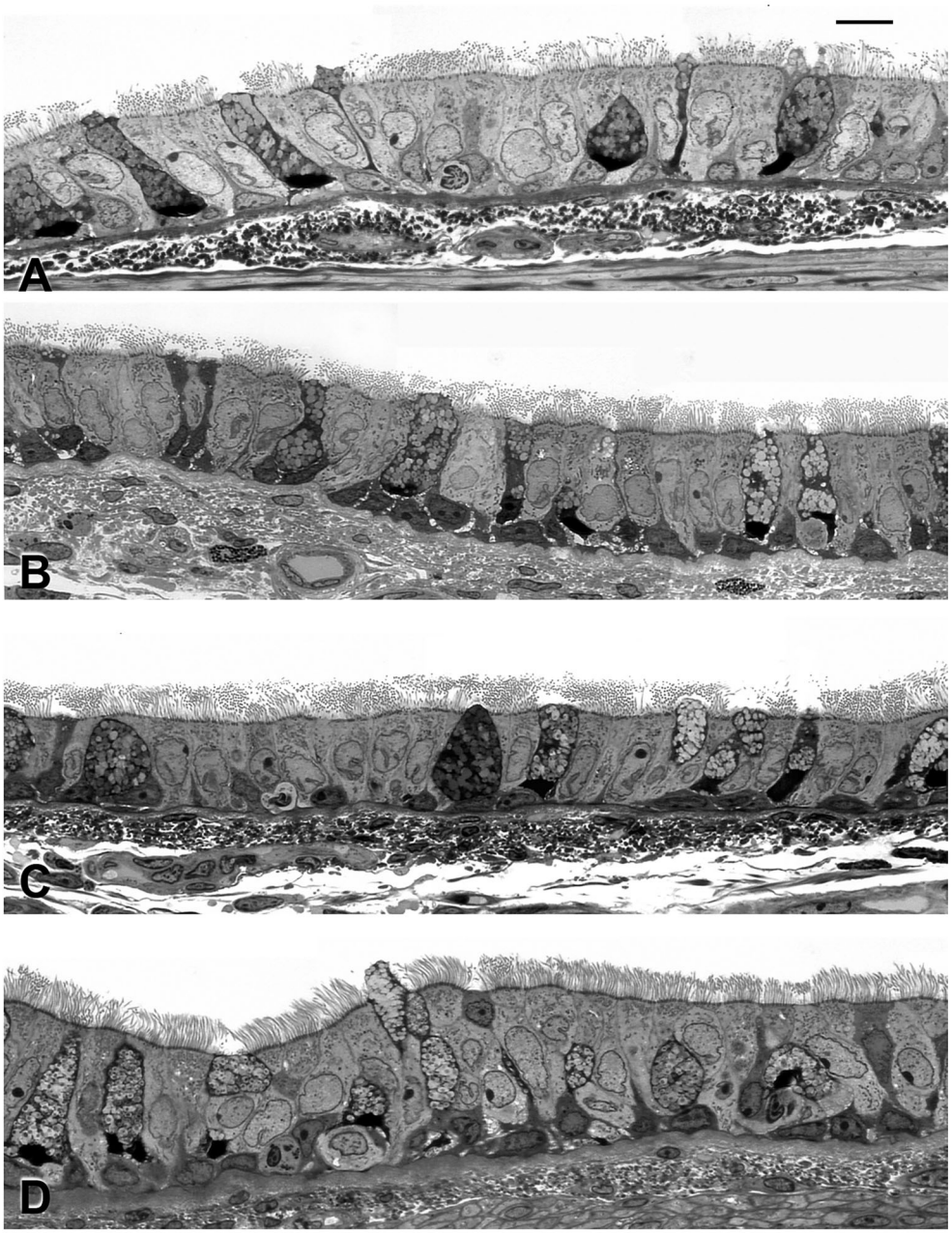

FIGURE 9.—Histological comparison of the mucosal surface in the proximal bronchi of infant rhesus monkeys (1 year of age) after 6 months' exposure to filtered air subsequent to 11 cycles of exposure to filtered air (A), house dust mite allergen (B), ozone (C) or both (D). Bar equals 10 μm.

Early in postnatal development, the bundles are arranged primarily perpendicular to the long axis of the airway.

By 90 days of age, a large percentage of the fibers are oriented greater than 30° from perpendicular. Exposure to O_3, HDMA or both disrupts this developmental process (Tran et al., 2004b). In terminal bronchioles of FA control 6-month-old monkeys, the majority of the smooth muscle bundles (~74%) around the airway are oriented at an angle less than 15° perpendicular to the long axis of the airway and only a very small percentage (~3%) of bundles were found at an angle greater than 30° (Figure 13). In O_3 exposed infant monkeys, only 43.0% of the terminal bronchiole smooth muscle bundles were oriented at an angle less than 15° perpendicular to the long axis of the airway, but there were 12% of bundles oriented at an angle of greater than 30°.

There was no significant difference in terminal bronchiole smooth muscle bundle thickness or abundance between FA and O_3 exposed monkeys, respectively. An opposite pattern of smooth muscle bundle orientation was present in the most proximal respiratory bronchiole. Only half of the smooth muscle bundles in the proximal respiratory bronchioles of FA control monkeys were oriented around the airway at an angle less than 15° perpendicular to the long axis of the airway, and ~16% of bundles were oriented at an angle of greater

Downloaded from http://tpx.sagepub.com at Instituto Superiore Di Sanita on June 20, 2008
© 2007 Society of Toxicologic Pathology. All rights reserved. Not for commercial use or unauthorized distribution.

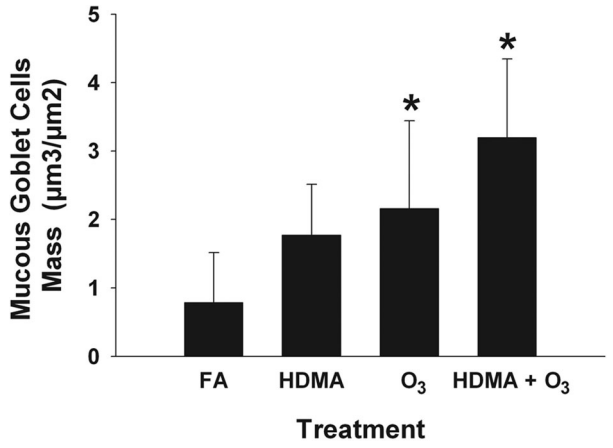

FIGURE 10.—Quantitative comparison of the abundance of mucous goblet cells in terminal bronchioles of infant rhesus monkeys (180 days of age) following 11 cycles of exposure to filtered air (FA), house dust mite allergen (HDMA), ozone (O_3) or both (HDMA+O_3). Mean ± 1 standard deviation. $^*p < 0.05$ compared to FA.

than 30°. In the first respiratory bronchiole of ozone-exposed monkeys, ~65% of the smooth muscle bundles were oriented at an angle less than 15° perpendicular to the long axis of the airway and only 5% of the bundles oriented at an angle of greater than 30°.

As in the terminal bronchioles, however, there were no significant differences in smooth muscle bundle thickness or abundance in the first respiratory bronchioles between FA control monkey and O_3-exposed monkeys, respectively (Fanucchi et al., 2006). Six months of exposure to FA subsequent to a 5-month exposure to O_3, HDMA or both does not provide sufficient time for the normal developmental and growth processes to adjust bundle size and orientation to match the configuration in unexposed, age-matched controls.

Airway Vasculature

Schematically, bronchial vasculature is part of the EMTU, and the role of vascular remodeling in the pathogenesis asthma is an evolving concept. Recent studies have described an increase in bronchovascular density in patients with asthma and asthma-like disease (Hoshino et al., 2001). To define the temporal and spatial aspects of vascular remodeling in the airway, we used a design-based stereological method to estimate bronchial vessels in juvenile monkeys exposed to O_3 and HDMA. Bronchial vascular surface area and density were significantly increased at mid-level airways in monkeys exposed to HDMA (Figure 14; Avdalovic et al., 2006). Gene expression of vascular endothelial growth factor (VEGF) was also significantly increased in distal airway levels in HDMA-exposed monkeys. Changes in vascular surface area and density were not as significant in O_3-exposed monkeys, and the combination of O_3 and HDMA led to similar

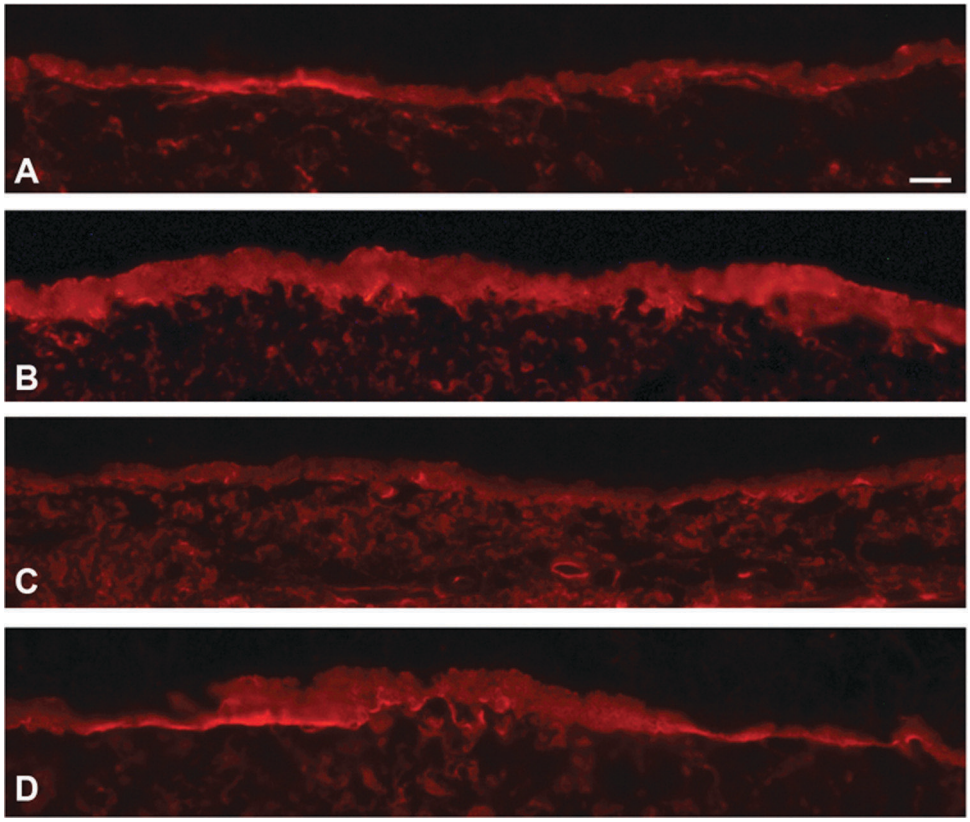

FIGURE 11.—Histological comparison of the basement membrane zone (BMZ) in the trachea of infant rhesus monkeys (180 days of age) following 11 cycles of exposure to filtered air (A), house dust mite allergen (B), ozone (C) or both (D). The BMZ is identified by indirect immunofluorescence (red) of collagen I. Compared to filtered air animals (A), the BMZ of HDMA exposed animals (B) was much thicker, that of ozone-exposed animals (C) much thinner and that of animals exposed to both (D) was highly irregular. Bar equals 10 ?m.

Downloaded from http://tpx.sagepub.com at Instituto Superiore Di Sanita on June 20, 2008
© 2007 Society of Toxicologic Pathology. All rights reserved. Not for commercial use or unauthorized distribution.

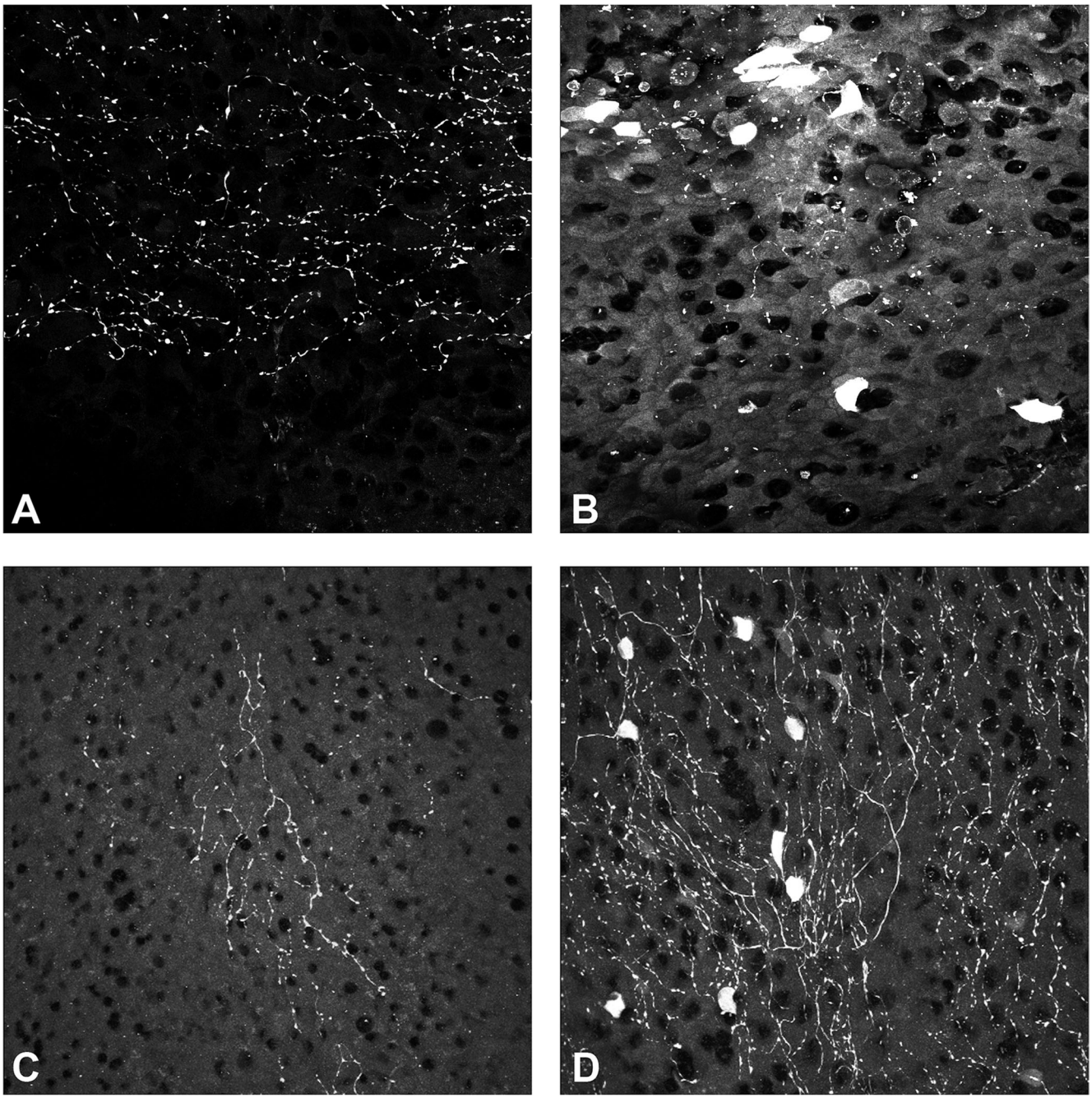

FIGURE 12.—Comparison of the distribution of nerve fibers and neuronal cells in the epithelium of midlevel airways of infant rhesus monkeys. The nerve fibers and neuronal cells were identified in whole mounts of airways exposed by microdissection using indirect immunofluorescence and an antibody to Protein Gene Product 9.5 (PGP 9.5). (A) In 6-month-old animals exposed to filtered air for 5 months, nerve fibers were relatively evenly distributed throughout the surface epithelium. (B) In contrast, animals of the same age exposed to ozone and allergen for 11 cycles had markedly reduced epithelial innervation and clusters of positive epithelial cells. (C) In 1-year-old animals exposed to filtered air for 11 cycles, nerve fibers were much reduced in density and distribution maintained the same interwoven pattern after 6 more months of filtered air. (D) In contrast, 1-year-old animals after 6 months' exposure to filtered air subsequent 11 cycles of exposure to ozone and allergen, the intraepithelial innervation was nearly twice as dense and found throughout the epithelial surface interspersed with positive epithelial cells.

changes as those seen in HDMA-exposed only monkeys (Avdalovic et al., 2003). These results imply that HDMA may stimulate an increase in bronchovascular density and that O_3 exposure is not additive.

Airway Immune System

The organization and distribution of immune and inflammatory cells within the infant tracheobronchial airway wall is very specific for the airway branch in which it is evaluated (Miller et al., 2005; Miller, 2006). Figure 4 shows that eosinophil frequency within airway lavage is significantly elevated in response to combined exposure to O_3 and HDMA, with no significant differences between animal groups exposed to FA (sensitized or nonsensitized), HDMA alone, and O_3 alone (Schelegle et al., 2003a). Comparatively, the density of eosinophil populations within epithelial and interstitial

Downloaded from http://tpx.sagepub.com at Instituto Superiore Di Sanita on June 20, 2008
© 2007 Society of Toxicologic Pathology. All rights reserved. Not for commercial use or unauthorized distribution.

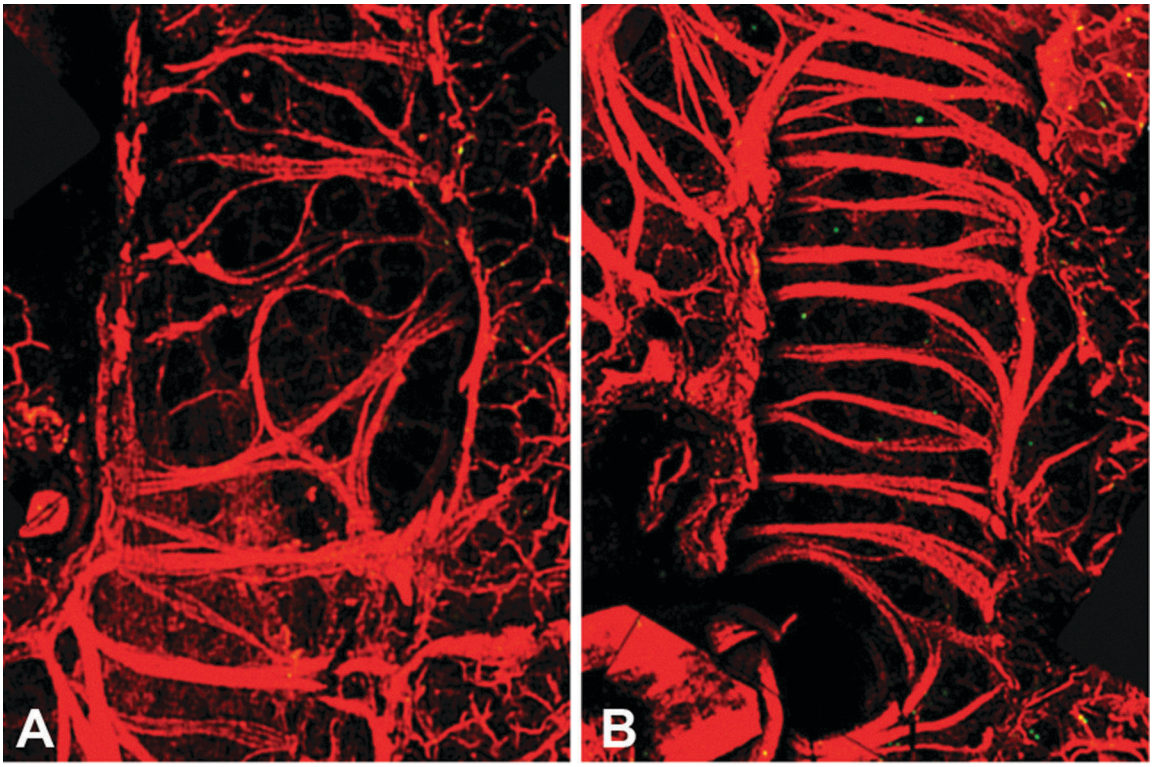

FIGURE 13.—Comparison of the organization of smooth muscle fibers in the proximal respiratory bronchioles of infant rhesus monkeys (180 days of age) following 11 cycles of exposure to filtered air (A) or both house dust mite allergen and ozone (B). The smooth muscle fibers are identified in whole mounts of airways exposed by microdissection by epifluorescence using Alexa 568 phalloidin (red), a probe for filamentous actin. Following exposure, smooth muscle bundle thickness increased and orientation was altered.

compartments does not necessarily reflect abundance within the airway lumen relative to exposure history (Figure 15A, 15B, top figures).

Within the epithelial and interstitial compartments, the volume of eosinophils from HDMA exposed animals is significantly elevated as compared with FA exposed animals, although exposure to both resulted in less abundance than exposure to HDMA alone. To add another level of complexity, the distribution of eosinophil populations within epithelial and interstitial compartments is variable, depending on where within the airway tree they are located (Figure 15A, 15B, bottom figures). Density of eosinophils within epithelium

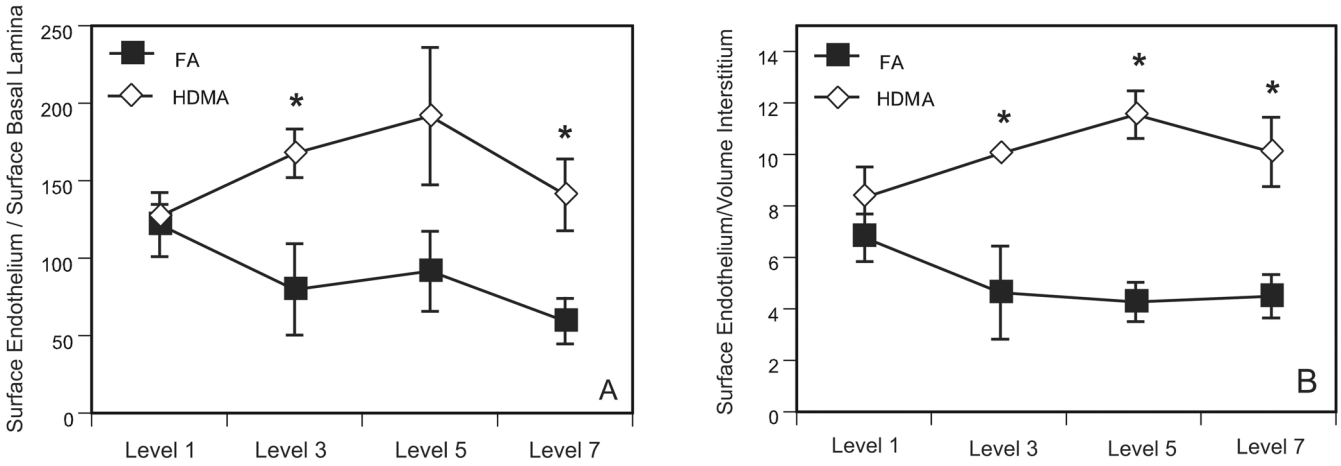

FIGURE 14.—Comparison of capillary density in the airway wall of different levels of the intrapulmonary tree in 3-year-old rhesus monkeys exposed to filtered air (FA) or house dust mite allergen (HDMA). The levels are sequentially numbered in a proximal to distal direction with Level 1 representing the most proximal bronchi and Level 7 representing the most distal bronchioles (terminal and respiratory). (A) Analysis based on estimations of the area of the luminal surface of the endothelium standardized to the surface area of the epithelial basement membrane. (B) Analysis based on estimations of the area of the luminal surface of the endothelium standardized to the volume of the interstitium. * $p < 0.05$ compared to control (FA) at the same airway generation.

Downloaded from http://tpx.sagepub.com at Instituto Superiore Di Sanita on June 20, 2008
© 2007 Society of Toxicologic Pathology. All rights reserved. Not for commercial use or unauthorized distribution.

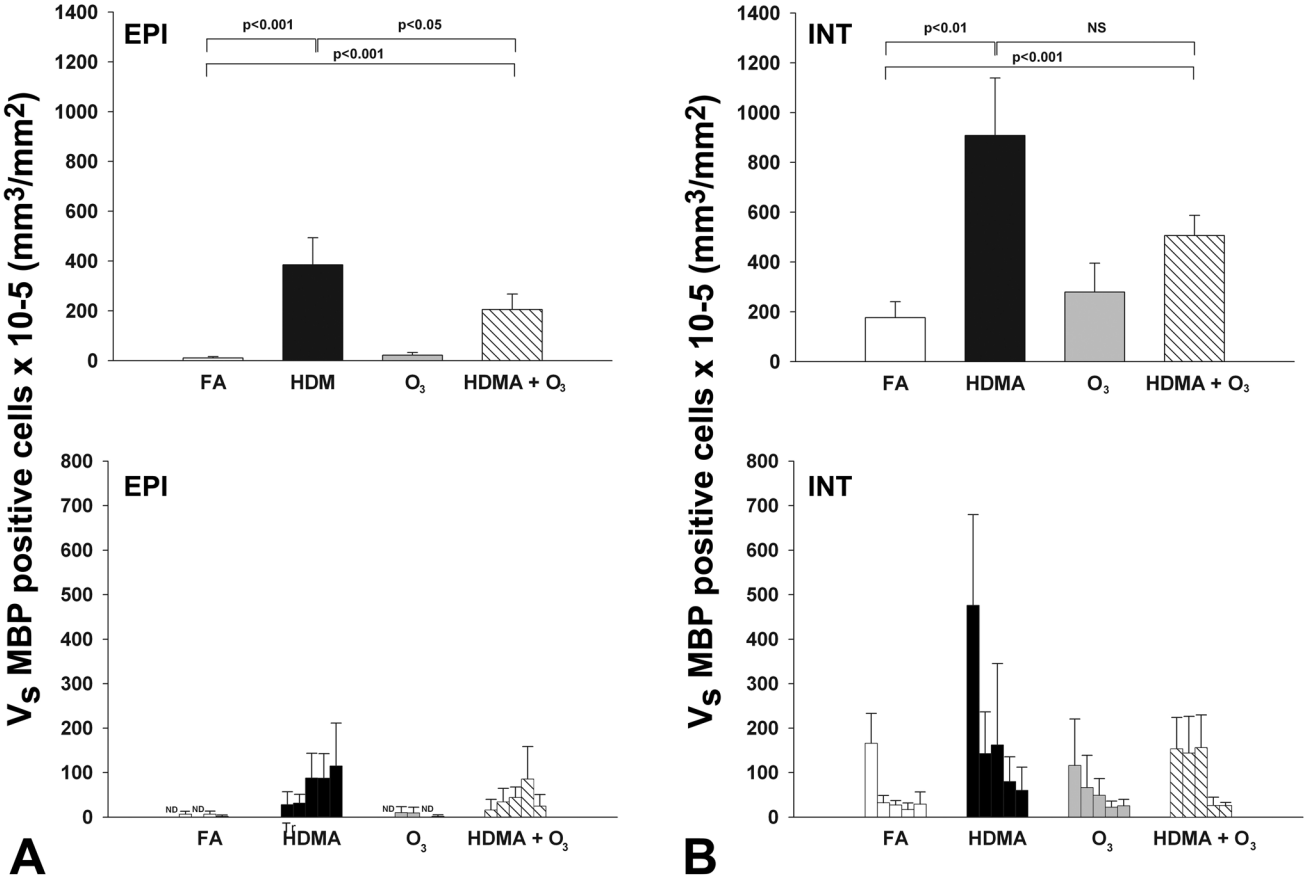

FIGURE 15.—Quantitative comparison of the distribution of eosinophils in the trachea (Tr), proximal (1) and mid-level (3,5) intrapulmonary bronchi and respiratory bronchioles (7) of infant rhesus monkeys (180 days of age) following 11 cycles of exposure to filtered air (FA), house dust mite allergen (HDMA), ozone (O_3) or both (HDMA+O_3). (A) Eosinophil volume within the epithelium (EPI) from infant monkey airways after the 11th exposure cycle. The top figure represents the sum of 5 airway generations for each treatment group, the bottom figure represents values for individual airway generations for each treatment group. (B) Eosinophil volume within interstitium (INT). The top figure represents the sum of 5 airway generations for each treatment group. The bottom figure represents values for individual airway generations for each treatment group. Columns represent the average volume ± SE of MBP+ staining cells (mm^3) within the interstitial compartment with respect to surface area of basal lamina (mm^2). Eosinophil abundance was determined by immunofluorescence staining for major basic protein (MBP). (Adapted from Miller et al., 2005.)

is highly dependant upon prior exposure to HDMA and appears to occur preferentially in distal airways. Density of eosinophils within interstitium is significantly dependent upon airway generation; eosinophils preferentially accumulate within the trachea and the most proximal intrapulmonary airways.

SUMMARY AND CONCLUSIONS

In summary, evaluation of the pathobiology of airway remodeling in growing lungs of neonates, using an animal model where exposure to allergen generates reactive airways disease with all the hallmarks of asthma in humans, illustrates that exposure to environmental pollutants and allergens early in life produces a large number of disruptions of fundamental growth and differentiation processes. All the compartments of the epithelial mesenchymal trophic unit are changed, including acceleration of mucous cell development, disruption of basement membrane growth and reorganization, alterations in the organization and orientation of airway smooth muscle, down-regulation of innervation of the epithelial compartment, and disruption of the sites of residence for migratory inflammatory and immune cells.

In addition, airway remodeling in neonatal lungs also involves restriction in the growth of tracheobronchial airways as well as fundamental alterations in branching number. Most of these disruptions do not appear to be easily correctable by subsequent extended periods in an environment free of either oxidant stressors or allergens.

While epidemiological studies have provided evidence of which environmental factors influence the development of asthma, there is a dearth of information on how these factors change normal airway development to result in the asthmatic condition. A major challenge is to determine when the airways change irreversibly along the disease continuum. Currently, we are in the process of evaluating the impact of early life exposure to oxidants and allergens on respiratory health over the long term and the potential implications for chronic lung disease in the adult, including increased susceptibility to infectious diseases, COPD, and chronic bronchitis. Meaningful studies of the mechanisms regulating growth and differentiation of the airways during lung development are needed.

Downloaded from http://tpx.sagepub.com at Instituto Superiore Di Sanita on June 20, 2008
© 2007 Society of Toxicologic Pathology. All rights reserved. Not for commercial use or unauthorized distribution.

This knowledge will help establish whether there are windows of susceptibility to asthma when infants and children should avoid exposure to harmful environmental factors. Such information is significant for public health as the basis for developing intervention strategies that can minimize childhood susceptibility. Major epidemiological studies, such as the National Children's Study (2005) that will follow children from birth to age 21, will help answer some of these questions. In conclusion, airways are complex structures that change by growing and differentiating for a significant time during postnatal life. The key to understanding how early life exposures cause asthma is to understand normal airway growth processes so that mechanisms behind the airway changes that occur in asthma can be determined.

ACKNOWLEDGMENTS

Development of the rhesus monkey as a model for allergic airways disease was the product of the interactions of all faculty and staff members of the Respiratory Diseases Unit at the California National Primate Research Center, whose members, in addition to the authors of the present paper, include the following: B. K. Tarkington, V. J. Wong, W. F. Walby, J. M. Bric, T. R. Duvall, K. S. Kott, D. R. Morin, A. J. Weir, S. J. Nishio, and N. K. Tyler. The support of Primate Services at the California National Primate Research Center for animal handling, care, and coordination and veterinary care, especially the efforts of Dr. L. L. Brignolo, Dr. K. L. Christe, S. M. Davis, and B. E. Rodello were critical to this study and are gratefully acknowledged. The authors thank A. W. Chang for organization and preparation of the manuscript.

This work was supported by National Institutes of Health grants NIEHS P01ES00628, NIEHS P01 ES11617, and NCRR RR00169. The University of California at Davis is a National Institute of Environmental Health Sciences Center for Environmental Health Sciences (ES05707), which supported core facilities used in this study.

All monkeys selected for the studies reviewed here were California National Primate Research Center colony-born macaques (*Macaca mulatta*). Care and housing of animals before, during, and after treatment complied with the provisions of the Institute of Laboratory Animal Resources and conform to practices established by the Association for Assessment and Accreditation of Laboratory Animal Care International.

REFERENCES

American Lung Association. Asthma and Children Fact Sheet. July 2005. ⟨http://www.lungusa.org/site/pp.asp?c=dvLUK9O0E&b=44352⟩. Accessed October 24, 2005.

Avdalovic, M., Usachenko, J., Tyler, N., Miller, L., Schelegle, E., Gershwin, L., Plopper, C., and Hyde, D. (2006). Vascular remodeling is airway generation-specific in a primate model of chronic asthma. *Am J Resp Crit Care Med,* In Press.

Avdalovic, M., Usachenko, J., Tyler, N., Miller, L., Schelegle, E., Plopper, C., and Hyde, D. (2003). Increased vascular density in bronchial airways is attenuated by ozone. *Am J Resp Crit Care Med* **10**, 1069–76.

Burri, P. H. (1997). Postnatal development and growth. In The Lung: Scientific Foundations (R. G. Crystal, J. B. West, E. R. Weibel, and P. J. Barnes, eds.), pp. 1013–26. Lippincott-Raven Publishers, Philadelphia.

Calderon-Garciduenas, L., Mora-Tiscareno, A., Fordham, L. A., Valencia-Salazar, G., Chung, C. J., Rodriguez-Alcaraz, A., Paredes, R., Variakojis, D., Villarreal-Calderon, A., Flores-Camacho, L., Antunez-Solis, A., Henriquez-Roldan, C., and Hazucha, M. J. (2003). Respiratory damage in children exposed to urban pollution. *Pediatr Pulmonol* **36**, 148–61.

Cudmore, R. E., Emery, J. L., and Mithal, A. (1962). Postnatal growth of the bronchi and bronchioles. *Arch Dis Child* **37**, 481–4.

Evans, M. J., Fanucchi, M. V., Baker, G. L., Van Winkle, L. S., Pantle, L. M., Nishio, S. J., Schelegle, E. S., Gershwin, L. J., Miller, L. A., Hyde, D. M., and Plopper, C. G. (2004). The remodelled tracheal basement membrane zone of infant rhesus monkeys after 6 months of recovery. *Clin Exp Allergy* **34**, 1131–6.

Evans, M. J., Fanucchi, M. V., Van Winkle, L. S., Baker, G. L., Murphy, A. E., Nishio, S. J., Sannes, P. L., and Plopper, C. G. (2002). Fibroblast growth factor-2 during postnatal development of the tracheal basement membrane zone. *Am J Physiol Lung Cell Mol Physiol* **283**, L1263–70.

Evans, M. J., Van Winkle, L. S., Fanucchi, M. V., and Plopper, C. G. (1999). The attenuated fibroblast sheath of the respiratory tract epithelial-mesenchymal trophic unit. *Am J Respir Cell Mol Biol* **21**, 655–7.

Fanucchi, M. V., and Plopper, C. G. (2004). Environmental toxicants and lung development in experimental models. In The Lung: Development, Aging, and the Environment (R. Harding, K. Pinkerton, and C. Plopper, eds.), pp. 345–52. Elsevier Academic Press, London.

Fanucchi, M. V., Plopper, C. G., Evans, M. J., Hyde, D. M., Van Winkle, L. S., Gershwin, L. J., and Schelegle, E. S. (2006). Cyclic exposure to ozone alters distal airway development in infant rhesus monkeys. *Am J Physiol Lung Cell Mol Physiol* **291**(4), L644–50.

Frischer, T., Studnicka, M., Gartner, C., Tauber, E., Horak, F., Veiter, A., Spengler, J., Kuhr, J., and Urbanek, R. (1999). Lung function growth and ambient ozone: a three-year population study in school children. *Am J Respir Crit Care Med* **160**, 390–6.

Gauderman, W. J., Avol, E., Gilliland, F., Vora, H., Thomas, D., Berhane, K., McConnell, R., Kuenzli, N., Lurmann, F., Rappaport, E., Margolis, H., Bates, D., and Peters, J. (2004). The effect of air pollution on lung development from 10 to 18 years of age. *N Engl J Med* **351**, 1057–67.

Gold, D. R., Wypij, D., Wang, X., Speizer, F. E., Pugh, M., Ware, J. H., Ferris, B. G., Jr., and Dockery, D. W. (1994). Gender- and race-specific effects of asthma and wheeze on level and growth of lung function in children in six U.S. cities. *Am J Respir Crit Care Med* **149**, 1198–208.

Holgate, S. T., Davies, D. E., Lackie, P. M., Wilson, S. J., Puddicombe, S. M., and Lordan, J. L. (2000). Epithelial-mesenchymal interactions in the pathogenesis of asthma. *J Allergy Clin Immunol* **105**, 193–204.

Holt, P. G., Sly, P. D., Martinez, F. D., Weiss, S. T., Bjorksten, B., von Mutius, E., and Wahn, U. (2004). Drug development strategies for asthma: in search of a new paradigm. *Nat Immunol* **5**, 695–8.

Hoshino, M., Takahashi, M., and Aoike, N. (2001). Expression of vascular endothelial growth factor, basic fibroblast growth factor, and angiogen immunoreactivity in asthmatic airways and its relationship to angiogenesis. *J Allergy Clin Immunol* **107**, 295–301.

Kajekar, R., Pieczarka, E. M., Smiley-Jewell, S. M., Schelegle, E. S., Fanucchi, M. V., and Plopper, C. G. (2007). Early postnatal exposure to allergen and ozone leads to hyperinnervation of the pulmonary epithelium. *Respir Physiol Neurobiol*..

Larson, S. D., Schelegle, E. S., Walby, W. F., Gershwin, L. J., Fanuccihi, M. V., Evans, M. J., Joad, J. P., Tarkington, B. K., Hyde, D. M., and Plopper, C. G. (2004). Postnatal remodeling of the neural components of the epithelial-mesenchymal trophic unit in the proximal airways of infant rhesus monkeys exposed to ozone and allergen. *Toxicol Appl Pharmacol* **194**, 211–20.

Lemanske, R. F. (2004). Viral infections and asthma inception. *J Allergy Clin Immunol* **114**, 1023–6.

Massaro, G. D., and Massaro, D. (1996). Formation of pulmonary alveoli and gas-exchange surface area: quantitation and regulation. *Annu Rev Physiol* **58**, 73–92.

McGowan, S. E., and Synder, J. M. (2004). Development of alveoli. In The Lung: Development, Aging, and the Environment (R. Harding, K. Pinkerton, and C. Plopper, eds.), pp. 55–73. Elsevier Academic Press, London.

Miller, L. A., Gerriets, J.E., Stovall, M.Y., Tyler, N.K., Gershwin, L.J., Schelegle, E.S., Plopper, C.G., and Hyde, D.M. (2006). Ozone modulates immune cell activation and trafficking in aeroallergen challenged infant monkeys. *AJRCCM*, Submitted.

Downloaded from http://tpx.sagepub.com at Instituto Superiore Di Sanita on June 20, 2008
© 2007 Society of Toxicologic Pathology. All rights reserved. Not for commercial use or unauthorized distribution.

Miller, L. A., Hurst, S. D., Coffman, R. L., Tyler, N. K., Stovall, M. Y., Chou, D. L., Putney, L. F., Gershwin, L. J., Schelegle, E. S., Plopper, C. G., and Hyde, D. M. (2005). Airway generation-specific differences in the spatial distribution of immune cells and cytokines in allergen-challenged rhesus monkeys. *Clin Exp Allergy* **35**, 894–906.

Payne, D. N., Rogers, A. V., Adelroth, E., Bandi, V., Guntupalli, K. K., Bush, A., and Jeffery, P. K. (2003). Early thickening of the reticular basement membrane in children with difficult asthma. *Am J Respir Crit Care Med* **167**, 78–82.

Peters, J. M., Avol, E., Gauderman, W. J., Linn, W. S., Navidi, W., London, S. J., Margolis, H., Rappaport, E., Vora, H., Gong, H., Jr., and Thomas, D. C. (1999a). A study of twelve Southern California communities with differing levels and types of air pollution. II. Effects on pulmonary function. *Am J Respir Crit Care Med* **159**, 768–75.

Peters, J. M., Avol, E., Navidi, W., London, S. J., Gauderman, W. J., Lurmann, F., Linn, W. S., Margolis, H., Rappaport, E., Gong, H., and Thomas, D. C. (1999b). A study of twelve Southern California communities with differing levels and types of air pollution. I. Prevalence of respiratory morbidity. *Am J Respir Crit Care Med* **159**, 760–7.

Phalen, R. F., Oldham, M. J., Beaucage, C. B., Crocker, T. T., and Mortensen, J. D. (1985). Postnatal enlargement of human tracheobronchial airways and implications for particle deposition. *Anatom Rec* **212**, 368–80.

Phalen, R. F., Yeh, H. C., Schum, G. M., and Raabe, O. G. (1978). Application of an idealized model to morphometry of the mammalian tracheobronchial tree. *Anatom Rec* **190**, 167–76.

Plopper, C. G. (1990). Structural methods for studying bronchiolar epithelial cells. In Models of Lung Disease: Microscopy and Structural Methods (J. Gil, ed.), pp. 537–59. Marcel Dekker, Inc., New York.

Plopper, C. G., and Harkema, J. R. (2005). The respiratory system and its use in research. In The Laboratory Primate (S. Wolfe-Coote, ed.), p. 621. Elsevier Academic Press, London.

Richardson, G., Eick, S., and Jones, R. (2005). How is the indoor environment related to asthma? Literature review. *J Adv Nurs* **52**, 328–39.

Romieu, I., Meneses, F., Ruiz, S., Sienra, J., Huerta, J., White, M., and Etzel, R. (1996). Effects of air pollution on the respiratory health of asthmatic children living in Mexico City. *Am J Respir Crit Care Med* **154**, 300–7.

Saglani, S., Malmstrom, K., Pelkonen, A. S., Malmberg, L. P., Lindahl, H., Kajosaari, M., Turpeinen, M., Rogers, A. V., Payne, D. N., Bush, A., Haahtela, T., Makela, M. J., and Jeffery, P. K. (2005). Airway remodeling and inflammation in symptomatic infants with reversible airflow obstruction. *Am J Respir Crit Care Med* **171**, 722–7.

Schelegle, E. S., Gershwin, L. J., Miller, L. A., Fanucchi, M. V., Van Winkle, L. S., Gerriets, J. P., Walby, W. F., Omlor, A. M., Buckpitt, A. R., Tarkington, B. K., Wong, V. J., Joad, J. P., Pinkerton, K. B., Wu, R., Evans, M. J., Hyde, D. M., and Plopper, C. G. (2001). Allergic asthma induced in rhesus monkeys by house dust mite (*Dermatophagoides farinae*). *Am J Pathol* **158**, 333–41.

Schelegle, E. S., Miller, L. A., Gershwin, L. J., Fanucchi, M. V., Van Winkle, L. S., Gerriets, J. E., Walby, W. F., Mitchell, V., Tarkington, B. K., Wong, V. J., Baker, G. L., Pantle, L. M., Joad, J. P., Pinkerton, K. E., Wu, R., Evans, M. J., Hyde, D. M., and Plopper, C. G. (2003a). Repeated episodes of ozone inhalation amplifies the effects of allergen sensitization and inhalation on airway immune and structural development in Rhesus monkeys. *Toxicol Appl Pharmacol* **191**, 74–85.

Schelegle, E. S., Walby, W. F., Alfaro, M. F., Wong, V. J., Putney, L., Stovall, M. Y., Sterner-Kock, A., Hyde, D. M., and Plopper, C. G. (2003b). Repeated episodes of ozone inhalation attenuates airway injury/repair and release of substance P, but not adaptation. *Toxicol Appl Pharmacol* **186**, 127–42.

Sporik, R., Chapman, M. D., and Platts-Mills, T. A. (1992). House dust mite exposure as a cause of asthma. *Clin Exp Allergy* **22**, 897–906.

Tager, I. B., Weiss, S. T., Munoz, A., Rosner, B., and Speizer, F. E. (1983). Longitudinal study of the effects of maternal smoking on pulmonary function in children. *N Engl J Med* **309**, 699–703.

Thorne, P. S., Kulhankova, K., Yin, M., Cohn, R., Arbes, S. J., Jr., and Zeldin, D. C. (2005). Endotoxin exposure is a risk factor for asthma: the national survey of endotoxin in United States housing. *Am J Respir Crit Care Med* **172**, 1371–7.

Tran, M. U., Weir, A. J., Fanucchi, M. V., Murphy, A. E., Van Winkle, L. S., Evans, M. J., Smiley-Jewell, S. M., Miller, L., Schelegle, E. S., Gershwin, L. J., Hyde, D. M., and Plopper, C. G. (2004a). Smooth muscle development during postnatal growth of distal bronchioles in infant rhesus monkeys. *J Appl Physiol* **97**, 2364–71.

Tran, M. U., Weir, A. J., Fanucchi, M. V., Rodriguez, A. E., Pantle, L. M., Smiley-Jewell, S. M., Van Winkle, L. S., Evans, M. J., Miller, L. A., Schelegle, E. S., Gershwin, L. J., Hyde, D. M., and Plopper, C. G. (2004b). Smooth muscle hypertrophy in distal airways of sensitized infant rhesus monkeys exposed to house dust mite allergen. *Clin Exp Allergy* **34**, 1627–33.

Downloaded from http://tpx.sagepub.com at Instituto Superiore Di Sanita on June 20, 2008
© 2007 Society of Toxicologic Pathology. All rights reserved. Not for commercial use or unauthorized distribution.