Scandinavian Journal of Gastroenterology

ISSN: 0036-5521 (Print) 1502-7708 (Online) Journal homepage: http://www.tandfonline.com/loi/igas20

Infliximab-induced skin manifestations in patients with inflammatory bowel disease

Alec Eligius Hellström, Martti Färkkilä & Kaija-Leena Kolho

To cite this article: Alec Eligius Hellström, Martti Färkkilä & Kaija-Leena Kolho (2016): Infliximab-induced skin manifestations in patients with inflammatory bowel disease, Scandinavian Journal of Gastroenterology, DOI: 10.3109/00365521.2015.1125524

To link to this article: http://dx.doi.org/10.3109/00365521.2015.1125524

Published online: 05 Jan 2016.

Submit your article to this journal

Article views: 30

View related articles

View Crossmark data

Full Terms & Conditions of access and use can be found at
http://www.tandfonline.com/action/journalInformation?journalCode=igas20

Download by: [University of Liverpool] **Date:** 14 January 2016, At: 03:37

SCANDINAVIAN JOURNAL OF GASTROENTEROLOGY, 2015
http://dx.doi.org/10.3109/00365521.2015.1125524

Taylor & Francis
Taylor & Francis Group

ORIGINAL ARTICLE

Infliximab-induced skin manifestations in patients with inflammatory bowel disease

Alec Eligius Hellström[a], Martti Färkkilä[a] and Kaija-Leena Kolho[b]

[a]Helsinki University Hospital, Clinic of Gastroenterology, University of Helsinki, Helsinki, Finland; [b]Helsinki University Hospital, Children's Hospital and Helsinki University, Helsinki, Finland

ABSTRACT

Objective The use of infliximab in rheumatoid and inflammatory bowel diseases (IBD) has been associated with a variety of adverse skin reactions, including paradoxical psoriatic lesions. The prevalence and possible predictors for these lesions were under observation in our cross-sectional prospective study. **Material and methods** Nurses screened the skin of 118 adult patients with IBD during infliximab infusions between 4 September 2013 and 30 September 2014 based on the structured questionnaire. Data on skin manifestations, concomitant medications, extraintestinal manifestations and inflammatory markers were collected for analysis. **Results** Non-infectious skin manifestations were observed in 27 (22.9%) patients during the study period, of which eight (29.6%) were new-onset, eight (29.6%) were exacerbations of existing lesions and 11 (40.7%) were baseline lesions that did not worsen during the study. Scaling eczema was the most commonly described skin manifestation ($n = 8$; 29.6%), followed by exacerbated atopic eczema ($n = 5$; 18.5%) and plausible infliximab-induced psoriasiform lesions ($n = 5$; 18.5%). The strongest associating factor for skin manifestations was Crohn's disease, in nearly 80% of afflicted patients. **Conclusions** Anti-TNF-α therapy is frequently associated with newly onset skin reactions, most commonly in patients with Crohn's disease. Non-infectious skin manifestations can be treated topically and do not require cessation of anti-TNF-α therapy.

ARTICLE HISTORY
Received 1 October 2015
Revised 17 November 2015
Accepted 23 November 2015
Published online
24 December 2015

KEYWORDS
Crohn's disease; drug eruption; psoriasis; tumour necrosis factor-alpha; ulcerative colitis

Downloaded by [University of Liverpool] at 03:37 14 January 2016

Introduction

Tumour necrosis factor-α (TNF-α) is a proinflammatory cytokine involved in the regulation of immune cells. The intravenously administered chimeric monoclonal antibody infliximab (IFX) and subcutaneously injected monoclonal antibodies adalimumab, golimumab and certolizumab are anti-TNF-α drugs approved for the treatment of inflammatory bowel disease. Anti-TNF-α therapy is indicated as the treatment of moderate to severe active luminal Crohn's disease (CD) or ulcerative colitis (UC). In a loss of response, therapy enhancement, and in case of failure, switching to another anti-TNF-α agent are viable strategies.[1,2]

The increased use of anti-TNF-α therapy for IBD has surged interest regarding adverse events of this relatively new drug class. Serious adverse events during anti-TNF-α therapy, which include opportunistic infections, exacerbation of congestive heart failure, hepatotoxicity, demyelination, drug-induced lupus erythematosis and malignancies, have been rigorously studied.[3] In recent years, surprisingly high rates of dermatological adverse events have been reported in prospective IBD studies. In addition to uncommon drug-induced lupus and skin malignancies, these include both acute and delayed infusion and injection reactions, eczematous presentations, infectious skin manifestations of all aetiologies and paradoxical new-onset or exacerbated psoriatic skin lesions.[4] A summary of the largest epidemiological studies that have investigated both psoriasiform and non-psoriasiform skin reactions in IBD populations including, to the best of our knowledge, all prospective and the two largest retrospective studies to date is presented in Table 1.

In a recent prospective paediatric study by Mälkönen et al., 48% of the children presented with IFX-related skin lesions. Most of dermatologist assessed (24% of the study population) patients had psoriasis-like skin manifestations.[5] Retrospective paediatric studies have suggested more cautious incidence rates for psoriasiform lesions of 8% and 10.5%.[6,7] These skin lesions have also been described in prospective rheumatoid studies with incidence rates between 1.0 and 5.3% for

CONTACT Martti Färkkilä martti.farkkila@hus.fi Helsinki University Hospital, Clinic of Gastroenterology, University of Helsinki, P.O. Box 340, FIN-00029 Helsinki, Finland

© 2015 Taylor & Francis

Table 1. Literature summary of the prospective and two largest retrospective studies on infliximab-induced skin reactions, including paradoxical psoriasiform skin lesions, in patients with inflammatory bowel disease.

		Patients	Skin lesions in total		Psoriasiform skin lesions	
Author	Type	*n*	*n*	%	*n*	%
Tillack et al. [11]	Prospective, incidence	434	99	22.8	21	4.8
Mälkönen et al. [5]	Prospective, incidence, paediatric	84	40	47.6	13[a]	15.5[a]
Huang et al. [13]	Prospective, prevalence	71	18	25.4	2	2.8
Baumgart et al. [14]	Prospective, incidence	50	31	62.0	6	12.0
Włodarczyk et al. [13]	Prospective, incidence, only Crohn's	30	18	60.0	8	26.6
Cleynen et al. [19]	Retrospective, incidence	922	207	22.0	81	8.8
Fidder et al. [16]	Retrospective, incidence	734	150	20.4	39[b]	5.3[b]

[a]Twenty out of 40 patients with skin lesions were dermatologist assessed. Out of these, 13 patients had psoriasiform lesions.
[b]Sixty-four out of 150 patients were dermatologist assessed. Out of these 64 patients, 39 had psoriasiform lesions.

psoriasiform and 18 and 26.5% for non-psoriasiform skin manifestations.[8–10] Although as the follow-up times, methods and study populations in all of the listed studies vary, results are not directly comparable. Smoking, increased BMI, short disease duration [11] and CD [5,12] have been suggested to associate specifically with psoriasiform lesions. On the other hand, low grade of intestinal inflammation,[5,13] long duration of anti-TNF-α therapy [5,14] and female gender [15–18] might associate with adverse skin events in some studies. Nevertheless, none of the above demographic or treatment-related predictors have been consistently reported in IBD literature. Some studies have not reported any statistically significant differences in demographic variables between groups.[13,14,19]

In this study, we focus on cutaneous adverse events during anti-TNF-α therapy. Due to inconsistent results in past literature, the prevalence, anatomical locations and possible predictors of adverse skin events are of interest in our study; psoriasiform lesions in particular. We hypothesise a large prevalence of skin lesions when systematically screened for.

Methods

One hundred and eighteen adult patients with IBD referred for therapy with IFX in the tertiary care hospital of Helsinki University Hospital, Finland, were enrolled in our prospective study. Patients referred to IFX infusions between 4 September 2013 and 30 September 2014 were asked to participate. Our study population accounted for 80% of all IFX-treated patients ($n = 148$) with the same indication during the study period in our hospital. Indication for IFX therapy was an inadequate response or intolerance to immunosuppressive therapy. IFX induction therapy was initiated with a dosage of 5 mg/kg during week 0, with the following infusions during weeks 2 and 6. Subsequent maintenance therapy was then continued on an 8-week interval. Some patients with an inadequate response had their regimen enhanced by increasing the dosage to 10 mg/kg or by shortening the infusion interval to 6 weeks.

Nurses systemically documented data on any current skin symptoms during every IFX infusion on a data collection sheet with a drawing of the human body to document the locations of observed skin reactions. On the same study sheet, any possible skin manifestations were described in detail on a list with 13 predefined anatomical locations. In addition, we examined the medical records of all included patients, and considered any recorded skin symptoms. Unfortunately, a median of one completed study sheet per patient was missing or unobtainable. Data from these infusions were disregarded.

A complete blood count was taken from every patient as a safety protocol a few days prior to infusion. These data were later gathered from patient charts. In addition, we collected C-reactive protein (CRP), faecal calprotectin (FC), plasma albumin, serum IFX and IFX-antibody levels when available.

Demographic data, concurrent IBD medication and extraintestinal manifestations (EIM) were collected from electronic patient records. Diagnoses of arthritis, ankylosing spondylitis, primary sclerosing cholangitis, autoimmune hepatitis, erythema nodosum, pyoderma gangrenosum, iritis, episcleritis and pancreatitis (not related to drugs) were regarded as EIMs. The software provided lists of diagnoses, prescriptions and medications, although we double-checked these data from the written patient records with an implemented search function. Medical records from previous health care districts were obtained from the hospital archives in non-electronic form, although some specific data such as the exact date of the first IFX induction or time of diagnosis were unavailable from less than five patients.

Delayed cutaneous infusion reactions, new onset and exacerbation of lesions and baseline lesions with probable association to IFX treatments were regarded as skin events. Conversely, acute infusion reactions, baseline lesions which improved, atopic skin conditions that did not worsen, birthmarks, itching and skin manifestations

Downloaded by [University of Liverpool] at 03:37 14 January 2016

of probable infectious aetiologies were not regarded as skin events in this study. Categorisation of probable IFX-related skin manifestations according to study reports was retrospectively made by A. H., K. -L. K. and M. F. We considered both the medical records and study sheets of the participants during categorisation.

Statistical analysis

Statistical analysis was performed with version 6.04 of Graphpad Prism 6 (Graphpad Inc., San Diego, CA). Continuous variables were reported as medians and interquartile ranges (IQR). Fisher's exact test or the Chi-squared test was used to compare categorical variables between groups. Analysis of independent quantitative continuous variables between groups was performed with Welch's *t*-test for parametric statistics and Mann–Whitney's *U*-test for non-parametric statistics. *p* Values of less than 0.05 were considered statistically significant. CRP values of "<3" were converted into values of "1.5" when using Mann–Whitney's *U*-test.

With the exception of FC analysis, we compared variables at the time of a skin event to variables of those without skin events at the end of the study period. FC analysis was done by comparing FC values available within one month of infusion from the first time a patient presented with a skin lesion, or if not available, at a later time, when the same skin lesion still existed against the latest available FC value from patients without lesions.

Ethical considerations

The study was conducted following the ethical principles of the Declaration of Helsinki. Our study protocol was approved by the Ethics Committee of the Helsinki University Central Hospital. All patients were asked for written informed consent prior to participation in the study.

Table 2. Study population demographics and clinical characteristics.

	n (%)	Median	IQR
Sex			
Female	54 (45.8)		
Male	64 (54.2)		
Age, years		38.5	26.2–41.5
Age at diagnosis, years		30.2	17.8–29.4
Disease duration before first IFX therapy, years		7.9	2.0–10.3
Disease duration at start of follow-up, years		8.0	3.1–13.1
Infliximab regimen duration at start of follow-up, months		8.2	0.5–29.5
Smoking			
Current	22 (17.8)		
No	71 (61.0)		
Former	18 (15.3)		
Data not available	7 (5.9)		
History of anti-TNF-α therapy			
Naïve to infliximab before current therapy	75 (63.6)		
Previous anti-TNF-α therapies	45 (38.1)		
1	30		
2	10		
≥ 3	5		
Disease			
Crohn's disease	54 (45.8)		
L1, Ileal	5		
L2, Colonic	19		
L3, Ileocolonic	29		
L4, Upper GI	1		
A1, <17 years	15		
A2, 17–40 years	36		
A3, $\geq$40 years	3		
B1, inflammatory	24		
B2, structuring	13		
B3, penetrating	17		
Perianal disease	33		
Ulcerative colitis	59 (50.0)		
Proctitis	3		
Distal colitis	13		
Pancolitis	43		
Inflammatory bowel disease unclassified	5 (4.2)		
Concurrent medication at end of follow-up			
Corticosteroids	26 (22.0)		
Oral	7 (5.9)		
Intravenous, prophylactic	20 (16.9)		
Mesalazine	48 (40.6)		
Thiopurines	67 (56.8)		
Methotrexate	6 (5.1)		
Cyclosporine	0		
Infliximab dosage, mg/kg		5.19	4.88–5.71
Regimen enhancement during study period	18 (15.3)		
Extraintestinal manifestations (one or more)	24 (20.3)		

Results

Clinical characteristics and laboratory values

Demographic and clinical characteristics of 118 IFX-treated patients with IBD are presented in Table 2. Dermatological adverse events were observed in 27 (22.9%) patients, whereas 91 (77.1%) patients presented either with no skin event or an event regarded as unrelated to IFX therapy.

A statistically significant difference between the patients with skin events and those without was found in the underlying disease. CD was diagnosed in 21 (77.8%) out of 27 patients with skin events. Conversely, 33 (36.3%) out of 91 patients without a skin event had CD ($p < 0.01$). A larger proportion of patients without skin events were on induction therapy during the study period (33.1% versus 14.8%; $p = 0.01$). The medians of cumulative infusion counts (13 versus 9 [IQR 8–19 versus 4–21]; $p = 0.08$), duration of current IFX regimen (20.5 versus 13.4 years [IQR 5.2–34.5 versus 4.6–36]; $p = 0.22$) and disease duration (8.3 versus 6.6 years [IQR 4.2–15.4 versus 2.6–11.9]; $p = 0.16$) were larger in the skin event group, although only numerically. The duration of current IFX regimen until new-onset, exacerbation or re-emergence of an existing non-infectious lesion during

Downloaded by [University of Liverpool] at 03:37 14 January 2016

our study period is presented as a survival in the graph in Figure 1.

IFX dosages between the group with skin reactions and the group without were similar (median 5.16 versus 5.13 mg/kg [IQR 4.71–6.38 versus 4.9–5.7 mg/kg]; $p = 0.75$). Rates of IFX regimen enhancement were also similar in both groups (four of 27 versus 14 of 91; $p = 1.00$). Half of the skin reaction group have had at least one previous IFX regimen before their ongoing one, compared with a third (14 of 27 versus 30 of 91; $p = 0.18$) in the group without. Complementary immunosuppressive medication was reported in 20 (74.1%) out of 27 patients with skin events and in 77 (84.6%) out of 91 patients without ($p = 0.25$). Oral corticosteroids were seldom needed and comparable between groups; in one and eight patients in respective groups ($p = 0.68$). As a prophylactic indication for infusion reactions, corticosteroids were intravenously administered to four and 16 patients in the respective groups ($p = 1.00$). Concomitant thiopurine therapy was also similar between groups (51.9% versus 56.0%; $p = 0.83$). Mesalazine was less frequently used in the group with skin reactions (25.9% versus 45.1%; $p = 0.12$). No patients with skin reactions were on methotrexate compared with the event-free group with six patients ($p = 0.33$).

Age (34.0 versus 31.4 years [IQR 27.9–46.5 versus 26.0–31.4]; $p = 0.55$) and age at diagnosis (23.1 versus 22.1 years [IQR 16.4–29.6 versus 17.9–29.8]; $p = 0.97$) were proportionate in patients with skin lesions compared with those without. Montreal classifications of CD and the extent of UC were also similar (data not shown). Lastly, differences in both current and past history of smoking were not observed (31.8% [seven of 22] versus 38.4% [33 of 86]; $p = 0.63$; data not available, $n = 10$).

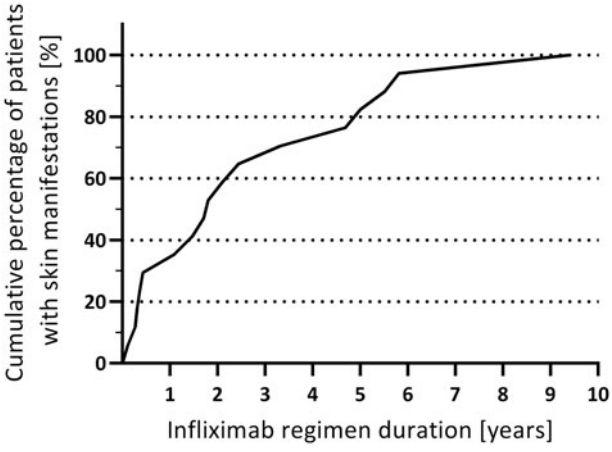

Figure 1. Duration of infliximab therapy in patients with inflammatory bowel disease afflicted by new-onset, exacerbation or re-emergence of skin lesions considered infliximab related ($n = 17$) at the time of observed skin lesion.

A fifth ($n = 24$) of the patients had a history of one or more diagnoses of EIMs: primary sclerosing cholangitis and erythema nodosum in seven (5.9%) each, arthritis in five (4.2%), ankylosing spondylitis and iritis in four (3.4%) each, pancreatitis in two (1.7%) and pyoderma gangrenosum, episcleritis or autoimmune hepatitis each in one patient (0.8%). No differences in the prevalence of EIMs between the two groups were found.

Laboratory findings were also inconclusive. Of the laboratory tests from every infusion, haemoglobin, haematocrit, erythrocyte, leukocyte, platelet and CRP levels were comparable between patients with skin manifestations and those without (data not shown). FC analysis yielded no significant findings between groups (median 77.5 versus 71.5 μg/g [IQR 26.3–166.3 versus 289.0 μg/g]; $p = 0.79$) (76.3%; total number of available samples, $n = 90$; 18 patients with skin manifestations and 72 without). In addition, serum albumin was routinely monitored in only 44 (37.3%), serum IFX levels from 63 (53.4%) and serum IFX antibody levels from 22 (18.6%) patients at some point during the study period. IFX antibodies were observed in three patients; none of them presented with a skin reaction. Group combined medians and IQRs of disease activity markers CRP (median 1.5 mg/l; IQR 1.5–5.0 mg/l), FC (median 76 μg/g; IQR 25–264.3 μg/g) and albumin (median 37.4 g/l; 34.6–39.9 g/l) suggested low disease activity in our total study population.

Type of skin lesions

Of the 27 patients with skin manifestations considered IFX associated, new-onset lesions were observed in eight (29.6%) patients. Exacerbation of existing skin conditions was also reported in eight (29.6%) patients; atopic in five, psoriatic in two and an erythematous presentation in one patient. Additionally, one patient on IFX induction therapy presented with scaling eczema of the scalp and earlobes attributed to previous adalimumab therapy, which initially resolved but later reappeared during IFX maintenance therapy. We observed baseline lesions that remained stable or later resolved in 10 (37.0%) patients. Skin manifestations of probable infectious aetiologies, thus not regarded as skin events, were observed in 13 (11.0%) of all patients: verrucae in five, herpes zoster and folliculitis in three, and a purulent abscess and fungal infection in one patient each. Five acute infusion reactions were also disregarded.

Psoriasiform skin lesions were observed in seven (5.9%) patients during our study period. Two patients had a pre-existing diagnosis of psoriasis before their initial IFX regimen. Of the five (4.2%) patients with plausible anti-TNF-α-induced psoriasis, new-onset

Downloaded by [University of Liverpool] at 03:37 14 January 2016

psoriasis was diagnosed in two (at cumulative infusions 42 and 10) patients. The patient with fewer infusions presented with baseline pustular psoriasis-like lesions in the feet and had an initial FC level of 369 μg/g, which decreased to 84 μg/g 5 weeks before the psoriatic condition exacerbated and spread to the palms. At 4 months after exacerbation, the lesions were markedly improved coinciding with an elevated FC level (1860 μg/g). IFX-associated psorasiform lesions diagnosed before the study period were stable in two and exacerbated in one patient. Interestingly, all these patients had low calprotectin (<100 μg/g) levels. Four of these patients had a perianal ileocolonic CD (female =3; a previous history of anti-TNF-α therapy, $n = 3$) and another patient (female) UC pancolitis.

The anatomical distribution of observed skin manifestations is presented in Figure 2 and descriptions of these skin events in Figure 3. Scaling eczema was described as erythematous in three, dry in one and undescribed in four patients. Excessive dryness was associated with hair loss in one patient. Out of the five patients with anti-TNF-α-induced psoriasis, three presented with psoriasis vulgaris. We observed an unusual presentation of palmoplantar pustulosis in one patient. Two patients had inverse psoriasis; one in combination with psoriasis vulgaris and another with unspecified psoriasiform lesions in the facial area, scalp and ear lobes. The ear lobes were the most often afflicted area in three out of five of these patients. All psoriasis diagnoses were made by a dermatologist. An unfortunate

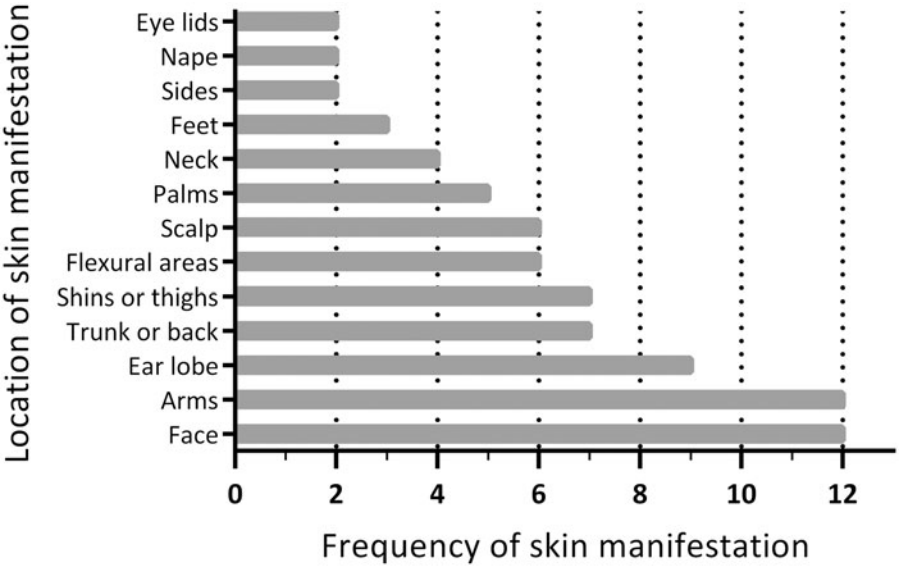

Figure 2. Anatomical distribution of skin manifestations from 27 patients with inflammatory bowel disease and skin manifestations considered infliximab related.

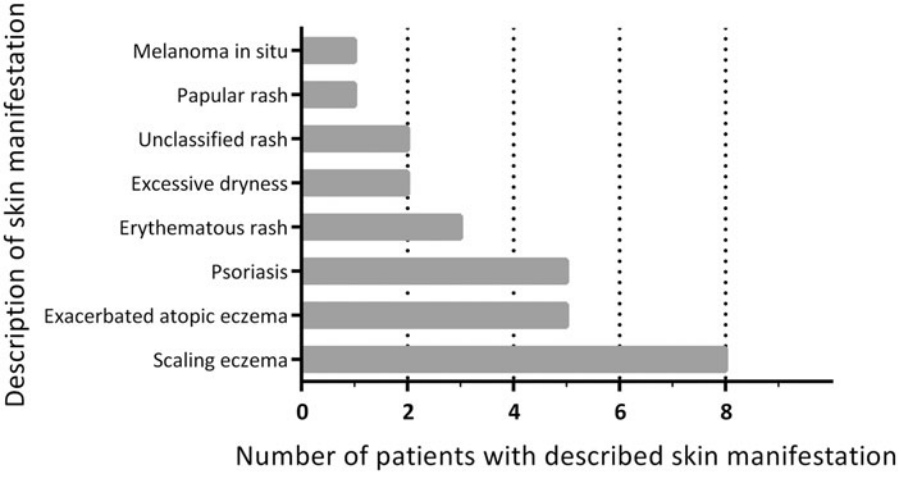

Figure 3. Clinical presentations of skin manifestations considered infliximab related from 27 patients with inflammatory bowel disease.

Downloaded by [University of Liverpool] at 03:37 14 January 2016

presentation of lentigo maligna was considered a skin manifestation due to a 10-year history of IFX treatment.

Outcomes of skin lesions

New-onset skin lesions resolved completely in five of eight patients. Complete improvement of baseline lesions, which did not exacerbate, was observed in five of 11 patients, while only one of eight patients with exacerbated skin lesions showed significant improvement. Topical medication was widely used and prescribed with a low threshold, but data on this were not gathered as less severe skin lesions were often treated outside of our hospital.

Psoriasiform lesions resolved with the combination of topical fusidic acid and corticosteroids in three out of five patients. The two unresolved cases did not respond to topical corticosteroids, although anti-TNF-α therapy was successfully continued without exacerbation of these lesions.

A third ($n = 33$; 28.0%) of the patients discontinued IFX therapy, although two of them restarted IFX therapy during the study period. However, adverse skin reactions did not indicate discontinuation of anti-TNF-therapy. The main reasons for stopping the therapy were either loss of response or failure to induce remission (36.4%) and remission of underlying disease (30.3%). Three patients had to stop therapy due to drug hypersensitivity.

Discussion

Major findings and study strengths

The present study is the second largest prospective study of skin manifestations associated with anti-TNF-agents so far presenting non-infectious dermatological adverse events in 22.9% of the patients, including new-onset skin lesions in 6.8%. CD was the most significant predisposing factor for skin manifestations. The focus on infliximab, the large number of infusions, the single centre data and conscious screening of the skin every 6–10 weeks are the major strengths. Nearly a fifth (18.6%) of the study population experienced a non-infectious non-psoriasiform adverse skin event during our 1-year study period, whereas 4.2% presented with psoriasiform skin eruptions. Almost 80% of patients with any skin manifestations had CD, while slightly under half of the whole study population had the same diagnosis. Patients with adverse skin events also had higher cumulative IFX infusion counts and longer disease and IFX therapy durations, although these findings were not statistically significant. In contrast to previous literature, although often reported in IBD and even rheumatoid [10,20] literature, female gender was not associated with skin manifestations. As the current hypotheses on the mechanisms of action for different anti-TNF-α-induced skin manifestations [4] offer no explanation for this finding, we suspect that reporting bias and the retrospective nature of some studies might strongly impact these findings.

Crohn's disease and skin manifestations: overlapping immunopathogenesis?

There are two main hypotheses suggested for the immunopathogenesis of psoriasiform skin lesions. One theory is that increased interferon-γ production by plasmacytoid dendritic cells secondary to TNF-α antagonism and the following T-cell activation would lead to an increased TNF-α production.[21] The other hypothesis includes Th17 cell enhancement and Treg cell downregulation following TNF-α inhibition that leads to increased Th17 cytokine IL-22 production. IL-22 would then act on keratinocytes and create a proinflammatory loop.[22] The pathogenesis of CD is mediated by Th1 and Th17 cells and their differentiation, too.[23] A gene variant of IL23R was associated with all cases of severe psoriasiform lesions in the study by Tillack et al. Patients with these lesions had a 100% response rate to the IL12/23 monoclonal antibody ustekinumab.[11] Sherlock et al.[15] also reported IL23R polymorphism in their paediatric study.

We observed exacerbated atopic eczema in a fifth of our patients with adverse skin events. Intriguingly, it has been suggested that Th17, although not part of the traditional Th1/Th2 paradigm, might be involved in the exacerbation of atopic dermatitis and inflammatory disorders of the skin.[24,25] These overlapping immunological pathways might explain why CD was strongly associated with skin manifestations in our study.

Clinical viewpoints and characteristics

The face and arms were most often afflicted by any skin lesions in our study. These regions have often also been involved in previous studies.[13,19,16] Although easily perceived as inconsequential by treating physicians, skin lesions, particularly of the facial area, can have a subjectively considerable impact on the patient's quality of life. When afflicted, the ear lobes and scalp were often described as scaling eczema. Thus, it is possible that in our study the prevalence of anti-TNF-α-induced psoriasis could be higher, as these lesions have also often manifested on the ear lobes or scalp in the previous literature.[5,7,11,13,18,19] In this study, we had 13 reported skin manifestations, which were interpreted as reactivation of infection or infections associated with

Downloaded by [University of Liverpool] at 03:37 14 January 2016

Downloaded by [University of Liverpool] at 03:37 14 January 2016

IFX use. From a clinical point of view, it is important to distinguish IFX-caused skin manifestation from infections, as none of the pure cutaneous manifestations required stopping of the therapy. In a prospective paediatric study by Mälkönen et al., children with skin manifestations required less oral corticosteroids, and they had lower FC levels compared with those without. At least a third of the children with skin manifestations had psoriasiform lesions,[5] which is in line with the study by Włodarczyk et al.[13] with adult patients. Neither study reported any differences in disease activity measured by the Crohn's Disease Activity Index (CDAI) or the paediatric equivalent PCDAI, although as in our study, endoscopic disease activity was not assessed. Our findings on CRP, albumin and FC suggest that our population was in deep remission and responded well to IFX therapy. It is noteworthy that all patients with IFX-induced psoriasiform lesions in our study also had their FC levels within reference values. We hope for future prospective studies with systematically gathered FC samples on to investigate this possible relationship.

In contrast to previous prospective IBD studies with high proportions of discontinuations due to any skin manifestations ranging from 6.3% to 22.0%,[5,14,19] no patients in our study had to stop their IFX regimen due to skin events. Denadai et al.[12] also reported that out of all reviewed cases of anti-TNF-α-induced psoriasis in IBD patients, 38.7% of the patients had to stop and 13.1% had to switch anti-TNF-α therapy, although it is speculative if the patients could have endured continued anti-TNF-α therapy combined with topical medication. Thus, identifying these paradoxical lesions, and treating them accordingly is of importance. Collamer et al. have proposed a treatment algorithm for anti-TNF-α-induced psoriasiform lesions: Topical medication should be given when lesions cover <5% of body surface area and combined with ultraviolet phototherapy when lesions exceed 5%. Additionally, systemic methotrexate should be added if response is not achieved,[26] or perhaps ustekinumab. Topical management of all skin lesions, in our experience, have proven to be effective at early intervention.

Anti-TNF-α-induced paradoxical psoriasis

Plaque psoriasis was the most common clinical psoriatic presentation in our study, which is also in line with Denadai et al.'s systematic review. With at least a third of the diagnoses biopsy-confirmed, they reported psoriasiform lesions as the most common psoriatic presentation (56%), followed by plaque psoriasis (21%) and pustular psoriasis (4%).[12]

The prevalence of psoriasis in the general population of the US and UK are 2.6% and 1.5%, respectively.[27,28] Two case–control studies from 1982 [29] and 1990,[30] before the introduction of biologics, reported a several-fold increase compared with controls in the prevalence of psoriasis in CD and UC patients, 9.6–11.2% and 5.7%, respectively. A huge case–control study ($n = 12{,}502$) reported that, independent of anti-TNF-α therapy, the prevalence of IBD in patients with psoriasis is higher than in the general population.[31] As such, psoriasis can be regarded as an EIM of IBD.[32] A recent study by Lolli et al. suggested that IBD-associated psoriasis could be milder when compared with non-IBD patients.[33] This does not seem to hold true when anti-TNF-α therapy is involved, as psoriasiform lesions are often severe enough to lead to withdrawal of therapy.[11,12] Mälkönen et al. investigated the presence of the HLA-Cw*0602 allele associated with psoriasis in paediatric patients with skin manifestations. Surprisingly, only 12.9% of patients tested positive for the allele.[5] It remains unclear if anti-TNF-α-induced psoriasis and extraintestinal psoriasis are two different entities.

Limitations

Contrary to the study design, some study sheets were self-reported or based on an interview. The descriptions of skin presentations on these sheets were often unspecific, which might lead to reporting bias. The prevalence of skin lesions is still likely to be accurate as adult patients are well capable of reporting their symptoms. Another problem arises from the classification of these skin manifestations. Some underestimation of the prevalence of skin lesions might have occurred in regions of the scalp, ear lobes, back and other less visible areas to the patient. In the medical records, skin manifestations were in roughly one third of the patients either vaguely or not at all described. Patients did not regularly see a dermatologist for their skin symptoms, which might influence our results.

Conclusion

In conclusion, our prospective study supports previous literature on the prevalence of anti-TNF-α-induced psoriasis (4.2%) and non-psoriasiform skin lesions (18.6%). The proportion of diagnosis of CD was significantly higher in the patient group with skin events in our study population. It is clinically important to introduce topical medications to chronic skin events to ensure that anti-TNF-α therapy is not unnecessarily stopped.

Downloaded by [University of Liverpool] at 03:37 14 January 2016

Declaration of interest

The authors report that they have no conflicts of interest. The authors alone are responsible for the content and writing of this paper.

Funding

Our study was supported by the Sigrid Jusélius Foundation and the Foundation for Paediatric Research.

References

[1] Dignass A, Van Assche G, Lindsay JO, et al. The second European evidence-based consensus on the diagnosis and management of Crohn's disease: current management. J Crohns Colitis. 2010;4:28–62.
[2] Dignass A, Lindsay JO, Sturm A, et al. Second European evidence-based consensus on the diagnosis and management of ulcerative colitis. Part 2: current management. J Crohns Colitis. 2012;6:991–1030.
[3] Van Assche G, Lewis JD, Lichtenstein GR, et al. The London position statement of the World Congress of Gastroenterology on Biological Therapy for IBD with the EuropeanCrohn's and Colitis Organisation: safety. Am J Gastroenterol. 2011;106:1594–1602.
[4] Mocci G, Marzo M, Papa A, et al. Dermatological adverse reactions during anti-TNF treatments: focus on inflammatory bowel disease. J Crohns Colitis. 2013;7:769–779.
[5] Mälkönen T, Wikström A, Heiskanen K, et al. Skin reactions during anti-TNFα therapy for pediatric inflammatory bowel disease: a 2-year prospective study. Inflamm Bowel Dis. 2014;20:1309–1315.
[6] Hiremath G, Duffy L, Leibowitz I. Infliximab-induced psoriasis in children with inflammatory bowel disease. J Pediatr Gastroenterol Nutr. 2011;52:230–232.
[7] Sherlock ME, Walters T, Tabbers MM, et al. Infliximab-induced psoriasis and psoriasiform skin lesions in pediatric Crohn disease and a potential association with IL-23 receptor polymorphisms. J Pediatr Gastroenterol Nutr. 2013;56:512–518.
[8] Flendrie M, Vissers WHPM, Creemers MCW, et al. Dermatological conditions during TNF-alpha-blocking therapy in patients with rheumatoid arthritis: a prospective study. Arthritis Res Ther. 2005;7:R666–R676.
[9] Lee HH, Song IH, Friedrich M, et al. Cutaneous side-effects in patients with rheumatic diseases during application of tumour necrosisfactor-alpha antagonists. Br J Dermatol. 2007;156:486–491.
[10] Machado NP, Torresdos Reis Neto E, Soares MRMP, et al. The skin tissue is adversely affected by TNF-alpha blockers in patients with chronic inflammatory arthritis: a 5-year prospective analysis. Clinics. 2013;68:1189–1196.
[11] Tillack C, Ehmann LM, Friedrich M, et al. Anti-TNF antibody-induced psoriasiform skin lesions in patients with inflammatory bowel disease are characterised by interferon-γ-expressing Th1 cells and IL-17A/IL-22-expressing Th17 cells and respond to anti-IL-12/IL-23 antibody treatment. Gut. 2014;63:567–577.
[12] Denadai R, Teixeira FV, Steinwurz F, et al. Induction or exacerbation of psoriatic lesions during anti-TNF-α therapy for inflammatory bowel disease: a systematic literature review based on 222 cases. J Crohns Colitis. 2013;7:517–524.
[13] Baumgart DC, Grittner U, Steingräber A, et al. Frequency, phenotype, outcome and therapeutic impact of skin reactions following initiation of Adalimumab therapy: experience from a consecutive cohort of inflammatory bowel disease patients. Inflamm Bowel Dis. 2011;17:2512–2520.
[14] Włodarczyk M, Sobolewska A, Wójcik B, et al. Correlations between skin lesions induced by anti-tumor necrosis factor-α and selected cytokines in Crohn's disease patients. World J Gastroenterol. 2014;20:7019–7026.
[15] Huang VWM, Dhami N, Fedorak D, et al. A study investigating the association of dermatological and infusion reactions to infliximab and infliximab trough levels. Can J Gastroenterol. 2015;29:35–40.
[16] Fidder H, Schnitzler F, Ferrante M, et al. Long-term safety of infliximab for the treatment of inflammatory bowel disease: a single-centre cohort study. Gut. 2009;58:501–508.
[17] Cullen G, Kroshinsky D, Cheifetz AS, et al. Psoriasis associated with anti-tumournecrosis factor therapy in inflammatory bowel disease: a new series and a review of 120 cases from the literature. Aliment Pharmacol Ther. 2011;34:1318–1327.
[18] Guerra I, Algaba A, Pérez-Calle JL, et al. Induction of psoriasis with anti-TNF agents in patients with inflammatory bowel disease: a report of 21 cases. J Crohns Colitis. 2012;6:518–523.
[19] Cleynen I, Vermeire S. Paradoxical inflammation induced by anti-TNF agents in patients with IBD. Nat Rev Gastroenterol Hepatol. 2012;9:496–503.
[20] Hernández MV, Sanmartí R, Cañete JD, et al. Cutaneous adverse events during treatment of chronic inflammatory rheumatoid conditions with tumor necrosis factor antagonists: study using the Spanish Registry of adverse events of biological therapies in rheumatoid diseases. Arthritis Care Res. 2013;65:2024–2031.
[21] Collamer AN, Battafano DF. Psoriatic skin lesions induced by tumor necrosis factor antagonist therapy: clinical features and possible immunopathogenesis. Semin Arthritis Rheum. 2010;40:233–240.
[22] Ma HL, Napierata L, Stedman N, et al. Tumor necrosis factoralpha blockade exacerbates murine psoriasis-like disease by enhancing Th17 function and decreasing expansion of Treg cells. Arthritis Rheum. 2010;62:430–440.
[23] Brand S. Crohn's disease: Th1, Th17 or both? The change of a paradigm: new immunological and genetic insights implicate Th17 cells in the pathogenesis of Crohn's disease. Gut. 2009;58:1152–1167.
[24] Koga C, Kabashima K, Shiraishi N, et al. Possible pathogenic role of Th17 cells for atopic dermatitis. J Invest Dermatol. 2008;128:2625–2630.
[25] Asarch A, Barak O, Loo DS, et al. Th17 cells: a new paradigm for cutaneous inflammation. J Dermatol Treat. 2008;19:259–266.
[26] Collamer AN, Guerrero KT, Henning JS, et al. Psoriatic skin lesions induced by tumor necrosis factor antagonist therapy: a literature review and potential mechanisms of action. Arthritis Rheum. 2008;59:996–1001.
[27] Koo J. Population-based epidemiologic study of psoriasis with emphasis on quality of life assessment. Dermatol Clin. 1996;14:485–496.

[28] Gelfand JM, Weinsten R, Porter SB, et al. Prevalence and treatment of psoriasis in the United Kingdom: a population-based study. Arch Dermatol. 2005;141: 1537–1541.
[29] Yates VM, Watkinson G, Kelman A. Further evidence for an association between psoriasis, Crohn's disease and ulcerative colitis. Br J Dermatol. 1982;106:323–330.
[30] Lee FI, Bellary SV, Francis C. Increased occurrence of psoriasis in patients with Crohn's disease and their relatives. Am J Gastroenterol. 1990;85:962–963.
[31] Cohen AD, Dreiher J, Birkenfeld S. Psoriasis associated with ulcerative colitis and Crohn's disease. J Eur Acad Dermatol Venereol. 2009;23: 561–565.
[32] Levine JS, Burakoff R. Extraintestinal, manifestations of inflammatory bowel disease. Gastroenterol Hepatol. 2011;7:235–241.
[33] Lolli E, Saraceno R, Calabrese E, et al. Psoriasis phenotype in inflammatory bowel disease: a case–control prospective study. J Crohns Colitis. 2015;9:699–707.

Downloaded by [University of Liverpool] at 03:37 14 January 2016