Journal Pre-proof



Delivery of infection from asymptomatic carriers of COVID-19 in a familial cluster

Feng Ye, Shicai Xu, Zhihua Rong, Ronghua Xu, Xiaowei Liu, Pingfu Deng, Hai Liu, Xuejun Xu

PII: S1201-9712(20)30174-0

DOI: https://doi.org/10.1016/j.ijid.2020.03.042

Reference: IJID 4048

To appear in: *International Journal of Infectious Diseases*

Received Date: 25 February 2020

Revised Date: 16 March 2020

Accepted Date: 18 March 2020

Please cite this article as: { doi: https://doi.org/

This is a PDF file of an article that has undergone enhancements after acceptance, such as the addition of a cover page and metadata, and formatting for readability, but it is not yet the definitive version of record. This version will undergo additional copyediting, typesetting and review before it is published in its final form, but we are providing this version to give early visibility of the article. Please note that, during the production process, errors may be discovered which could affect the content, and all legal disclaimers that apply to the journal pertain.

© 2019 Published by Elsevier.

Journal Pre-proof

Delivery of infection from asymptomatic carriers of COVID-19 in a familial cluster

Feng Ye[1]*, Shicai Xu[2]*, Zhihua Rong[3], Ronghua Xu[1], Xiaowei Liu[1], Pingfu Deng[1], Hai Liu[4], Xuejun Xu[1]

1 Department of Neurosurgery, The Second People's Hospital of Chengdu, Chengdu, China.

2 Department of Surgery, People's Hospital of Luxian County, Luzhou, China.

3 Department of Surgery, The Affiliated Hospital of Southwest Medical University, Luzhou, China.

4 Luzhou Center for Disease Control and Prevention, Luzhou, China.

Correspondence: Xuejun Xu, Department of Neurosurgery, The Second People's Hospital of Chengdu, 10 Qingyun South Street, Chengdu, Sichuan 610021, China.

E-mail: docxxj@163.com.

*These authors contributed equally to this study.

E-mail address of all authors

FY: yefeng19930@126.com

SCX: xsc691092906@163.com

ZHR: doctorrzh@126.com

RHX: 1442416311@qq.com

XWL: 625289749@qq.com

PFD: 743371203@qq.com

Journal Pre-proof

Journal Pre-proof

HL: liuhai6233@163.comXXJ: docxxj@163.com

Highlights

- There are more than 100,000 confirmed COVID-19 cases, with spread to over 100 countries as of 2020-03-08.
- Asymptomatic carriers during the incubation period can be a latent infection source of COVID-19.
- Person-to-person transmission has been ascertained, whereas asymptomatic spreaders should also be a concern for disease prevention.

Abstract

Objectives: With the ongoing outbreak of COVID-19 around the world, it has become a worldwide health concern. One previous study reported a family cluster with asymptomatic transmission of COVID-19. Here, we report another series of cases and further demonstrate the repeatability of the transmission of COVID-19 by pre-symptomatic carriers.

Methods: A familial cluster of five patients associated with COVID-19 was enrolled in the hospital. We collected epidemiological and clinical characteristics, laboratory outcomes from electronic medical records, and also affirmed them with the patients and their families.

Results: Among them, three family members(Case 3/4/5) had returned from Wuhan. Additionally, two family members, those who had not travelled to Wuhan, also

Journal Pre-proof

Journal Pre-proof

contracted COVID-19 after contacting with the other three family members. Case 1 developed severe pneumonia and was admitted to the ICU. Case 3 and Case 5 presented fever and cough on days 2 through 3 of hospitalization and had ground-glass opacity changes in their lungs. Case 4 presented with diarrhoea and pharyngalgia after admission without radiographic abnormalities. Case 2 presented no clinical or radiographic abnormalities. All the cases had an increasing level of C-reactive protein.

Conclusions: Our findings indicate that COVID-19 can be transmitted by asymptomatic carriers during the incubation period.

Keywords: COVID-19; SARS-CoV-2; Asymptomatic carrier; Incubation period; Pneumonia

Journal Pre-proof

Introduction

On Dec 31, 2019, the government of Hubei Province, China, first reported a

Journal Pre-proof

group of confused patients with pneumonia[1]. Metagenomics sequencing analysis revealed a novel coronavirus, which was officially named SARS-CoV-2 and is the cause of the disease named COVID-19[2]. The National Health Commission (NHC) set COVID-19 as a category B infectious disease with A-class management on Jan 20[1]. Furthermore, on Jan 30, the WHO issued a Public Health Emergency of International Concern (PHEIC) alarm and appealed all specialists over the world working together to control the rapid spread of COVID-19. As of Mar 8, there had been 80,859 confirmed patients of COVID-19 in China, including 3,100 deaths. Internationally, over 100 countries have now reported laboratory-confirmed cases, including a total of 24,031 cases[3].

The first clinical data from 41 individuals with a confirmed diagnosis of COVID-19 from Wuhan, China, have been published[4]. Most of them had been directly exposed to the Wuhan seafood wholesale market, which sells freshly slaughtered game animals, that were the original infection source[4]. The present data strongly suggest that game animals or mammals were probably intermediate hosts of SARS-CoV-2 that originated from the Chinese horseshoe bat[5, 6]. In addition, the virus has preferential tropism to human airway epithelial cells through the same cellular receptor as that for SARS, angiotensin-converting enzyme 2(ACE2), which is a central body receptor for the surface glycoprotein S of the virus[7]. The way to ascertain disease depends on positive real-time reverse transcription-polymerase chain reaction(rRT-PCR) results for SARS-CoV-2 nucleic acid, and the associated mortality rates are 2-3%[3, 8]. Currently, there are no definite antiviral therapies or vaccines for

Journal Pre-proof

COVID-19, although some drugs are under investigation.

With the extensive outbreak of COVID-19, a mass of studies with a larger population have been reported. Obviously, the total number of cases and transmission events have far exceeded those of SARS and H1N1. Wu et al.[9] found that the mean R_0 of COVID-19 was approximately 2.68(95% CI: 2.47-2.86). An increasing number of outbreaks of familial transmission stressed the possibility of person-to-person transmission[10-12]**.** The measures in which public health officials quarantine confirmed cases and isolate intimate patients are significant progress in responding to COVID-19 control. Another question for consideration is a group of asymptomatically infected individuals, which may propagate the virus and impede infection control[5,13]. Bai et al.[14] presented clinical data showing a familial cluster of 5 patients with COVID-19 and 1 asymptomatic family member, which presumed the possibility of infection from asymptomatic carriers.

In this study, we report the clinical features of a family cluster involving five COVID-19 cases in Luzhou. Three cases came from Wuhan, and the other two cases had not left Luzhou recently. Our data further verified the delivery of infection from asymptomatic carriers of COVID-19 during the incubation period.

Methods

On Feb 4, a 50-year-old woman(Case 1) was admitted to the People's Hospital of Luxian County(Luzhou, Sichuan Province, China) with fever, dizziness, cough and shortness of breath. On examination, her maximum temperature was 39. 1°C, and her

Journal Pre-proof

blood pressure was 152/93 mmHg. A chest CT scan revealed massive shadows of high density in the lungs. The local CDC performed rRT-PCR tests for SARS-CoV-2 nucleic acid, and a throat swab was positive(Ct values, 19). Then, Case 1 was diagnosed and immediately isolated.

Subsequently, forty-four other intimate contacts were admitted to our hospital for general physical examination on Feb 5. The local CDC ascertained that the nasopharyngeal or oropharyngeal swabs were positive for 4 cases(Case 2/3/4/5) according to SARS-CoV-2 nucleic acid tests(Table 2). All cases were enrolled in hospital and treated in isolation. A detailed data collection for the five patients was executed, and all patients underwent chest CT imaging. All the laboratory procedures for clinical samples have been previously reported[15]. Nasopharyngeal and oropharyngeal swabs and stool and urine samples were obtained and maintained viral transport medium. Plasma was separated from EDTA bottles, and serum was separated from clotted blood bottles. Specimens were placed between 2°C and 8°C and sent to the CDC. RRT-PCR tests for SARS-CoV-2 nucleic acid were performed by the local CDC, , and the detection reagents were from Maccura Biotechnology Co.,Ltd and Sansure Biotechnology Co.,Ltd.

The Ethics Committee of the People's Hospital of Luxian County approved this study. We obtained written consent from all the patients about clinical data, radiographic pictures, information, etc.

Results

Journal Pre-proof

Journal Pre-proof

We documented and analysed the clinical symptoms, laboratory results, and history of five cases with verified COVID-19, as presented in Table 1. The relationship between the 5 cases and their general information are shown in Figure 3.

Case 1, a 50-year-old woman, had lived in Luzhou year-round and had hypertension and chronic emphysema disease. Between Jan 23 and Jan 25, she attended the family reunion dinner with her family members(Case 2/3/4/5). On Jan 30, they celebrated the Spring Festival together. Because of the limits on access, Case 1 could not leave her hometown in the countryside, where there had been no previous reports of COVID-19. Furthermore, she had not been in contact with any person returning from Wuhan(except Case 3/4/5). In particular, Case 1 did not present any symptoms until Feb 1. She became ill with fever, and non-productive cough, and she took drugs at that time. By the evening, Case 1 started feeling better and continued to enjoy the Spring Festival. However, two days later, a fever of 38.6°C recurred, along with dizziness, non-productive cough, and shortness of breath. She was presented to the hospital by her son on Feb 4(Figure 2). The laboratory examination revealed an increasing level of white blood cell count (12.4×10^9/L), neutrophil count(7.82×10^9/L), C-reactive protein level (189.2 mg/L) and a low lymphocyte count(0.84×10^9/L) and platelet count(88×10^9/L) (Table 1). CT images showed massive shadows of high density in the lungs(Figure 1). Case 1 developed severe pneumonia and was enrolled in the ICU as dyspnoea increased, with hypoxemia on day 2 of hospitalization. As of Feb 15, her clinical condition had improved, and her oxygen saturation values recovered to 94% on supplemental oxygen. A nasopharyngeal and a oropharyngeal

Journal Pre-proof

swab obtained on admission day 10 remained positive for SARS-CoV-2(Table 2).

Case 2, a 28-year-old man, was living in Luzhou. He had not come to an area where COVID-19 was spreading or had contact with any fever or pneumonia patients. He had just attended the family reunion dinner with his family members, including his mother (Case 1)/uncle(Case 3)/aunt(Case 4)/cousin(Case 5) on Jan 23 through 25. After the diagnosis of COVID-19, he never had an elevated temperature, and there were no abnormal symptoms except an increasing level of C-reactive protein (10.5 mg/L) and a reduced lymphocyte count(1.03×10^9/L). Chest CT images showed no significant abnormalities(Figure 1).

On Jan 22, Case 4, a migrant who did business in Wuhan, drove back to Luzhou with Case 3 and Case 5 for the Spring Festival. On Feb 5, she also presented to the hospital, and a nasopharyngeal swab was positive for SARS-CoV-2(Ct values, 26). Her chest CT images were standard(Figure 1). From Jan 22 to Feb 4, Case 4 did not present any symptoms until 7 PM on Feb 5. She started having slight pharyngalgia and diarrhoea (3-5 times per day) without increasing body temperature or cough. Laboratory examination indicated a rising C-reactive protein (43.5 mg/L), and her platelet count decreased(72×10^9/L). Case 4 was started on oxygen support at 2 L per minute and was treated with oseltamivir (75 mg every 12 hours), dioctahedral smectite powder (3 g every 8 hours) and cefixime (100 mg every 12 hours). Two days later, she felt better. Her rRT-PCR results were negative on Feb 15(Table 2).

Case 3 and Case 5 are previously healthy men without a history of hypertension or type 2 diabetes. On days 3 through 5 of hospitalization, they developed fever and

Journal Pre-proof

cough symptoms. Chest CT scans showed ground-glass opacities in the lungs(Figure 1), and other laboratory examinations showed mildly decreasing lymphocyte counts(Table 1) and increasing C-reactive protein (9.0/24.7 mg/L). Their infections were moderate. Although their symptoms had resolved except cough, they remained hospitalized because their rRT-PCR test results were positive as of Feb 15(Table 2).

Discussion

COVID-19 has been proven to be transmitted through the respiratory tract, digestive system, and mucosal surfaces(such as the conjunctiva)[10,16]. Nosocomial infections in healthcare facilities also occur and highlight the significance of effective infection control[13]. At the onset, the symptoms are usually fever, cough, shortness of breath and pharyngalgia or diarrhoea[17]. The emblematic radiologic characteristic is ground-glass opacities in the lungs. Laboratory data present as lymphocytopenia, hypoxemia, thrombocytopenia, and even liver and kidney dysfunction in severe pneumonia patients[4]. At present, verified patients are the primary sources of infection, while asymptomatic carriers can also be a source to propagate the outbreak. These patients are not easy to detect when initially infected but might have abnormal symptoms later[4].

In this familial cluster of five patients associated with COVID-19 in Luzhou, China, Case 1 had contact with only her family members(Case 2/3/4/5), some of them must be asymptomatic carriers of COVID 19. It was certain that Case 2 through 5 had no abnormal symptoms before the outbreak of Case 1. Notably, COVID-19 is highly

Journal Pre-proof

infectious, and may be transmitted by asymptomatic carriers during the incubation period. The timeline events suggest that Case 4 was the most likely initial infection source, as the time of the onset of symptoms and negative rRT-PCR results was relatively earlier than Case 3 and Case 5(Figure 2). Case 2 was afebrile without any clinical signs, and his chest CT images showed no abnormalities on Feb 5 and Feb 15(Figure 1), which also proved the existence of asymptomatic carriers. Our findings provide evidence that asymptomatic carriers can be a latent source of COVID-19 infection. As the spread of COVID-19 is aggravating worldwide, it is pressing to provide more meritorious information for an improved understanding of the transmission and precaution of COVID-19. Further studies on the mechanism in which asymptomatic carriers can acquire and transmit COVID-19 are warranted.

Declarations

Authors' Contributions

All of the authors collected epidemiological and clinical data and discussed the results. FY drafted the article. ShXu contributed to conclude all clinical data. ZRo and PDe analysed all epidemiological data. XXu and RXu revised the final manuscript.

Funding

This work was not funded and did not receive any specific grant from funding agencies in the public, commercial, or not-for-profit sectors.

Journal Pre-proof

Journal Pre-proof

Ethical approval

The Ethics Committee of People's Hospital of Luxian County approved this study. We obtained written consent from all the patients about clinical data, radiographic pictures, information, etc.

Conflict of Interest

The authors declare that there are no conflicts of interest.

Conflict of Interest Statement

No conflict of interest exits in the submission of this manuscript, and manuscript is approved by all authors for publication. We all read "Instructions to Authors" and comply with those instructions and accept the conditions posed. I would like to declare on behalf of my co-authors that the work described was original research that has not been published previously, and not under consideration for publication elsewhere, in whole or in part. If the paper is accepted, it will not be published elsewhere in the same form, in English or in any other language, without written consent of the copyright holder.

Acknowledgements

The authors would like to acknowledge the Luzhou CDC for performing SARS-CoV-2 nucleic acid tests, and thank AJE Editing Service (https://www.aje.com)

Journal Pre-proof

Journal Pre-proof

for editing this manuscript.

Availability of data and materials

All data and materials used in this work are publicly available.

Journal Pre-proof

Journal Pre-proof

References

1. **The Central Government of the People's Republic of China. [Accessed 9 Feb. 2020].** Available from: http://www.gov.cn.
2. **World health Organization. WHO Director-General's remarks at the media briefing on 2019-nCoV on 11 February 2020. [Accessed 11 February 2020]** Available from: https://www.who.int/home.
3. **World Health Organization, "Coronavirus disease 2019 (COVID-2019) Situation Report -48" (WHO,2020). [Accessed 8 March 2020] .** Available from: https://www.who.int/docs/default-source/coronaviruse/situation-reports/20200308-sitrep-48-covid-19.pdf?sfvrsn=16f7ccef_4.
4. Huang C, Wang Y, Li X, Ren L, Zhao J, Hu Y, Zhang L, Fan G, Xu J, Gu X: **Clinical features of patients infected with 2019 novel coronavirus in Wuhan, China.** The Lancet 2020.
5. Zhou P, Yang X-L, Wang X-G, Hu B, Zhang L, Zhang W, Si H-R, Zhu Y, Li B, Huang C-L: **Discovery of a novel coronavirus associated with the recent pneumonia outbreak in humans and its potential bat origin.** bioRxiv 2020.
6. Lu R, Zhao X, Li J, Niu P, Yang B, Wu H, Wang W, Song H, Huang B, Zhu N: **Genomic characterisation and epidemiology of 2019 novel coronavirus: implications for virus origins and receptor binding.** The Lancet 2020.
7. Munster VJ, Koopmans M, van Doremalen N, van Riel D, de Wit E: **A novel coronavirus emerging in China—key questions for impact assessment.** New England Journal of Medicine 2020.
8. Chen N, Zhou M, Dong X, Qu J, Gong F, Han Y, Qiu Y, Wang J, Liu Y, Wei Y: **Epidemiological and clinical characteristics of 99 cases of 2019 novel coronavirus pneumonia in Wuhan, China: a descriptive study.** The Lancet 2020.
9. Wu JT, Leung K, Leung GM: **Nowcasting and forecasting the potential domestic and international spread of the 2019-nCoV outbreak originating in Wuhan, China: a modelling study.** The Lancet 2020.
10. Chan JF-W, Yuan S, Kok K-H, To KK-W, Chu H, Yang J, Xing F, Liu J, Yip CC-Y, Poon RW-S: **A familial cluster of pneumonia associated with the 2019 novel coronavirus indicating**

Journal Pre-proof

person-to-person transmission: a study of a family cluster. The Lancet 2020.

11. Rothe C, Schunk M, Sothmann P, Bretzel G, Froeschl G, Wallrauch C, Zimmer T, Thiel V, Janke C, Guggemos W: **Transmission of 2019-nCoV infection from an asymptomatic contact in Germany.** New England Journal of Medicine 2020.
12. Phan LT, Nguyen TV, Luong QC, Nguyen TV, Nguyen HT, Le HQ, Nguyen TT, Cao TM, Pham QD: **Importation and human-to-human transmission of a novel coronavirus in Vietnam.** New England Journal of Medicine 2020.
13. Zhang H, Kang Z, Gong H, Xu D, Wang J, Li Z, Cui X, Xiao J, Meng T, Zhou W: **The digestive system is a potential route of 2019-nCov infection: a bioinformatics analysis based on single-cell transcriptomes.** bioRxiv 2020.
14. Bai Y, Yao L, Wei T, Tian F, Jin D-Y, Chen L, Wang M: **Presumed Asymptomatic Carrier Transmission of COVID-19.** JAMA 2020.
15. To KK, Chan KH, Li IW, Tsang TY, Tse H, Chan JF, Hung IF, Lai ST, Leung CW, Kwan YW: **Viral load in patients infected with pandemic H1N1 2009 influenza A virus.** Journal of medical virology 2010, **82:**1-7.
16. To KK-W, Tsang OTY, Chik-Yan Yip C, Chan K-H, Wu T-C, Chan J, Leung W-S, Chik TS-H, Choi CY-C, Kandamby DH: **Consistent detection of 2019 novel coronavirus in saliva.** Clinical Infectious Diseases 2020.
17. **National Health Commission of the People's Republic of China. Diagnosis and treatment of novel coronavirus infected pneumonia (The sixth edition). [Accessed 19 Feb. 2020].** http://www.nhc.gov.cn.

Journal Pre-proof

Journal Pre-proof

Figure 1. Respectively, the chest CT images of five Cases. (A).Massive shadows of high density of Case 1. (B/D). No abnormalities of Case 2 and Case 4. (C/E). Ground-glass changes of Case 3 and Case 5.

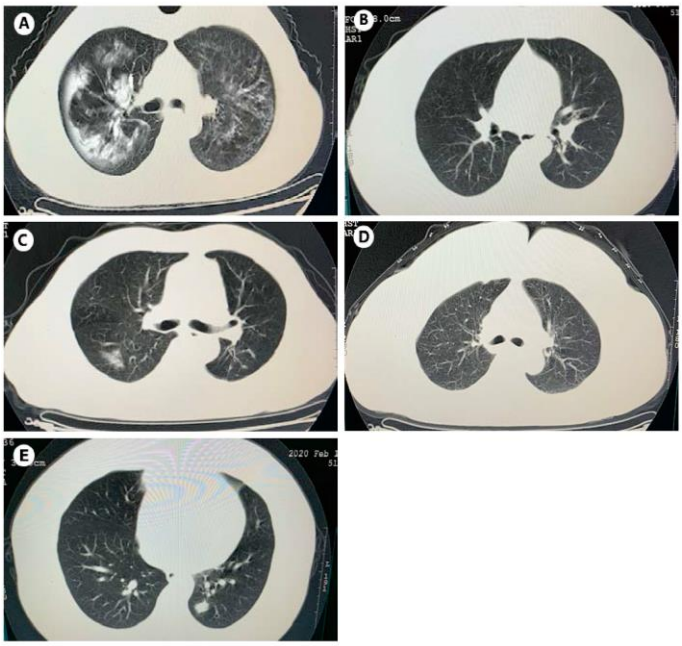

Figure 2. Timeline of exposure to the asymptomatic carrier of COVID-19 which leads to a familial cluster infection.

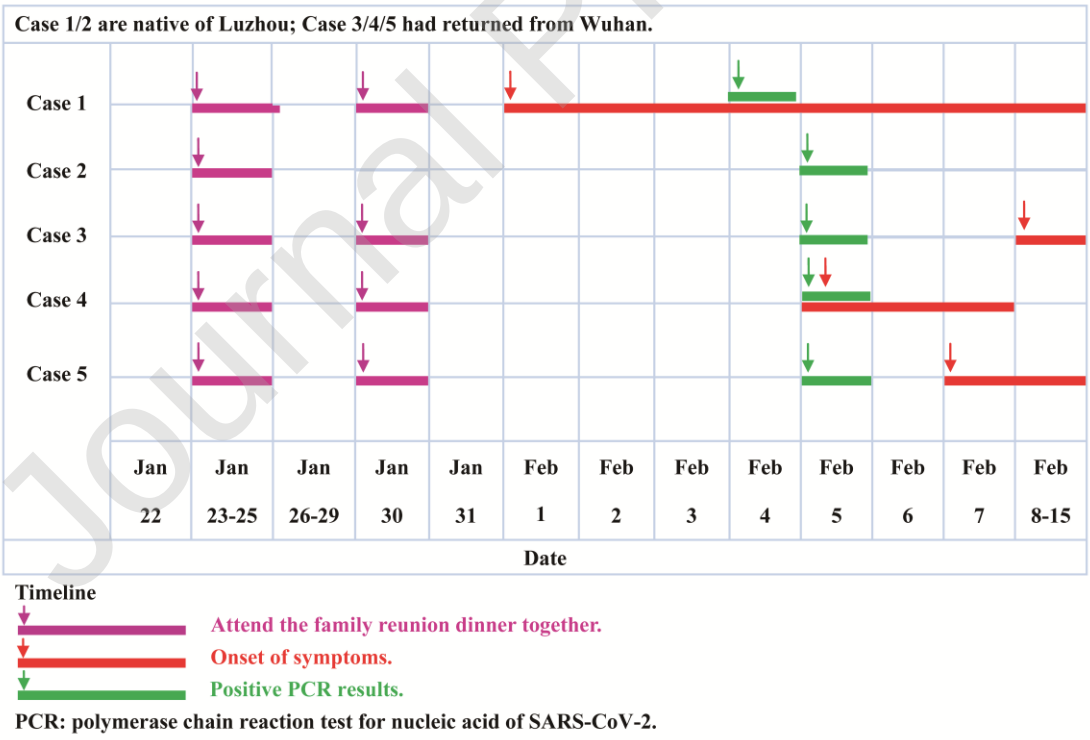

Figure 3. The relationship between the 5 cases and their general information.

Journal Pre-proof

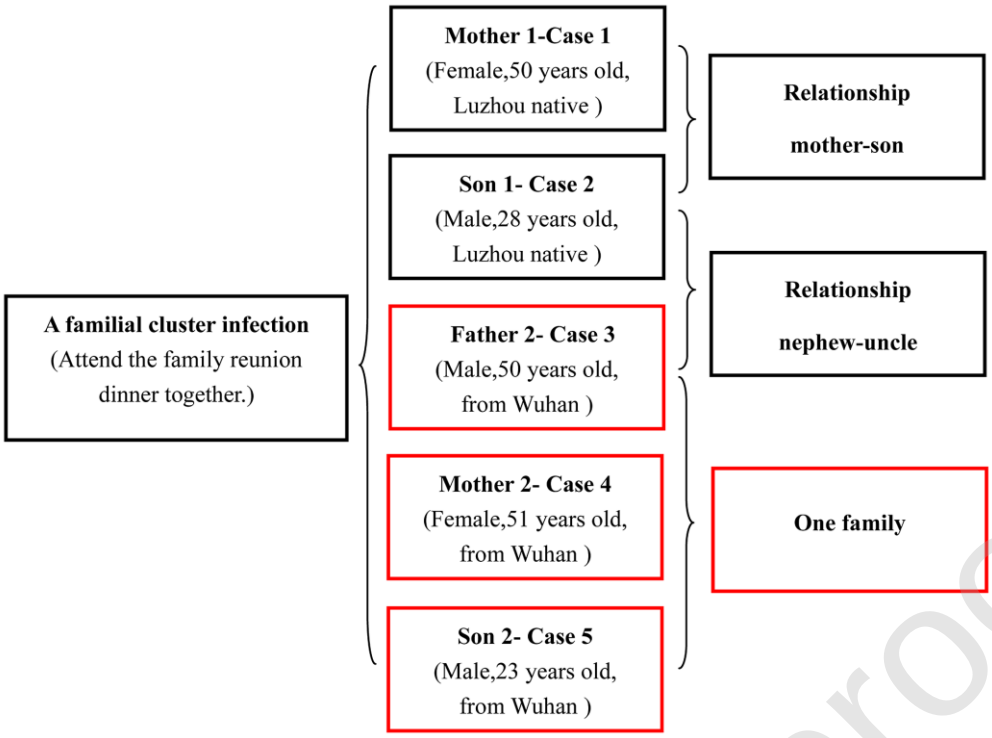

Journal Pre-proof

Journal Pre-proof

	Case 1	Case 2	Case 3	Case 4	Case 5
Relationship	**Mother of Case 2**	**Son of Case 1**	**Father of Case 5**	**Mother of Case 5**	**Son of Case3 and 4**

Table 1: Summary of clinical features and laboratory results of a family cluster infected with COVID-19.

Journal Pre-proof

Journal Pre-proof

Age(years)	50	28	50	51	23
Sex	Female	Male	Male	Female	Male
Occupation	Farmer	Worker	Trader	Trader	Trader
Chronic medical illness	Hypertension,emphysema	None	None	None	None
Presenting symptoms and signs					
Fever	+	-	+(hospital exposure)	-	+(hospital exposure)
Cough	+	-	+(hospital exposure)	-	+(hospital exposure)
Dizziness	+	-	-	-	-
Shortness of breath	+	-	-	-	-
Stuffiness	-	-	-	-	-
Diarrhoea	-	-	-	+(hospital exposure)	-
Pharyngalgia	-	-	-	+(hospital exposure)	-
Body temperature (°C)	39.1	36.2	38.2(hospital exposure)	37.0	38.0(hospital exposure)
Oximetry saturation (%)	low90% (hospital exposure)	94%	92%	92%	98%
White blood cell count (× 10^9 cells per L); (normal range4.00–10.00)	12.4 (↑)	6.12	9.57	7.44	8.24

Journal Pre-proof

Neutrophil count (× 10^9 cells per L); (normal range1.80–6.30)	**7.82 (↑)**	**3.57**	**4.11**	**5.25**	**3.13**
Lymphocyte count (× 10^9 cells per L);(normal range 1·10–3·20)	**0.84 (↓)**	**1.03(↓)**	**1.07(↓)**	**1.70**	**2.46**
Haemoglobin (g/dL); (normal range 120 –160)	**140**	**152**	**166(↑)**	**147**	**164(↑)**
Platelet count (× 10^9 cells per L); (normal range100–300)	**88 (↓)**	**156**	**187**	**72(↓)**	**242**
C-reactive protein (mg/L); (normal range 0·0–5·0)	**189.2 (↑)**	**10.5(↑)**	**9.0(↑)**	**43.5(↑)**	**24.7(↑)**

NA=not available. +=positive. –=negative. ↑=above normal range. ↓=below normal range

Journal Pre-proof

Journal Pre-proof

Table 2. Results of rRT-PCR test for SARS-CoV-2 nucleic acid.

	Case 1		**Case 2**		**Case 3**		**Case 4**		**Case 5**	
Date / Specimen	Feb 4	Feb 14	Feb 5	Feb 12	Feb 5	Feb 15	Feb 5	Feb 15	Feb 5	Feb 15
Nasopharyngeal swab	NA	+(Ct 37)	+(Ct 30)	-	+(Ct 22)	+(Ct 33)	+(Ct 26)	-	NA	+(Ct 37)
oropharyngeal swab	+(Ct 19)	+(Ct 35)	+(Ct 23)	+(Ct 38)	+(Ct 21)	+(Ct 31)	NA	-	+(Ct 21)	+(Ct 34)
Serum	ND	-	ND	NA	ND	-	ND	-	ND	NA
Urine	ND	ND	ND	ND	ND	ND	ND	ND	ND	ND
Stool	ND	NA	ND	ND	ND	ND	ND	-	ND	ND

Ct values for rRT-PCR presented in parentheses. Lower Ct values indicate higher viral loads.Ct=cycle threshold. +=positive. –=negative. ND=not detected. NA=not available.

Journal Pre-proof