Celebrating 35 Years 1979-2014

Pediatrics in Review

An Official Journal of the American Academy of Pediatrics

Scabies: A Review of Diagnosis and Management Based on Mite Biology

Alexandra K. Golant and Jacob O. Levitt

Pediatrics in Review 2012;33;e1
DOI: 10.1542/pir.33-1-e1

The online version of this article, along with updated information and services, is located on the World Wide Web at:
http://pedsinreview.aappublications.org/content/33/1/e1

Pediatrics in Review is the official journal of the American Academy of Pediatrics. A monthly publication, it has been published continuously since 1979. Pediatrics in Review is owned, published, and trademarked by the American Academy of Pediatrics, 141 Northwest Point Boulevard, Elk Grove Village, Illinois, 60007. Copyright © 2012 by the American Academy of Pediatrics. All rights reserved. Print ISSN: 0191-9601.

American Academy of Pediatrics
DEDICATED TO THE HEALTH OF ALL CHILDREN™

Downloaded from http://pedsinreview.aappublications.org/ at Eccles Health Sciences Lib on October 16, 2014

Scabies: A Review of Diagnosis and Management Based on Mite Biology

Alexandra K. Golant, MD*
Jacob O. Levitt, MD*

Author Disclosure
At the time he wrote this article, Dr Levitt was the Vice-President of Taro Pharmaceuticals, USA, Inc, which manufactures a malathion product, and a stockholder. Dr Golant has no financial interests relevant to this article. The article does include discussion of unapproved therapeutic agents.

Objectives

After completing this article, readers should be able to:

1. Understand the biology and life cycle of the mite *Sarcoptes scabiei* var *hominis*.
2. Know how to diagnose a scabies infestation.
3. Recognize the three basic clinical presentations of scabies: classic, crusted and nodular.
4. Understand how scabies is transmitted and the risk of infestation to contacts.
5. Know the principles of managing scabies, including pharmacologic treatment and the prevention of recurrence.

Introduction

Scabies is a parasitosis caused by the mite *Sarcoptes scabiei* var *hominis*, with crusted scabies being more contagious than classic scabies because of a larger mite burden. Scabies is found primarily in poor and overcrowded conditions but can affect individuals of all ages and socioeconomic status without regard to level of hygiene. The predominant disease manifestations are mediated through inflammatory and hypersensitivity reactions to mites and mite products. (1) Hallmarks of infestation include intense itching, papular rash, and emotional disturbance from the concept of arthropod infestation. Complications of bacterial infection are a cause of significant morbidity in developed but especially in less developed countries. Effective scabies control requires treatment of affected patients, their close contacts, and environmental fomites. Control is difficult to achieve because of delayed or missed diagnosis, improper application of medication, inadequate treatment, or poor compliance. Treatment with most scabicidal medications calls for treating with an initial dose and re-treating 7 days later; however, the biological basis for when optimally to re-treat has never been documented.

Mite Biology and Life Cycle

The scabies mite is an obligate parasite that burrows in the epidermis of human skin, on average within 30 minutes after first contact. (2)(3)(4)(5) The adult mite burrows at 0.5 to 5.0 mm per day into the stratum corneum and deposits feces in its path; female mites also lay eggs. (6) Eggs hatch into larvae within 2 to 3 days, which then leave the burrow to mature on the skin surface. In 10 to 11 days, females mature into egg-laying adults. (7) The total life span of the adult female is approximately 5 weeks. Adult mites have eight legs, making them easily distinguishable from less mature larval forms, which have six legs. (3)(8) During maturation on the skin surface, larval mite forms are capable of burrowing into the patient's epidermis or moving to a different host. Mites can crawl as fast as 2.5 cm per minute on warm skin. (8)

Scabies mites can survive off the human host and remain capable of infestation for an average of 24 to 36 hours at room conditions (21°C and 40%–80% relative humidity) and up to 19 days in a cool, humid environment. (2) A mite's ability to infect a host decreases with increased time off of the host. (2) Adult mites use odor and thermotaxis to identify a new host. (9)

Abbreviations

BIT: burrow ink test
Ig: immunoglobulin
KOH: potassium hydroxide

Diagnosis

Accurate diagnosis of scabies infestation is an imperfect science. Given the extensive differential, correct clinical diagnosis rates among inexperienced clinicians is low. Furthermore, it

*Department of Dermatology, The Mount Sinai Medical Center, New York, NY.

Downloaded from http://pedsinreview.aappublications.org/ at Eccles Health Sciences Lib on October 16, 2014

often is difficult to distinguish among active infestation, residual skin reaction, and reinfestation. In practice, diagnosis often is made (or excluded) empirically from correlation of clinical symptoms with suggestive skin lesions or history of contact with a known scabies case; however, using such correlation will both overdiagnose and underdiagnose actual cases.

Scabies can be diagnosed by a variety of methods: potassium hydroxide (KOH) scraping of a burrow, dermoscopy, magnification of digital photography, skin biopsy, and clinical presentation, which typically includes itchy red papules and contacts with a similar rash. The gold standard involves direct visualization of the mite or its eggs. Direct visualization can be achieved by KOH preparation of a skin scraping taken from a burrow (Fig 1 A and B) or biopsy of a burrow demonstrating a mite (Fig 2). KOH testing provides excellent specificity (few false-positives) but low sensitivity (many false-negatives) because of the small number of parasites found in a typical host who has classic scabies. (1) Because scybala in isolation on a slide (Fig 3) can look like debris of nonscabies origin, the presence of scybala alone should not be considered diagnostic. Biopsy showing only perivascular inflammatory cell infiltrates with numerous eosinophils, edema, and epidermal spongiosis is merely suggestive and not definitive. (10) A recent article asserts that the visualization of only "pink pigtail" structures connected to the stratum

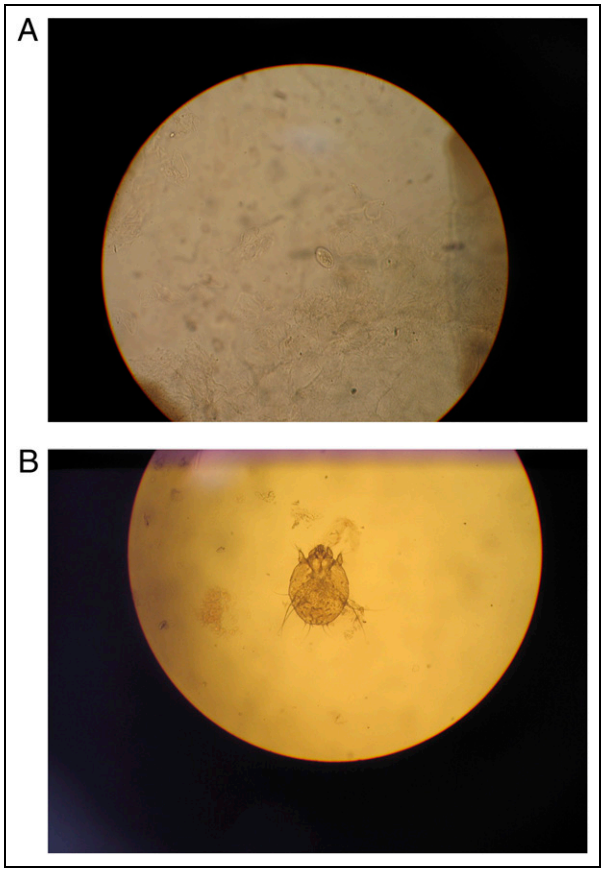

Figure 1. KOH-prepared skin scrapings. A. Mite egg. B. Scraping taken from burrow demonstrating intact whole mite.

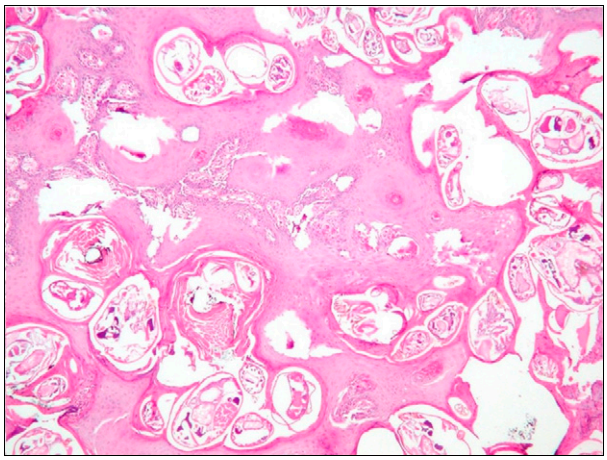

Figure 2. Biopsy of crusted scabies. Note the large mite burden, perivascular inflammatory infiltrate, and epidermal spongiosis (hematoxylin–eosin stain; original magnification ×10).

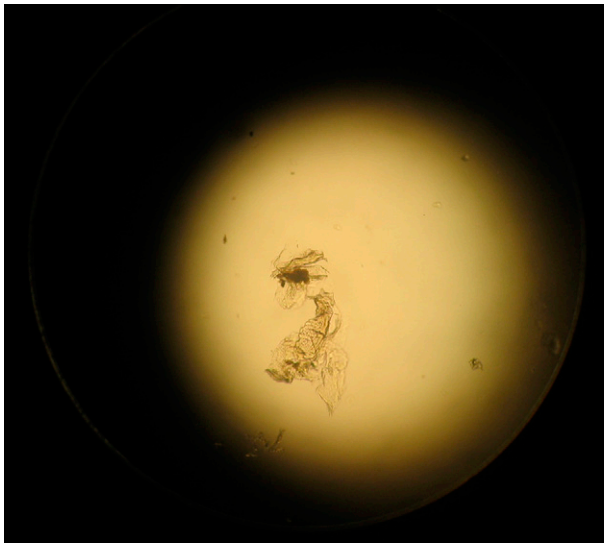

Figure 3. Scybala (fecal pellets) in isolation on a slide. Because of the resemblance to nonscabetic debris, microscopic visualization of scybala alone should not be considered diagnostic of scabies.

Downloaded from http://pedsinreview.aappublications.org/ at Eccles Health Sciences Lib on October 16, 2014

corneum (Fig 4), representing empty mite egg casings, suggests scabies. (11) Dermoscopy (12) and magnification of high-resolution digital photography (13) (Fig 5) are also good diagnostic methods, albeit less definitive than visualizing a mite on KOH preparation or biopsy. Dupuy et al (12) reported 91% sensitivity and 86% specificity for dermoscopy by experienced users, with slightly lower specificity for inexperienced users. Selecting an appropriate lesion for diagnostic testing is especially important because excoriated or inflamed lesions are less likely to harbor the mite or mite products. (14) Acral areas, such as the wrists and finger webs, are the best sites to sample; however, any skin that contains a red papule with central burrow should yield a mite.

Alternative methods of diagnosis include the burrow ink test (BIT), in which suspicious papules are marked with ink and then wiped off with an alcohol pad to remove the surface ink from the lesion. A positive BIT result (Fig 6) occurs when the ink tracks down the mite burrow, forming a characteristic dark, zigzagged line that is readily apparent to the naked eye. This test is useful if one does not have digital camera, microscope, dermatoscope, or skin biopsy capabilities. Epiluminescence microscopy ("jet-with-contrail" pattern) (15) and high-resolution videodermatoscopy are newer, noninvasive techniques that allow inspection of the skin in vivo from the surface to the superficial papillary dermis. (1) Studies of more advanced tests, such as polymerase chain reaction antigen detection, intradermal skin test, and enzyme-linked immunosorbent assay antibody detection are in progress. (1)

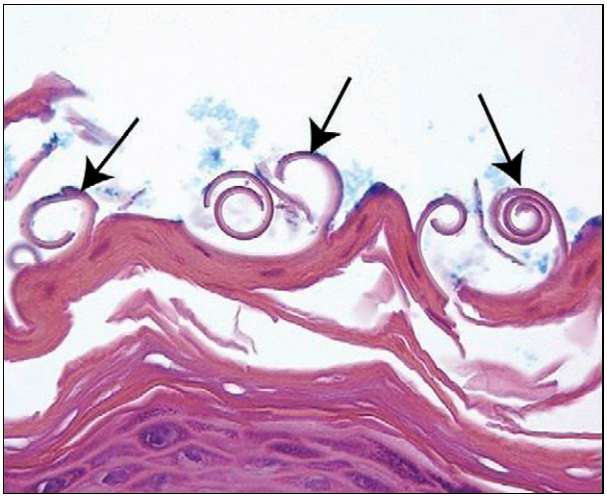

Figure 4. Pink pigtails connected to stratum corneum, representing empty mite egg casings (hematoxylin-eosin stain; original magnification ×40). Reprinted with permission from Kristjansson AK, Smith MK, Gould JW, Gilliam AC. Pink pigtails are a clue for the diagnosis of scabies. *J Am Acad Dermatol*. 2007;57(1):174.

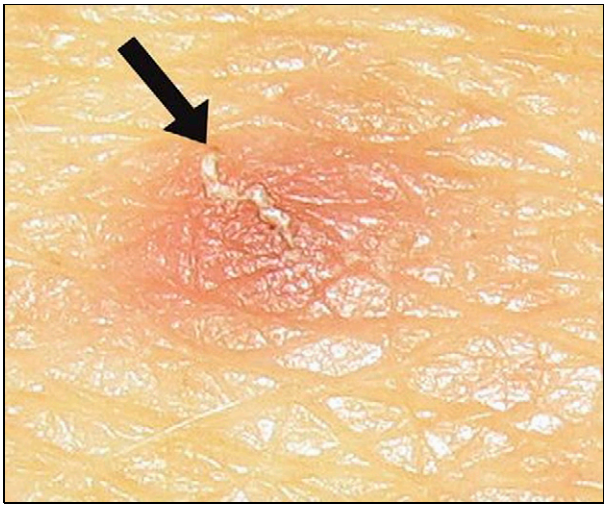

Figure 5. Scabies burrow via high-resolution digital photography (4 megapixel) showing mite at end of burrow (original magnification ×150). Reprinted with permission from Levitt JO. Digital photography in the diagnosis of scabies. *J Am Acad Dermatol*. 2008;59(3):530.

Figure 6. Burrow demonstrating a positive BIT result. The BIT is useful when other diagnostic methods are unavailable.

Clinical Presentation

Scabies has three basic clinical presentations: classic, crusted, and nodular. Classic scabies, the most common form, produces symptoms of severe pruritus (worse in the evening), fatigue, irritability, and, in some patients, fever from secondary impetigo or cellulitis. The parasite burden in classic

Downloaded from http://pedsinreview.aappublications.org/ at Eccles Health Sciences Lib on October 16, 2014

Figure 7. High magnification of burrows on an abdomen. The burrow is a seripigenous grey line in the skin formed by the digestive properties of the advancing mite's secretions and is pathognomonic of scabies infestation.

scabies usually is low, with an average of 10 to 12 mites during the first 3 months of infestation. (3)(16) The classic sign of scabies is the burrow (Fig 7), a serpigenous grey line in the skin formed by the digestive properties of secretions from the advancing mite. (4)(17) In classic scabies, skin lesions have a predilection for the interdigital web spaces of hands, flexor surfaces of wrists, extensor surfaces of elbows, periumbilical skin, axillae, genitalia, and the periareolar region in females (Fig 8 A–D). Contrary to popular belief, burrows may not be present in tropical climates, nor are they requisite in children. (2)(4)(8)(9) Although a single burrow is highly sensitive diagnostically, burrows often are obliterated by bathing, scratching, crust formation, or superinfection. (6) In the authors' experience, a burrow is observed in most scabies cases diagnosed in nontropical climates. Hypersensitivity of both immediate and delayed types has been implicated in the development of lesions other than burrows. (18) Note, however, that the degree of rash does not correlate with the number of mites present.

Crusted scabies occurs in immunocompromised patients, such as those on long-term immunosuppressive therapy (ie, organ transplant recipients) or those with HIV or human T-lymphotropic virus type 1 infection. Other susceptible groups are mentally or physically handicapped patients, such as those who have paralyzed limbs, sensory neuropathy, or leprosy, because they may be unable to feel the itch or to scratch. (19) An older and now disfavored term for crusted scabies is "Norwegian scabies," a reference to affected Norwegian patients with leprosy. (20) Progression from classic scabies is uncommon. (1) Crusted scabies is a psoriasiform dermatitis, frequently associated with hyperkeratotic skin crusts, peripheral eosinophilia, and high immunoglobulin (Ig) E and IgG levels. Crusted scabies can present in a generalized or focal manner, with manifestations limited to the scalp, face, nails, or soles. (1) Interestingly, about 50% of patients who develop crusted scabies report only mild pruritus or none at all. (21) Fissure development and secondary bacterial infections are common and are partially responsible for the high mortality associated with this form of the disease.

Although crusted scabies is caused by the same mite that causes classic scabies, the mite density in crusted scabies is much greater and can range from thousands to millions per patient, compared with the dozen or so mites typically found in classic scabies. (18) This difference accounts for crusted scabies being considerably more infectious than classic scabies. One study found that up to 4,700 mites per g of skin were counted in skin shed from hyperkeratotic patients, suggesting that crusted scabies predisposes contacts of the patient to infection through infested fomites in addition to direct contact. (22) Patients afflicted with crusted scabies also pose a treatment dilemma because eradicating the mite and egg burden from heavily crusted areas of the skin is difficult.

Nodular scabies is an uncommon variant (18) characterized by extremely pruritic reddish brown nodules up to 2 cm in size that typically are found on the genitalia, buttocks, groin, and axillae. Nodules are considered to be the result of hypersensitivity reactions to mite products because mites almost never are identified in these lesions. Nodular scabies can create a treatment dilemma because nodules can persist for weeks after treatment and may require corticosteroid injections. (21) Often, patients will demand repeat therapy with scabicides, and overly aggressive repeat therapy must be tempered with reassurance that the nodules eventually will resolve with appropriate anti-inflammatory therapy.

Transmission and Affected Contacts

It can take 4 to 6 weeks after initial mite exposure to develop signs or symptoms of scabies infestation. This delay in symptom development ("clinically latent period") is responsible for undetected transmission and is thought to be due to delayed type IV hypersensitivity reaction against mites and mite products. (21) Evidence for this cell-mediated immune response has been confirmed by histologic examination of scabies lesions, which often show inflammatory cell infiltrates composed of eosinophils, lymphocytes, and histiocytes. (1) If patients are

Downloaded from http://pedsinreview.aappublications.org/ at Eccles Health Sciences Lib on October 16, 2014

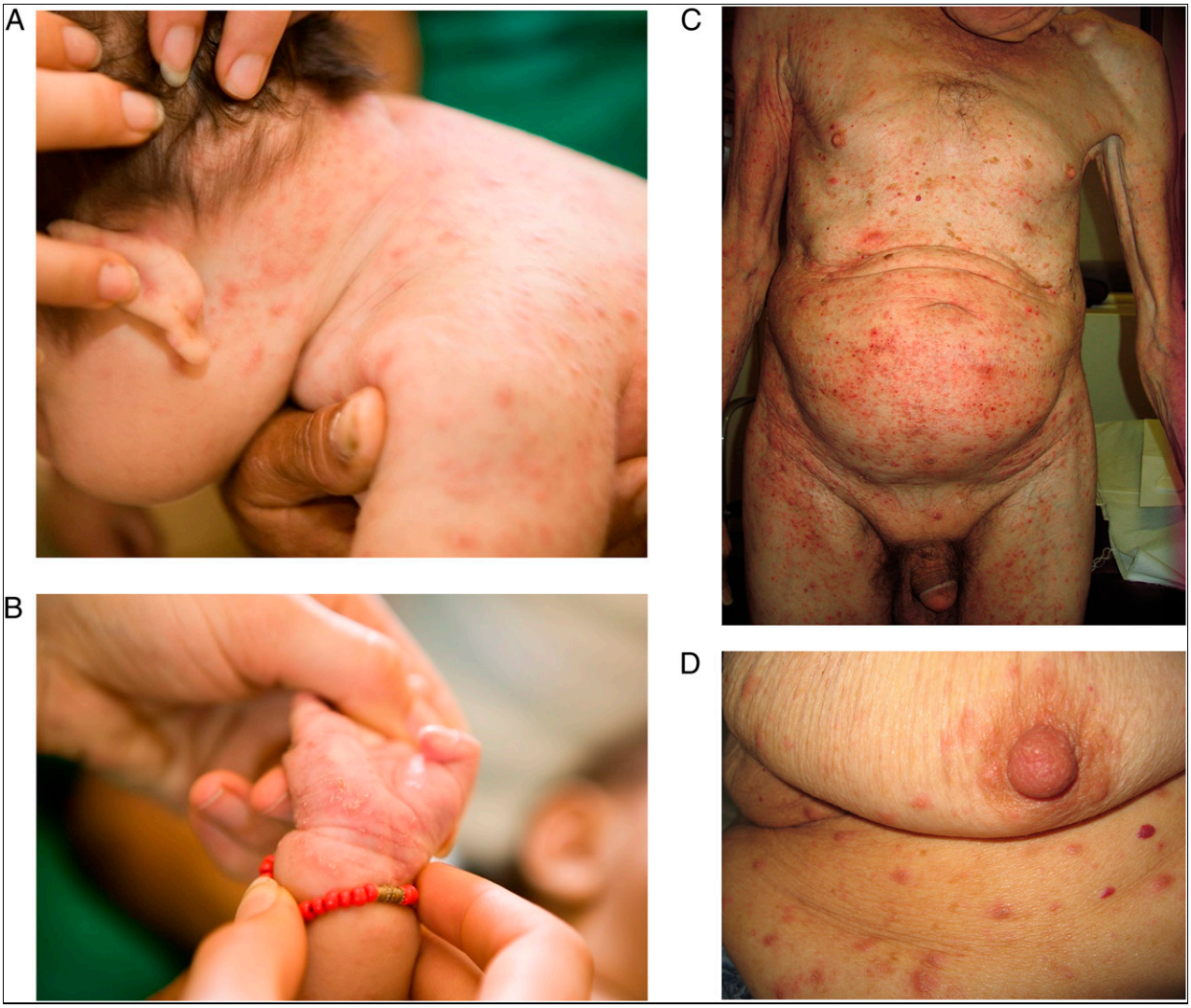

Figure 8. Typical scabies lesions: A. Lesions on a child. Note lesions on the scalp and neck, areas usually spared in adult infestation. B. Close-up of lesions on a child. Note predilection for the wrist and palms, characteristic of pediatric infestation. C. Extensive total body skin lesions on an adult. D. Close-up of lesions on an adult female. Note concentration in periareolar regions, characteristic of adult infestation.

reinfested, symptoms can reappear within days. Scabies also evokes a humoral immune response, demonstrated by high peripheral IgG and IgE levels and dermal IgE deposits found on biopsy of affected patients. (23)(24) The potential for diagnostic delay following initial infestation poses challenges for treating and eradicating scabies in both the source patient and any close contacts.

Scabies theoretically can be contracted by the transfer of eggs, larvae, or mature mites to the skin of the new host (25); however, mature mites are the most likely culprits. Early studies by Mellanby (3)(26) demonstrated that direct body contact was the predominant route for scabies transmission, and the number of scabies mites is directly proportional to risk of transmission. Mellanby found that of 300 volunteers who lay nude in warm beds recently vacated by scabetic hosts infected with <20 mites, 4 (1.3%) became infested. The number rose to 15% when hosts had >50 mites (3 of 20 volunteers became infested).

Scabies mites dislodged from an infested individual use odor and thermotaxis to identify a new host. (9) For these stimuli to be sufficient, individuals must be in close skin-to-skin contact, as occurs during sexual intercourse or when children sleep in the same bed. Bedding,

Downloaded from http://pedsinreview.aappublications.org/ at Eccles Health Sciences Lib on October 16, 2014

clothing, furniture, and other environmental sources can act as fomites, especially in crusted scabies, in which a high parasite load resides in shed scales. Transmission among family members is most common, supported by evidence from molecular studies that show the genotype of mites from household members is more homogeneous than the genotypes of mites from separate households within a community. (22)

Differential Diagnosis

Almost all pruritic dermatoses must be considered in the differential diagnosis (Table 1) because scabies can closely mimic a wide range of other skin conditions. The likelihood of a certain diagnosis varies according to the age of the patient and the setting. Various infections, arthropod assault, bullous dermatoses, and cutaneous lymphoproliferative disorders can all mimic scabies. Of note, scabies can present like bullous pemphigoid, having bullae associated with eosinophils and a positive direct immunofluorescence. (34)

Scabies in children often is missed until close contacts present with similar symptoms. Typical and atypical scabies skin lesions are found more often in areas of the body that are historically spared in adults, including the scalp, face, palms, soles, and intertriginous areas (Fig 8 A and B). (3)(9) In this population, scabies can be easily confused with atopic dermatitis or infantile acropustulosis, a condition characterized by transient episodes of acrally distributed pruritic vesicles and pustules. Indeed, a true infantile acropustulosis may follow treated scabies. Several case reports document misdiagnosis of scabies as Langerhans cell histiocytosis. (30)(31)(32)(33) Furthermore, especially in poor countries, children are more likely to present with scabies complicated by bacterial superinfection. (21)

The elderly are another challenging population with respect to the presentation of scabies. In this age group, cutaneous manifestations of classic scabies can be atypical, which may reflect an altered host immune response to the mite. Diagnostic delay in this population is common and of particular concern because itching is often dismissed as "senile pruritus" or anxiety. (18) In institutional settings, diagnostic delay allows for spread to others in the facility. The potential for misdiagnosis in pediatric or elderly patients can lead to inappropriate long-term application of potent topical corticosteroids, which predisposes these already vulnerable populations to more severe forms of the disease, including crusted scabies. Long-term corticosteroid use can also affect the presentation of routine scabies, with vesicles, pustules, and nodules predominating over classic skin lesions. (37)

Complications

Scabies-associated morbidity is frequently underestimated when considering the impact of the disease. In addition to the discomfort and loss of sleep caused by intense pruritus, patients can become secondarily infected from bacterial entry into excoriated skin. Bacterial transmission can also occur directly from the mite itself because *Staphylococcus aureus* and nephritogenic strains of group A *Streptococcus* have been isolated from mites and fecal pellets. (4) Scabies infection can lead to impetigo, furuncles, or cellulitis that can progress to acute poststreptococcal glomerulonephritis and rheumatic heart disease. (14) Such complications are of greatest concern in tropical regions and are seen less often in dry climates. (1)(4)(38) When bacterial superinfection is suspected, concomitant treatment with topical or systemic antibacterial agents should be started as soon as possible.

Other scabies complications includes postscabies pruritus, a well-described pruritic condition that can last for days to weeks after the primary infestation and is thought to result from hypersensitivity to mites and mite products. (14) Practitioners should avoid confusing this complication with a treatment failure to avoid overprescribing scabicidal medication. Postscabies pruritus can be controlled with oral antihistamines or corticosteroids, and a trial of phototherapy may be warranted in resistant cases.

Table 1. Differential Diagnosis of Scabies (27)(28)(29)(30)(31)(32)(33)(34)(35)(36)

Impetigo	Papular urticaria	Bullous pemphigoid
Folliculitis/furunculosis	Allergic reaction/drug rash	Lymphomatoid papulosis
Tinea corporis	Psoriasis	Dermatitis herpetiformis
Syphilis	Eczema	Langerhans cell histiocytosis (especially in children)
Insect bites (eg, bed bugs, fleas, chiggers)	Seborrheic dermatitis	Sezary syndrome (cutaneous T-cell lymphoma)
Animal scabies	Systemic lupus erythematosus	Infantile acropustulosis

Downloaded from http://pedsinreview.aappublications.org/ at Eccles Health Sciences Lib on October 16, 2014

Finally, the mere concept of insect infestation can cause serious psychological and emotional distress for some patients, including feelings of shame, guilt, and persistent delusions of parasitosis. (14) The best way to prevent these types of complications is to educate patients about the disease to alleviate fears and help improve compliance with treatment to ensure an expeditious cure.

Principles of Treatment

The choice of scabies treatment is based on effectiveness, potential toxicity, type of disease, and the patient's age. In general, there is a lack of randomized controlled trials comparing the efficacy of topical scabies treatments; however, excellent clinical success rates with permethrin 5% cream, malathion 0.5% lotion, and oral ivermectin at 200 μg/kg make them all good treatment options. Generally recommended principles of treatment include treating the source patient concomitantly with any close contacts and sanitizing fomites and domicile.

When treating an individual, topical agents should be applied to the entire body surface with particular attention to the face (including eyelids), groin, back, under the nails, and in and behind the external ears. If hands are washed before the typically recommended 8-hour application time, the topical agent should be reapplied to the hands. Classic dogma, mainly originating from the package insert of topical scabicidal medications, does not provide explicit guidelines for treatment of the face or scalp. (39)(40) There is no physiologic basis for not treating these areas, and even cases of classic, noncrusted scabies in adults have been reported to affect the forehead. (41) That said, many cases of scabies are treated successfully without treating the scalp. In children, the elderly, and in tropical climates, the face and scalp should be treated routinely. (9)

The authors' personal practice in New York involves empiric scalp treatment in a heavier infestation or if there is failure with initial therapy that did not include scalp treatment. Fingernails should be cut and subungual debris should be cleaned. Of course, if there is coexisting superinfection, topical or systemic antibiotics should be started as soon as possible and should be continued in conjunction with the scabies treatment. It is important to remember that pruritus can persist for up to 4 weeks after successful treatment as a result of hypersensitivity reactions and can be treated with antihistamines and anti-inflammatory agents, such as medium-potency topical corticosteroids.

In the case of crusted scabies, crusts can harbor thousands of mites. Keratolytics should be added to the treatment regimen until the hyperkeratosis has resolved. Typically, cases of crusted scabies require more cycles of re-treatment than classic scabies. Although judgments about therapy are dependent on clinical assessment of mite and scale burden, in our experience, three and rarely four rounds of topical or oral therapy are necessary to treat crusted scabies.

When treating fomites and the home environment, all clothing, bedding, and towels can be decontaminated by drying them at 60°C for 10 minutes; washing is not necessary. (8) Indeed, if a typical dryer cycle lasts 20 minutes, two loads of laundry can be treated with one dryer cycle (providing some monetary savings). Arlian et al (42) took dust samples from homes of scabetic hosts, 81% of whom had moderate to heavy infestation but no hyperkeratosis (scaling and/or crusting), and found that 44% of samples contained live mites. Live mites were recovered mostly from bedroom floors, couches, chairs, and mattresses. Vacuuming the floors of the bedroom and bathroom, as well as heavily used couches and chairs, is prudent in all cases and integral in cases of crusted scabies. Mites can survive off of the host for up to 19 days in cool, humid environments, but most die after 36 hours at room temperature. (2) Thus, the alternative is not to use contaminated fomites for a minimum of 2 days (or up to 3 weeks for those who wish to take every possible precaution). We feel 3 weeks is too extreme for classic scabies but might be appropriate for crusted scabies, for example, in the event of treatment failure.

Clinical Contexts

When devising a treatment plan for close contacts, one must take into account the context of the infestation—inpatient versus outpatient. For an individual case of classic scabies in the outpatient setting, treatment is targeted toward the source patient and any close contacts, whether or not contacts exhibit symptoms (in light of the clinically latent period that can last up to 6 weeks). Because the commonly used topical scabicides are essentially innocuous, it is not necessary to examine close contacts before prescribing topical therapy. We believe that it is more beneficial to ensure simultaneous treatment of contacts than to delay therapy for examination and counseling.

For an individual case of crusted scabies, the host patient should be treated with a regimen adequate to eradicate crusted scabies (ie, sufficient repeat cycles of therapy ensuring elimination of scale), and practitioners should use increased vigilance in warning any contacts about potential exposure owing to the increased infectivity of crusted scabies. Special attention should be paid to at-risk populations, including children, immunosuppressed patients, and the neurologically impaired. Of course, fomite

Downloaded from http://pedsinreview.aappublications.org/ at Eccles Health Sciences Lib on October 16, 2014

decontamination is of increased importance in crusted scabies.

When a patient with classic scabies is identified in an institutional setting, the affected patient must be put on contact isolation and all close contacts must be informed, educated about delayed onset of symptoms, and offered treatment. Close contacts may be defined as those who have extended, nongloved physical contact, including visitors, doctors, phlebotomy and radiology technicians, nurses, and other patients residing in the same room. When multiple cases are identified in one institution contemporaneously, there often is a source patient who has crusted scabies.

When a source patient with crusted scabies is identified in an institution, the previously mentioned precautions should be taken, in addition to informing and screening other staff, such as phlebotomists and nursing assistants, and patients on the same floor, even if there is no evidence of direct contact with the source patient. One should inform, screen, and empirically treat the laundry staff because of possible exposure to mites from shed skin during laundering of bedding and other fomite sources. More comprehensive fomite decontamination, including all chairs, curtains, furniture, and floors in patient rooms and waiting areas, is appropriate. For patients leaving the facility within 6 weeks after the outbreak, it may be easiest to treat empirically at discharge; otherwise, a note to the receiving facility should be provided.

For community outbreaks, the goal of treatment is to decrease the burden of disease dramatically rather than eliminate the outbreak altogether. This goal is accomplished through community education, treatment of all community inhabitants, decontamination of fomites, and monthly screening of patients and contacts. In small communities, particularly isolated island or rural populations, infestation rates of 33% have fallen to <1% by such methods in one study, and from 29% to <10% in another study after community-wide permethrin treatment. (43)(44) Reintroduction of scabies into treated communities will always be present, but with screening programs in place, epidemics can be avoided.

Rational Recommendations for Treatment and Re-treatment

Package inserts of topical scabicidal medications advise treating patients with a single application, noting that one treatment typically is curative. (39)(40) Lindane prescribing information instructs to treat from the neck down because of safety considerations, (40) and permethrin prescribing information states that scalp treatment for adults is not necessary because infestation is uncommon in this population, but recommends re-treatment at day 14 if mites are again detected. (39)

To make a rational basis for therapy, akin to that done for head lice, (45) we need to know if a given therapy has ovicidal as well as scabicidal activity. Because there is a lack of information on this point, we must assume the worst case scenario: that therapies are not ovicidal. We must also understand the scabies life cycle, which has been elegantly elucidated by Arlian et al. (42) As stated earlier, an egg hatches after a maximum of 3 days and takes a minimum of 8 days to mature to an egg-laying adult. Treatment at day 0 would kill all the mites. Hatchlings from eggs laid just before therapy would become infectious on day 3. Thus, re-treating at day 3 or 4 (allowing for outlier late hatchlings) appears a more rational approach. In this case, hatchlings, as well as any adult survivors from the initial therapy, are exposed to therapy.

Although controlled clinical studies in monitored settings may yield high cure rates, in practice, treatment failures from a single application are common. For this reason, we recommend empiric re-treatment at day 4 for confirmed cases. Naturally, if one assumes that a drug is both scabicidal and ovicidal, a high success rate should be achieved with one application. Provided all contacts were treated in the 4-day window, there does not seem to be a benefit in waiting beyond 4 days to re-treat the infected patient, for the following reasons: (1) contacts are not often treated exactly at the same time; (2) fomites are not decontaminated consistently; and (3) a single application is not always effective (owing to application error or poor compliance). A delay in re-treatment allows time for establishment of greater disease burden and greater potential for spread to others if there is any failure of the first treatment.

Although we posit that re-treatment on day 4 will lead to better clinical outcomes, these recommendations are not substantiated by clinical data and thus need to be validated through randomized controlled clinical trials with each agent.

Pharmacotherapy of Scabies

Permethrin

Permethrin 5% cream is accepted as the current gold standard for scabies treatment because of an efficacy of ~90% in most studies from the past two decades (4)(43)(44)(46)(47)(48)(49)(50)(51)(52)(53)(54)(55) and an excellent safety profile. Permethrin is labeled for application to the entire body for 8 to 12 hours, usually right before bedtime. According to a 2007 Cochrane review, permethrin is the most effective topical scabicide, significantly more efficacious than crotamiton and lindane.

Downloaded from http://pedsinreview.aappublications.org/ at Eccles Health Sciences Lib on October 16, 2014

(56) In addition to its superior efficacy, permethrin also has an excellent safety profile. Compared with lindane, permethrin is less toxic, has lower percutaneous absorption, and produces lower blood and brain concentrations when applied topically. Permethrin is indicated and is safe for use in newborns, young children, and pregnant (category B) and lactating women. (14) Although there are no reports of confirmed in vivo resistance to permethrin in scabies mites, in vitro resistance of scabies mites to permethrin has been well demonstrated, (5)(57)(58) and concerns about in vivo mite resistance have recently been described in a number of Aboriginal communities in northern Australia. (5)(57)(58)(59)(60)

Malathion

Malathion 0.5% lotion is approved for the treatment of head lice in the United States but is not currently indicated for the treatment of scabies. In the United Kingdom, malathion is approved for scabies and is available over the counter. Malathion requires two applications 7 days apart. (61) A few small studies have demonstrated malathion's efficacy in scabies, with cure rates ranging from 83% to 100%. (62)(63)(64)(65) The safety profile of malathion, which is excellent, is reviewed by Idriss and Levitt. (41)

Because malathion is available as a runny lotion, it may be more appropriate than scabicidal creams for treatment of hairy areas of the body, such as the scalp. (41) Adverse effects of malathion include occasional skin irritation and conjunctivitis with eye contact.

Ivermectin

Ivermectin is used off label as an oral medication for scabies, alone or in combination with a topical agent. Most large studies to date have shown that one or two doses of ivermectin (200 μg/kg, 3–9 days apart) produced cure rates equivalent to treatment with conventional topical medications (benzyl benzoate, lindane, permethrin) for classic scabies. (21) Efficacy rates from several open-label studies of ivermectin (one to two doses) for the treatment of classic scabies since 1996 have ranged from 76% to 100%. (66)(67)(68)(69)(70)

A single dose of ivermectin yielded a 70% cure rate, which increased to 95% with a second dose at 2 weeks. (55) The temporal and additive nature of this clinical response suggests that ivermectin may lack ovicidal properties and thus may not be effective during all stages of the mite life cycle. (21) Based on our knowledge of the scabies mite life cycle and ivermectin's short half-life (18 hours), treating patients with two doses of ivermectin 4 days apart seems to be a more rational regimen. (71)

Based on its route of administration, ivermectin holds the greatest potential for treating scabies in the context of epidemic or endemic outbreaks. Topical scabicides have the potential to be applied inappropriately and are generally poorly tolerated by bedridden patients because they can be challenging for staff to apply. (14) Therapy with a tablet is relatively quick and efficient and virtually guarantees whole-body exposure. For that reason, ivermectin has also been efficacious for the treatment of severe crusted scabies in adults and older children, usually when given in multiple doses and in combination with topical permethrin. (21)

Potential adverse effects of ivermectin include hepatotoxicity, tachycardia, and hypotension. (71) Owing to limited safety data and a less developed blood-brain barrier, ivermectin is not recommended for use in children younger than 5 years of age or in pregnant or lactating women. (72) Of note, ivermectin is a P-glycoprotein inhibitor, which can lead to serious toxicity if used in conjunction with other P-glycoprotein substrates, such as methotrexate, cyclosporin, digoxin, and some anticancer treatments. (73)(74)

These treatments comprise most of scabies therapy in the United States and are those that the authors feel are most effective. The following medications can also be used.

Crotamiton

Crotamiton 10% cream is labeled for topical application from the chin down, with repeat application suggested at 24 hours. Although crotamiton is labeled for application over 1 to 2 days, daily application for 5 days has produced better cure rates. (4)(9)(50)(58) Safety for the use of crotamiton in newborns and infants has not been well established. Results from a double-blind randomized study proved that crotamiton cream is significantly less efficacious than permethrin. (50) Potential adverse effects from crotamiton cream include erythema and conjunctivitis. In addition, high resistance rates have been reported after a single application of 8 to 12 hours. (50)(75)

Lindane

Cure rates from four early studies ranged from 49% to 96% when measured at 4 weeks after a single topical application of lindane. (76) Treatment failures are attributed largely to resistance. Lindane's use is greatly limited by safety concerns regarding its potential neurotoxicity. The spectrum of serious neurologic adverse effects includes irritability, vertigo, seizures, vomiting, diarrhea, and syncope. (21) Lindane currently carries a black box warning in the United States because of reported deaths from its use, and the drug is banned in ~50 countries, mainly

Downloaded from http://pedsinreview.aappublications.org/ at Eccles Health Sciences Lib on October 16, 2014

because of its persistence in the environment. One bottle of lindane contaminates 6 million gallons of water, costing $4000 of wastewater clean-up per treatment. (77)

Benzyl Benzoate

Benzyl benzoate is a scabicide used alone or in combination with topical sulfiram. It is labeled for use in adults and in diluted form for children, infants, and breastfeeding mothers. (21) Different treatment regimens have been proposed (including single versus multiple applications), but no comparative data are available. Benzyl benzoate is not approved for use in the United States. Although cure rates in one study were lower for benzyl benzoate when compared with oral ivermectin, (78) in vitro testing has shown benzyl benzoate kills scabies mites more rapidly than permethrin and may be a useful alternative to permethrin in severe crusted scabies. (24)(57)(79) Benzyl benzoate should be washed off within 24 hours after application because it is a known irritant that can cause contact dermatitis. (18) Analgesics and antihistamines can be used as pretreatment to diminish the application discomfort, if necessary. If ingested, benzyl benzoate can cause difficulty urinating, jerking movements, and loss of consciousness. (4)(58)(78)(80) When used in combination with sulfiram, treatment with benzyl benzoate can mimic the effect of disulfiram; thus, it is advised to avoid alcohol ingestion for at least 48 hours after treatment. (18)

Summary

- Scabies is a contagious parasitic dermatitis that is a significant cause of morbidity, especially outside of the United States. Scabies is diagnosed most often by correlating clinical suspicion with the identification of a burrow.
- Although scabies should be on the differential for any patient who presents with a pruritic dermatosis, clinicians must consider a wide range of diagnostic possibilities. This approach will help make scabies simultaneously less over- and underdiagnosed by clinicians in the community.
- Atypical or otherwise complex presentations may necessitate the use of more definitive diagnostic modalities, such as microscopic examination of KOH-prepared skin scrapings, high-resolution digital photography, dermoscopy, or biopsy.
- Scabies therapy involves making the correct diagnosis, recognizing the correct clinical context to guide treatment of contacts and fomites, choosing the most effective medication, understanding how to use the agent properly, and following a rational basis for when to use and reuse that agent.
- Although the development of new therapeutic agents is always welcome, tried and true treatments are still effective today. Permethrin is the gold standard therapy, with malathion being an excellent topical alternative. Ivermectin is an effective oral alternative that is especially useful in crusted scabies, patients who are bedridden, and in institutional outbreaks.
- Despite the availability of effective therapeutics, treatment failures still occur, mostly secondary to application error (ie, failure to treat the face and scalp or close contacts, failure to reapply medication) or failure to decontaminate fomites.
- Because increasing resistance to scabies treatments may be on the horizon, we propose that standard of care for scabies treatment should involve routine treatment of the scalp and face and re-treating patients at day 4 on the basis of the scabies life cycle to ensure more efficient mite eradication.
- Practitioners should attempt to treat all close contacts simultaneously with the source patient.
- To eradicate mites, all fomites should be placed in a dryer for 10 minutes on a high setting, furniture and carpets vacuumed, and nonlaunderables isolated for a minimum of 2 days, or, for those who wish to be rigorous, 3 weeks.

References

1. Walton SF, Currie BJ. Problems in diagnosing scabies, a global disease in human and animal populations. *Clin Microbiol Rev.* 2007;20(2):268–279
2. Arlian LG, Runyan RA, Achar S, Estes SA. Survival and infectivity of *Sarcoptes scabiei* var. *canis* and var. *hominis. J Am Acad Dermatol.* 1984;11(2 pt 1):210–215
3. Mellanby K. Biology of the parasite. In: Orkin M, Maibach HI, eds. *Cutaneous Infestations and Insect Bites.* New York, NY: Marcel Dekker; 1985:9–18
4. Burgess I. Sarcoptes scabiei and scabies. *Adv Parasitol.* 1994;33: 235–292
5. Walton SF, Holt DC, Currie BJ, Kemp DJ. Scabies: new future for a neglected disease. *Adv Parasitol.* 2004;57:309–376
6. Heukelbach J, Feldmeier H. Scabies. *Lancet.* 2006;367(9524): 1767–1774
7. Arlian LG, Vyszenski-Moher DL. Life cycle of *Sarcoptes scabiei* var. *canis. J Parasitol.* 1988;74(3):427–430
8. Arlian LG. Biology, host relations, and epidemiology of *Sarcoptes scabiei. Annu Rev Entomol.* 1989;34(1):139–161
9. Meinking T. Infestations. *Curr Probl Dermatol.* 1999;11(3): 73–120
10. Falk ES, Bolle R. IgE antibodies to house dust mite in patients with scabies. *Br J Dermatol.* 1980;103(3):283–288
11. Kristjansson AK, Smith MK, Gould JW, Gilliam AC. Pink pigtails are a clue for the diagnosis of scabies. *J Am Acad Dermatol.* 2007;57(1):174–175
12. Dupuy A, Dehen L, Bourrat E, et al. Accuracy of standard dermoscopy for diagnosing scabies. *J Am Acad Dermatol.* 2007;56 (1):53–62
13. Levitt JO. Digital photography in the diagnosis of scabies. *J Am Acad Dermatol.* 2008;59(3):530

Downloaded from http://pedsinreview.aappublications.org/ at Eccles Health Sciences Lib on October 16, 2014

14. Chouela E, Abeldaño A, Pellerano G, Hernández MI. Diagnosis and treatment of scabies: a practical guide. *Am J Clin Dermatol.* 2002;3(1):9–18

15. Argenziano G, Fabbrocini G, Delfino M. Epiluminescence microscopy. A new approach to in vivo detection of *Sarcoptes scabiei*. *Arch Dermatol.* 1997;133(6):751–753

16. McCarthy JS, Kemp DJ, Walton SF, Currie BJ. Scabies: more than just an irritation. *Postgrad Med J.* 2004;80(945):382–387

17. Burgess IF. Human lice and their management. *Adv Parasitol.* 1995;36:271–342

18. Chosidow O. Scabies and pediculosis. *Lancet.* 2000;355 (9206):818–826

19. Cargill CF, Pointon AM, Davies PR, Garcia R. Using slaughter inspections to evaluate sarcoptic mange infestation of finishing swine. *Vet Parasitol.* 1997;70(1–3):191–200

20. Danielssen DC, Boeck W. *Traité de la Spédalskhed on Eléphantiasis des Grecs.* Paris, France: JB Baillière. Translated by L. A. Cosson; 1848

21. Hengge UR, Currie BJ, Jäger G, Lupi O, Schwartz RA. Scabies: a ubiquitous neglected skin disease. *Lancet Infect Dis.* 2006;6(12):769–779

22. Walton SF, McBroom J, Mathews JD, Kemp DJ, Currie BJ. Crusted scabies: a molecular analysis of S*arcoptes scabiei* variety *hominis* populations from patients with repeated infestations. *Clin Infect Dis.* 1999;29(5):1226–1230

23. Cabrera R, Agar A, Dahl MV. The immunology of scabies. *Semin Dermatol.* 1993;12(1):15–21

24. Roberts LJ, Huffam SE, Walton SF, Currie BJ. Crusted scabies: clinical and immunological findings in seventy-eight patients and a review of the literature. *J Infect.* 2005;50(5):375–381

25. Dixon C. Scabies—a golden opportunity. *Public Health.* 1941; 55:10–14

26. Mellanby K. Scabies in 1976. *R Soc Health J.* 1977;97(1): 32–36, 40

27. Bastian HM, Lindgren AM, Alarcón GS. Scabies mimicking systemic lupus erythematosus. *Am J Med.* 1997;102(3):305–306

28. Ploysangam T, Breneman DL, Mutasim DF. Cutaneous pseudolymphomas. *J Am Acad Dermatol.* 1998;38(6 pt 1):877–895, quiz 896–897

29. Gach JE, Heagerty A. Crusted scabies looking like psoriasis. *Lancet.* 2000;356(9230):650

30. Tidman MJ, Adamson B, Allan S, Wallace WH. Childhood scabies mistaken for Langerhans cell histiocytosis. *Clin Exp Dermatol.* 2003;28(1):111–112

31. Janik-Moszant A, Tomaszewska R, Szczepański T, Sońta-Jakimczyk D, Pobudejska A. Infantile scabies or Langerhans cell histiocytosis? *Med Pediatr Oncol.* 2003;40(2):111–112

32. Talanin NY, Smith SS, Shelley ED, Moores WB. Cutaneous histiocytosis with Langerhans cell features induced by scabies: a case report. *Pediatr Dermatol.* 1994;11(4):327–330

33. Burch JM, Krol A, Weston WL. *Sarcoptes scabiei* infestation misdiagnosed and treated as Langerhans cell histiocytosis. *Pediatr Dermatol.* 2004;21(1):58–62

34. Balighi K, Robati RM, Hejazi N. A dilemma: bullous-pemphigoid-like eruption in scabies or scabies-induced bullous pemphigoid. *Dermatol Online J.* 2006;12(4):13

35. Bhawan J, Milstone E, Malhotra R, Rosenfeld T, Appel M. Scabies presenting as bullous pemphigoid-like eruption. *J Am Acad Dermatol.* 1991;24(2 pt 1):179–181

36. Ackerman AB, Stewart R, Stillman M. Scabies masquerading as dermatitis herpetiformis. *JAMA.* 1975;233(1):53–54

37. Cestari TF, Martignago BF. Scabies, pediculosis, bedbugs, and stinkbugs: uncommon presentations. *Clin Dermatol.* 2005;23(6): 545–554

38. Currie B, Huffam S, O'Brien D, Walton S. Ivermectin for scabies. *Lancet.* 1997;350(9090):1551

39. Elimite cream [package insert]. Irving, CA: Allergan, Inc; 2007

40. Lindane lotion 1% [package insert]. Morton Grove, IL: Morton Grove Pharmaceuticals; 2007

41. Idriss S, Levitt J. Malathion for head lice and scabies: treatment and safety considerations. *J Drugs Dermatol.* 2009;8(8): 715–720

42. Arlian LG, Estes SA, Vyszenski-Moher DL. Prevalence of *Sarcoptes scabiei* in the homes and nursing homes of scabietic patients. *J Am Acad Dermatol.* 1988;19(5 pt 1):806–811

43. Taplin D, Porcelain SL, Meinking TL, et al. Community control of scabies: a model based on use of permethrin cream. *Lancet.* 1991;337(8748):1016–1018

44. Carapetis JR, Connors C, Yarmirr D, Krause V, Currie BJ. Success of a scabies control program in an Australian aboriginal community. *Pediatr Infect Dis J.* 1997;16(5):494–499

45. Lebwohl M, Clark L, Levitt J. Therapy for head lice based on life cycle, resistance, and safety considerations. *Pediatrics.* 2007;119 (5):965–974

46. Hegazy AA, Darwish NM, Abdel-Hamid IA, Hammad SM. Epidemiology and control of scabies in an Egyptian village. *Int J Dermatol.* 1999;38(4):291–295

47. Zargari O, Golchai J, Sobhani A, et al. Comparison of the efficacy of topical 1% lindane vs 5% permethrin in scabies: a randomized, double-blind study. *Indian J Dermatol Venereol Leprol.* 2006;72(1):33–36

48. Hansen RC, Remmers E, Menter MA. A controlled comparative trial of permethrin 5% dermal cream and 1% lindane lotion for the treatment of scabies. *Clin Res.* 1986; 34(1):160A

49. Taplin D, Meinking TL, Porcelain SL, Castillero PM, Chen JA. Permethrin 5% dermal cream: a new treatment for scabies. *J Am Acad Dermatol.* 1986;15(5 pt 1):995–1001

50. Taplin D, Meinking TL, Chen JA, Sanchez R. Comparison of crotamiton 10% cream (Eurax) and permethrin 5% cream (Elimite) for the treatment of scabies in children. *Pediatr Dermatol.* 1990;7 (1):67–73

51. Haustein UF, Hlawa B. Treatment of scabies with permethrin versus lindane and benzyl benzoate. *Acta Derm Venereol.* 1989;69 (4):348–351

52. van der Rhee HJ, Farquhar JA, Vermeulen NP. Efficacy and transdermal absorption of permethrin in scabies patients. *Acta Derm Venereol.* 1989;69(2):170–173

53. Yonkosky D, Ladia L, Gackenheimer L, Schultz MW. Scabies in nursing homes: an eradication program with permethrin 5% cream. *J Am Acad Dermatol.* 1990;23(6 pt 1):1133–1136

54. Schultz MW, Gomez M, Hansen RC, et al. Comparative study of 5% permethrin cream and 1% lindane lotion for the treatment of scabies. *Arch Dermatol.* 1990;126(2):167–170

55. Usha V, Gopalakrishnan Nair TV. A comparative study of oral ivermectin and topical permethrin cream in the treatment of scabies. *J Am Acad Dermatol.* 2000;42(2 pt 1):236–240

56. Strong M, Johnstone PW. Interventions for treating scabies. *Cochrane Database Syst Rev.* 2007;(3):CD000320

57. Walton SF, Myerscough MR, Currie BJ. Studies in vitro on the relative efficacy of current acaricides for *Sarcoptes scabiei* var. *hominis*. *Trans R Soc Trop Med Hyg.* 2000;94(1):92–96

Downloaded from http://pedsinreview.aappublications.org/ at Eccles Health Sciences Lib on October 16, 2014

58. Walker GJ, Johnstone PW. Interventions for treating scabies. *Cochrane Database Syst Rev*. 2000;(3):CD000320
59. Mounsey KE, Holt DC, McCarthy J, Currie BJ, Walton SF. Scabies: molecular perspectives and therapeutic implications in the face of emerging drug resistance. *Future Microbiol.* 2008;3(1): 57–66
60. Pasay C, Arlian L, Morgan M, et al. The effect of insecticide synergists on the response of scabies mites to pyrethroid acaricides. *PLoS Negl Trop Dis.* 2009;3(1):e354
61. Derbac M. Liquid [package insert]. Manchester, United Kingdom: SSL International; 2008
62. Hanna NF, Clay JC, Harris JR. *Sarcoptes scabiei* infestation treated with malathion liquid. *Br J Vener Dis.* 1978;54(5):354
63. Burgess I, Robinson RJ, Robinson J, Maunder JW, Hassan Z. Aqueous malathion 0.5% as a scabicide: clinical trial. *Br Med J (Clin Res Ed)*. 1986;292(6529):1172
64. Thianprasit M, Schuetzenberger R. Prioderm lotion in the treatment of scabies. *Southeast Asian J Trop Med Public Health.* 1984;15(1):119–121
65. Myint KM. Scabies in a nursing home. *Public Health.* 1990; 104(3):189–190
66. Madan V, Jaskiran K, Gupta U, Gupta DK. Oral ivermectin in scabies patients: a comparison with 1% topical lindane lotion. *J Dermatol.* 2001;28(9):481–484
67. Conti Díaz IA, Amaro J. Treatment of human scabies with oral ivermectin. *Rev Inst Med Trop Sao Paulo.* 1999;41(4):259–261
68. Dourmishev A, Serafimova D, Dourmishev L. Efficacy and tolerance of oral ivermectin in scabies. *J Eur Acad Dermatol Venereol.* 1998;11(3):247–251
69. Elmogy M, Fayed H, Marzok H, Rashad A. Oral ivermectin in the treatment of scabies. *Int J Dermatol.* 1999;38(12):926–928
70. Offidani A, Cellini A, Simonetti O, Fumelli C. Treatment of scabies with ivermectin. *Eur J Dermatol.* 1999;9(2):100–101
71. Stromectol [package insert]. Whitehouse Station, NJ: Merck & Co, Inc; 2009
72. Paasch U, Haustein UF. Management of endemic outbreaks of scabies with allethrin, permethrin, and ivermectin. *Int J Dermatol.* 2000;39(6):463–470
73. Meinking TL, Burkhart CN, Burkhart CG. Infestations. In: Bolognia JL, Jorizzo JL, Rapini RP, eds. *Dermatology.* New York, NY: Mosby; 2003:1323–1324
74. Currie B, Hengge U. Scabies. In: Tyring SK, Lupi O, Hengge UR, eds. *Tropical Dermatology.* Philadelphia, PA: Elsevier Churchill Livingstone; 2006:375–385
75. Amer M, el-Gharib I. Permethrin versus crotamiton and lindane in the treatment of scabies. *Int J Dermatol.* 1992;31(5): 357–358
76. Taplin D, Rivera A, Walker JG, Roth WI, Reno D, Meinking T. A comparative trial of three treatment schedules for the eradication of scabies. *J Am Acad Dermatol.* 1983;9(4):550–554
77. Environmental Protection Agency. NAFTA decisions pressure FDA to limit use of key dual-use chemical. EPA Water Policy Report. Volume 16, Number 1, January 8, 2007:20–21
78. Glaziou P, Cartel JL, Alzieu P, Briot C, Moulia-Pelat JP, Martin PM. Comparison of ivermectin and benzyl benzoate for treatment of scabies. *Trop Med Parasitol.* 1993;44(4):331–332
79. Currie BJ, Harumal P, McKinnon M, Walton SF. First documentation of in vivo and in vitro ivermectin resistance in *Sarcoptes scabiei*. *Clin Infect Dis.* 2004;39(1):e8–e12
80. Brooks PA, Grace RF. Ivermectin is better than benzyl benzoate for childhood scabies in developing countries. *J Paediatr Child Health.* 2002;38(4):401–404

Downloaded from http://pedsinreview.aappublications.org/ at Eccles Health Sciences Lib on October 16, 2014

Scabies: A Review of Diagnosis and Management Based on Mite Biology

Alexandra K. Golant and Jacob O. Levitt

Pediatrics in Review 2012;33;e1
DOI: 10.1542/pir.33-1-e1

Updated Information & Services	including high resolution figures, can be found at: http://pedsinreview.aappublications.org/content/33/1/e1
References	This article cites 69 articles, 7 of which you can access for free at: http://pedsinreview.aappublications.org/content/33/1/e1#BIBL
Subspecialty Collections	This article, along with others on similar topics, appears in the following collection(s): **Dermatology** http://pedsinreview.aappublications.org/cgi/collection/dermatology_sub **Infectious Diseases** http://pedsinreview.aappublications.org/cgi/collection/infectious_diseases_sub
Permissions & Licensing	Information about reproducing this article in parts (figures, tables) or in its entirety can be found online at: http://pedsinreview.aappublications.org/site/misc/Permissions.xhtml
Reprints	Information about ordering reprints can be found online: http://pedsinreview.aappublications.org/site/misc/reprints.xhtml

American Academy of Pediatrics
DEDICATED TO THE HEALTH OF ALL CHILDREN™

Downloaded from http://pedsinreview.aappublications.org/ at Eccles Health Sciences Lib on October 16, 2014