Allergology International. 2010;59:✱✱✱-✱✱✱
DOI: 10.2332/allergolint.10-RAI-0223

REVIEW ARTICLE

Role of IgE in Eosinophilic Otitis Media

Yukiko Iino[1]

ABSTRACT
Eosinophilic otitis media (EOM) is an intractable otitis media characterized by the presence of a highly viscous yellow effusion containing eosinophils. It mainly occurs in patients with bronchial asthma and is resistant to conventional treatments for otitis media. Here we discuss the role of IgE in the pathogenesis of EOM. In middle ear effusion, a significantly higher IgE level was detected in EOM patients than in control patients with common otitis media with effusion. This IgE level was significantly higher (about 10 fold) than the serum IgE level. In addition, many IgE-immunopositive cells were found in the middle ear mucosa. The IgE staining was mainly observed on mast cell surfaces, but also partially in the cytoplasm of cells that appeared to be plasma cells. These results suggested that IgE is produced locally in the middle ear mucosa. The existence of high-level IgE may exacerbate eosinophilic inflammation in the middle ear. One of the most distinct characteristics of EOM is the high incidence of sensory hearing loss independent of age. High-tone hearing loss is more frequently found and more severe in EOM patients than in control patients with common chronic otitis media. The concentration of IgE in middle ear effusion significantly and positively correlated with bone conduction hearing levels at 2 kHz and 4 kHz in EOM patients. Overproduction of IgE locally in the middle ear may be related to the pathological condition of EOM and eventually cause inner ear damage.

KEY WORDS
bronchial asthma, eosinophilic otitis media, eosinophils, IgE, sensory hearing loss

INTRODUCTION

Eosinophilic otitis media (EOM) is an intractable otitis media characterized by the presence of a highly viscous yellow effusion containing eosinophils. It mainly occurs in patients with bronchial asthma and is resistant to conventional treatments for otitis media. In 1993, Tomoioka *et al.*[1] first reported on three cases of patients suffering from intractable otitis media associated with bronchial asthma as a new middle ear disease entitiy. They proposed to name this otitis media eosinophilic otitis media (EOM) in 1997.[2] Today, 13 years after the proposal, cases of this disease have accumulated and the clinical characteristics of the disease have become clear. Not only is EOM an intractable and persistent disease, it also presents a high risk of developing severe hearing loss (deafness in some cases).[1-3] The pathological condition of this disease has been demonstrated as active inflammation of the middle ear with production of various chemical mediators that induce migration of eosinophils in the middle ear mucosa.[4-6] In patients with EOM, high concentration of immunoglobulin E (IgE), playing a crucial role in type I allergic reaction, is detected in middle ear effusion. In addition, many IgE-immunopositive cells were found in the middle ear mucosa,[4] indicating that IgE is potentially related to the pathological condition of EOM. In this paper, we discuss the role of IgE in the pathogenesis of EOM.

PATHOGENESIS OF EOM

MECHANISM OF INFILTRATION OF EOSINOPHILS INTO THE MIDDLE EAR

Histological examination of middle ear effusion showed that a large number of eosinophils, which are considered to be eosinophilic mucin, in addition to a mucus component, was observed. Many of these eosinophils are degranulated, and some eosinophils exhibit cytolysis with the nucleus breaking out of the cells (Fig. 1). However, there are not as many eosinophils observed in the middle ear mucosa as in the middle ear effusion (Fig. 2). It is considered that eosinophils that migrated to the middle ear mucosa do not stay locally in the middle ear but migrate immediately to the middle ear cavity. In contrast, nasal

[1]Department of Otolaryngology, Jichi Medical University Saitama Medical Center, Saitama, Japan.
Correspondence: Yukiko Iino, MD, PhD, Department of Otolaryngology, Jichi Medical University Saitama Medical Center, 1–847 Amanuma-cho, Omiya-ku, Saitama 330–8503, Japan.
Email: yiino@jichi.ac.jp
Received 5 May 2010. Accepted for publication .
©2010 Japanese Society of Allergology

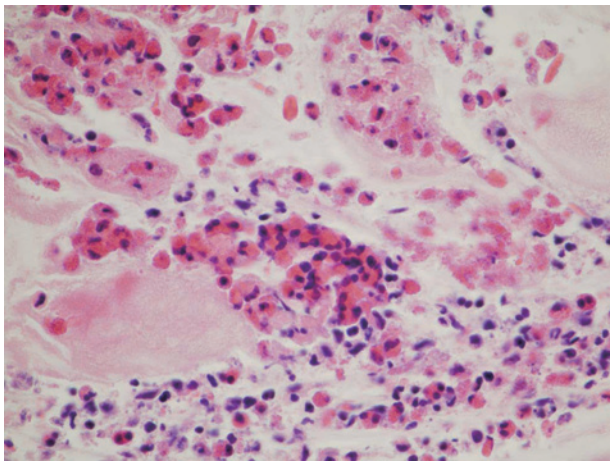

Fig. 1 Histological section of middle ear effusion in a patient with EOM (HE stainings).

polyps and the paranasal sinus mucosa of patients with eosinophilic chronic rhinosinusitis show extensive accumulation of eosinophils in the submucosa (Fig. 3). Therefore, the mechanism of eosinophil migration and survival may be slightly different between middle ear mucosa and paranasal mucosa/nasal polyps.

Eosinophil cationic protein (ECP) is an eosinophil-derived cytoplasmic protein and is a marker for eosinophilic inflammation. The concentration of ECP in the middle ear effusion of EOM patients was significantly higher than that in the control patients with common otitis media with effusion.[4] Moreover, a significantly larger number of EG2-positive cells were observed in the middle ear mucosa of EOM patients than in the control patients, proving that active eosinophilic inflammation is occurring in EOM.[4] Regarding eosinophil chemoattractants, the concentrations of IL-5 and eotaxin in middle ear effusion were significantly higher in EOM patients than in the con-

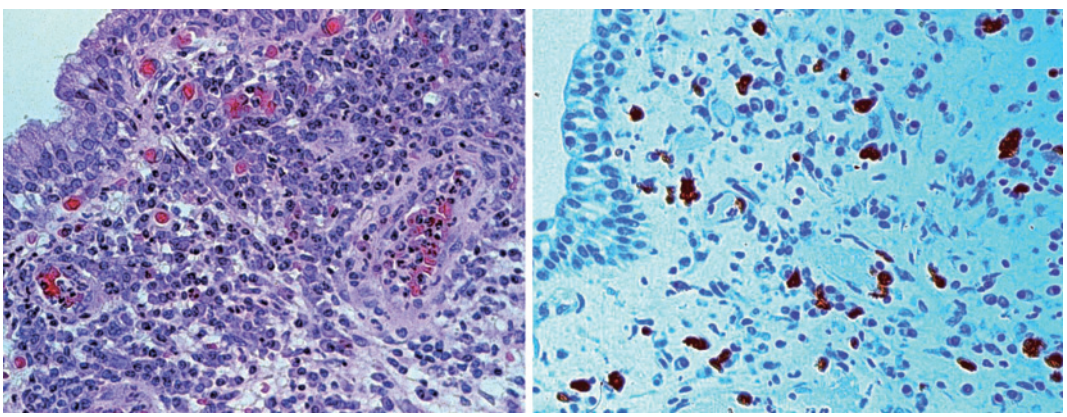

HE EG2

Fig. 2 Histological and immunohistological sections of middle ear mucosa in a patient with eosinophilic otitis media.

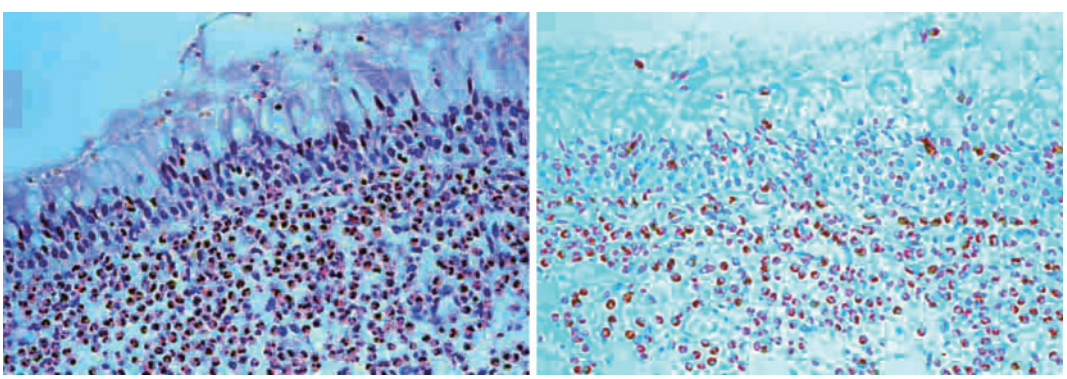

HE EG2

Fig. 3 Histological and immunohistological sections of paranasal sinus mucosa in a patient with eosinophilic chronic rhinosinusitis.

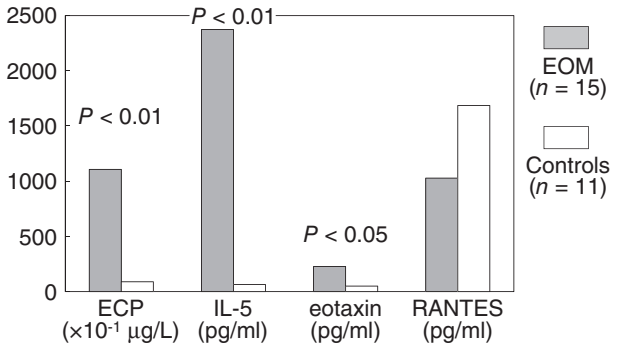

Fig. 4 Concentrations of eosinophil chemoattractants in middle ear effusion in patients with eosinophilic otitis media (EOM) and in patients with common otitis media with effusion (controls).

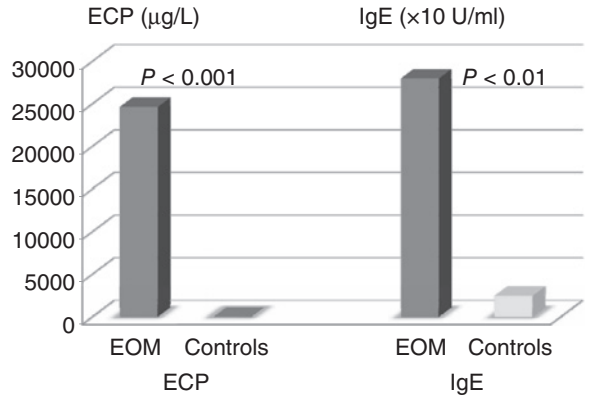

Fig. 5 Concentrations of ECP and IgE in middle ear effusion in patients with eosinophilic otitis media (EOM) and in patients with common otitis media with effusion (controls).

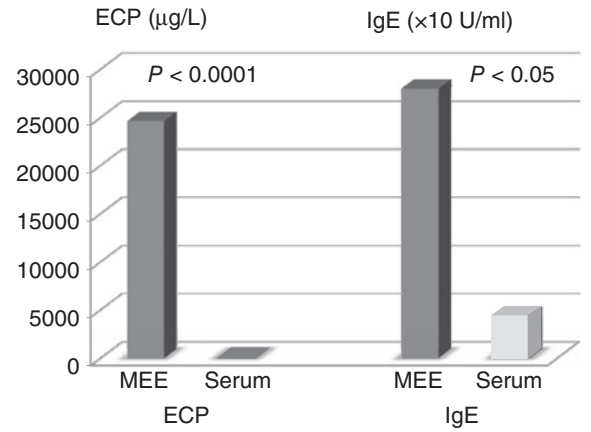

Fig. 6 Concentrations of ECP and IgE in middle ear effusion and serum in patients with eosinophilic otitis media.

trol group (Fig. 4).[5,6] However, no significant difference in regulated on activation normal T cell expressed and secreted (RANTES) level was observed between the EOM patients group and the control group (Fig. 1).[6] ECP concentration positively correlated with that of IL-5. IL-5 is a cytokine involved in not only eosinophil migration but also local activation of eosinophils and increased cell survival. IL-5 is considered to be most highly involved in the pathological condition of eosinophilic inflammation in EOM.

Immunohistochemically, the number of cells immunopositive for IL-5 and ecalectin, which are the chemotactic and activating factors for eosinophils, significantly increased in the middle ear mucosa of EOM patients compared with that of the control patients. Furthermore, the expressions of eotaxin, RANTES and ecalectin mRNAs were detected by *in situ* hybridization.[6] The fact that chemotactic and activating factors for eosinophils were detected not only at the protein level but also at the mRNA level, indicated that active eosinophilic inflammation occurs in the middle ear itself.

IgE IN EOM

IgE is an immunoglobulin produced by B lymphocytes, and plays an important role in type I allergic reactions. IgE binds to the surface of mast cells, and the mast cells degranulate when an antigen binds and bridges two IgEs, releasing many types of chemical substance that cause various inflammatory conditions. Although an increased antigen-specific IgE level is not always detected in patients with EOM, many of them showed higher levels of total IgE in serum. A significantly higher IgE level, similar to ECP level, was detected in middle ear effusion in the EOM patient group than in the control group (Fig. 5).[7] This IgE level was significantly higher (about 10 fold) than serum IgE level, and hence IgE in the former is considered to have been produced locally in the middle ear (Fig. 6).[7] Immunohistological examination also showed many IgE-positive cells in the middle ear mucosa. The immunostainings of IgE was generally observed on mast cell surfaces, but also partially in the cytoplasm of cells that appeared to be plasma cells (Fig. 7).[4] IgE is therefore considered to be produced locally in the middle ear mucosa. Bachert *et al.*[8] reported that significant concentrations of IgE specific to *Staphylococcus aureus* enterotoxins A and B were detected in the nasal polyp tissue from patients with chronic rhinosinusitis. As the patients showed no increase in antigen-specific IgE level in serum or no positive reaction in skin test, they concluded that IgE was produced locally in nasal polyps. *Staphylococcus aureus* enterotoxins A and B also have the properties of superantigens which can strongly stimulate IgE production. In case of EOM, substance(s) that stimulates IgE production in the middle ear is as yet undetermined, and this should be investigated in detail in the future.

In type I allergic reaction, eosinophils also play an important role in the late phase of reaction. In an animal model, it was also reported that not IgG_1 but IgE

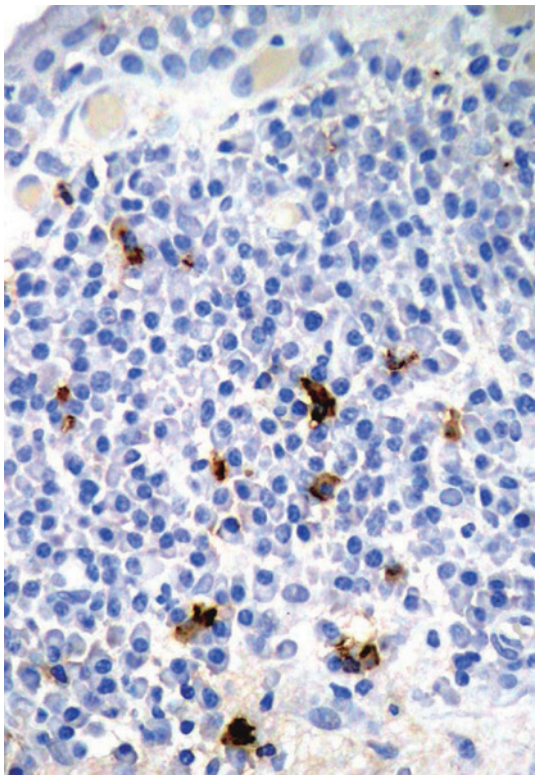

Fig. 7 A immunohistological section of middle ear mucosa of a patient with EOM. Many IgE-immunopositive cells are seen in the submucosa.

is involved in airway inflammation and hypersensitivity in the late phase of reaction in bronchial asthma.[9] FcεRI, a high-affinity receptor of IgE, was found in eosinophils and the pathway for the release of cytotoxic proteins from eosinophils was demonstrated as an IgE-dependent hypersensitivity reaction.[10] The existence of high-level IgE may exacerbate eosinophilic inflammation in the middle ear together with various cellular factors such as reactive oxygen species, cytokines, and chemokines released by eosinophils (Fig. 8).

SENSORY HEARING LOSS AND IgE IN EOM

Patients with EOM have conductive hearing loss in the initial stage but begin to develop mixed-type hearing loss during the course of the disease. It was reported that some patients exhibited an increased bone-conduction threshold, which led to deafness in some of them.[1-3] An epidemiological survey in Japan showed that 47% of patients showed an increased bone conduction hearing level (BCHL), 6% of which eventually became deaf.[11] Generally, the type of hearing loss in patients with EOM is mostly high-tone loss.[12] However, it is generally accepted that ears with common type of chronic otitis media also show gradual sensorineural hearing loss compared with healthy ears,[13,14] and in these studies, a significant increase in BCHL was also found at higher frequencies. It seems likely that the BCHL deterioration associated with EOM is one of the symptoms, which is sometimes observed in COM. Therefore, we com-

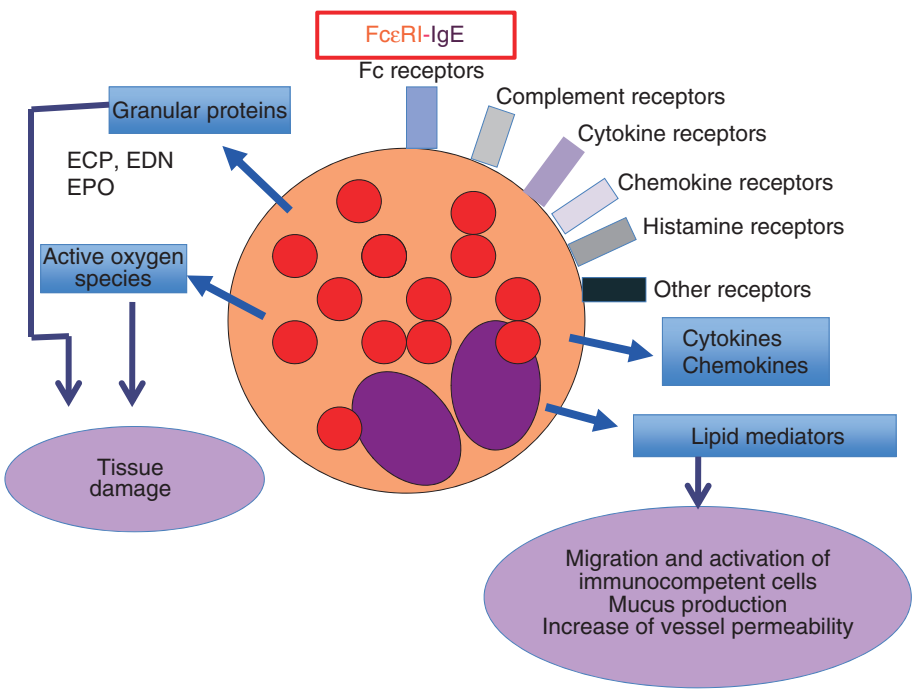

Fig. 8 Role of eosinophils in inflammatory conditions.

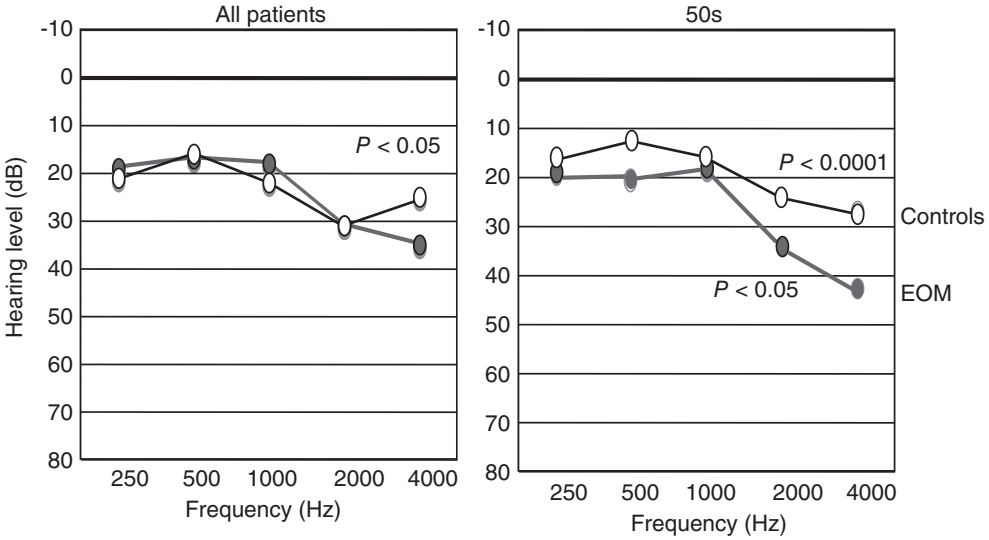

Fig. 9 Bone conduction hearing level of patients with eosinophilic otitis media (EOM: 65 ears) and common chronic otitis media (controls: 71 ears).

pared BCHL in non-eosinophilic chronic otitis media patients who had undergone tympanoplasty (control group) with that in patients with EOM (EOM group), and found that the incidence and extent of increase in BCHL in high frequencies were significantly higher in the latter group. The difference was notably significant in patients in their 50s (Fig. 9).[15] Nakagawa *et al.*[16] reported that in case of EOM, BCHLs at 4000 and 8000 Hz were higher than those at lower frequencies, and the loss rate was about 10 times that in case of COM, which was reported by Cusimano *et al.*[17] In our study, the infected ear with granulomatous otitis media was often accompanied by a significant increase in BCHL.[15] These findings suggest that bacterial infection and eosinophilic inflammation in the middle ear might exert a synergistic effect on inner ear damage.

We measured the concentrations of ECP and IgE in middle ear effusion as markers of eosinophilic inflammation,[18,19] and analyzed the correlation between these concentrations and BCHL in EOM patients to determine whether eosinophilic inflammation is indeed related to the deterioration of BCHL. As the results, the concentration of IgE in middle ear effusion significantly and positively correlated with BCHL at 2 kHz and 4 kHz.[7] The ears with a higher concentration of ECP in middle ear effusion also tended to show deterioration of BCHL at 4 kHz. Other clinical risk factors for BCHL deterioration were male gender, long duration of EOM, association with bacterial infection, severe inflammatory changes of the middle ear mucosa, and high serum IgE concentration.[7]

The mechanism underlying inner ear damage by eosinophilic and bacterial inflammation is unclear. Eosinophils are much more cytotoxic than neutrophils,[20] because eosinophils can generate a higher level of reactive oxygen species than neutrophils.[21] The cytotoxic proteins and active oxygen species generated by eosinophils may damage the epithelial layer including the round window membrane, and lipid mediators released from eosinophils render the membrane permeable. These events allow inflammatory substances such as bacterial toxins and inflammatory cytokines to enter into the inner ear, resulting in inner ear damage. Sensory hearing loss varies from stable over a long period of time in some patients to the rapid deterioration in other patients. The IgE level in middle ear effusion may become a good indicator of increase in BCHL.

CONCLUSIONS

Overproduction of IgE locally in the middle ear may be related to the pathological condition of EOM and eventually inner ear damage. Currently, an effective treatment for EOM is administration of systemic and topical corticosteroids,[22] and irrigation of the middle ear using saline-heparin solution.[12] However, therapy targeting IgE, that is, anti-IgE antibody therapy with omalizumab for example, could establish to cure or improve EOM.

REFERENCES

1. Tomioka S, Yuasa R, Iino Y. Intractable otitis media in cases with bronchial asthma. In: Mogi G, Honjo I, Ishii T, Takasaka T (eds). *Recent Advances in Otitis Media, Proceedings of the Second Extraordinary International Symposium on Recent Advances in Otitis Media.* Amsterdam/New York: Kugler Publications, 1993;183-6.
2. Tomioka S, Kobayashi T, Takasaka T. Intractable otitis media in patients with bronchial asthma (eosinophilic otitis media). In: Sanna M (ed). *Cholesteatoma and Mastoid Surgery.* Rome: CIC Edizioni Internazionali, 1997;851-3.
3. Nagamine H, Iino Y, Kojima C, Miyazawa T, Iida T. Clini-

cal characteristics of so- called eosinophilic otitis media. *Auris Nasus Larynx* 2002;**29**:19-28.
4. Iino Y, Nagamine H, Yabe T, Matsutani S. Eosinophils are activated in middle ear mucosa and middle ear effusion of patients with intractable otitis media associated with bronchial asthma. *Clin Exp Allergy* 2001;**31**:1135-43.
5. Nonaka M, Fukumoto A, Ozu C *et al*. IL-5 and eotaxin levels in middle ear effusion and blood from asthmatics with otitis media with effusion. *Acta Otolaryngol* 2003;**123**:383-7.
6. Iino Y, Kakizaki K, Katano H, Saigusa H, Kanegasaki S. Eosinophil chemoattractant in middle ear patients with eosinophilic otitis media. *Clin Exp Allergy* 2005;**35**:1370-6.
7. Iino Y, Usubuchi H, Kodama K *et al*. Eosinophilic inflammation in the middle ear induces deterioration of bone conduction hearing level in patients with eosinophilic otitis media. *Otol Neurotol* 2010;**31**:100-4.
8. Bachert C, Gevaert P, Holtappels G, Johansson SG, van Cauwenberge P. Total and specific IgE in nasal polyps is related to local eosinophilic inflammation. *J Allergy Clin Immunol* 2001;**107**:607-14.
9. Itami DM, Latinne D, Bazin H *et al*. Immunoglobulin E is not required for but enhances airway inflammation and hyperresponsiveness. *Allegy* 2003;**58**:1117-24.
10. Capron M. Eosiophils: receptors and mediators in hypersensitivity. *Clin Exp Allergy* 1989;**19** (Suppl 1):3-8.
11. Suzuki H, Matsutani S, Kawase T *et al*. [Epidemiologic surveillance of "eosinophilic otitis media" in Japan]. *Otol Jpn* 2004;**14**:112-7(in Japanese).
12. Iino Y. Eosinophilic otitis media: A new middle ear disease entitiy. *Curr Allergy Asthma Rep* 2008;**8**:525-30.
13. El-Sayed Y. Bone conduction impairment in uncomplicated chronic suppurative otitis media. *Am J Otolaryngol* 1998;**19**:149-53.
14. Blakley BW, Kim S. Dose chronic otitis media cause sensorineural hearing loss? *J Otolaryugol* 1998;**27**:17-20.
15. Iino Y, Usubuchi H, Kodama K, Takizawa K, Kanazawa T, Ohta Y. Bone conduction hearing level in patients with eosinophilic otitis media associated with bronchial asthma. *Otol Neurotol* 2008;**29**:949-52.
16. Nakagawa T, Matsubara A, Shiratsuchi H *et al*. Intractable otitis media with eosinophils; Importance of diagnosis and validity of treatment for hearing preservation. *ORL J Otorhinolaryngol Relat Spec* 2006;**68**:118-22.
17. Cusimano F, Cocita VC, D'Amico A. Sensorineural hearing loss in chronic otitis media. *J Laryngol Otol* 1989;**103**:158-63.
18. Barck C, Lundahl J, Halldén G, Bylin G. Total eosinophil cationic protein levels in induced sputum as a marker of changes in eosinophilic inflammation in a patient with allergic asthma. *Ann Allergy Asthma Immunol* 2005;**95**:86-92.
19. Zeller S, Glaser AG, Vilhelmsson M, Rhyner C, Crameri R. Immunoglobulin-E-mediated reactivity to self antigens: a controversial issue. *Int Arch Allergy Immunol* 2008;**145**:87-93.
20. Robers RL, Ank BJ, Stiehm ER. Human eosinophils are more toxic than neutrophils in antibody-independent killing. *J Allergy Clin Immunol* 1991;**6**:1105-15.
21. Shult PA, Graziano FM, Wallow IH, Busse WW. Comparison of superoxide generation and luminal-dependent chemiluminescence with eosinophils and neutrophils from normal individuals. *J Lab Clin Med* 1985;**106**:638-45.
22. Iino Y, Nagamine H, Kakizaki K *et al*. Effectiveness of instillation of triamcinolone acetonide into middle ear for eosinophilic otitis media associated with bronchial asthma. *Ann Allergy Asthma Immunol* 2006;**97**:761-6.