Task force report

Cutaneous manifestations in patients with mastocytosis: Consensus report of the European Competence Network on Mastocytosis; the American Academy of Allergy, Asthma & Immunology; and the European Academy of Allergology and Clinical Immunology

Karin Hartmann, MD,[a,b] Luis Escribano, MD, PhD,[c] Clive Grattan, MA, MD,[d] Knut Brockow, MD,[e] Melody C. Carter, MD,[f] Ivan Alvarez-Twose, MD,[g] Almudena Matito, MD, PhD,[g] Sigurd Broesby-Olsen, MD,[h] Frank Siebenhaar, MD,[i] Magdalena Lange, MD, PhD,[j] Marek Niedoszytko, MD, PhD,[k] Mariana Castells, MD, PhD,[l] Joanna N. G. Oude Elberink, MD, PhD,[m] Patrizia Bonadonna, MD,[n] Roberta Zanotti, MD,[o] Jason L. Hornick, MD, PhD,[p] Antonio Torrelo, MD,[q] Jürgen Grabbe, MD,[r] Anja Rabenhorst, PhD,[a] Boguslaw Nedoszytko, PhD,[j] Joseph H. Butterfield, MD,[s] Jason Gotlib, MD,[t] Andreas Reiter, MD,[u] Deepti Radia, MD,[v] Olivier Hermine, MD, PhD,[w] Karl Sotlar, MD,[x] Tracy I. George, MD,[y] Thomas K. Kristensen, PhD,[z] Hanneke C. Kluin-Nelemans, MD, PhD,[aa] Selim Yavuz, MD,[bb] Hans Hägglund, MD, PhD,[cc] Wolfgang R. Sperr, MD,[dd] Lawrence B. Schwartz, MD, PhD,[ee] Massimo Triggiani, MD, PhD,[ff] Marcus Maurer, MD,[i] Gunnar Nilsson, PhD,[gg] Hans-Peter Horny, MD,[x] Michel Arock, PharmD, PhD,[hh] Alberto Orfao, MD, PhD,[c] Dean D. Metcalfe, MD,[f] Cem Akin, MD, PhD,[l] and Peter Valent, MD[dd]

Cologne, Luebeck, Munich, Mannheim, and Berlin, Germany, Salamanca, Toledo, and Madrid, Spain, Norwich and London, United Kingdom, Bethesda, Md, Odense, Denmark, Gdansk, Poland, Boston, Mass, Groningen, The Netherlands, Verona and Salerno, Italy, Aarau, Switzerland, Rochester, Minn, Stanford, Calif, Paris and Cachan, France, Albuquerque, NM, Istanbul, Turkey, Stockholm, Sweden, Vienna, Austria, and Richmond, Va

Cutaneous lesions in patients with mastocytosis are highly heterogeneous and encompass localized and disseminated forms. Although a classification and criteria for cutaneous mastocytosis (CM) have been proposed, there remains a need to better define subforms of cutaneous manifestations in patients with mastocytosis. To address this unmet need, an international task force involving experts from different organizations (including the European Competence Network on Mastocytosis; the American Academy of Allergy, Asthma & Immunology; and the European Academy of Allergology and Clinical Immunology) met several times between 2010 and 2014 to discuss the classification and criteria for diagnosis of cutaneous manifestations in patients with mastocytosis. This article provides the major outcomes of these meetings and a proposal for a revised definition and criteria. In particular, we recommend that the typical maculopapular cutaneous lesions (urticaria pigmentosa) should be subdivided into 2 variants, namely a monomorphic variant with small maculopapular lesions, which is typically seen in adult patients, and a polymorphic variant with larger lesions of variable size and shape, which is typically seen in pediatric patients. Clinical observations suggest that the monomorphic variant, if it develops in children, often persists into adulthood, whereas the polymorphic variant may resolve around puberty. This delineation might have important prognostic implications, and its implementation in diagnostic algorithms and future mastocytosis classifications is recommended. Refinements are also suggested for the diagnostic criteria of CM, removal of telangiectasia macularis eruptiva perstans from the current classification of CM, and removal of the adjunct solitary from the term solitary mastocytoma. (J Allergy Clin Immunol 2015;■■■:■■■-■■■.)

Key words: *Classification, cutaneous mastocytosis, diagnostic criteria, mast cell, mastocytosis, standardization, urticaria pigmentosa*

Mastocytosis is characterized by expansion of clonal mast cells in different organs, often related to activating *KIT* mutations.[1-6] The organs most frequently involved are the skin and bone marrow. Traditionally, the disease is divided into cutaneous mastocytosis (CM) and systemic mastocytosis (SM). CM is more frequently seen in children, whereas the majority of adults are given a diagnosis of SM. Patients with SM often also present with cutaneous involvement. Overall, more than 80% of all patients with mastocytosis exhibit characteristic brown or red skin lesions.[7] Darier's sign, which is defined by whealing and reddening of lesions upon mechanical stroking or rubbing, is usually demonstrable.[8] Skin lesions in patients with mastocytosis are highly heterogeneous and encompass localized and disseminated forms.

The classification of CM has been based on macroscopic features of skin lesions, their distribution, or disease onset.[9-15] In addition, different types of CM have been proposed based on their associations with disease progression or symptoms.[9-11,16] A generally accepted approach is to divide CM into (1) maculopapular cutaneous mastocytosis (MPCM), also known as urticaria pigmentosa; (2) diffuse cutaneous mastocytosis (DCM); and (3) mastocytoma of the skin (Fig 1). The World Health Organization confirmed this concept in 2001 and 2008.[3-5] In 2007, a European Union–US consensus group also established criteria for

Abbreviations used
CM: Cutaneous mastocytosis
DCM: Diffuse cutaneous mastocytosis
ISM: Indolent systemic mastocytosis
MPCM: Maculopapular cutaneous mastocytosis
SM: Systemic mastocytosis

cutaneous involvement in patients with mastocytosis.[17] These criteria include the presence of (1) a typical skin lesion (major criterion), (2) a histologically confirmed infiltrate of mast cells in the dermis (minor criterion), and (3) an activating *KIT* mutation at codon 816 in lesional skin (minor criterion).

Since the development of these classifications, however, the clinical manifestations, prognosis, and molecular findings in patients with mastocytosis have been analyzed in more detail. In particular, it appears that adult and pediatric patients, who manifest different disease courses, also exhibit different types of cutaneous lesions.[9,10,16,18-25] So far, however, it remains unknown whether specific skin lesions are associated with either distinct clinical manifestations, *KIT* mutations, or other genetic defects. This lack of knowledge might in part be due to different terminologies and classifications of skin lesions used in the past.[26-28] Therefore many of our colleagues believe that there is an unmet need to better define the different forms of CM.

To address this issue, an international task force involving experts from different medical specialties was initiated within the European Competence Network on Mastocytosis in collaboration with the American Academy of Allergy, Asthma & Immunology and the European Academy of Allergology and Clinical Immunology. The task force met between 2010 and 2014, including at the Consensus Conference on Mastocytosis in October 2012 in Boston. The current document describes the major outcomes of these meetings and proposes new and revised consensus definitions and criteria for cutaneous manifestations of mastocytosis.

DIFFERENT CHARACTERISTICS OF ADULTHOOD-ONSET AND CHILDHOOD-ONSET MASTOCYTOSIS

Mastocytosis can develop in adulthood or during childhood. There are several important distinctions between these 2 age

From [a]the Department of Dermatology, University of Cologne; [b]the Department of Dermatology, University of Luebeck; [c]Servicio Central de Citometria (NUCLEUS), Centro de Investigacion del Cancer (IBMCC; CSIC/USAL) and Department of Medicine and IBSAL, University of Salamanca; [d]Norfolk and Norwich University Hospital, Norwich; [e]the Department of Dermatology and Allergy Biederstein, Technical University of Munich; [f]the Laboratory of Allergic Diseases, National Institute of Allergy and Infectious Diseases, National Institutes of Health, Bethesda; [g]Instituto de Estudios de Mastocitosis de Castilla La Mancha (CLMast), Hospital Virgen del Valle, Toledo; [h]the Department of Dermatology and Allergy Centre and [z]the Department of Pathology, Odense University Hospital; [i]the Department of Dermatology and Allergy, Interdisciplinary Mastocytosis Center Charité, Charité Universitätsmedizin Berlin; the Departments of [j]Dermatology, Venereology and Allergology and [k]Allergology, Medical University of Gdansk; [l]the Division of Rheumatology, Immunology, and Allergy, Harvard Medical School, Brigham and Women's Hospital, Boston; [m]the Department of Allergology, Groningen Research Institute for Asthma and COPD, University Medical Center of Groningen, University of Groningen; [n]the Allergy Unit and [o]the Section of Hematology, Department of Medicine, Verona University Hospital; [p]the Department of Pathology, Brigham and Women's Hospital, and Harvard Medical School, Boston; [q]the Department of Dermatology, Hospital del Nino Jesus, Madrid; [r]the Department of Dermatology, Cantonal Hospital Aarau; [s]the Division of Allergic Diseases, Mayo Clinic, Rochester; [t]the Division of Hematology, Department of Medicine, Stanford University School of Medicine; [u]III. Medizinische Klinik, Universitätsmedizin Mannheim, Universität Heidelberg, Mannheim; [v]the Department of Haematology, Guys and St Thomas' NHS Foundation Trust, Guys Hospital, London; [w]the Department of Hematology, National Reference Center of Mastocytosis, INSERM U1163, CNRS ERL8564, Imagine Institute, Université Paris Descartes, Sorbonne, Paris Cité; [x]the Institute of Pathology, Ludwig-Maximilians-Universität, Munich; [y]the Department of Pathology, University of New Mexico, Albuquerque; [aa]the Department of Hematology, University Hospital Groningen, University of Groningen; [bb]the Department of Internal Medicine, Division of Hematology, University of Istanbul; [cc]Hematology Center Karolinska, Karolinska University Hospital, Stockholm; [dd]the Department of Internal Medicine I, Division of Hematology & Hemostaseology, Medical University of Vienna; [ee]the Department of Internal Medicine, Division of Rheumatology, Allergy & Immunology, Richmond; [ff]the Division of Allergy and Clinical Immunology, University of Salerno; [gg]Clinical Immunology and Allergy, Department of Medicine, Karolinska Institutet, Stockholm; and [hh]Molecular Oncology and Pharmacology, LBPA CNRS UMR8113, Ecole Normale Supérieure de Cachan.

Supported by research grants from the German Research Council (DFG; HA 2393/6-1; CRC/SFB832, project A14; to K.H.); from the Division of Intramural Research, National Institute of Allergy and Infectious Diseases (to D.D.M.); and from the Austrian Science Funds (FWF; projects SFB F4611 and SFB F4707-B20; to P.V.). The Consensus Conference on Mastocytosis in Boston, Massachusetts (October 2012), was supported by the American Academy of Allergy, Asthma & Immunology. A task force/consensus panel on mastocytosis between 2010 and 2012 was supported by the European Academy of Allergy and Clinical Immunology.

Disclosure of potential conflict of interest: K. Hartmann has consultant arrangements with Novartis and has received payment for lectures from Abbvie, Biogen, and Novartis. F. Siebenhaar has consultant arrangements with Novartis and Patara, has received grants from Patara, and has received payment for lectures from Novartis and Uriach. M. Niedoszytko has received travel support from National Science Center Poland (2011/01/M/NZS/01362). M. Castells is on the Board of Directors for the American Academy of Allergy, Asthma & Immunology; has consultant arrangements with Merck and Sanofi; is employed by Brigham and Women's Hospital; and has received grants from Ovations for the Cure. J. N. G. Oude Elberink has consultant arrangements with HAL Allergy; has received grants from ALK-Abelló, Meda, and Chiesi; and has received payment for lectures from Novartis. A. Torrelo has consultant arrangements with Bayer and has received payment for lectures from Pierre Fabre. J. H. Butterfield has received royalties for an HMC-1 cell line. J. Gotlib has received travel support from Novartis. O. Hermine has a board membership, consultant arrangements, patents, and stock/stock options with ABScience; has received grants from Celgene; and has received travel support from Celgene, Novartis, and Roche. T. I. George has received grants from Allakos, Seattle Genetics, and Novartis; has received a consulting fee or honorarium from Novartis, Blueprint Medicine, and the Mastocytosis Society; has received travel support and fees for participation in review activities from Novartis; has consultant arrangements with Celgene and Incyte; has received payment for lectures from Sysmex; has received royalties from the American Registry of Pathology, Wolters Kluwer, and UpToDate; and has received payment for development of educational presentations from the American Society of Clinical Pathology. H. C. Kluin-Nelemans has received travel support from Novartis. W. R. Sperr has received grants from Thermo Fisher Scientific, Lipomed, Novartis, and Meda; has received travel support from Novartis, Ariad, and Gilead; has consultant arrangements with Ariad and Celgene; and has received payment for lectures from Amgen and Celgene. L. B. Schwartz has received royalties from Thermo Fisher Scientific and Millipore. A. Orfao has received grants from the Ramon Areces Foundation and Instituto de Salud Carlos III, Ministry of Economy and Competitiveness. C. Akin has consultant arrangements with Novartis, Patara Pharma, and Blueprint Medicines; has received payment for lectures from Thermo Fisher Scientific; and has a patent for the LAD2 cell line. P. Valent has consultant arrangements with Novartis; has received grants from Novartis, Celgene, Capella, and Ariad; and has received payment for lectures from Novartis, Celgene, Ariad, Pfizer, and BMS. The rest of the authors declare that they have no relevant conflicts of interest.

Received for publication June 19, 2015; Revised July 27, 2015; Accepted for publication August 6, 2015.

Corresponding author: Karin Hartmann, MD, Department of Dermatology, University of Luebeck, Ratzeburger Allee 160, 23538 Luebeck, Germany. E-mail: karin.hartmann@uksh.de.

0091-6749/$36.00
© 2015 American Academy of Allergy, Asthma & Immunology
http://dx.doi.org/10.1016/j.jaci.2015.08.034

FIG 1. Subforms of CM. Cutaneous manifestations in mastocytosis are categorized into MPCM, presenting with disseminated brown lesions **(A)**; DCM, presenting with generalized erythema and thickened skin **(B)**; and mastocytoma, presenting with a brown or red elevated lesion **(C)**.

TABLE I. Characteristics of typical adulthood-onset and typical childhood-onset mastocytosis

Parameter	Adulthood-onset mastocytosis	Childhood-onset mastocytosis
Most frequent category of mastocytosis	ISM	Cutaneous mastocytosis
Typical course of the disease	Chronic	Temporary
Frequency of anaphylaxis (%)	50	<10
Typical tryptase level (μg/L)	>20	<20
Typical location of *KIT* mutation	Exon 17, most frequently *KIT* D816V	Exon 8, 9, 11, or 17 or absent
Most frequent type of cutaneous lesions	Maculopapular	Maculopapular
Typical morphology of maculopapular lesions	Monomorphic	Polymorphic
Typical size of maculopapular lesions	Small	Large
Typical distribution of maculopapular lesions	Thigh, trunk	Trunk, head, extremities

groups (Table I). In patients with adulthood-onset mastocytosis, cutaneous lesions are usually associated with SM, most often indolent systemic mastocytosis (ISM).[29-31] In contrast, CM without histologically evident involvement of other organs is found in the majority of pediatric patients.[19,21,24,32,33] The course of mastocytosis in adults is usually chronic, whereas children often have spontaneous resolution around puberty.[34-36] About 50% of adult patients experience anaphylaxis, whereas less than 10% of children do so.[37-42] In children the risk of anaphylactic reactions also correlates with the severity of skin involvement and the serum tryptase level.[16,19,41,43]

Moreover, recent studies have shown that adult and pediatric patients differ with respect to mutations in the *KIT* gene.[26,27,44,45] More than 80% of adult patients with mastocytosis carry the *KIT* D816V mutation in exon 17. In contrast, only 35% of patients with childhood-onset mastocytosis express *KIT* D816V; 40% of pediatric patients express other *KIT* mutations affecting exon 8, 9, or 11; and 25% have no detectable *KIT* mutations (*KIT* wild-type).[32]

Despite the increasing knowledge about mastocytosis in different age groups, few studies have focused on the characteristics of cutaneous lesions. However, as detailed below, clinical experience indicates that skin lesions in most adult patients are small sized and monomorphic, whereas children often present with large polymorphic lesions.[9-11,18,33]

CLINICAL PRESENTATION OF CUTANEOUS INVOLVEMENT IN PATIENTS WITH MASTOCYTOSIS

Adulthood-onset mastocytosis

Most patients with adulthood-onset disease and cutaneous involvement present with the characteristic small, round, brown or red monomorphic lesions (Fig 2). In previous classifications this form of CM has been termed urticaria pigmentosa.[13,14,46-49] Because urticaria is defined today by transient wheals[50] and the lesions in patients with mastocytosis are stable rather than transient, the European Union–US consensus group proposed using the more descriptive term MPCM in 2001 and 2007.[4,11,17] Numbers of lesions vary greatly among patients, ranging from fewer than 10 lesions to almost universal coverage, and numbers might correlate with the extent of systemic involvement, as well as with the serum tryptase level.[33] Lesions often start to develop on the thigh (Fig 2, *A*), axilla, or lower trunk and then, over several years, spread to the upper trunk, distal extremities and lateral neck (Fig 2, *B-E*). Facial skin is typically spared. Most adult patients develop mastocytosis between 20 to 35 years of age; however, later onset is also observed. In some cases the first lesions even appear after the age of 65 to 70 years.[30,31]

In a majority of adult patients with maculopapular lesions, mast cell infiltrates are also found in the bone marrow, corresponding to the final diagnosis of SM (most frequently ISM).[29] Rarely, adult patients with maculopapular lesions do not show systemic involvement and thus represent cases with true MPCM.[29] The clinical characteristics of these adults with CM are similar to those found in patients with ISM. The percentage of patients with true CM varies between different centers and might also depend on the sensitivity of the diagnostic procedures applied to detect SM criteria. The maculopapular skin lesions found in patients with ISM and those with CM also occur in patients with advanced SM, namely SM with an associated clonal hematologic non–mast cell lineage disease or aggressive SM. In these categories the lesions tend to show confluence and might regress as the disease progresses (Fig 2, *F*).[13] However, regression of skin lesions can also occur in adults with nonadvanced mastocytosis categories.[51] Together, the task force estimated that around 95% of patients with ISM exhibit maculopapular skin lesions compared with around 50% of patients with advanced SM. Among patients with mast cell leukemia, less than 50% present with skin lesions.[52]

Some adult patients also have telangiectatic or fixed red macular lesions, particularly on the chest, shoulders, neck, and

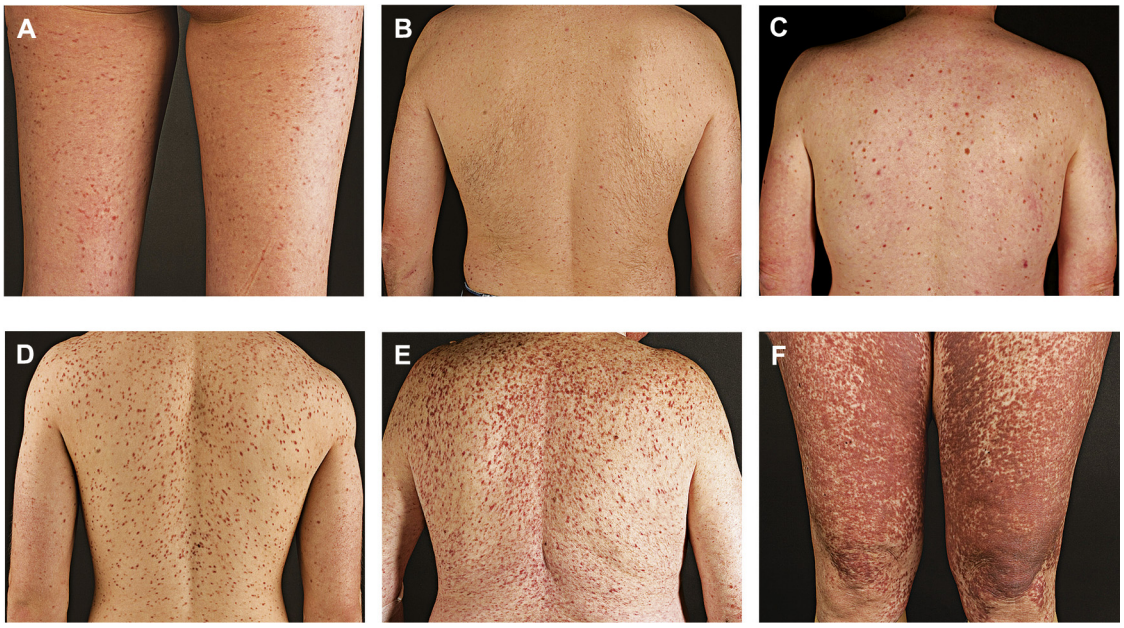

FIG 2. MPCM in patients with adulthood-onset mastocytosis. **A,** Characteristic small brown monomorphic lesions often start to develop on the thigh. **B-E,** Lesions spread over several years to the trunk and extremities. **F,** Confluence of lesions might be associated with advanced SM categories.

FIG 3. Darier's sign. **A-C,** A wheal-and-flare reaction develops upon stroking of a CM lesion with a tongue spatula. Darier's sign is a highly specific diagnostic feature of CM.

upper back. These patients usually also have maculopapular lesions at other body sites.[53] Therefore the task force is of the opinion that the presence of telangiectasias should not form the basis of a separate variant of CM. Accordingly, telangiectasia macularis eruptiva perstans, which has been proposed as a separate variant of CM in previous classifications, should no longer be diagnosed.[14,54,55]

Rarely, adult patients present with larger, polymorphic, and sometimes also elevated skin lesions. This subform usually has its onset during childhood, might be associated with *KIT* mutations other than *KIT* D816V, and might show histologic features of well-differentiated SM, including a mature morphology of mast cells, aberrant expression of CD30, low or absent expression of CD25, increased flow cytometric light scatter features, and overexpression of cytoplasmic carboxypeptidase.[56-61]

Apart from MPCM, adult patients also present rarely with DCM. This subform of CM is usually detected in early childhood and can be related to *KIT* mutations in exons 8 or 9.[27,62] DCM can also be associated with familial mastocytosis caused by germline mutations in *KIT*.[62-64]

In contrast to MPCM and DCM, mastocytomas are almost never observed in adults.

Darier's sign is an important clinical feature of CM (Figs 3 and Fig 4, *B*).[8,65] It is elicited by stroking a CM lesion around 5 times by using moderate pressure with a tongue spatula. Within a few minutes, a wheal-and-flare reaction of the lesion (not or hardly seen in the surrounding skin) will develop. Thus Darier's sign differs from dermographism, which also affects nonlesional skin. The task force points out that a clearly positive Darier's sign is an important diagnostic finding in patients with mastocytosis. It is not always positive in adult patients but usually positive in pediatric patients. In this regard it is noteworthy that antihistamines can decrease the wheal-and-flare reaction. The Darier's sign is often not elicited correctly, resulting in false-negative or false-positive results.

Childhood-onset mastocytosis

Skin lesions in patients with childhood-onset mastocytosis are more heterogeneous than those in adults. All 3 subforms of CM,

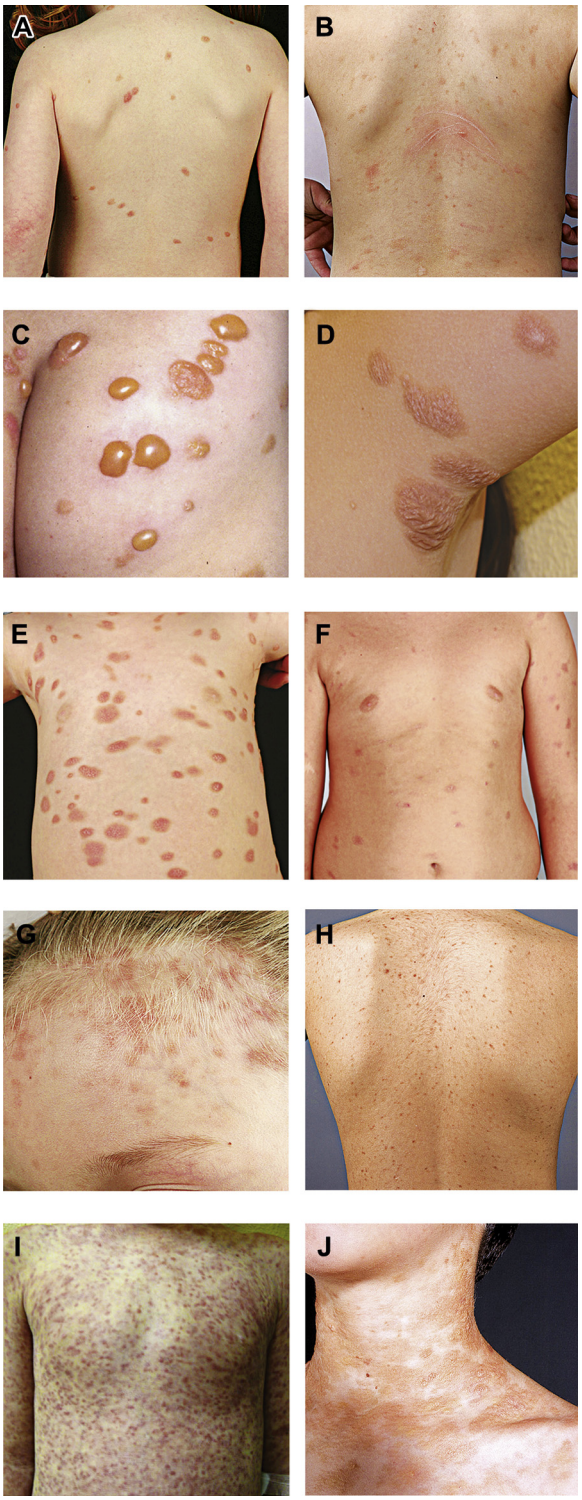

FIG 4. MPCM in patients with childhood-onset mastocytosis. **A-G,** Most children have characteristic large brown lesions of different sizes (polymorphic). Lesion margins can be sharp (Fig 4, *A* and *E*) or indistinct (Fig 4, *B* and *G*) and elevated (Fig 4, *C* and *E*) or flat (Fig 4, *B* and *F*). Nodular lesions present during infancy (Fig 4, *C* and *E*) may develop into plaques or macules at the age of 5 to 10 years (Fig 4, *D* and *F*) before they regress by adolescence. **G,** Lesions on the forehead are characteristic for polymorphic MPCM. **H** and **I,** Few pediatric patients show small monomorphic lesions like the ones observed in adults. **J,** Atypical variants can also occur in children, such as one with yellow firm lesions, which was previously also termed xanthelasmoid CM.

including MPCM, DCM, and mastocytomas, can be observed. Onset is usually within the first 6 months of life. In some patients CM is already present at birth.

Among patients with MPCM, at least 2 variants should be differentiated (Fig 4). Most children display a variant with brown or red and often oval lesions of different sizes (Fig 4, *A-G*).[20,21] The majority of lesions are clearly larger than those found in patients with adulthood-onset mastocytosis.[11,18,33] The lesional margins can be sharp (Fig 4, *A* and *E*) or indistinct (Fig 4, *B* and *G*), and the lesions can be elevated (Fig 4, *C* and *E*) or flat (Fig 4, *B* and *F*). Some of the lesions are plaques or nodules but not papules or macules (Fig 4, *C* and *E*). Therefore these types have also been termed "plaque" or "nodular" in the past.[9-11] However, it should be noted that although children usually show largely homogeneous lesions of a certain type at a given time, the type can vary during the course of the disease. For example, nodules present during infancy (Fig 4, *C* and *E*) may transform into plaques at the age of around 5 to 10 years and into macules after the age of 10 years (Fig 4, *D* and *F*) before the lesions finally regress around puberty in many (but not all) patients. In a few patients nodules do not regress completely but flatten with time and remain as atrophic lesions with wrinkles similar to anetoderma (Fig 4, *D*). Very rarely, nodules can also persist into adulthood. As mentioned above, older patients with these nodular forms can present with characteristics of well-differentiated systemic mastocytosis, such as aberrant expression of CD30, absent expression of CD25 and increased light scatter features, and lack of the *KIT* D816V mutation.[56-61] In contrast to the small maculopapular lesions in adults, the distribution of the polymorphic variant in children is usually asymmetric and generalized at diagnosis, typically involving the head, neck, and extremities. A characteristic feature is the presence of brown lesions on the lateral parts of the forehead (Fig 4, *G*). Lesions on the head often exhibit a particularly prominent Darier's sign. As in other variants of CM in pediatric patients, the polymorphic skin lesions can undergo blistering upon irritation until the patient is 2 to 3 years of age (Fig 4, *C*). Again, lesions on the head are particularly prone to blistering. It is usually considered that the vast majority of children with these polymorphic lesions have pure CM, although systemic involvement has not been systematically ruled out in these patients. Accordingly, serum tryptase levels are usually within the normal range.[18] Sometimes, in children with pronounced cutaneous lesions, tryptase levels are increased at diagnosis but usually decrease within 1 to 2 years.[36] Overall, as mentioned above, prognosis is favorable, with most patients showing spontaneous regression by adolescence.[18,22,34,36] However, in some patients disease persists into adulthood, with the precise frequency remaining to be determined.

A small percentage of pediatric patients exhibit small monomorphic round lesions like the ones observed in adults (Fig 4, *H* and *I*). These children can present with increased serum tryptase levels that do not decrease over time.[18,20] Moreover, these patients might have systemic involvement in other organs. Usually, mastocytosis then persists into adulthood and represents SM, thereby clearly contrasting with the clinical outcome in patients with the polymorphic MPCM variant.[18]

There are also atypical rare variants that do not fit into either the polymorphic or monomorphic types of maculopapular lesions, such as a variant with yellow firm lesions previously termed xanthelasmoid CM (Fig 4, *J*).[66,67] Review of selected cases

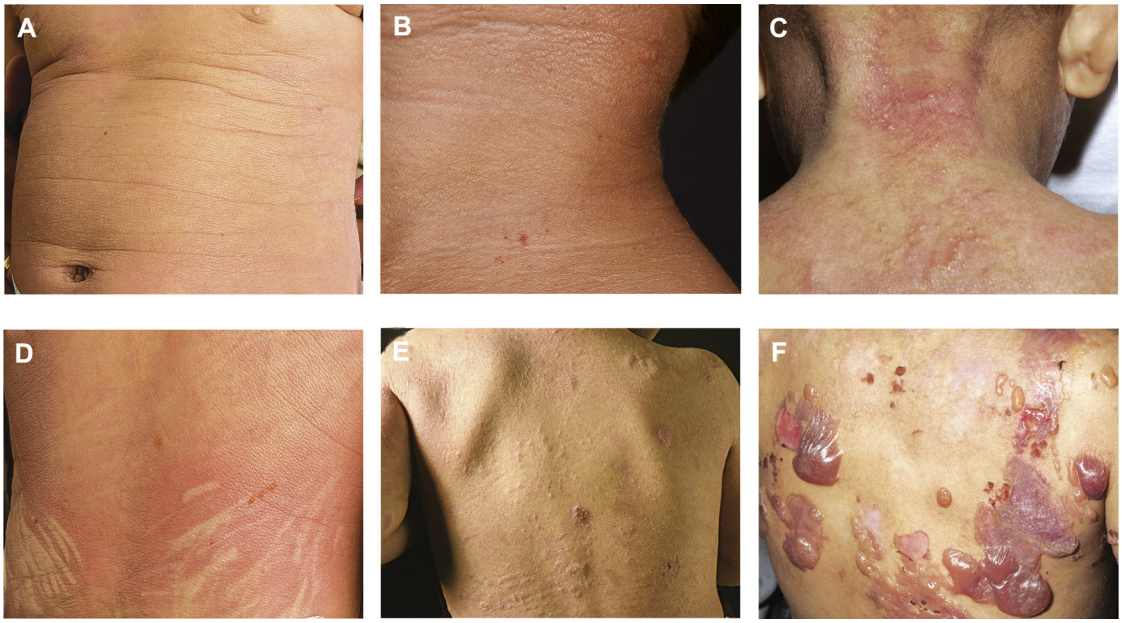

FIG 5. DCM. **A,** DCM is characterized by erythema and generalized thickened skin. **B** and **C,** Papules can be associated with DCM. **D,** Pronounced dermographism is characteristic for DCM. **E** and **F,** Infants with DCM often present initially with large blisters. Fig 5, *C* and *F*, are courtesy of the National Institutes of Health/National Institute of Allergy and Infectious Diseases.

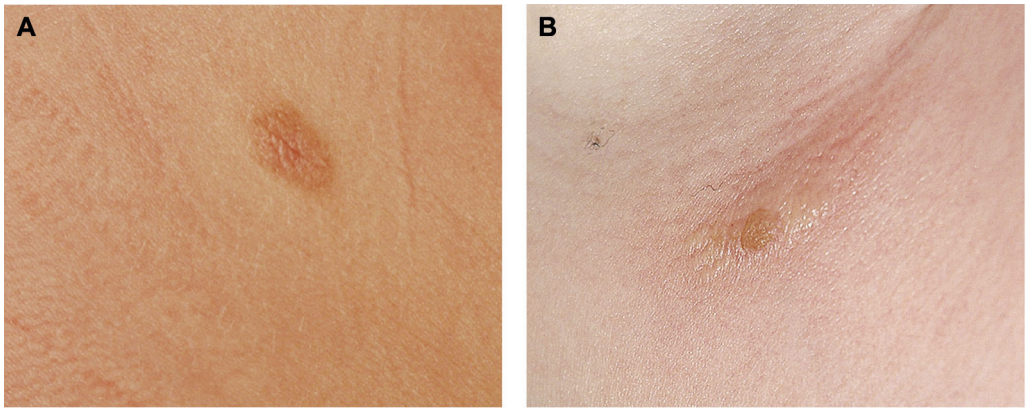

FIG 6. Mastocytoma. **A,** Mastocytoma typically presents as a brown or red nodular lesion. **B,** Blistering can be associated with mastocytoma.

reveals that these variants often show normal tryptase levels and a favorable clinical course, with skin lesions resolving by the time of late adolescence (14-16 years of age).[18]

Children with DCM do not present with individualized lesions but rather exhibit generalized erythema, usually with pachydermia (thickened skin, Fig 5).[43,68,69] Their skin color usually appears darker than normal skin. Papules can be associated with particularly pachydermatous skin areas (Fig 5, *A-C*). In most cases a pronounced and persistent dermographism is seen after minimal mechanical irritation (Fig 5, *D*). DCM might initially present with large blisters, which can be elicited by rubbing or scratching and also can be triggered by viral infections or teething (Fig 5, *E* and *F*). The tendency to blister usually improves within 3 to 4 years. Some patients with DCM show prolonged bleeding from skin wounds, probably because of local release of heparin. Serum tryptase levels are usually increased at presentation, although most patients do not have systemic organ involvement. Similar to the polymorphic variant of MPCM, cutaneous lesions often resolve in patients with DCM by adolescence. As noted above, some patients belong to families in which mastocytosis is inherited in an autosomal dominant pattern.[18,62-64] These patients typically have persistently increased tryptase levels, mast cell infiltrates in extracutaneous organs, and a chronic course. It should be noted that the term DCM refers only to patients with generalized thickened and dark skin but not to those with extensive and sometimes even confluent MPCM.

Another subform of CM in children is mastocytoma (Figs 3, *B* and *C*, and 6). Usually, mastocytoma presents as a single elevated brown or yellow lesion. At initial diagnosis, blistering over the lesion can be observed. A few of these children might also present with more than 1 lesion. Upon stroking the lesion, flushing with sudden reddening of the skin and sweating may occur

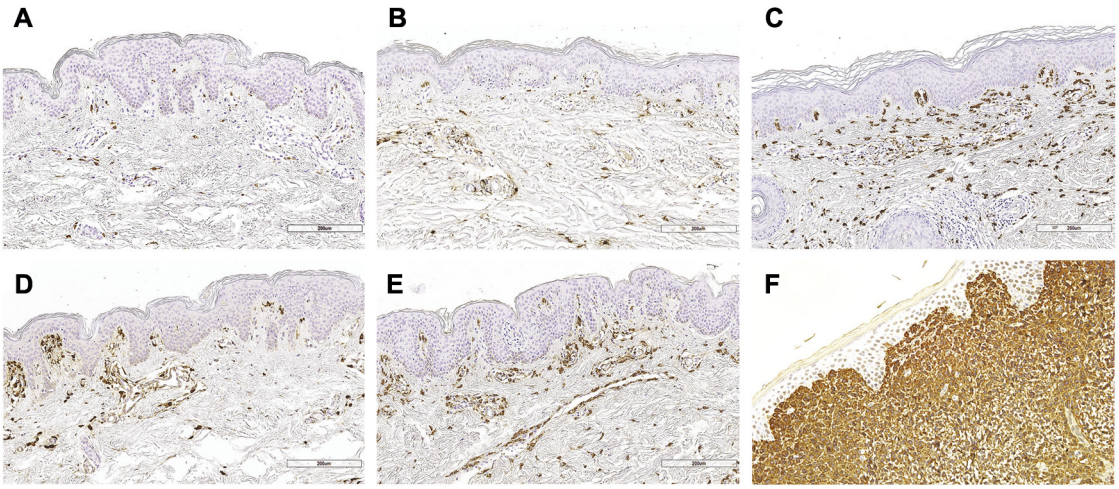

FIG 7. Histologic features of CM. Compared with healthy skin **(A)**, dermal mast cell numbers are increased in skin from patients with CM **(B-F)** and are shown here stained with tryptase antibody. Mast cell numbers vary greatly from patient to patient. Monomorphic adulthood-onset MPCM (Fig 7, *B* and *C*) is typically associated with a less pronounced increase in mast cell numbers compared with those in patients with polymorphic childhood-onset MPCM (Fig 7, *D* and *E*). Mast cell numbers are particularly increased in patients with DCM. Fig 7, *F*, is courtesy of M. Mollejo Villanueva, Toledo, Spain.

Subforms	Variants	Typical manifestations
Maculopapular cutaneous mastocytosis (syn. urticaria pigmentosa)	Monomorphic	
	Polymorphic	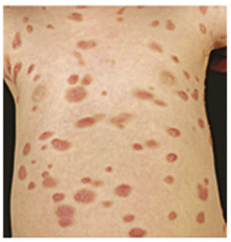
Diffuse cutaneous mastocytosis		
Cutaneous mastocytoma		

FIG 8. Refined classification of cutaneous involvement in patients with mastocytosis.

(Fig 3, *B*). Serum tryptase levels are generally normal, and no systemic involvement is found. Mastocytomas usually do not persist into adulthood.[70]

The task force is aware of the fact that delineation between subsets of cutaneous involvement in children is not always clear-cut. Overlaps can be found, especially between extensive variants of polymorphic MPCM and DCM, as well as between nodular variants of polymorphic MPCM and mastocytoma when more than 1 mastocytoma lesion is present.

Darier's sign is nearly always positive in pediatric patients (Figs 3 and 4, *B*). In young children with mastocytoma or the nodular variant of polymorphic MPCM, however, elicitation of the Darier's sign can provoke flushing and systemic hypotension. In such patients it is recommended not to test for the presence of the Darier's sign or to elicit it very gently.

HISTOLOGIC AND IMMUNOHISTOCHEMICAL FINDINGS IN PATIENTS WITH CM

On average, numbers of mast cells are increased 4- to 8-fold in the lesional dermis of patients with CM (Fig 7) compared with those in skin from healthy subjects (around 40 mast cells/mm^2; Fig 7, *A*) and about 2- to 3-fold compared with those in skin of patients with inflammatory cutaneous diseases.[11,17,71-75] However, in patients with mastocytosis, the number of dermal mast cells varies from patient to patient, and there is even an overlap between mastocytosis and healthy skin.[75,76] To date, it is not known whether the mast cell counts in lesional skin differ between patients with specific subforms of CM. However, numbers of mast cells are generally high in patients with DCM (Fig 7, *F*) and mastocytomas.[11] The personal experience of the authors suggests that the pediatric polymorphic variant of MPCM shows higher mast cell numbers (Fig 7, *D* and *E*) than the monomorphic variant (Fig 7, *B* and *C*).[77] One should also keep in mind that mast cell numbers in healthy skin vary depending on the anatomic site investigated; for example, the face contains more mast cells than the trunk, and superficial dermal layers exhibit more mast cells than deeper layers.[76]

The task force reviewed different staining methods used to detect and enumerate mast cells. The group recommends the use of an antibody against tryptase as the standard immunohistochemical marker to detect and quantify mast cells in skin sections.[17] An experienced dermatopathologist can also recognize normal mast cells in Giemsa- or toluidine blue–stained sections, but hypogranulated mast cells can be missed by using histochemical staining and are more readily detected by immunohistochemistry using an anti-tryptase antibody.

At present, little is known about specific patterns of dermal mast cell infiltrates and their possible correlation with subforms of CM and other clinical characteristics.[11] Mast cells in lesional skin can be spindle shaped or round. Mast cells in skin lesions of patients with the monomorphic MPCM variant tend to be spindle shaped, whereas mast cells in polymorphic lesions tend to be spherical (round).

In contrast to mast cells in bone marrow infiltrates in patients with SM, no specific, aberrantly expressed marker of clonal cutaneous mast cells has been described to date. In particular, staining of cutaneous mast cells for CD25 often yields a negative result.[29,78-80] Mast cells in skin lesions can also stain negatively for CD25 or CD2 in patients with SM, in whom bone marrow mast cells display CD25 or CD2. Other markers used to detect neoplastic mast cells in extracutaneous organs in patients with SM, such as CD30, have not been explored systematically in cutaneous lesions.

TABLE II. Refined criteria for cutaneous involvement in patients with mastocytosis

Major criterion
Typical skin lesions of mastocytosis associated with Darier's sign
Minor criteria
Increased numbers of mast cells in biopsy sections of lesional skin
(Activating) *KIT* mutation in lesional skin tissue

PROPOSED VARIANTS OF CUTANEOUS INVOLVEMENT IN PATIENTS WITH MASTOCYTOSIS

The current classification of CM with its 3 subforms, MPCM (urticaria pigmentosa), DCM, and mastocytoma, remains valid and should be used in practice (Fig 8). However, the task force proposes a few refinements within this classification. First, there is agreement to subdivide maculopapular skin lesions into 2 variants, namely (1) the monomorphic variant with small maculopapular lesions, which is typically seen in (most) adult patients but also in a subgroup of children, and (2) the polymorphic variant with larger asymmetric lesions that can be macular, plaque type, or nodular, which is typically observed in pediatric patients. The terms monomorphic and polymorphic are designed to refer to the variability of skin lesions in a given patient, with monomorphic describing that all lesions are similar in shape, color, and size and polymorphic describing that a patient has lesions with different shapes, colors, or sizes. Moreover, the task force recommends eliminating the telangiectatic variant (telangiectasia macularis eruptiva perstans).

The group also discussed that the term MPCM does not cover all patients in this category in an optimal manner. For example, pediatric patients with nodular lesions are not accurately described by the term maculopapular (Fig 4, *E*). For the time being, however, the concept and terminology of MPCM should be maintained.

Also, the group proposes that the adjunct solitary be removed from the term solitary mastocytoma (Fig 8). This recommendation is based on the fact that some patients with mastocytoma can present with more than 1 lesion but still do not show a disseminated form compatible with MPCM. The group discussed whether there is a maximal number of lesions by which mastocytoma is defined. Although there are no published data to fully support the current proposal and it needs to be prospectively validated, based on clinical experience, the group recommends that a maximum of 3 lesions should still qualify as mastocytoma, provided that the lesions are typical for mastocytoma and distinguishable from typical cases of MPCM. In patients with 4 or more lesions, the diagnosis remains MPCM. Mastocytoma should be termed cutaneous mastocytoma instead of mastocytoma of the skin to comply with the other subforms of CM. Thus the group recommends that the previous term solitary mastocytoma of the skin be changed to cutaneous mastocytoma.

CRITERIA OF CUTANEOUS INVOLVEMENT IN PATIENTS WITH MASTOCYTOSIS

The presence of macroscopically visible typical skin lesions remains the major criterion for cutaneous involvement in patients with mastocytosis (Table II). The task force recommends adding Darier's sign to this criterion.[8,65] Darier's sign, which is applied to the evaluation of fixed cutaneous lesions, as described above, is specific for mastocytosis, and its elicitation is easy and noninvasive. As mentioned, Darier's sign is positive in almost all children and most adults with CM lesions. However, pediatric patients with mastocytoma or nodular lesions can develop a systemic reaction, including hypotension, during testing for Darier's sign. Therefore testing should be avoided or be performed with caution in this group of patients. In all other patients it should be used as the standard method in the diagnostic work-up of mastocytosis.

In addition to the major criterion, 2 minor criteria are usually present, as listed in the consensus paper from 2007.[17] The first criterion is the histologic evidence of increased numbers of mast cells in lesional skin. As detailed above, there is no fixed cutoff at which mast cell counts are increased. Also, some patients with cutaneous lesions show mast cell numbers that are still within the normal range.[75] However, most patients display at least a 4-fold increase of dermal mast cells. Therefore this minor criterion remains valid, although it might sometimes be important to correlate the pathologic findings with clinical manifestations.

In 2007, the second minor criterion was defined as the "presence of a *KIT* mutation in codon 816."[17] Based on recent studies demonstrating that around 40% of pediatric patients express *KIT* mutations in other codons of *KIT*,[26,27,31] the task force recommends changing the wording of this criterion to "(activating) *KIT* mutation in lesional skin tissue." However, it should be noted that only a few laboratories are able to sequence *KIT* from skin tissue at present.

Most adults given a diagnosis of cutaneous involvement upon use of these criteria will also exhibit SM, usually with involvement of bone marrow. Therefore it is recommended to offer all adult patients a complete staging, including a bone marrow biopsy. By contrast, in children presenting with cutaneous lesions of mastocytosis, a final diagnosis of CM can almost always be assumed without performing a bone marrow biopsy.[17]

FUTURE PERSPECTIVES AND UNMET NEEDS

A common language for classifying different forms and variants of cutaneous involvement in patients with CM and those with SM is the basis for future multicenter projects, including patient registries and interventional clinical trials. The refined definitions and adjusted criteria proposed in this document will contribute to this purpose. On the basis of a common terminology, the next objective is to collect large patient groups in registries and to delineate various correlations between specific subforms of CM and other disease parameters, clinical end points, and prognosis. Especially for pediatric patients, it will be important to carefully define prognostic factors to better tailor counseling, follow-up, and treatment. Future studies should also address histologic infiltration patterns, morphologies of mast cells, immunohistochemical and serologic markers, and peripheral blood allele-specific PCR in different subgroups of patients. Furthermore, the relevance of *KIT* mutations should be explored. Finally, genomic profiling and studies of somatic aberrations and polymorphisms should aid in the identification of new mechanisms underlying disease manifestations and progression. These studies will contribute to improved understanding and better management of patients with mastocytosis.

We thank our patients and their families for their cooperation in this study and Friedemann Reinhold and Cornelius Evers from the Photo Department, University Hospital Cologne, Cologne, Germany, for professional photographic images. All coauthors contributed equally to discussions on the definition and criteria of cutaneous manifestations in mastocytosis in joint meetings, in particular at the Annual Meetings of the European Competence Network on Mastocytosis in Stockholm, Sweden (November 2010); Istanbul, Turkey (November 2011); Vienna, Austria (September 2012); London, United Kingdom (September 2013); and Odense, Denmark (September 2014), and the Consensus Conference on Mastocytosis in Boston, Massachusetts (October 2012). In addition, all coauthors provided essential input to this document by drafting parts of the manuscript and approving the final version of the document.

REFERENCES

1. Akin C, Valent P. Diagnostic criteria and classification of mastocytosis in 2014. Immunol Allergy Clin North Am 2014;34:207-18.
2. Valent P. Mastocytosis: a paradigmatic example of a rare disease with complex biology and pathology. Am J Cancer Res 2013;3:159-72.
3. Horny HP, Akin C, Metcalfe DD, Escribano L, Bennett JM, Valent P, et al. Mastocytosis (mast cell disease). In: Swerdlow SH, Campo PE, Harris NL, Jaffe ES, Pileri SA, Stein H, editors. World Health Organization (WHO) classification of tumours pathology and genetics of tumours of the haematopoietic and lymphoid tissues, Vol 2. Lyon (France): IARC Press; 2008. pp. 54-63.
4. Valent P, Horny HP, Li CY, Longley JB, Metcalfe DD, Parwaresch RM, et al. Mastocytosis. In: Jaffe ES, Harris NL, Stein H, Vardiman JW, editors. World Health Organization (WHO) classification of tumours pathology and genetics of tumours of the haematopoietic and lymphoid tissues, Vol 1. Lyon (France): IARC Press; 2001. pp. 291-302.
5. Valent P, Horny HP, Escribano L, Longley BJ, Li CY, Schwartz LB, et al. Diagnostic criteria and classification of mastocytosis: a consensus proposal. Leuk Res 2001;25:603-25.
6. Theoharides TC, Valent P, Akin C. Mast cells, mastocytosis, and related disorders. N Engl J Med 2015;373:163-72.
7. Akin C, Metcalfe DD. Systemic mastocytosis. Annu Rev Med 2004;55:419-32.
8. Galen BT, Rose MG. Darier's sign in mastocytosis. Blood 2014;123:1127.
9. Hartmann K, Henz BM. Cutaneous mastocytosis—clinical heterogeneity. Int Arch Allergy Immunol 2002;127:143-6.
10. Hartmann K, Henz BM. Classification of cutaneous mastocytosis: a modified consensus proposal. Leuk Res 2002;26:485-6.
11. Wolff K, Komar M, Petzelbauer P. Clinical and histopathological aspects of cutaneous mastocytosis. Leuk Res 2001;25:519-28.
12. Hartmann K, Henz BM. Mastocytosis: recent advances in defining the disease. Br J Dermatol 2001;144:682-95.
13. Metcalfe DD. Classification and diagnosis of mastocytosis: current status. J Invest Dermatol 1991;96:2S-4S.
14. Soter NA. The skin in mastocytosis. J Invest Dermatol 1991;96:32S-8S.
15. Sagher F, Even-Paz Z. Incidence of mastocytosis. In: Sagher F, Even-Paz Z, editors. Mastocytosis and the mast cell. New York: Karger; 1967. pp. 14-7.
16. Alvarez-Twose I, Vano-Galvan S, Sanchez-Munoz L, Morgado JM, Matito A, Torrelo A, et al. Increased serum baseline tryptase levels and extensive skin involvement are predictors for the severity of mast cell activation episodes in children with mastocytosis. Allergy 2012;67:813-21.
17. Valent P, Akin C, Escribano L, Fodinger M, Hartmann K, Brockow K, et al. Standards and standardization in mastocytosis: consensus statements on diagnostics, treatment recommendations and response criteria. Eur J Clin Invest 2007;37:435-53.
18. Wiechers T, Rabenhorst A, Schick T, Preussner LM, Förster A, Valent P, et al. Large maculopapular cutaneous lesions are associated with favorable outcome in childhood-onset mastocytosis. J Allergy Clin Immunol 2015 [Epub ahead of print]. http://dx.doi.org/10.1016/j.jaci.2015.05.034.
19. Lange M, Niedoszytko M, Renke J, Glen J, Nedoszytko B. Clinical aspects of paediatric mastocytosis: a review of 101 cases. J Eur Acad Dermatol Venereol 2013;27:97-102.

20. Lange M, Nedoszytko B, Górska A, Zawrocki A, Sobjanek M, Kozlowski D. Mastocytosis in children and adults: clinical disease heterogeneity. Arch Med Sci 2012;8:533-41.
21. Torrelo A, Alvarez-Twose I, Escribano L. Childhood mastocytosis. Curr Opin Pediatr 2012;24:480-6.
22. Uzzaman A, Maric I, Noel P, Kettelhut BV, Metcalfe DD, Carter MC. Pediatric-onset mastocytosis: a long term clinical follow-up and correlation with bone marrow histopathology. Pediatr Blood Cancer 2009;53:629-34.
23. Carter MC, Metcalfe DD. Paediatric mastocytosis. Arch Dis Child 2002;86: 315-9.
24. Hartmann K, Metcalfe DD. Pediatric mastocytosis. Hematol Oncol Clin North Am 2000;14:625-40.
25. Kettelhut BV, Metcalfe DD. Pediatric mastocytosis. Ann Allergy 1994;73: 197-202.
26. Ma D, Stence AA, Bossler AB, Hackman JR, Bellizzi AM. Identification of KIT activating mutations in paediatric solitary mastocytoma. Histopathology 2014;64: 218-25.
27. Bodemer C, Hermine O, Palmerini F, Yang Y, Grandpeix-Guyodo C, Leventhal PS, et al. Pediatric mastocytosis is a clonal disease associated with D816V and other activating c-KIT mutations. J Invest Dermatol 2010;130:804-15.
28. Yang Y, Létard S, Borge L, Chaix A, Hanssens K, Lopez S, et al. Pediatric mastocytosis–associated KIT extracellular domain mutations exhibit different functional and signaling properties compared with KIT-phosphotransferase domain mutations. Blood 2010;116:1114-23.
29. Berezowska S, Flaig MJ, Rueff F, Walz C, Haferlach T, Krokowski M, et al. Adult-onset mastocytosis in the skin is highly suggestive of systemic mastocytosis. Mod Pathol 2014;27:19-29.
30. Lim KH, Tefferi A, Lasho TL, Finke C, Patnaik M, Butterfield JH, et al. Systemic mastocytosis in 342 consecutive adults: survival studies and prognostic factors. Blood 2009;113:5727-36.
31. Lanternier F, Cohen-Akenine A, Palmerini F, Feger F, Yang Y, Zermati Y, et al. Phenotypic and genotypic characteristics of mastocytosis according to the age of onset. PLoS One 2008;3:e1906.
32. Meni C, Bruneau J, Georgin-Lavialle S, Le Sache de Peufeilhoux L, Damaj G, Hadj-Rabia S, et al. Paediatric mastocytosis: a systematic review of 1747 cases. Br J Dermatol 2015;172:642-51.
33. Brockow K, Akin C, Huber M, Metcalfe DD. Assessment of the extent of cutaneous involvement in children and adults with mastocytosis: relationship to symptomatology, tryptase levels, and bone marrow pathology. J Am Acad Dermatol 2003;48:508-16.
34. Ben-Amitai D, Metzker A, Cohen HA. Pediatric cutaneous mastocytosis: a review of 180 patients. Isr Med Assoc J 2005;7:320-2.
35. Caplan RM. The natural course of urticaria pigmentosa. Analysis and follow-up of 112 cases. Arch Dermatol 1963;87:146-57.
36. Carter MC, Clayton ST, Komarow HD, Brittain EH, Scott LM, Cantave D, et al. Assessment of clinical findings, tryptase levels, and bone marrow histopathology in the management of pediatric mastocytosis. J Allergy Clin Immunol 2015 [Epub ahead of print]. http://dx.doi.org/10.1016/j.jaci.2015.04.024.
37. Barnes M, Van L, DeLong L, Lawley LP. Severity of cutaneous findings predict the presence of systemic symptoms in pediatric maculopapular cutaneous mastocytosis. Pediatr Dermatol 2014;31:271-5.
38. Gulen T, Hagglund H, Dahlen B, Nilsson G. High prevalence of anaphylaxis in patients with systemic mastocytosis—a single-centre experience. Clin Exp Allergy 2014;44:121-9.
39. Matito A, Alvarez-Twose I, Morgado JM, Sanchez-Munoz L, Orfao A, Escribano L. Anaphylaxis as a clinical manifestation of clonal mast cell disorders. Curr Allergy Asthma Rep 2014;14:450.
40. Valent P. Risk factors and management of severe life-threatening anaphylaxis in patients with clonal mast cell disorders. Clin Exp Allergy 2014;44:914-20.
41. Brockow K, Jofer C, Behrendt H, Ring J. Anaphylaxis in patients with mastocytosis: a study on history, clinical features and risk factors in 120 patients. Allergy 2008;63:226-32.
42. Gonzalez de Olano D, de la Hoz Caballer B, Nunez Lopez R, Sanchez Munoz L, Cuevas Agustin M, Dieguez MC, et al. Prevalence of allergy and anaphylactic symptoms in 210 adult and pediatric patients with mastocytosis in Spain: a study of the Spanish network on mastocytosis (REMA). Clin Exp Allergy 2007;37: 1547-55.
43. Lange M, Niedoszytko M, Nedoszytko B, Lata J, Trzeciak M, Biernat W. Diffuse cutaneous mastocytosis: analysis of 10 cases and a brief review of the literature. J Eur Acad Dermatol Venereol 2012;26:1565-71.
44. Soucie E, Brenet F, Dubreuil P. Molecular basis of mast cell disease. Mol Immunol 2015;63:55-60.
45. Yanagihori H, Oyama N, Nakamura K, Kaneko F. c-kit mutations in patients with childhood-onset mastocytosis and genotype-phenotype correlation. J Mol Diagn 2005;7:252-7.
46. Travis WD, Li CY, Bergstralh EJ, Yam LT, Swee RG. Systemic mast cell disease. Analysis of 58 cases and literature review. Medicine 1988;67:345-68.
47. Parwaresch MR, Horny HP, Lennert K. Tissue mast cells in health and disease. Pathol Res Pract 1985;179:439-61.
48. Czarnetzki BM, Behrendt H. Urticaria pigmentosa: clinical picture and response to oral disodium cromoglycate. Br J Dermatol 1981;105:563-7.
49. Sangster A. An anomalous mottled rash, accompanied by pruritus, factitious urticaria and pigmentation, “urticaria pigmentosa (?)”. Trans Clin Soc London 1878;11:161-3.
50. Zuberbier T, Aberer W, Asero R, Bindslev-Jensen C, Brzoza Z, Canonica GW, et al. The EAACI/GA(2) LEN/EDF/WAO Guideline for the definition, classification, diagnosis, and management of urticaria: the 2013 revision and update. Allergy 2014;69:868-87.
51. Brockow K, Scott LM, Worobec AS, Kirshenbaum A, Akin C, Huber MM, et al. Regression of urticaria pigmentosa in adult patients with systemic mastocytosis: correlation with clinical patterns of disease. Arch Dermatol 2002;138:785-90.
52. Georgin-Lavialle S, Lhermitte L, Dubreuil P, Chandesris MO, Hermine O, Damaj G. Mast cell leukemia. Blood 2013;121:1285-95.
53. Williams KW, Metcalfe DD, Prussin C, Carter MC, Komarow HD. Telangiectasia macularis eruptiva perstans or highly vascularized urticaria pigmentosa? J Allergy Clin Immunol Pract 2014;2:813-5.
54. Marrouche N, Grattan C. TMEP or not TMEP: that is the question. J Am Acad Dermatol 2014;70:581-2.
55. Soter NA. Mastocytosis and the skin. Hematol Oncol Clin North Am 2000;14: 537-55.
56. Chan EC, Bai Y, Kirshenbaum AS, Fischer ER, Simakova O, Bandara G, et al. Mastocytosis associated with a rare germline KIT K509I mutation displays a well-differentiated mast cell phenotype. J Allergy Clin Immunol 2014;134:178-87.
57. Alvarez-Twose I, Gonzalez P, Morgado JM, Jara-Acevedo M, Sanchez-Munoz L, Matito A, et al. Complete response after imatinib mesylate therapy in a patient with well-differentiated systemic mastocytosis. J Clin Oncol 2012;30:27.
58. Sanchez-Munoz L, Alvarez-Twose I, Garcia-Montero AC, Teodosio C, Jara-Acevedo M, Pedreira CE, et al. Evaluation of the WHO criteria for the classification of patients with mastocytosis. Mod Pathol 2011;24:1157-68.
59. Teodosio C, Garcia-Montero AC, Jara-Acevedo M, Sanchez-Munoz L, Alvarez-Twose I, Nunez R, et al. Mast cells from different molecular and prognostic subtypes of systemic mastocytosis display distinct immunophenotypes. J Allergy Clin Immunol 2010;125:719-26.
60. Akin C, Escribano L, Nuñez R, Garcia-Montero A, Angulo M, Orfao A, et al. Well-differentiated systemic mastocytosis: a new disease variant with mature mast cell phenotype and lack of codon 816 c-Kit mutations. J Allergy Clin Immunol 2004;113(suppl):S327.
61. Alvarez-Twose I, Jara-Acevedo M, Morgado JM, Garcia-Montero A, Sanchez-Munoz L, Teodosio C, et al. Clinical, immunophenotypic, and molecular characteristics of well-differentiated systemic mastocytosis. J Allergy Clin Immunol 2015 [Epub ahead of print]. http://dx.doi.org/10.1016/j.jaci.2015.05.008.
62. Hartmann K, Wardelmann E, Ma Y, Merkelbach–Bruse S, Preussner LM, Woolery C, et al. Novel germline mutation of KIT associated with familial gastrointestinal stromal tumors and mastocytosis. Gastroenterology 2005;129: 1042-6.
63. Wang HJ, Lin ZM, Zhang J, Yin JH, Yang Y. A new germline mutation in KIT associated with diffuse cutaneous mastocytosis in a Chinese family. Clin Exp Dermatol 2014;39:146-9.
64. Tang X, Boxer M, Drummond A, Ogston P, Hodgins M, Burden AD. A germline mutation in KIT in familial diffuse cutaneous mastocytosis. J Med Genet 2004; 41:e88.
65. Skrabs CC. Darier sign: a historical note. Arch Dermatol 2002;138:1253-4.
66. Husak R, Blume-Peytavi U, Pfrommer C, Geilen CC, Goerdt S, Orfanos CE. Nodular and bullous cutaneous mastocytosis of the xanthelasmoid type: case report. Br J Dermatol 2001;144:355-8.
67. Revert A, Jorda E, Ramon D, Verdeguer JM, Torres V, Pitarch A. Xanthelasmoid mastocytosis. Pediatr Dermatol 1991;8:152-4.
68. Neri I, Virdi A, Balestri R, Patrizi A. Diffuse cutaneous mastocytosis: a heterogeneous disease. Arch Dis Child 2013;98:607.
69. Wawrzycki B, Pietrzak A, Chodorowska G, Kanitakis J. Diffuse cutaneous bullous mastocytosis in a newborn. Dermatol Ther 2013;26:176-9.
70. Webber NK, Ponnampalam J, Grattan CE. How reliable is blood tryptase as a marker of systemic disease in an infant with cutaneous mastocytomas? Clin Exp Dermatol 2008;33:198-9.

71. Rabenhorst A, Schlaak M, Heukamp LC, Förster A, Theurich S, von Bergwelt-Baildon M, et al. Mast cells play a protumorigenic role in primary cutaneous lymphoma. Blood 2012;120:2042-54.
72. Ribatti D, Nico B, Finato N, Crivellato E, Beltrami CA. Co-localization of tryptase and cathepsin-G in mast cells in cutaneous mastocytosis. Cancer Lett 2009;279:209-12.
73. Brockow K, Akin C, Huber M, Scott LM, Schwartz LB, Metcalfe DD. Levels of mast-cell growth factors in plasma and in suction skin blister fluid in adults with mastocytosis: correlation with dermal mast-cell numbers and mast-cell tryptase. J Allergy Clin Immunol 2002;109:82-8.
74. Irani AA, Garriga MM, Metcalfe DD, Schwartz LB. Mast cells in cutaneous mastocytosis: accumulation of the MCTC type. Clin Exp Allergy 1990;20:53-8.
75. Garriga MM, Friedman MM, Metcalfe DD. A survey of the number and distribution of mast cells in the skin of patients with mast cell disorders. J Allergy Clin Immunol 1988;82:425-32.
76. Weber A, Knop J, Maurer M. Pattern analysis of human cutaneous mast cell populations by total body surface mapping. Br J Dermatol 2003;148:224-8.
77. Büttner C, Grabbe J, Haas N, Sepp NT, Kunkel G, Henz BM. Comparison of genetic and immunohistochemical findings in childhood and adult onset urticaria pigmentosa. Int Arch Allergy Immunol 1999;118:206-7.
78. Morgado JM, Sanchez Munoz L, Matito A, Mollejo M, Escribano L, Alvarez Twose I. Patterns of expression of CD25 and CD30 on skin mast cells in pediatric mastocytosis. J Contemp Immunol 2014;1:44-56.
79. Lange M, Zawrocki A, Nedoszytko B, Wasag B, Niedoszytko M, Jassem E, et al. Does the aberrant expression of CD2 and CD25 by skin mast cells truly correlate with systemic involvement in patients presenting with mastocytosis in the skin? Int Arch Allergy Immunol 2014;165:104-10.
80. Hollmann TJ, Brenn T, Hornick JL. CD25 expression on cutaneous mast cells from adult patients presenting with urticaria pigmentosa is predictive of systemic mastocytosis. Am J Surg Pathol 2008;32:139-45.