Clin Exp Allergy 2005; **35**:146–152 doi:10.1111/j.1365-2222.2005.02137.x

Airway remodelling and inflammation in sheep lungs after chronic airway challenge with house dust mite

K. J. Snibson*, R. J. Bischof*, R. F. Slocombe† and E. N. Meeusen*

*Centre for Animal Biotechnology and †Faculty of Veterinary Science, The University of Melbourne, Parkville, Vic., Australia

Summary

Background Remodelling of airway walls is a significant morbidity factor in patients suffering from chronic asthma. The relationship between airway remodelling and the inflammatory response is not well defined. Sheep have been used extensively to model airway disease in humans and represent a suitable model to examine airway remodelling.

Objective The aim of the present study was to develop a model for airway remodelling in sheep after repeated challenge with a relevant human allergen to assess the relationship of airway remodelling with inflammation.

Methods Repeated challenges of house dust mite (HDM) extract or saline (control) were administered to local lung segments of sheep for a period of 6 months. After the last challenge, lung tissues from both challenged and unchallenged lung compartments of the same sheep were compared using morphometric image analysis and (immuno) histological studies.

Results All HDM-challenged sheep developed significant bronchoalveolar lavage eosinophilia during challenge. At the end of the challenge period, significant increases in airway collagen and airway smooth muscle content were found in a proportion (3/7) of the HDM-challenged sheep. Hyperplasia of goblet cells and epithelial cells were observed in small bronchi and bronchioles exposed to allergen. Irrespective of airway remodelling changes, all HDM-challenged, but no saline-challenged sheep, displayed significant increases in mast cells in alveolar septa and airway walls of challenged lungs compared with untreated lung compartments of the same sheep. Significant increases were also observed in CD5 and γδ T cell subpopulations in all allergen-exposed lung parenchyma.

Conclusion A proportion of atopic sheep develop typical airway remodelling changes after chronic allergen challenge, which is not directly related to the level of allergic inflammation.

Keywords airway smooth muscle, collagen, eosinophils, mast cells, remodelling

Submitted 17 October 2003; revised 7 July 2004; accepted 29 September 2004

Introduction

It is now generally accepted that long-term structural and functional changes to lung tissues (airway remodelling) in patients suffering from chronic asthma leads to significant increases in morbidity. The concept of airway remodelling has gained widespread recognition after the publication of several key long-term clinical studies showing an accelerated and irreversible decline in lung function in asthmatics compared with non-asthmatics [1–4]. A number of pathologic features of remodelling may account for the irreversible nature of the disease, and include: thickening of the lamina reticularis via the deposition of collagen, tenascin and fibronectin; abnormal mesenchymal–epithelial interactions; airway smooth muscle (ASM) hypertrophy and hyperplasia; and angiogenesis in the airway wall.

Correspondence: Dr Kenneth J. Snibson, Centre for Animal Biotechnology, School of Veterinary Science, The University of Melbourne, Parkville, Vic. 3010, Australia. E-mail: ksnibson@unimelb.edu.au

The mechanisms and factors that confer these changes in lung tissue architecture of asthmatics are likely to be complex. It has been traditionally thought that remodelling of the airways is a secondary consequence of persistent inflammation; however, the precise nature of this relationship has been recently questioned [5]. It is well established that T-helper type 2 (Th2 type) immune responses are important in initiating the cycle of inflammation and repair underlying the chronic inflammatory processes of asthma. The infiltration of the airways by Th2-type lymphocytes and eosinophils is a predominant feature in the clinical manifestations of the disease. Eosinophils, in particular, have the potential to produce significant tissue damage when activated through the release of oxygen radicals and cationic proteins. They can also contribute to repair mechanisms by releasing growth factors, cytokines and other cellular mediators in injured tissues [6]. The prolonged exposure to these events of repetitive tissue damage and subsequent repair is likely to be a key factor in the mechanism conferring structural changes in the lungs of chronic asthmatics. One impediment

 © 2005 Blackwell Publishing Ltd

in the study of the processes leading to airway remodelling is the lack of suitable experimental animal models that closely resemble the human condition in all aspects of the disease and allow detailed examination of factors leading up to airway remodelling. We have recently shown that sheep showing high titres of house dust mite (HDM)-specific IgE in serum after immunization with HDM respond to lung HDM infusion with significant eosinophil infiltration into bronchoalveolar lavage (BAL) fluid and lung tissues [7, 8]. In the current study, we have extended the sheep model to investigate the effects of repeated challenges of HDM on airway inflammation and its association with the induction of airway wall remodelling.

Materials and methods

Chronic lung challenges

Four to 5-month-old female Merino-cross lambs used in these studies were immunized with HDM extract (*Dermatophagoides pteronyssinus*; CSL, Melbourne, Australia) [8]. Seven sheep with high HDM-specific serum IgE levels (atopic sheep) were selected for further lung challenges.

Segmental allergen challenges with solubilized HDM (5 mL of 200 μg HDM/mL saline) were delivered deep into the left caudal lung lobe using a flexible fibre-optic endoscope. The right caudal lobe of the lung of the same sheep was used as an untreated internal control. Challenges were conducted twice-weekly for the first 3 months and then once weekly for the final 3 months (6 months total). Three separate sheep were treated in the same manner, except that they were immunized with saline in adjuvant, and repeatedly challenged with saline (saline control sheep). BAL cells were collected from sheep on a designated post-challenge day throughout the repeated challenge regime. Specifically, on week 6 (day 1), week 9 (day 2), week 24 (day 3), week 4 (day 4), week 9 (day 5), week 7 (day 6) and week 26 (day 7), 10 mL of saline was introduced into challenged lung segments using a fibre-optic endoscope. The recovered BAL cells were counted, centrifuged, dried onto a microscope slide as a cytospot and then differentially stained with Wright's Geisma stain (Sigma, Castle Hill, NSW, Australia) as described [8].

All experimental animal procedures and the collection of cells/tissues were approved by the Animal Experimentation Ethics Committee of the University of Melbourne.

Lung tissue fixation, histology and immunohistochemistry

Eight to 9 days after the final challenge, sheep were killed by a mild intravenous barbiturate overdose. To preserve morphological integrity, the lungs from a number of sheep were subjected to inflation fixation. Inflated lungs (25 cm H_2O internal pressure) were fixed in 10% formalin in 1.9 times normal strength phosphate-buffered saline (PBS) for 24 h. From each lung region, a number of 4 μm-thick histological sections were cut in series and stained with either haematoxylin and eosin (H&E), Masson's trichrome, Alcian blue/PAS or toluidine blue.

Tissues for immunohistochemistry and histology were processed from lung compartments from the remaining repeatedly challenged sheep [8, 9]. Mast cells were identified on frozen sections by staining with 1% toluidine blue in 50% methanol. Eosinophils were identified on frozen sections by incubation with 0.6% diamino benzidine tetrahydrochloride (Sigma) and 0.01% H_2O_2 to detect endogenous peroxidase. Immunohistochemistry was performed using the indirect immunoperoxidase technique with monoclonal antibodies against sheep cell surface molecules [8, 9]. For cell counts, either 200 immunoperoxidase positive cells were counted in a maximum of 20 microscope fields (× 400 magnification) using an area-calibrated grid, or a minimum of 20 microscope fields were counted for less frequent cell types. A separate sheep was used to assess eosinophil localization in the airways after the first exposure to HDM. Lung tissues from this sheep were removed 48 h after a single HDM challenge, fixed in formalin and stained with H&E [8].

Morphometric analysis

Digital image analyses were performed on histological sections using Image-Pro Plus software (Media Cybernetics version 4.1.0.0). Airway wall measurements were based on previously defined nomenclature [10]. Airway size was assessed by the measurement of basement membrane perimeter of airways cut in cross-section, similar to that performed by others [11–13]. Total airway wall area was determined by a digital calculation of the area enclosed by the basement membrane and the surrounding adventitia. Collagen and smooth muscle area contents of the airway wall were determined by digital colour analysis of Masson's trichrome-stained histological sections. For each airway wall, the area of collagen was calculated from the non-cellular proportion of the airway wall that was stained blue. Similarly, smooth muscle areas were digitally calculated from histologically identified smooth muscle that stained red. For each lung compartment, image data were averaged from a total of three sections, each taken from a separate paraffin block. In each set of three sections, measurements were taken from all available bronchioles and small bronchi, ranging from 200 to 2000 μm in diameter (calculated on basement membrane perimeter), which were cut in transverse section and free of branching. All measurements were standardized to airway basement membrane length to adjust for airway size [10].

Statistical analyses

Challenged and unchallenged, control lung regions in the same sheep were statistically analysed for significant differences ($P<0.05$) using two-tailed paired Student's *t*-tests. For morphometric analyses of smooth muscle and collagen content in the airway wall, average area measurements from the challenge lobe were statistically compared with data obtained from the untreated lobe in each sheep. For tissue cell counting experiments, data from challenge lobes were averaged from all sheep examined and statistically compared with equivalent data derived from untreated control lobes using a two-sample *t*-test for independent samples.

Results

Granulocyte infiltration into the bronchoalveolar lavage and lung tissues after house dust mite challenge

The percentages of eosinophils and neutrophils present in BAL collected at several time-points after repeated challenge

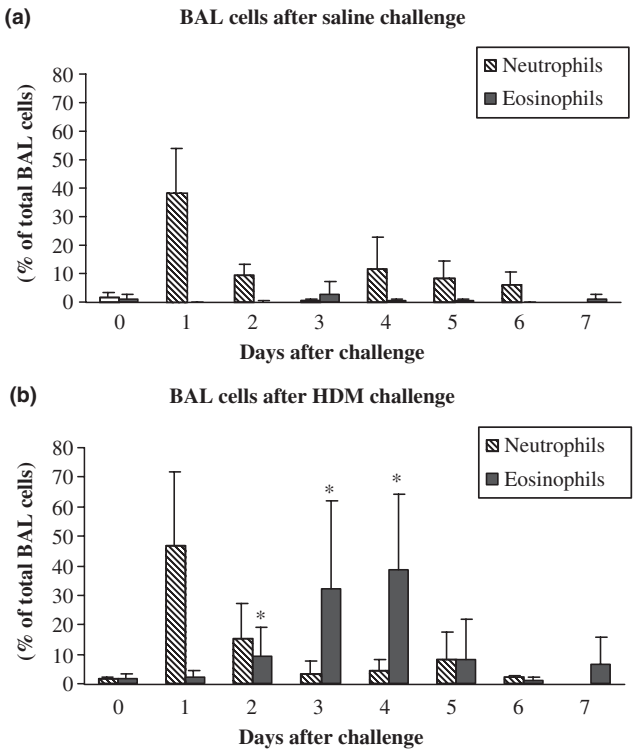

Fig. 1. Relative numbers of eosinophils and neutrophils in the bronchoalveolar lavage (BAL) after a challenge of either saline (a) or house dust mite (HDM) (b). Values for each time-point were averaged from data obtained from five HDM- and four saline-infused sheep at various times after challenge during the 6-month challenge period. An asterisk denotes significant difference between HDM- and saline-challenged sheep ($P<0.05$).

with either saline or HDM are shown in Fig. 1. In both saline- and HDM-challenged sheep, neutrophils were observed in the BAL in increased numbers at the earliest time-point examined (1 day). The percentage of neutrophils infiltrating the BAL fluid peaked at day 1 after challenge and returned to baseline levels by day 3 post-challenge. There was a clear difference between HDM-and saline-challenged sheep with respect to the percentage of eosinophils entering the BAL. In particular, no significant increase in the percentage of BAL eosinophils was observed at any time-point for the saline-challenged sheep (Fig. 1a), whereas all HDM-challenged sheep showed a marked increase in BAL eosinophils at later time-points compared with the early neutrophil infiltration (Fig. 1b). Increased percentages of eosinophils were present in the BAL of HDM sheep at days 2 and 3 post-challenge before returning to baseline levels by day 6. Many BAL eosinophils at days 4 and 5 appeared to have degranulated, as judged by a loss of granularity of the cytoplasm and cytoplasmic vacuolation (not shown).

The localization of eosinophils in lung tissues was determined in a separate sheep by histological analysis of lung lobes 48 h after the first HDM challenge. Most HDM-challenged airways were circumscribed with a mass of infiltrating inflammatory cells that were largely absent from saline-challenged lobes from the same animal (not shown). Eosinophils were a dominant infiltrating cell type in HDM-challenged lobes and were prominently associated with smooth muscle and the lamina propria of bronchi and were

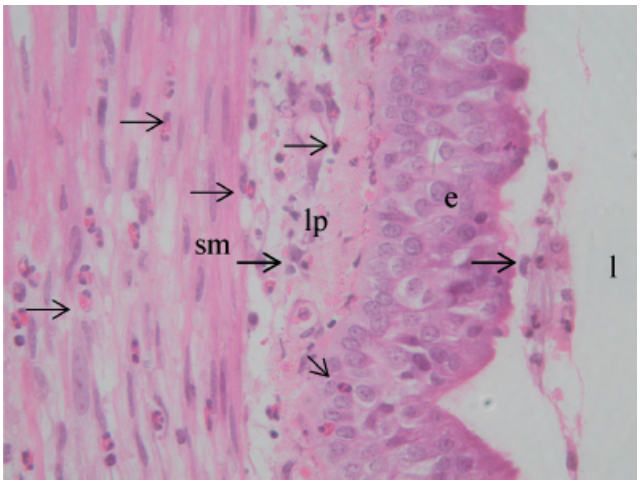

Fig. 2. Location of infiltrating eosinophils in a bronchial airway wall 48 h after the first house dust mite challenge. Arrows, eosinophils; sm, airway smooth muscle; lp, lamina propria; e, epithelium; l, airway lumen. × 200 haematoxylin and eosin.

also evident within the airway epithelium (Fig. 2). Eosinophils were usually intact, although a number of isolated and scattered eosinophilic granules were observed free in the connective tissues of these regions, possibly derived from degranulated eosinophils.

Changes in lung tissues after repeated lung challenges

Histopathology An evaluation of the histopathology of lungs sampled 8–9 days after the 6-month challenge period revealed a marked increase in collagen and smooth muscle in small bronchi and bronchiolar walls in a proportion of the HDM-challenged lung compartments compared with untreated airway walls of the same sheep (Fig. 3). There was also prominent hyperplasia of Alcian blue-stained goblet cells lining the bronchiolar lumen in the HDM-challenged lung compartments (Figs 3b and d), which was absent in similar-sized bronchioles in the untreated right lungs (Figs 3a and c). Epithelial cells lining HDM-challenged bronchioles were columnar rather than cuboidal as in the control side bronchioles. There were no noticeable differences between lung compartments in separate sheep repeatedly challenged with saline (not shown).

Morphometric analysis

A blinded morphometric analysis revealed that five of seven HDM-challenged sheep showed increased airway wall collagen (Masson's trichrome stained) in lung compartments chronically challenged with HDM compared with untreated control compartments in the same animal (Table 1, Fig. 4a). Three of these were statistically significant ($P<0.05$) while no significant increases were observed in any of the saline-challenged control sheep (Fig. 4a).

A similar morphometric analysis of ASM revealed that three of seven HDM-challenged sheep showed statistically significant ($P<0.05$) increases in the area of airway wall smooth muscle in lung compartments chronically challenged with HDM compared with untreated control compartments

in the same animal (Table 1, Fig. 4b). No such increases were observed in saline-challenged control sheep (Fig. 4b).

Mast cells, eosinophils and lymphocyte subpopulations in lung tissues repeatedly challenged with house dust mite

There was a significant increase in the number of mast cells (metachromatic cells stained with toluidine blue) in all HDM-challenged lung compartments 8–9 days after the final challenge, compared with the untreated, control lung tissues in the same sheep. On average, twice the number of mast cells per square millimetre of lung parenchyma were counted in challenged lung compartments compared with untreated lung tissue controls (Fig. 5a). Most of the increase in mast cell numbers was found in alveolar septa and, to a lesser extent, in airway walls (Fig. 5b). There was a similar twofold increase in the number of IgE-labelled cells in lung parenchyma exposed to HDM (Figs 5a and 6). Careful analysis of serial sections of IgE and toluidine blue-stained mast cells showed that IgE staining was restricted to mast cells (data not shown). Similar staining intensity for IgE was observed on mast cells irrespective of whether they were located in the HDM-challenged or untreated lung compartments (Figs 6a and b). No increases in IgE^+ mast cells were observed in sheep repeatedly challenged with saline (not shown).

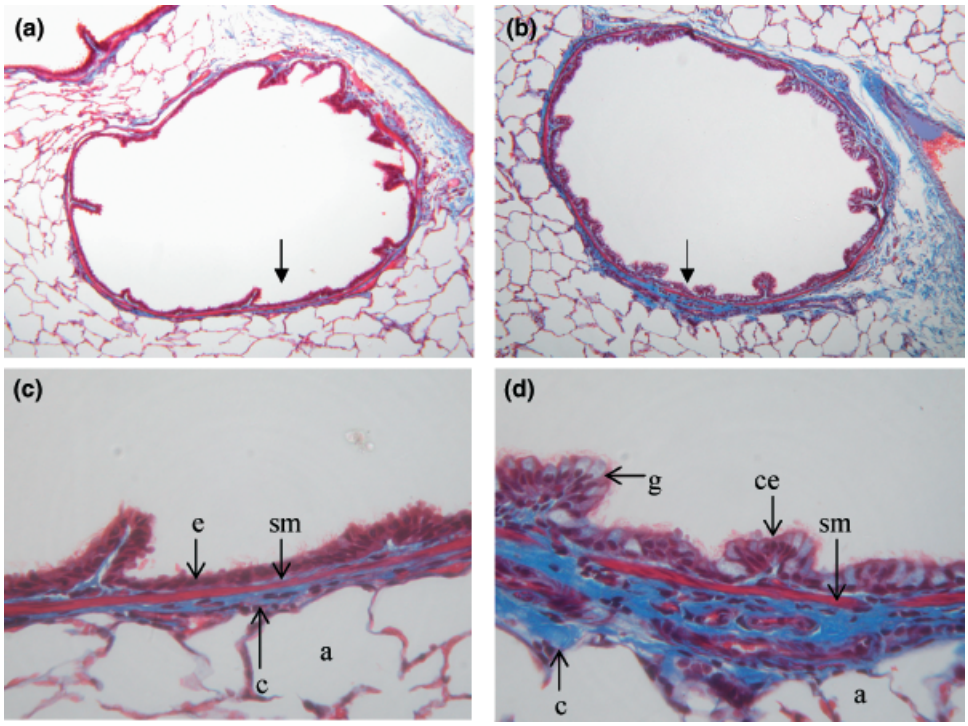

Fig. 3. Chronic challenges with house dust mite (HDM) induce local airway wall changes in sheep lungs. Panels depict histology of Masson's trichrome-stained sections of similar size bronchioles from untreated control (a and c) and HDM-challenged (b and d) lung compartments in the same sheep. Large arrows, areas used for high-power magnification in lower panels; a, alveoli; c, collagen (blue); ce, columnar epithelium; e, cuboidal epithelium; g, goblet cell (additional staining shows that these are predominantly Alcian blue +ve); sm, smooth muscle. Magnification, a and b × 100, c and d × 400.

Table 1. Airway wall collagen and smooth muscle content in individual HDM- or saline-challenged sheep

Sheep no.	Infusion	†Ratio collagen area : BM length		†Ratio smooth muscle area : BM length	
		Challenge‡	Control‡	Challenge‡	Control‡
SAL1	Saline	12.09 ± *9.08*	14.23 ± *9.89*	6.77 ± *5.22*	6.65 ± *5.34*
SAL2	Saline	9.48 ± *5.37*	7.90 ± *6.51*	5.17 ± *4.13*	5.07 ± *4.17*
SAL3	Saline	8.02 ± *6.26*	10.28 ± *7.54*	4.41 ± *3.75*	4.89 ± *3.64*
HDM1	HDM	6.92 ± *4.70*	4.84 ± *2.54*	2.13 ± *1.68*	3.33 ± *2.64*
HDM2	HDM	*10.91 ± *7.90*	4.70 ± *3.20*	4.90 ± *3.60*	3.19 ± *2.45*
HDM3§	HDM	33.74 ± *24.74*	26.42 ± *19.25*	32.48 ± *21.15*	20.00 ± *11.71*
HDM4	HDM	*9.75 ± *6.66*	5.20 ± *2.97*	*6.64 ± *5.38*	3.56 ± *2.60*
HDM5§	HDM	43.61 ± *40.28*	25.85 ± *13.70*	*39.72 ± *31.93*	20.48 ± *11.99*
HDM6	HDM	9.44 ± *7.20*	14.51 ± *7.16*	4.74 ± *3.74*	6.44 ± *5.29*
HDM7§	HDM	*56.35 ± *51.95*	24.25 ± *15.47*	*41.13 ± *29.51*	18.33 ± *10.22*

*$P<0.05$, Challenge vs. control.
†Data were obtained from morphometric image analysis of Masson's trichrome-stained histological cross-sections of small bronchi and bronchioles. Average collagen and smooth muscle area values were expressed as the respective area per airway basement membrane (BM) length area to adjust for differences in airway size. House dust mite-challenged (HDM) sheep received repeated infusions of HDM to the left lung (challenge). Saline-challenged (SAL) sheep received repeated infusions of saline in lieu of HDM. In all sheep, the right lung was left untreated (control).
‡Mean values ± SD (italic), $n = 30$.
§Immersion-fixed lungs.

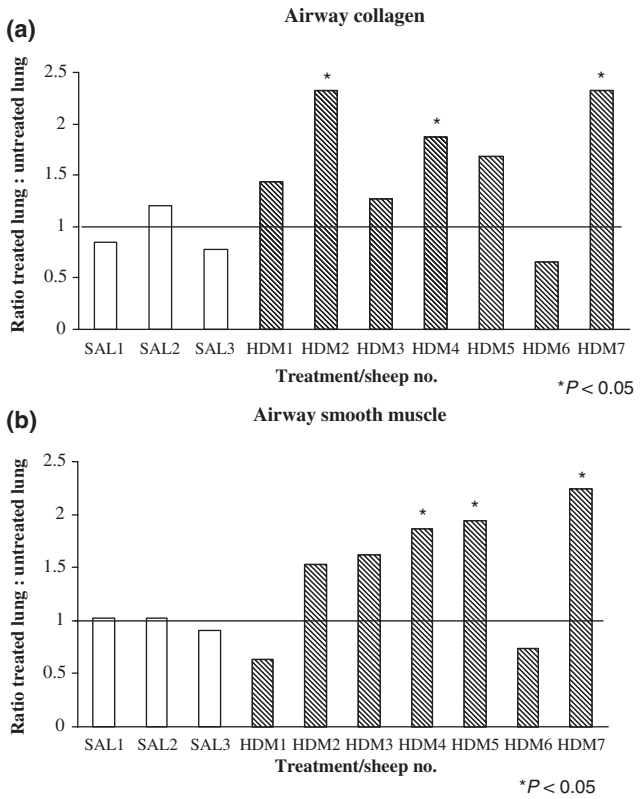

Fig. 4. Relative area content of collagen (a) and airway smooth muscle (ASM) (b) in three control (SAL1–3) and seven experimental (HDM1–7) sheep. The data represent a ratio of collagen or ASM area content for individual sheep in the challenged (left) lung vs. the respective area content in the untreated (right) lung, normalized to one. The data were processed from raw data presented in Table 1. An asterisk denotes significant difference between area data averaged from challenged and untreated lung segments in the same sheep ($P<0.05$). SAL, saline-challenged; HDM, house dust mite-challenged.

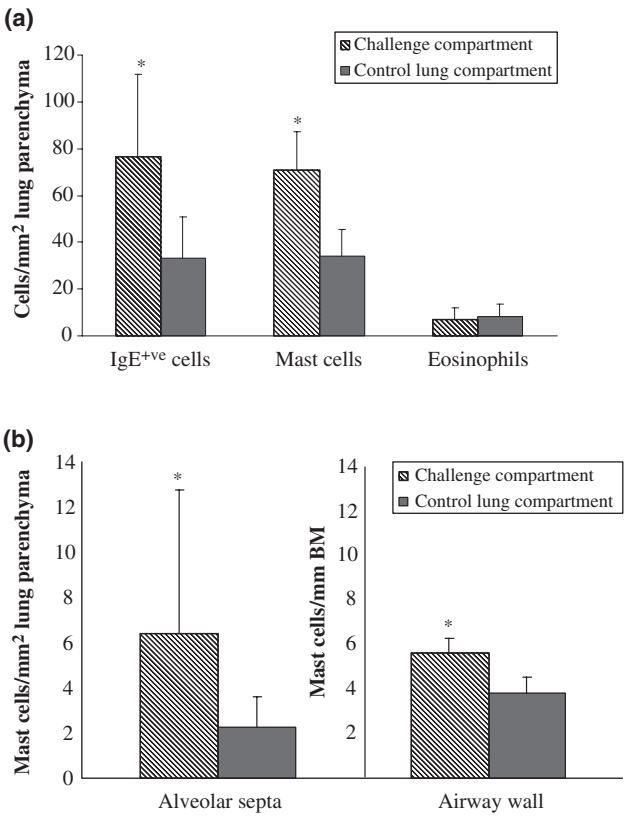

Fig. 5. (a) Mast cells, IgE$^+$ cells and eosinophils in frozen tissue sections prepared from lung compartments receiving repeated house dust mite challenges (challenge) and untreated lung compartments (control). $n = 5$ sheep. (b) Mast cell populations in alveolar septa and airway walls as assessed from paraffin sections. The data are expressed in cells per square millimetre lung parenchyma for mast cells in alveolar septa and cells/mm airway wall basement membrane for mast cells in airway walls. $n = 3$ sheep (*$P<0.05$).

In contrast to mast cells, the post-mortem histopathological analysis revealed that the number of eosinophils in lung compartments challenged with HDM was not significantly different from their respective numbers in internal untreated control compartments 8–9 days after the final challenge (see Fig. 5a).

Immunohistochemistry on lung tissues sampled 8–9 days after the final challenge revealed elevated numbers of CD5$^+$ and γδ-TCR$^+$ lymphocytes in HDM-challenged lung compartments compared with untreated control compartments (Fig. 7). While there were large variations in the number of lymphocytes between sheep, the increase in these subpopulations in the challenged lung compartment was consistent in all HDM-challenged sheep, and significantly higher compared with the unchallenged lung compartments of the same sheep when compared by two-tailed paired students *t*-tests. The relative number of CD4, CD8 and B cells (either CD45R$^+$ or CD21$^+$) was not significantly different between HDM and untreated lung compartments (Fig. 7). No significant lymphocyte changes were observed in saline-challenged lungs (not shown). A comparison of data from individual HDM-challenged sheep showed that there was no correlation between increases in mast cells and lymphocytes and remodelling of airway collagen and smooth muscle.

Discussion

The results of the present study indicate that repeated challenges with HDM can induce a local pathophysiological environment conducive to remodelling-like changes in the lungs of a proportion of atopic sheep. The changes observed in these sheep resemble many important features of the lung pathology in chronic asthmatics, including (1) increases in small airway collagen and smooth muscle content, (2) a greater density of mast cells in alveolar septa and airway walls and (3) goblet cell hyperplasia. It is noteworthy that these structural changes in the lung were induced with HDM, an allergen relevant to many asthma sufferers [14] and recently shown to induce an acute allergic inflammatory response in the lungs of sensitized sheep [8]. This is the first report showing that repeated HDM challenges and the consequent inflammatory responses can induce airway wall remodelling in sheep lungs. Most animal models of asthma exhibit some, but not all, of the morphological and functional lesions of the chronic human disease [15–17]. The most commonly used model, the mouse, has further limitations in airway size, structure and development [18] when modelling human respiratory disease. Airway remodelling has been demonstrated in a large animal model, where infant monkeys

repeatedly exposed to HDM show atypical development of basement membranes and neural components in the airways [19, 20].

Eosinophils are well recognized as central effector cells in the inflamed asthmatic airway and have been suggested to be active in remodelling of asthmatic lungs [21]. The data presented in this study show that eosinophils are recruited to lung tissues and BAL fluids between 2 and 5 days after HDM provocation and, importantly, are distributed in the vicinity of airway wall components in which remodelling changes were observed (lamina priopria, smooth muscle and epithelium of bronchi). There was evidence of eosinophilic granules in these regions, although it could not be conclusively proven that these were from degranulating eosinophils. The data are consistent with the presence of infiltrating eosinophils and possibly their degranulation products contributing to damage and inflammation of tissues associated with the airway wall. While the challenge regime used in these studies (HDM challenges once or twice a week) was sufficient to maintain the recruitment of eosinophils to the BAL and lung tissues throughout the challenge period, it is interesting to note that eosinophils were absent from the BAL 6 days after challenge and were largely depleted in lung tissues 8–9 days post-challenge. Eosinophil survival and persistence in allergic tissues is a known factor in the exacerbation of asthma [22]. The results of the present study suggest that the lifespan of eosinophils recruited into lung tissues in response to HDM provocation in this model is about 6 days and that regular provocations with HDM were required to maintain persistent high numbers of lung eosinophils.

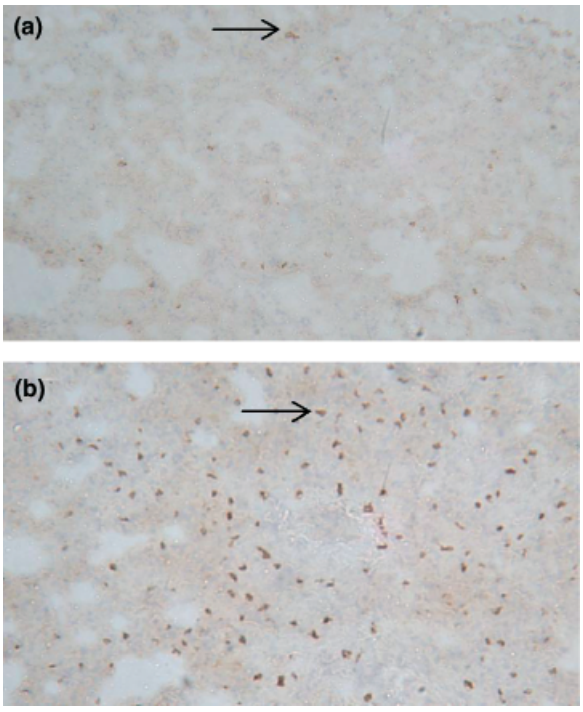

Fig. 6. Mast cells (arrows) stained with anti-IgE antibody on frozen tissue sections taken from an untreated lung compartment (a) and a lung compartment repeatedly challenged with house dust mite (b) from the same sheep (× 100).

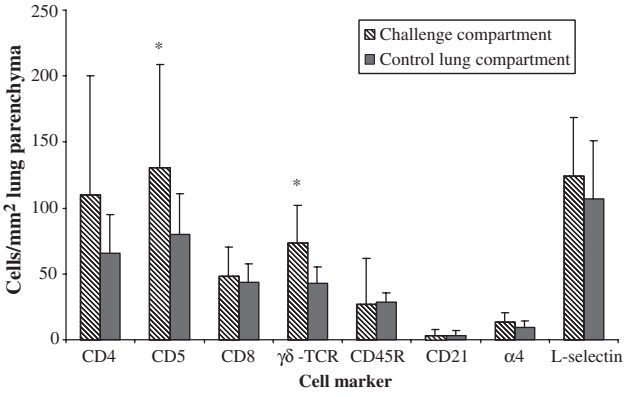

Fig. 7. Lymphocyte subpopulations in tissue sections prepared from lung compartments receiving repeated house dust mite challenges (challenge) and untreated lung compartments (control) (*$P<0.05$).

The data from the BAL cell counts do not support a role for neutrophils in remodelling of the sheep lung in response to repeated HDM challenges. Neutrophils were recruited to the BAL in both saline- and HDM-challenged sheep; however, only HDM-treated sheep exhibited remodelling changes. The increase in neutrophils in the BAL was transient and did not extend beyond the first 24 h after challenge. These results, however, do not preclude that neutrophils could contribute to remodelling if they were to persist in the lung tissues and BAL fluids for continuous periods, as suggested for some asthmatic patients [23].

Mast cells were present in significantly higher numbers in lung tissues exposed to HDM. Compared with the short period of the eosinophil response, the effect of repeated HDM challenges on mast cells appears to be relatively long lasting, as the mast cells were counted in autopsy lung tissues sampled 8–9 days after the final HDM challenge. Higher densities of mast cells were found in alveolar septa and airway walls. These findings are consistent with the human condition in that mast cell density is higher in lung tissues of fatal asthmatics and mild asthmatics compared with non-asthmatic controls [24, 25] and increased mast cell numbers around ASM are correlated with increased airway hyper-responsiveness [26]. It is not known whether there is a relationship between mast cell hyperplasia in HDM-exposed lungs and the remodelling changes observed in the present study. It has been suggested that tryptase, a neutral serine protease that is predominantly expressed in mast cells, could be involved in repair of damaged tissues in remodelling of asthmatic lungs [27, 28]. Tryptase is thought to act through the protease-activate receptor-2 and is known to play a role in proliferation of ASM, epithelial cells and fibroblasts. It is plausible that repeated triggering of the numerous IgE-primed mast cells allows for increased release of mast cell products such as tryptase. The sheep model for airway remodelling presented here could be used to test whether tryptase or other mast cell products are involved in tissue repair mechanisms by analysing the remodelling response to repeated HDM provocations in the presence of known inhibitors [29].

Large variations in cellular and immunological responses to HDM in sheep have been noted [8] and probably relate to the range of responses expected in an outbred population [18]. It is noteworthy that different degrees of remodelling occurred despite the fact that eosinophil numbers were elevated in the BAL of all sheep and all sheep had increased density of mast

cells and $CD5^+$ and $\gamma\delta$-TCR^+ lymphocytes in lung tissue exposed to HDM. Remodelling is known to involve complex interactions between chronic inflammatory responses and between cell mediators, cell and tissue repair processes and genetic factors [27]. The variability of airway remodelling responses in sheep may therefore at least be partly because of factors that are not directly related to inflammation, such as cellular repair mechanisms and interactions with other cellular processes that lead to irreversible lung damage. With the complexity involved it is not surprising that the degree and nature of remodelling responses vary in sheep as indeed it does in asthmatic patients [30] and further examination of the molecular basis of this variability may elucidate the genetic or physiological factors determining susceptibility.

Given the fact that sheep lungs are physiologically and morphometrically similar to lungs of humans, allergen-induced remodelling in the sheep lung is more likely to cause a comparable pathophysiological deterioration in lung function typical of this disease. In this respect, an earlier study of chronic airway challenge with *Ascaris* antigen in sheep demonstrated a stable increase in lung resistance in responsive animals [31]. Further studies will aim to examine the relationship of airway remodelling on the development of airway hyper-reactivity after chronic allergen challenge. In addition, the development of a large animal model for chronic inflammatory airway disease as described in this study will allow a closer examination of the molecular mechanisms and processes involved in airway remodelling in asthmatic lungs.

References

1 Grol MH, Gerritsen J, Vonk JM et al. Risk factors for growth and decline of lung function in asthmatic individuals up to age 42 years. A 30-year follow-up study. Am J Respir Crit Care Med 1999; 160:1830–7.

2 Ulrik CS, Lange P. Decline of lung function in adults with bronchial asthma. Am J Respir Crit Care Med 1994; 150: 629–34.

3 Carter PM, Heinly TL, Yates SW, Lieberman PL. Asthma: the irreversible airways disease. J Invest Allergol Clin Immunol 1997; 7:566–71.

4 Brown PJ, Greville HW, Finucane KE. Asthma and irreversible airflow obstruction. Thorax 1984; 39:131–6.

5 Davies DE, Wicks J, Powell RM, Puddicombe SM, Holgate ST. Airway remodeling in asthma: new insights. J Allergy Clin Immunol 2003; 111:215–25.

6 Phipps S, Ying S, Wangoo A, Ong YE, Levi-Schaffer F, Kay AB. The relationship between allergen-induced tissue eosinophilia and markers of repair and remodeling in human atopic skin. J Immunol 2002; 169:4604–12.

7 Dunphy J, Barcham G, Bischof R, Young A, Nash A, Meeusen EN. Isolation and characterization of a novel eosinophil-specific galectin released into the lungs in response to allergen challenge. J Biol Chem 2002; 277:14916–24.

8 Bischof RJ, Snibson K, Shaw R, Meeusen ENT. Induction of allergic inflammation in the lungs of sensitized sheep after local challenge with house dust mite. Clin Exp Allergy 2003; 33: 367–75.

9 Dunphy JL, Balic A, Barcham GJ, Horvath AJ, Nash AD, Meeusen EN. Isolation and characterization of a novel inducible mammalian galectin. J Biol Chem 2000; 275:32106–13.

10 Bai A, Eidelman DH, Hogg JC et al. Proposed nomenclature for quantifying subdivisions of the bronchial wall. J Appl Physiol 1994; 77:1011–4.

11 Elliot J, Vullermin P, Robinson P. Maternal cigarette smoking is associated with increased inner airway wall thickness in children who die from sudden infant death syndrome. Am J Respir Crit Care Med 1998; 158:802–6.

12 Bai TR, Cooper J, Koelmeyer T, Pare PD, Weir TD. The effect of age and duration of disease on airway structure in fatal asthma. Am J Respir Crit Care Med 2000; 162:663–9.

13 Carroll N, Elliot J, Morton A, James A. The structure of large and small airways in nonfatal and fatal asthma. Am Rev Respir Dis 1993; 147:405–10.

14 Sharma S, Lackie PM, Holgate ST. Uneasy breather: the implications of dust mite allergens. Clin Exp Allergy 2003; 33:163–5.

15 Kumar RK, Foster PS. Murine model of chronic human asthma. Immunol Cell Biol 2001; 79:141–4.

16 Evans MJ, Van Winkle LS, Fanucchi MV et al. Fibroblast growth factor-2 in remodeling of the developing basement membrane zone in the trachea of infant rhesus monkeys sensitized and challenged with allergen. Lab Invest 2002; 82:1747–54.

17 Palmans E, Kips JC, Pauwels RA. Prolonged allergen exposure induces structural airway changes in sensitized rats. Am J Respir Crit Care Med 2000; 161:627–35.

18 Collie DD. Comparative, complementary and relevant: the immunologcal basis of ovine lung allergic responses. Clin Exp Allergy 2003; 33:282–6.

19 Evans MJ, Fanucchi MV, Baker GL et al. Atypical development of the tracheal basement membrane zone of infant rhesus monkeys exposed to ozone and allergen. Am J Physiol Lung Cell Mol Physiol 2003; 285:L931–9.

20 Larson SD, Schelegle ES, Walby WF et al. Postnatal remodeling of the neural components of the epithelial–mesenchymal trophic unit in the proximal airways of infant rhesus monkeys exposed to ozone and allergen. Toxicol Appl Pharmacol 2004; 194:211–20.

21 Busse W, Elias J, Sheppard D, Banks-Schlegel S. Airway remodeling and repair. Am J Respir Crit Care Med 1999; 160:1035–42.

22 Kankaanranta H, Lindsay MA, Giembycz MA, Zhang X, Moilanen E, Barnes PJ. Delayed eosinophil apoptosis in asthma. J Allergy Clin Immunol 2000; 106:77–83.

23 Sampson AP. The role of eosinophils and neutrophils in inflammation. Clin Exp Allergy 2000; 30 (Suppl. 1):22–7.

24 Carroll NG, Mutavdzic S, James AL. Increased mast cells and neutrophils in submucosal mucous glands and mucus plugging in patients with asthma. Thorax 2002; 57:677–82.

25 Berger P, Walls AF, Marthan R, Tunon-de-Lara JM. Immunoglobulin E-induced passive sensitization of human airways: an immunohistochemical study. Am J Respir Crit Care Med 1998; 157:610–6.

26 Brightling CE, Bradding P, Symon FA, Holgate ST, Wardlaw AJ, Pavord ID. Mast-cell infiltration of airway smooth muscle in asthma. N Engl J Med 2002; 346:1699–705.

27 Howarth P, Wilson J, Bousquet J, Rak S, Pauwels RA (eds) Airway remodelling, 1st Edn. New York: Marcel Dekker Inc., 2001; 1–293.

28 Abraham WM. Tryptase: potential role in airway inflammation and remodeling. Am J Physiol Lung Cell Mol Physiol 2002; 282:L193–6.

29 Elrod KC, Moore WR, Abraham WM, Tanaka RD. Lactoferrin, a potent tryptase inhibitor, abolishes late-phase airway responses in allergic sheep. Am J Respir Crit Care Med 1997; 156:375–81.

30 Beasley R, Page C, Lichtenstein L. Airway remodelling in asthma. Clin Exp Allergy Rev 2002; 2:109–16.

31 Bosse J, Boileau R, Begin R. Chronic allergic airway disease in the sheep model: functional and lung-lavage features. J Allergy Clin Immunol 1987; 79:339–44.