*Journal of Pediatric Gastroenterology and Nutrition*
**38:**16–26 © January 2004 Lippincott Williams & Wilkins, Inc., Philadelphia

Invited Review

# Neonatal Enteropathies: Defining the Causes of Protracted Diarrhea of Infancy

Philip M. Sherman, David J. Mitchell, and Ernest Cutz

*Research Institute, Hospital for Sick Children, University of Toronto, Toronto, Ontario, Canada*

**ABSTRACT**
The underlying causes of chronic diarrhea beginning early in life are increasingly well defined. Infectious and post-infectious enteropathies and food sensitive/allergic enteropathy account for the majority of cases. Recent attention has focused on characterizing defined entities, which cause protracted diarrhea in infants and young children. Disorders of intestinal ion transport usually present at birth following a pregnancy complicated by polyhydramnios. Intestinal mucosal biopsies show normal architect with intact villus-crypt axis. Neonatal enteropathies, by contrast, are characterized by blunting of the villi. These include microvillus inclusion disease, tufting enteropathy, autoimmune enteropathy and IPEX syndrome - and it is these conditions that are the subject of the current review. ***JPGN 38:16–26, 2004.*** **Keywords:** Diarrhea—Infants—Microvilli—Tufting—IPEX—Autoimmune—Epithelium. © 2003 Lippincott Williams & Wilkins, Inc.

## INTRODUCTION

Chronic and prolonged diarrhea is a symptom complex with a variety of underlying etiologies. A recent medical position statement, which was published by the American Gastroenterological Association (1), provides a comprehensive review of the subject in adults. However, a different approach is required for evaluating infants and young children with protracted diarrhea. The increasingly well-characterized enteropathies that present in the neonatal period or early infancy (2) provide the basis for this review.

Intractable diarrhea of infancy is a term coined many years ago by Avery (3) to describe chronic, unexplained diarrhea in young children. The phrase has since been decried because it describes a symptom complex rather than a discrete disease entity (4). Protracted diarrhea has been used more recently as a generic term to describe infants with loose and frequent stools of sufficient severity to require nutritional support, often in the form of parenteral alimentation (5). The emphasis on adequate support of total caloric intake and nutritional rehabilitation has dramatically improved the survival of affected infants and children.

Address correspondence and reprint requests to Dr. Philip M. Sherman, Gastroenterology and Nutrition, Room 8409, Hospital for Sick Children, 555 University Avenue, Toronto, Ontario, M5G 1X8, Canada, (e-mail: sherman@sickkids.ca).

Causes of protracted diarrhea beginning early in life can be divided into those entities having a normal villus-crypt axis and those associated with villus atrophy (Table 1). Congenital defects in the transport of sodium, chloride, glucose/galactose and bile acids, and congenital enterokinase deficiency each can cause prolonged diarrhea dating to the early neonatal period (6). Often, a maternal history of polyhydramnios during the pregnancy is a clue to the diagnosis. Stool collection for the determination of fecal electrolyte concentrations should be undertaken early on in the assessment because the results can prove helpful in identifying the underlying molecular defect (7). In recent years, major advances have been made in understanding the molecular basis of these diseases (8,9).

The value of identifying an underlying etiology of chronic protracted diarrhea is that it allows improved counseling of parents, families, referring physicians and other health care professionals about long-term prognosis and therapeutic options (6). In addition, since some of these conditions appear to have a genetic basis, the potential risk of subsequent affected siblings can be better assessed (10).

### Microvillus Inclusion Disease

#### *Presentation*

Microvillus inclusion disease is a severe enteropathy with watery diarrhea often beginning on the first day of



Copyright © Lippincott Williams & Wilkins. Unauthorized reproduction of this article is prohibited.

**TABLE 1.** *Causes of protracted diarrhea beginning during the first six months of life*

| |
|---|
| Normal villus-crypt architecture: |
| Transport defects |
| chloride-bicarbonate exchanger (chloride-losing diarrhea) |
| sodium-hydrogen exchanger (congenital sodium diarrhea) |
| ileal bile acid receptor defect |
| sodium-glucose cotransporter (glucose-galactose malabsorption) |
| Micronutrient deficiency |
| acrodermatitis enteropathica (zinc deficiency) |
| Enzyme deficiency |
| enterokinase deficiency |
| Congenital short bowel |
| Villus atrophy: |
| microvillus inclusion disease |
| tufting enteropathy |
| autoimmune enteropathy |
| IPEX syndrome |
| infectious enteropathy |
| post-infectious enteropathy |
| allergic enteropathy |
| idiopathic |

life which is characterized on transmission electron microscopy by microvillus inclusions in enterocytes and colonocytes. This entity has been variously referred to as microvillus inclusion disease, congenital microvillus atrophy, familial microvillous atrophy and Davidson's syndrome (11). We prefer the term microvillus inclusion disease because it highlights the characteristic diagnostic feature unique to this disorder, whereas microvillus atrophy is a non-specific finding observed in various types of intestinal injury.

In microvillus inclusion disease, diarrhea can be so watery that it is mistaken for urine. The fecal sodium and chloride concentrations approximate those of serum and the volume of stool loss may be equal to or greater than that observed during cholera infection. Ion flux studies demonstrate a net secretory state which accounts for the voluminous diarrhea (12). As a result, affected infants will die of dehydration unless appropriate (often massive) intravenous fluid replacement is provided. Once infection has been excluded, microvillus inclusion disease is the most common identified cause of severe protracted diarrhea beginning during the first week of life (13). In contrast to neonates with transport defects (for example, congenital chloride-losing diarrhea), polyhydramnios is not a common prenatal complication. Microvillus inclusion disease has been identified in infants from multiple ethnic backgrounds worldwide (14). Multiple siblings can be affected (11). The disease appears to cluster in infants of Navajo descent (15,16) providing evidence in support of a genetic etiology.

Our experience indicates that classic microvillus inclusion disease is a severe and intractable enteropathy requiring total parenteral nutrition for the delivery of fluids and calories and that the condition is inevitably fatal without continuous intravenous nutrition or intestinal transplantation (13). However, there are some reports of milder variants of microvillus inclusion disease that present later and in which the prognosis may be better (17). Indeed, in some cases advancing enteral nutrition has been possible over time (18).

## Morphology

Duodenal biopsies in classic microvillus inclusion disease show normoplastic villus atrophy with relatively little crypt hyperplasia, and an absence of marked inflammatory infiltrate in the lamina propria (Figure 1 A). On higher magnification, the surface enterocytes are focally piled-up and disorganized, with extensive vacuolization of the apical cytoplasm and loss of brush border definition (Figure 1 B). As shown in Figure 1 C with periodic-acid Schiff (PAS) staining the apical brush border is poorly defined and there is PAS-positive staining of the apical cytoplasm of enterocytes that is not seen in normal small intestine (19). Immunohistochemistry for brush border enzymes demonstrates the presence of alkaline phosphatase within the apical cytoplasm as well as in circular structures corresponding to microvillus inclusions (20).

Immunostaining for various cytoplasmic and membrane antigens is useful in supporting the diagnosis of microvillus inclusion disease at the light microscope level. For example, immunostaining for villin, a microfilament component of the microvillus core, clearly demonstrates the intracytoplasmic microvillus inclusions (Figure1 D). Similarly, antibodies against carcinoembryonic antigen (CEA) and CD10, a leukemia antigen normally expressed in the brush border of enterocytes, are both useful in demonstrating microvillus inclusions (21,22). In cases of microvillus inclusion disease there is increased epithelial cell turnover with both enhanced proliferation (Ki67 staining) and increased programmed cell death (apoptosis detected by TUNEL assay) to levels higher than that observed in normal small bowel, but less than seen in gluten-sensitive enteropathy (23).

The morphology of duodenal biopsies in the variant forms of microvillus inclusion disease is more variable and may evolve with time. In the reported cases (17) and in our experience (unpublished data), duodenal biopsies may initially show total villus atrophy, but later in life show relatively normal villi on routine histopathology (Figure 2 A). However, in this setting PAS staining or immunostaining for CD10 will show patches of abnormal enterocytes containing microvillus inclusions next to apparently normal small bowel epithelium (Figure 2 B).

On transmission electron microscopy, intracytoplasmic microvillus inclusions in surface epithelial cells are a characteristic and diagnostic feature of microvillus inclusion disease (Figure 3 A) because such inclusions are not found in other small bowel enteropathies (24,25). Microvillus inclusions can also be identified in colonocytes (26) and in epithelial cells lining the stomach, renal


Copyright © Lippincott Williams & Wilkins. Unauthorized reproduction of this article is prohibited.

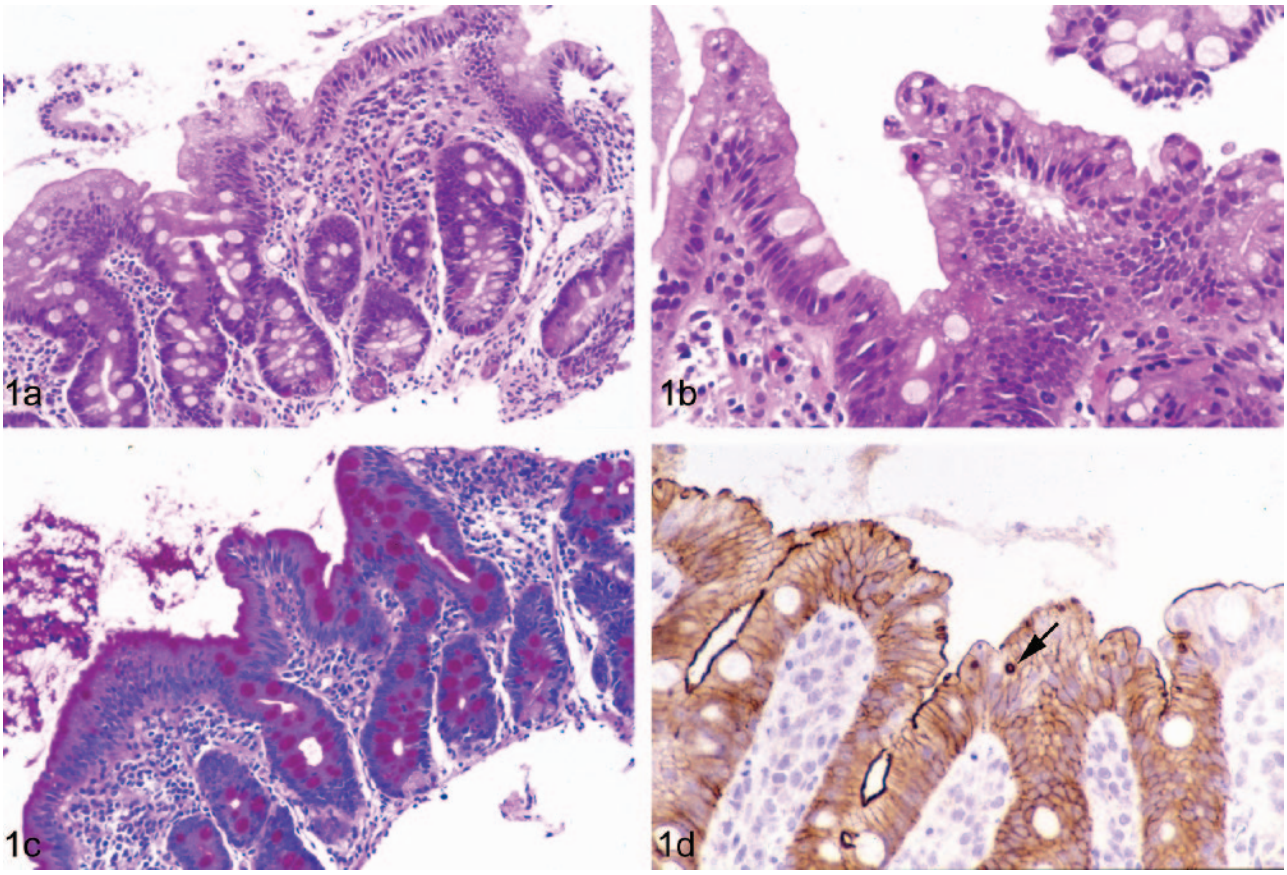


**FIG. 1.** Histopathologic features of classic microvillus inclusion disease. A: Low magnification view of a jejunal biopsy obtained from a child with microvillus inclusion disease showing total villus atrophy and relatively short crypts, but with the usual number and type of inflammatory cells contained in the lamina propria (hematoxylin and eosin, approximate original magnification, X 200). B: Higher magnification of surface enterocytes with vacuolated apical cytoplasm and focal piling-up of cells. Several well-preserved goblet cells are present (H & E, X 400). C: Periodic acid Schiff stain demonstrating positive staining of the apical cytoplasm of enterocytes and normal staining of goblet cells (PAS, X 200). D: Immunohistochemistry for villin showing patchy linear staining of the brush border membrane, most prominent in mid-crypt enterocytes, and occasional intracytoplasmic circular structures (arrow) corresponding to microvillus inclusions (immunoperoxidase stain, X 400).

tubules (11) and gall bladder (12). The classic microvillus inclusions are composed of complete brush borders with a microvillus membrane, microfilaments, the terminal web and a surface filamentous coat (Figure 3 B). These microvillus inclusions are usually located close to the apical surface, but sometimes are found deeper in the cell cytoplasm without a clear membrane demarcation. Since microvillus inclusions are not found in every enterocyte, an extensive search on multiple blocks must be undertaken. Another common problem is inappropriate tissue orientation with lack of surface enterocytes evident in the sample viewed under transmission electron microscopy. When faced with these technical issues, it is possible to use formalin fixed, paraffin embedded tissues and re-process them for electron microscopy, as microvillus inclusions appear well preserved in such preparations (Figure 3 C).

The other characteristic electron microscopic feature of microvillus inclusion disease is the presence of apical secretory granules (also referred to as vesicular bodies). Vesicular bodies have a variable morphology but are usually composed of a single limiting membrane surrounding a lumen filled with a mixture of amorphous granular material, small vesicles and fragments of membranes. Vesicular bodies, which account for the vacuolated appearance and PAS-positive staining of enterocytes in microvillus inclusion disease, are prominent in surface epithelia, but are also found in cells lining the mid- and lower crypts (Figure 3 D). A report of three cases describes the enterocytes which contain secretory granules, but which lack the classic microvillus inclusions (27). It is possible that this unusual histology simply reflects a sampling bias since not every enterocyte will contain microvillus inclusions.


Copyright © Lippincott Williams & Wilkins. Unauthorized reproduction of this article is prohibited.

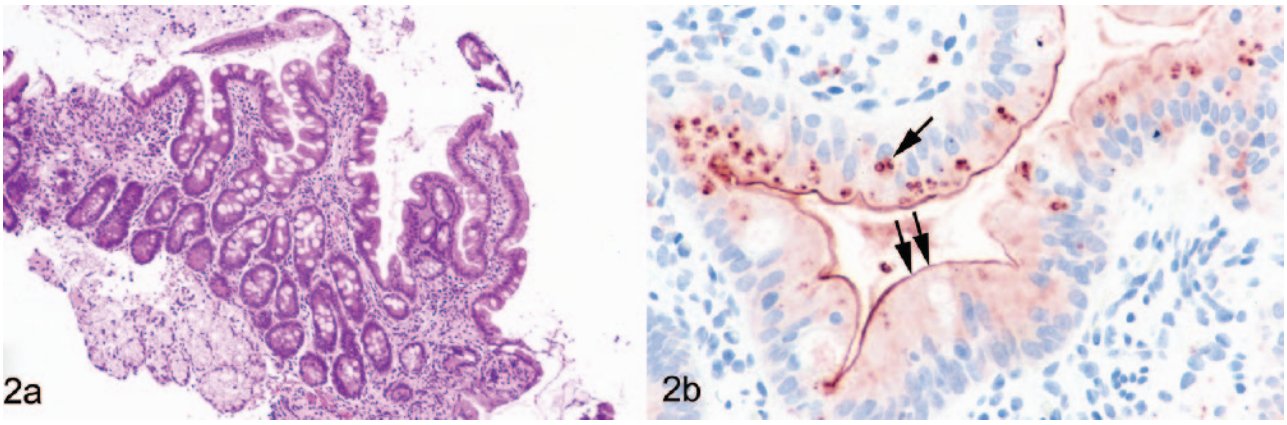


**FIG. 2.** Histopathologic features in the variant form of microvillus inclusion disease. A: Several relatively normal appearing villi and crypts in a duodenal biopsy of an infant with protracted diarrhea (hematoxylin and eosin, approximate original magnification, X 100). B: Immunostaining for CD10 showing patchy involvement of the surface epithelium. Some enterocytes contain positively immunostained cytoplasmic inclusions (arrow) and variable apical membrane staining. Adjacent epithelial cells show relatively intact brush border immunostaining (double arrow) without intracytoplasmic inclusions (immunoperoxidase, X 400).

## Pathogenesis

The primary defect causing microvillus inclusion disease is not known. The occurrence among siblings has raised the possibility that it is a genetic defect inherited in an autosomal recessive manner (11,13). Speculation has focused on the assertion that the inclusions represent a genetic defect in the trafficking of membrane proteins to the apical surface of differentiated epithelia. It appears that the underlying defect is specifically related to the routing of constituents integral to the apical plasma membrane since cytoskeletal proteins tested are present and structurally intact (28). Moreover, the insertion of transporters (eg. Na+-K+ATPase) into the basolateral membrane is also preserved (28,29).

Comparable inclusions in rat small bowel enterocytes are observed following enteral challenge with colchicine, an agent known to depolymerize and thereby disrupt the normal function of microtubules in the cell cytoplasm (30). As in microvillus inclusion disease, delivery of proteins to the basolateral surface of rat enterocytes is not affected by treatment with pharmacologic agents used to impair the normal function of microtubules (30). These findings suggest that disruption of the delivery of structurally intact constituents of the apical brush border membrane could account for the morphologic changes observed in microvillus inclusion disease (Figure 3 E). Further studies to address this issue using human gut epithelia clearly are warranted.

A more recent study used immunogold electron microscopy on small bowel mucosa obtained from four children with microvillus inclusion disease to demonstrate sucrase-isomaltase hydrolase activity in the secretory granules present in crypt epithelia (31). Microvillus inclusions were reported to correspond to early endosomes since they did not contain markers typical of lysosomes (eg. LAMP1, acid phosphatase). The authors concluded that autophagocytosis of the apical membrane of enterocytes accounted for the typical morphology, but did not identify the underlying defect that might promote such an aberrant response (31). Of course, it is also conceivable that in microvillus inclusion disease the abnormal apical membrane of enterocytes resulting from a defect in the trafficking of membrane vesicles renders it more susceptible to autophagocytosis.

Currently, there are major advances being made in the study of the fundamental processes controlling cell differentiation, epithelial cell polarity, and intestinal epithelial response to injury (reviewed in 32, 33). It is anticipated that this knowledge will stimulate research aimed at identifying the basic defect causing microvillus inclusion disease.

## Tufting Enteropathy

### *Presentation*

Tufting enteropathy, also referred to as intestinal epithelial dysplasia, presents in the first few months of life with chronic watery diarrhea and impaired growth. Some affected infants are reported to have dysmorphic facial features (34). The long-term prognosis is variable. Most affected individuals depend on parenteral alimentation to acquire a caloric intake sufficient for normal growth and development. However, a recent report describes a 27 year old patient with tufting enteropathy who delivered a normal child after an uncomplicated pregnancy (35).

## Morphology

Typical light microscopic findings in jejunal biopsies of infants with tufting enteropathy include total or partial villus atrophy, crypt hyperplasia and normal or slightly


Copyright © Lippincott Williams & Wilkins. Unauthorized reproduction of this article is prohibited.

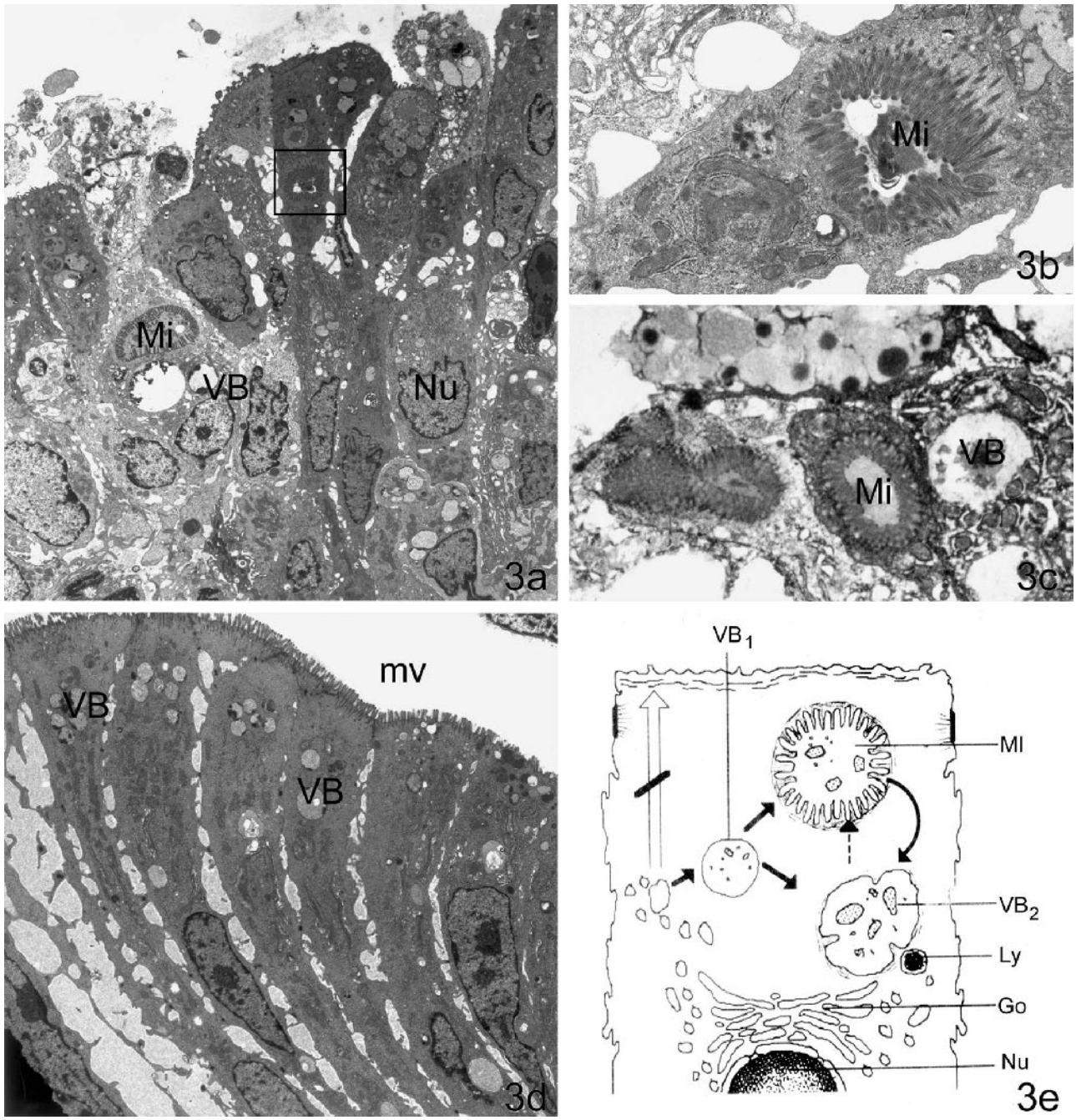


**FIG. 3.** Ultrastructural features of enterocytes in classic microvillus inclusion disease. A: Low magnification transmission electron photomicrograph showing surface enterocytes with haphazard arrangement of nuclei (Nu). The apical plasma membrane lacks well-developed brush border microvilli. Intracytoplasmic microvillus inclusions (Mi and boxed area) and vesicular bodies (VB) account for cytoplasmic inclusions (approximate original magnification, X 5,000). B: Higher power view of characteristic microvillus inclusion (Mi) from the boxed area shown in Figure 3 A. Well developed brush border microvilli face inwardly. Note the absence of a limiting membrane separating the microvillus inclusion from the adjacent cytoplasm (X 18,000). C: Well preserved microvillus inclusion (Mi) and vesicular body (VB) in an electron microscopy sample re-processed from formalin fixed, paraffin embedded tissue (X 15,000). D: Low magnification transmission electron photomicrograph of mid-crypt epithelium showing relatively well preserved brush border microvilli (MV). Except for the presence of occasional vesicular bodies (VB), cytoplasmic organelles are well preserved without microvillus inclusions (X 8,000). E: Schematic diagram of the possible enterocyte defect in microvillus inclusion disease. Normally, vesicles derived from the Golgi complex (Go) migrate to the cell surface (open arrows), transporting brush border membrane components to be assembled at the apical membrane. This pathway might be blocked (cross-bar) in microvillus inclusion disease, leading to the retention of transporting vesicles in the cell cytoplasm. Smaller vesicular bodies (VB1) may give rise to microvillus inclusions (Mi) or develop into larger vesicular bodies (VB2), which eventually fuse with lysozomes (Ly). A large vesicular body (VB2) could also represent the precursor of—or an intermediate stage—in the formation of microvillus inclusions (dashed arrow). Nu denotes the nucleus of the cell. Reproduced with permission [to be obtained] from Reference # 13.

Copyright © Lippincott Williams & Wilkins. Unauthorized reproduction of this article is prohibited.

increased density of inflammatory cells in the lamina propria (Figure 4 A). In contrast to celiac disease or autoimmune enteropathy, the number of intra-epithelial lymphocytes in tufting enteropathy is not markedly increased (11,36).

The characteristic feature of tufting enteropathy is the presence of focal epithelial "tufts" composed of closely packed enterocytes with rounding of the apical plasma membrane which results in a tear-drop configuration of the affected epithelial cell (Figure 4 B). These morphologic changes may persist for years with some improvement in villus architecture on long-term follow-up (unpublished observations). In contrast with microvillus inclusion disease, PAS staining in tufting enteropathy shows a thin linear staining of the apical membrane surface without PAS positivity of the enterocyte cytoplasm (Figure 4 C). On transmission electron microscopy, the cytoplasmic organelles of enterocytes appear well preserved. The brush border microvilli may be shortened, but there is an absence of microvillus inclusions or vesicular bodies (Figure 4 D). An increase in the number and length of desmosomes between enterocytes forming the tufts has been reported (37).

## Pathogenesis

The molecular basis for tufting enteropathy is not known. There may be a primary genetic defect; support for such a contention is provided by the observation that many affected individuals are of Maltese ancestry and involved families can have many affected infants (36,38).

One case report of an infant with an underlying defect in the laying down of extracellular matrix (eg. altered laminin and changes in proteoglycan deposition) had some of the morphologic features of tufting enteropathy (38). Epithelial cells lacking appropriate basement membrane are less well differentiated and subject to undergo programmed cell death (ie. apoptosis) (39,40). These changes may be related to a defect in the expression of cellular adhesion molecules. Patey et al. (37) reported

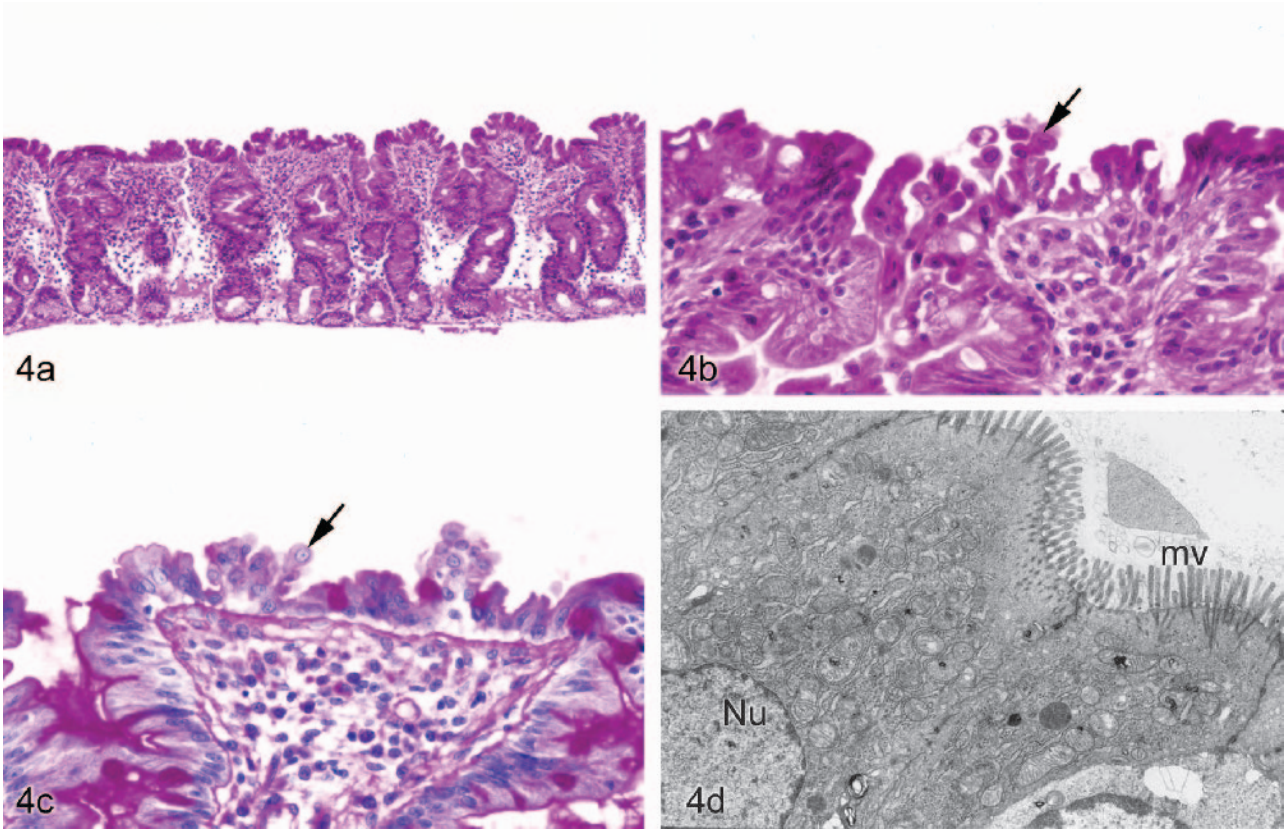


**FIG. 4.** Histopathologic and ultrastructural features of tufting enteropathy. A: Low power view of a jejunal biopsy obtained from a child with tufting enteropathy showing severe villus atrophy and moderate crypt hyperplasia without a marked inflammatory cell component in the lamina propria (hematoxylin and eosin stain, approximate original magnification, X 80). B: Higher magnification view of surface epithelial tufts formed at the tips of blunted villi (arrow). (H & E, X 400). C: Periodic acid Schiff stain demonstrating patchy surface membrane staining without intracytoplasmic positivity. Occasional teardrop-shaped cells (arrow) are present within epithelial tufts (PAS, X 400). D: Transmission electron photomicrograph of surface enterocytes showing normal brush border microvilli (MV), the cell nucleus (Nu) and well-preserved cytoplasmic organelles (X 10,000). Panels A–C reproduced with permission [to be obtained] from Reference #36.


Copyright © Lippincott Williams & Wilkins. Unauthorized reproduction of this article is prohibited.

altered distribution of alpha2/beta1 integrin and ultrastructural changes in desmosomes in the small bowel of six children with tufting enteropathy. A second case report describes deficient expression of alpha6/beta4 integrin in an infant with protracted diarrhea in whom epithelial cell detachment was observed in the stomach, small bowel and colon (41). However, this report may possibly describe a child with another condition (epidermolysis bullosa associated with pyloric atresia) rather than tufting enteropathy (Alain Lachaux, Personal Communication).

A mouse model in which the gene encoding the transcription factor Elf3 is disrupted also has morphologic features compatible with tufting enteropathy in human infants (42). In the mouse, there is abnormal morphogenesis of the villi from what appear to be intact progenitor cells in the crypts. The enterocytes in Elf3-deficient mice produce reduced levels of the transforming growth factor-beta type 2 receptor, which induces the differentiation of immature gut epithelia. Both the clinically based studies and the findings in experimental animals likely contain clues to the pathogenesis of tufting enteropathy that should be followed up in a careful, cooperative analysis of all cases identified at every center worldwide.

## Autoimmune Enteropathy

### *Presentation*

Cuenod et al. (43) summarized the clinical features of autoimmune enteropathy. They described 13 children with protracted diarrhea beginning during the first year of life whose intestinal mucosal biopsies showed villus atrophy and an infiltration of activated T cells into the lamina propria. In contrast to infants with microvillus inclusion disease and tufting enteropathy, those with autoimmune enteropathy frequently had extra-intestinal manifestations of autoimmunity. In addition, children with autoimmune enteropathy rarely had a family history of unexplained infant diarrhea. The onset of diarrhea frequently began after the first eight weeks of life and there was an apparent clinical response to potent immune suppression.

## Morphology

Autoimmune enteropathy is characterized by a marked infiltration of activated T lymphocytes in the lamina propria of both the small and large intestinal lamina propria (44). The histopathology is similar to celiac disease, except that there is a relative paucity of intraepithelial lymphocytes (43). Furthermore, most of the affected infants have no history of gluten injestion before the onset of diarrhea (11). In typical autoimmune enteropathy, duodenal biopsies show total villus atrophy, crypt hyperplasia and a dense lymphoplasmacytic infiltrate into the lamina propria (Figure 5 A). Intraepithelial lymphocytes are present in both the surface and crypt epithelia (Figure 5 B). Crypt abscesses are identified in severely affected cases. The lesions are not confined to the small bowel; similar changes can be seen in the stomach and colon in some children. Immunohistochemistry shows up to a tenfold increase in CD3-positive lymphocytes within the epithelium and lamina propria (Figure 5 C). The villus atrophy and crypt hyperplasia are both considered secondary features of an autoimmune-induced injury to the gut.

It is essential to exclude an underlying primary immune deficiency in infants considered to have autoimmune enteropathy. For instance, mutations in the gene encoding the CD3-gamma subunit of the T cell have been described in children with protracted diarrhea in infancy and features of autoimmunity (45).

## Pathogenesis

In infants with autoimmune enteropathy there is evidence of circulating systemic antibody against enterocytes. The autoantigen that the circulating antibody recognizes was initially not well defined, but investigators reported either a 55 kilodalton (46) or a 75 kilodalton protein (47,48). The autoantigen is encoded by a gene on chromosome 19p13 with homology to the tumor suppressor MCC (mutated in colon cancer) and, therefore, has been named MCC2 (49). Circulating antibody is present in low titer and reacts against normal enterocytes from various animal species, including mice and rats, as well as human intestine. Antibody levels decline or disappear in response to immune suppression therapy and the titer may correlate with the volume of stool output.

In an apparently related condition, the autoantibody is directed against goblet cells. In case reports, the circulating antibody binds to mucins in goblet cells (50). Histology of small bowel mucosa is characterized by an infiltration in the lamina propria of T cells accompanied by an absence of goblet cells, Paneth cells and enteroendocrine cells (50). In contrast to what is generally reported in autoimmune enteropathy, the surface epithelial cells in this condition are relatively intact. It is possible that this defect, which appears to involve secretory cell lineages, is a result of a defect in Math1 transcription factor. Math1 null mice demonstrate an absence of goblet, Paneth, and enteroendocrine cells while the enterocyte lineage is preserved (51).

## IPEX Syndrome

### *Presentation & Morphology*

IPEX refers to a condition characterized by immune dysregulation, polyendocrinopathy, enteropathy and


Copyright © Lippincott Williams & Wilkins. Unauthorized reproduction of this article is prohibited.

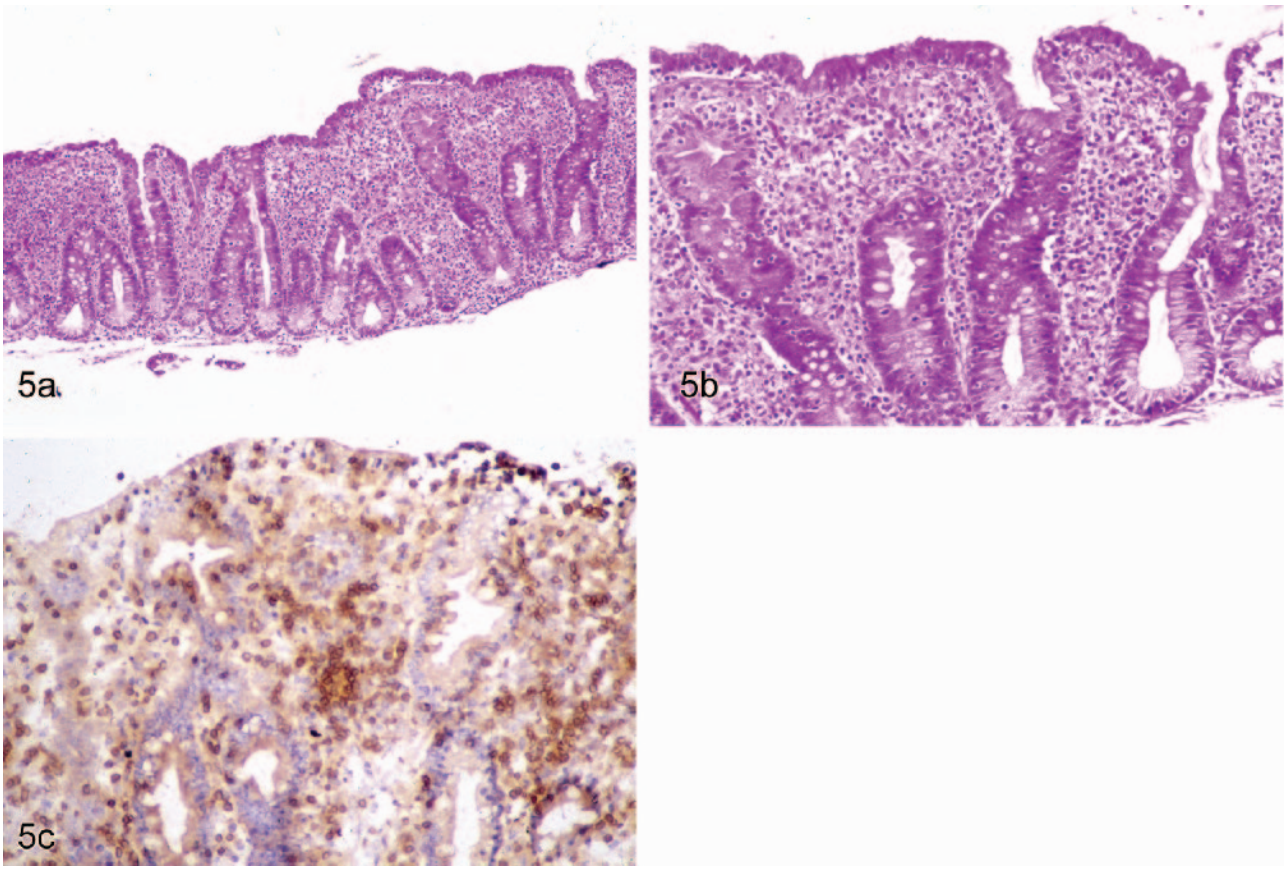


**FIG. 5.** Histopathologic features of autoimmune enteropathy. A: Jejunal biopsy obtained from a child with autoimmune enteropathy showing total villus atrophy, crypt hyperplasia and a marked mononuclear cell inflammatory infiltrate in the lamina propria (hematoxylin and eosin stain, approximate original magnification, X 80). B: Higher magnification view of surface and crypt epithelium with numerous intraepithelial lymphocytes (H & E, X 200). C: Immunohistochemistry using CD3 antibody demonstrates numerous CD3-positive cells infiltrating both the surface and crypt epithelia (immunoperoxidase stain, X 200). Reproduced with permission [to be obtained] from Reference #11.

X-linkage. The syndrome has many intestinal manifestations in common with autoimmune enteropathy, including villus atrophy with a marked infiltration into the lamina propria of activated T cells.

## Pathogenesis

The underlying genetic basis of the IPEX syndrome is a mutation of the FOXP3 gene (52,53). FOXP3, also referred to as scurfin, is a transcription factor involved in the proliferation of CD4+ T cells (54). The central role of FOXP3 in the development of regulatory T cells has been highlighted recently (55,56). Children considered to have autoimmune enteropathy who develop insulin-dependent diabetes mellitus, thyroid disease, eczematous ichthyosis or hemolytic anemia or who have a similarly effected sibling should be carefully tested for the FOXP3 mutation. A previous reports of brothers with unexplained protracted diarrhea beginning in early infancy and a number of circulating autoantibodies, including anti-enterocyte antibody (57), must be considered potentially to have mutations in the FOXP3 gene.

## Therapeutic Considerations

Nutritional support and provision of adequate hydration is of paramount importance to ensure optimal growth and development. Measurement of urine volume and urine sodium losses can prove helpful in ensuring sufficient fluid intake to maintain intravascular volume. For severely affected children, total parenteral nutrition must be instituted early. Dissecting the underlying etiology and providing targeted therapy should await nutritional rehabilitation. In other instances where there is less severe involvement of the gut, the use of elemental or low carbohydrate-containing formula can promote enteral delivery of calories and nutrients thereby avoiding the complications associated with parenteral alimentation (58).

Medications, including antisecretory agents (59,60) and trophic factors (61) have been used with variable


Copyright © Lippincott Williams & Wilkins. Unauthorized reproduction of this article is prohibited.

success. For autoimmune enteropathies, immune suppressive agents - including corticosteroids, cyclosporine (62,63), tacrolimus (64), infliximab (65), cyclophosphamide (66) and mycophenolate mofetil (67) – have been used with apparent benefit. In infants with microvillus inclusion disease and tufting enteropathy these options are usually unsuccessful and the long-term prognosis is more guarded. As a result, small bowel transplantation has been undertaken in these settings with promising results in a limited number of subjects (68,69). Isolated small bowel (70,71) and combined liver-intestinal transplantation (72,73) both have been successfully used in the management of children with microvillus inclusion disease.

For children with IPEX syndrome, a recent report indicates that allogeneic bone marrow transplant can be curative (74). Whether similar benefit can be obtained in a subset of severely affected patients with autoimmune enteropathy unresponsive to potent immune suppression should be determined in a carefully controlled clinical research setting. Development of an appropriate animal model would be of great benefit in determining the utility of bone marrow transplantation for affected infants and children.

## Conclusions & Future Directions

A concerted effort to define the molecular bases of microvillus inclusion disease, tufting enteropathy and autoimmune enteropathy is urgently required. This approach is ultimately much more likely to provide for rational therapy and appropriate prenatal testing compared with the empiric approach that has been undertaken to date. Given the low prevalence of these disorders, it is likely that a multicenter and multinational initiative - similar to the approach currently being taken to elucidate the etiology of inflammatory bowel diseases (75) - will be required to advance the field. No doubt, there are additional disease entities that cause protracted diarrhea in infants and young children awaiting description and definition. It is disappointing that so little progress has been made to date in undertaking genome-wide scanning in affected patients, their siblings and parents. An initiative led by the National Institutes for Health, or comparable funding agency, likely will be necessary (75). Affected children, their families and caretakers deserve no less.

**Acknowledgments:** Research activities of the authors are supported by operating grants from the Canadian Institutes for Health Research (CIHR). PMS is the recipient of a Canada Research Chair in Gastrointestinal Disease. DJM is the recipient of a Research Initiative Fellowship Award from CIHR-Industry (Canadian Association of Gastroenterology/Astra Zeneca Canada).

## REFERENCES

1. Fine KD, Schiller LR. AGA technical review on the evaluation and management of chronic diarrhea. *Gastroenterology* 1999;116: 1464–86.
2. Murch SH. Toward a molecular understanding of complex childhood enteropathies. *J Pediatr Gastroenterol Nutr* 2002;34:S4-S10.
3. Avery GB, Villavicencio O, Lilly JR, et al. Intractable diarrhea in early infancy. *Pediatrics* 1968;41:712–22.
4. Lo CW, Walker WA. Chronic protracted diarrhea of infancy: a nutritional disease. *Pediatrics* 1983;72:786–800.
5. Anonymous. Chronic diarrhoea in children: a nutritional disease. *Lancet* 1987;329:143–44.
6. Catassi C, Fabiani E, Spagnuolo MI, et al. Severe and protracted diarrhea: results of the 3-year SIGEP multicenter survey. *J Pediatr Gastroenterol Nutr* 1999;29:63–8.
7. Hoglund P, Holmberg C, Sherman P, et al. Distinct outcomes of chloride diarrhoea in two siblings with identical genetic background of the disease: implications for early diagnosis and treatment. *Gut* 2001;48:724–27.
8. Field M. Intestinal ion transport and the pathophysiology of diarrhea. *J Clin Invest* 2003;111:931–43.
9. Martin M, Silveira TR, Grand R, et al. Genetics of gastrointestinal and hepatobiliary disorders. *J Pediatr Gastroenterol Nutr* 2002; 35:S118-S127.
10. Goulet OJ, Brousse N, Canioni D, et al. Syndrome of intractable diarrhoea with persistent villous atrophy in early childhood: a clinicopathologic survey of 47 cases. *J Pediatr Gastroenterol Nutr* 1998;26:151–61.
11. Cutz E, Sherman PM, Davidson GP. Enteropathies associated with protracted diarrhea of infancy: clinicopathological features, cellular and molecular mechanisms. *Pediatr Pathol Lab Med* 1997;17: 335–68.
12. Rhoads JM, Vogler RC, Lacey SR, et al. Microvillus inclusion disease: in vitro jejunal electrolyte transport. *Gastroenterology* 1991;100:811–17.
13. Cutz E, Rhoads JM, Drumm B, et al. Microvillus inclusion disease: an inherited defect of brush-border assembly and differentiation. *N Engl J Med* 1989;320:646–51.
14. Kaneko K, Shimizu T, Fujiwara S, et al. Microvillous inclusion disease in Japan. *J Pediatr* 1999;135:400.
15. Pohl JF, Shub MD, Trevellin EE, et al. A cluster of microvillous inclusion disease in the Navajo population. *J Pediatr* 1999;134: 103–106.
16. Schofield DE, Agostini RM, Yunis EJ. Gastrointestinal microvillus inclusion disease. *Am J Clin Pathol* 1992;98:119–24.
17. Phillips AD, Schmitz J. Familial microvillous atrophy: a clinicopathological survey of 23 cases. *J Pediatr Gastroenterol Nutr* 1992;14:380–96.
18. Croft NM, Howatson AG, Ling SC, et al. Microvillous inclusion disease: an evolving condition. *J Pediatr Gastroenterol Nutr* 2000; 31:185–89.
19. Phillips AD, Szafranski M, Man L-Y, et al. Periodic acid-Schiff staining abnormality in microvillous atrophy: photometric and ultrastructural studies. *J Pediatr Gastroenterol Nutr* 2000;30:34–42.
20. Lake BD. Microvillus inclusion disease. Specific diagnostic features shown by alkaline phosphatase histochemistry. *J Clin Pathol* 1988;41:880–82.
21. Groisman GM, Ben-Izhak O, Schwersenz A, et al. The value of polyclonal carcinoembryonic antigen immunostaining in the diagnosis of microvillous inclusion disease. *Hum Pathol* 1993;24: 1232–37.
22. Groisman GM, Amar M, Livne E. CD10: a valuable tool for the light microscopic diagnosis of microvillous inclusion disease (familial microvillous atrophy) *Am J Surg Pathol* 2002;26:902–907.
23. Groisman GM, Sabo E, Meir A, et al. Enterocyte apoptosis and proliferation are increased in microvillous inclusion disease (familial microvillous atrophy). *Hum Pathol* 2000;31:1404–10.
24. Bell SW, Kerner Jr. JA, Sibley RK. Microvillous inclusion disease:


Copyright © Lippincott Williams & Wilkins. Unauthorized reproduction of this article is prohibited.

the importance of electron microscopy for diagnosis. *Am J Surg Pathol* 1991;15:1157–64.
25. Wilson W, Scott RB, Pinto A, et al. Intractable diarrhea in a newborn infant: microvillous inclusion disease. *Can J Gastroenterol* 2001;15:61–64.
26. Phillips AD, Jenkins P, Raafat F, et al. Congenital microvillous atrophy. Specific diagnostic features. *Arch Dis Childh* 1985;60: 135–40.
27. Raafat F, Green NJ, Nathavitharana KA, et al. Intestinal microvillous dystrophy: a variant of microvillous inclusion disease or a new entity? *Hum Pathol* 1994;25:1243–48.
28. Ameen NA, Salas PJI. Microvillus inclusion disease: a genetic defect affecting apical membrane protein traffic in intestinal epithelium. *Traffic* 2000;1:76–83.
29. Michail S, Collins JF, Xu H, et al. Abnormal expression of brush-border membrane transporters in the duodenal mucosa of two patients with microvillus inclusion disease. *J Pediatr Gastroenterol Nutr* 1998;27:536–42.
30. Achler C, Filmer D, Merte C, et al. Role of microtubules in polarized delivery of apical membrane proteins to the brush border of the intestinal epithelium. *J Cell Biol* 1989;109:179–89.
31. Reinshagen K, Naim HY, Zimmer K-P. Autophagocytosis of the apical membrane in microvillus inclusion disease. *Gut* 2002;51: 514–21.
32. Nelson WJ. Adaptation of core mechanisms to generate cell polarity. *Nature* 2003;422:766–74.
33. Mostov K, Zegus M. Just mix and patch. *Nature* 2003;422:267–68.
34. Abely M, Hankard GF, Hugot JP, et al. Intractable infant diarrhea with epithelial dysplasia associated with polymalformation. *J Pediatr Gastroenterol Nutr* 1998;27:348–52.
35. Cameron DJS, Barnes GL. Successful pregnancy outcome in tufting enteropathy. *J Pediatr Gastroenterol Nutr* 2003;36:158.
36. Reifen RM, Cutz E, Griffiths AM, et al. Tufting enteropathy: a newly recognized clinicopathological entity associated with refractory diarrhea in infants. *J Pediatr Gastroenterol Nutr* 1994;18: 379–385.
37. Patey N, Scoazec JY, Cuenod-Jabri B, et al. Distribution of cell adhesion molecules in infants with intestinal epithelial dysplasia (tufting enteropathy). *Gastroenterology* 1997;113:833–43.
38. Goulet O, Kedinger M, Brousse N, et al. Intractable diarrhea of infancy with epithelial and basement membrane abnormalities. *J Pediatr* 1995;127:212–19.
39. Boudreau N, Werb Z, Bissell MJ. Suppression of apoptosis by basement membrane requires three-dimensional tissue organization and withdrawal from the cell cycle. *Proc Natl Acad Sci* (USA) 1996;93:3509–3513.
40. Ruoslahti E, Reed JC. Anchorage dependence, integrins, and apoptosis. *Cell* 1994;77:477–78.
41. Lachaux A, Bouvier R, Loras-Duclaux I, et al. Isolated deficient alpha6beta4 integrin expression in the gut associated with intractable diarrhea. *J Pediatr Gastroenterol Nutr* 1999;29:395–401.
42. Ng AY-N, Waring P, Ristevski S, et al. Inactivation of the transcription factor Elf3 in mice results in dysmorphogenesis and altered differentiation of intestinal epithelium. *Gastroenterology* 2002;122:1455–66.
43. Cuenod B, Brousse N, Goulet O, et al. Classification of intractable diarrhea in infancy using clinical and immunohistological criteria. *Gastroenterology* 1990;99:1037–43.
44. Murch SH, Fertleman CR, Rodriques C, et al. Autoimmune enteropathy with distinct mucosal features in T-cell activation deficiency: the contribution of T cells to the mucosal lesion. *J Pediatr Gastroenterol Nutr* 1999;28:393–99.
45. Arnaiz-Villena A, Timon M, Corell A, et al. Primary immunodeficiency caused by mutations in the gene encoding the CD3-gamma subunit of the T-lymphocyte receptor. *N Engl J Med* 1992; 327:529–33.
46. Colletti RB, Guillot AP, Rosen S, et al. Autoimmune enteropathy and nephropathy with circulating anti-epithelial cell antibodies. *J Pediatr* 1991;118:858–64.
47. Kobayashi I, Imamura K, Yamada M, et al. A 75-kD autoantigen recognized by sera from patients with X-linked autoimmune enteropathy associated with nephropathy. *Clin Exp Immunol* 1998; 111:527–31.
48. Kobayashi I, Imamura K, Kubota M, et al. Identification of an autoimmune enteropathy-related 75-kilodalton antigen. *Gastroenterology* 1999;117:823–30.
49. Ishikawa S, Kobayashi I, Hamada J-I, et al. Interaction of MCC2, a novel homologue of MCC tumor suppressor, with PDZ-domain protein AIE-75. *Gene* 2001;267:101–10.
50. Moore L, Xu X, Davidson G, et al. Autoimmune enteropathy with anti-goblet cell antibodies. *Hum Pathol* 1995;26:1162–68.
51. Yang Q, Bermingham NA, Finegold MJ, et al. Requirement of Math1 for secretory cell lineage commitment in the mouse intestine. *Science* 2001;294:2155–58.
52. Bennett CL, Christie J, Ramsdell F, et al. The immune dysregulation, polyendocrinopathy, enteropathy, X-linked syndrome (IPEX) is caused by mutations of FOXP3. *Nature Genet* 2001;27:20–21.
53. Wildin RS, Ramsdell F, Peaker J, et al. X-linked neonatal diabetes, enteropathy and endocrinopathy syndrome is the human equivalent of mouse scurfy. *Nature Genet* 2001;27:18–20.
54. Patel DD. Escape from tolerance in the human X-linked autoimmunity-allergic dysregulation syndrome and the Scurfy mouse. *J Clin Invest* 2001;107:155–57.
55. Fontenot JD, Gavin MA, Rudensky AY. Foxp3 programs the development and function of CD4+CD25+ regulatory T cells. *Nature Immunol* 2003;4:330–36.
56. Hori S, Nomura T, Sakaguchi S. Control of regulatory T cell development by the transcription factor Foxp3. *Science* 2003;299: 1057–61.
57. Lachaux A, Bouvier R, Cozzani E, et al. Familial autoimmune enteropathy with circulating anti-bullous pemphigoid antibodies and chronic autoimmune hepatitis. *J Pediatr* 1994;125:858–62.
58. Lifschitz CH, Carrazza F. Effect of formula carbohydrate concentration on tolerance and macronutrient absorption in infants with severe, chronic diarrhea. *J Pediatr* 1990;117:378–91.
59. Owyang C. Treatment of chronic secretory diarrhea of unknown origin by lithium carbonate. *Gastroenterology* 1984;87:714–18.
60. Bisset WM, Jenkins H, Booth I, et al. The effect of somatostatin on small intestinal transport in intractable diarrhea of infancy. *J Pediatr Gastroenterol Nutr* 1993;17:169–75.
61. Drumm B, Cutz E, Tomkins B, et al. Urogastrone/epidermal growth factor in treatment of congenital microvillous atrophy. *Lancet* 1988;331:111–112.
62. Seidman EG, Lacaille F, Russo P, et al. Successful treatment of autoimmune enteropathy with cylcosporine. *J Pediatr* 1990;117: 929–32.
63. Sanderson IR, Phillips AD, Spencer J, et al. Response to autoimmune enteropathy to cyclosporin A therapy. *Gut* 1991;32:1421–25.
64. Bousvaros A, Leichtner AM, Book L, et al. Treatment of pediatric autoimmune enteropathy with tacrolimus (FK506). *Gastroenterology* 1996;111:237–43.
65. Vanderhoof JA, Young RJ. Autoimmune enteropathy in a child: response to infliximab therapy. *J Pediatr Gastroenterol Nutr* 2002; 34:312–16.
66. Oliva-Hemker MM, Loeb DM, Abraham SC, et al. Remission of severe autoimmune enteropathy after treatment with high-dose cyclophosphamide. *J Pediatr Gastroenerol Nutr* 2003;36:639–43.
67. Quiros-Tejeira R, Ament ME, Vargas JH. Induction of remission in a child with autoimmune enteropathy using mycophenolate mofetil. *J Pediatr Gastroenterol* Nutr 2003;36:482–85.
68. Lacaille F, Cuenod B, Colomb V, et al. Combined liver and small bowel transplantation in a child with epithelial dysplasia. *J Pedatr Gastroenterol Nutr* 1998;27:230–33.
69. Paramesh AS, Fishbein T, Tschernia A, et al. Isolated small bowel transplantation for tufting enteropathy. *J Pediatr Gastroenterol Nutr* 2003;36:138–40.



Copyright © Lippincott Williams & Wilkins. Unauthorized reproduction of this article is prohibited.

70. Bunn SK, Beath SV, McKeirnan PJ, et al. Treatment of microvillus inclusion disease by intestinal transplantation. *J Pediatr Gastroenterol Nutr* 2000;31:176–80.
71. Oliva MM, Perman JA, Saavedra JM, et al. Successful intestinal transplantation for microvillus inclusion disease. *Gastroenterology* 1994;106:771–74.
72. Randak C, Langnas AN, Kaufman SS, et al. Pretransplant management and small bowel-liver transplantation in an infant with microvillus inclusion disease. *J Pediatr Gastroenterol* 1998;27: 333–37.
73. Herzog D, Atkison P, Grant D, et al. Combined bowel-liver transplantation in an infant with microvillus inclusion disease. *J Pediatr* Gastro*enterol Nutr* 1996;22:405–408.
74. Baud O, Goulet O, Canioni D, et al. Treatment of the immune dysregulation, polyendocrinopathy, enteropathy, X-linked syndrome (IPEX) by allogeneic bone marrow transplantation. *N Engl J Med* 2001;344:1758–62.
75. Collins SM, McHugh K, Croitoru K, et al. The establishment of a national tissue bank for inflammatory bowel disease research in Canada. *Can J Gastroenteorol* 2003;17:107–109.

# Clinical Quiz

Joel R. Lim, Joseph F. Fitzgerald, and John M. Dewitt, Contributors

*Division of Pediatric Gastroenterology, Hepatology, and Nutrition, James Whitcomb Riley Hospital for Children, Indiana University School of Medicine, Indianapolis, Indiana, U.S.A.*

## CASE HISTORY

A 17-year-old girl presented with a 3-month history of severe, episodic, epigastric pain that radiated to her upper back. The pain was accompanied by nausea and occasional vomiting, which was nonbilious and nonbloody. The pain initially occurred once weekly but progressed to two times a week. The pain was described as sharp, often following a meal, and unrelated to bowel movements. The patient reported no constipation or diarrhea. The pain did not awaken her at night. There had been a documented 6-kg weight loss. There was no history of abdominal trauma. The patient's medical history was unremarkable. Her family history revealed that her maternal grandmother had diverticulitis, and her mother and paternal uncle had had cholecystectomies because of cholecystitis. There was no family history of pancreatic disease. Results of initial blood screening studies were normal.

The patient was referred to our service after a contrast radiographic study of her upper gastrointestinal tract and an abdominal computed tomography scan revealed a mass within the third portion of the duodenum. Physical examination showed a well-developed, well-nourished teenager (body mass index, 75%–85%) who was in no distress. Vital signs were normal. Her sclerae were anicteric. Her abdomen was not distended but was tender in the low epigastrium on deep palpation. There was no hepatomegaly or splenomegaly, and no masses were palpated. There were no abdominal bruits or friction rubs. There was no active anal disease, and digital examination of the rectum revealed a normal rectal vault with no stool present. She had no peripheral edema.

Upper intestinal endoscopy and endoscopic ultrasound examination of the duodenum were performed (Fig. 1, A & B).

What is your diagnosis?

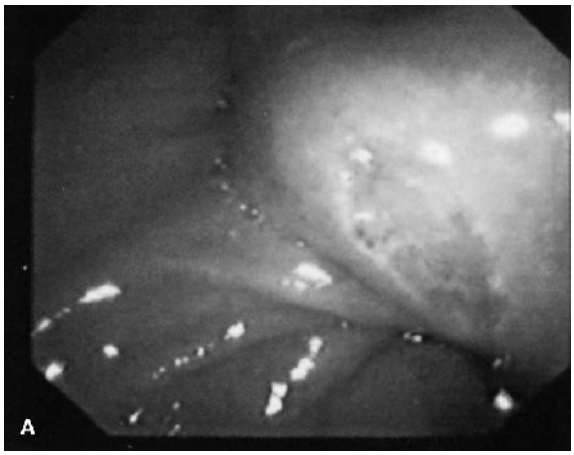


**(A)** Third portion of the duodenum.

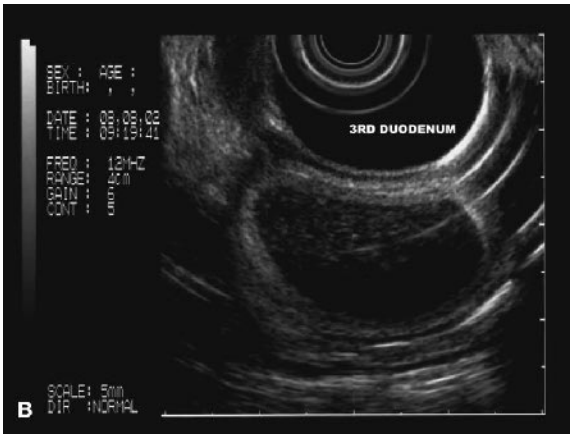


**(B)** Endoscopic ultrasound.

*ANSWER: See page 000.*


Copyright © Lippincott Williams & Wilkins. Unauthorized reproduction of this article is prohibited.