Different effects of pimecrolimus and betamethasone on the skin barrier in patients with atopic dermatitis

Jens-Michael Jensen, MD,[a] Stephan Pfeiffer, Dipl Ing,[b] Magdalena Witt, MD,[a] Matthias Bräutigam, MD,[c] Claudia Neumann, BTA,[a] Michael Weichenthal, MD,[a] Thomas Schwarz, MD,[a] Regina Fölster-Holst, MD,[a] and Ehrhardt Proksch, MD, PhD[a] *Kiel, Flintbek, and Nuremberg, Germany*

Background: Genetic defects leading to skin barrier dysfunction were recognized as risk factors for atopic dermatitis (AD). It is essential that drugs applied to patients with AD restore the impaired epidermal barrier to prevent sensitization by environmental allergens.
Objectives: We investigated the effect of 2 common treatments, a calcineurin inhibitor and a corticosteroid, on the skin barrier.
Methods: In a randomized study 15 patients with AD were treated on one upper limb with pimecrolimus and on the other with betamethasone twice daily for 3 weeks.
Results: Stratum corneum hydration and transepidermal water loss, a marker of the inside-outside barrier, improved in both groups. Dye penetration, a marker of the outside-inside barrier, was also reduced in both drugs. Electron microscopic evaluation of barrier structure displayed prevalently ordered stratum corneum lipid layers and regular lamellar body extrusion in pimecrolimus-treated skin but inconsistent extracellular lipid bilayers and only partially filled lamellar bodies after betamethasone treatment. Both drugs normalized epidermal differentiation and reduced epidermal hyperproliferation. Betamethasone was superior in reducing clinical symptoms and epidermal proliferation; however, it led to epidermal thinning.
Conclusion: The present study demonstrates that both betamethasone and pimecrolimus improve clinical and biophysical parameters and epidermal differentiation. Because pimecrolimus improved the epidermal barrier and did not cause atrophy, it might be more suitable for long-term treatment of AD. (J Allergy Clin Immunol 2009;123:1124-33.)

Key words: *Atopic dermatitis, skin barrier, pimecrolimus, corticosteroid, skin penetration*

Abbreviations used
AD: Atopic dermatitis
pEASI: Partial Eczema Area and Severity Index
TEWL: Transepidermal water loss

Atopic dermatitis (AD) is a complex disease arising from an interaction between genetic and environmental factors.[1-3] It was recently demonstrated that functional mutations in the epidermal differentiation complex gene filaggrin are strong risk factors for AD and asthma.[4-7] In particular, patients with filaggrin mutations are predisposed to early-onset and extrinsic AD.[7] Attention has therefore been drawn to disturbed epidermal differentiation and impaired epidermal barrier function, which appear to be hallmark features of AD.[8-14] Because a disturbed barrier allows penetration of allergens into the skin and consequent sensitization, these observations suggest that epidermal barrier disruption is not secondary to immunologic reaction but might be primary in patients with AD, supporting the concept of a disturbed outside-inside barrier.[15-20]

The majority of patients with AD in adulthood exhibit increased serum IgE levels and sensitization to aeroallergens and food allergens (extrinsic AD). Extrinsic AD is less common in early childhood but increases with age.[21,22] IgE-mediated sensitization might be of crucial importance in the development of AD.[23] An immune system deviation shifting toward a T_H2 response has long been considered the major pathogenic event in AD.[1,2,24]

Recent treatment strategies for AD have focused on immune intervention. The development of the calcineurin inhibitors is one offspring of this development.[25] Studies have revealed quite remarkable differences between the older and newer generations of AD treatments. Corticosteroids, but not calcineurin inhibitors, have been shown to negatively affect viability, maturation, and immune function of murine and human epidermal Langerhans cells.[26,27] This suggests that the prolonged use of corticosteroids could have adverse effects on epidermal immune cells.

Considering the novel appreciation of the epidermal barrier in the pathogenesis of AD, future developments in AD treatment might focus on restoration of the epidermal barrier. Likewise, it is important to know how topical drugs already used in AD treatment affect the epidermal barrier. We therefore investigated whether topical application of calcineurin inhibitors and corticosteroids, 2 frequently used medications for atopic skin, differ in their effects on the epidermal barrier.

METHODS

Patients and treatment regimens

Fifteen patients with mild-to-moderate AD (according to Hanifin and Rajka criteria) and a target lesion score of 3 to 8 (on a scale of 0-12) for both right and left target lesions, and symmetric AD lesions (not differing >1 point between the right and left sides) affecting the upper limbs by at least 10% were treated

From [a]the Department of Dermatology, University of Kiel; [b]Microscopy Services, Flintbek; and [c]Novartis Pharma GmbH, Clinical Research, Nuremberg.

Supported by grants of the Deutsche Forschungsgemeinschaft (SFB415/B2 and SFB617/A7, A21) and Novartis Pharma, Nürnberg (Germany), given to E. Proksch and J.-M. Jensen. T. Schwarz and E. Proksch have acted as consultants to Novartis. M. Bräutigam is employed by Novartis.

Disclosure of potential conflict of interest: J.-M. Jensen has received a travel grant from Novartis. T. Schwarz has received grants from Novartis and Therakos and has served as an advisor for Novartis. The rest of the authors have declared that they have no conflict of interest.

Received for publication November 26, 2008; revised March 24, 2009; accepted for publication March 26, 2009.

Reprint requests: Ehrhardt Proksch, MD, PhD, Department of Dermatology, University of Kiel, Schittenhelmstr. 7, 24105 Kiel, Germany. E-mail: eproksch@dermatology.uni-kiel.de.

0091-6749/$36.00
© 2009 American Academy of Allergy, Asthma & Immunology
doi:10.1016/j.jaci.2009.03.032

twice daily for 3 weeks on 1 upper limb with 1% pimecrolimus cream and on the other upper limb with 0.1% betamethasone valerate cream in a double-blind manner. Follow-up observation was continued for 1 additional week. No systemic treatment for AD was allowed. Emollients for the treatment of AD and other non-pharmaceutical interventions were allowed as normal practice only on nontarget lesions and monitored by the investigator. The study was approved by the local ethics commission and the German Federal Institute for Pharmaceuticals and Medical Products (EudraCT-Nr. 2004-004824-11, Bundesinstitut für Arzneimittel und Medizinprodukte).

Clinical assessment

The partial Eczema Area and Severity Index (pEASI), with which only the upper limbs were evaluated, was used to assess disease severity. Each symptom (erythema, infiltration/induration, excoriation, and lichenification) was given a score ranging from 0 (none) to 3 (severe). Assessment was performed on days 1, 8, 15, 22, and 29 (1 week after the end of the treatment period) separately for both of the upper limbs. Patients recorded their pruritus symptoms on diary cards according to a visual analog scale (range, 1-10).

Biophysical measurements of stratum corneum hydration and transepidermal water loss

Water content of the stratum corneum and transepidermal water loss (TEWL), a marker for the inside-outside barrier, were determined at each visit in both lesional and nonlesional skin by using the Corneometer and the Tewameter TM210 (both Courage & Khazaka, Cologne, Germany) in all patients. Stratum corneum hydration was expressed in preset Corneometer units.[28] We performed measurements for stratum corneum hydration and TEWL in accordance with the guidelines of the Standardization Group of the European Contact Dermatitis Society.[29] Each value was the average of 3 measurements. During the course of all measurements, relative environmental humidity was 45% ± 2%, and temperature was 22°C ± 1°C.

Dye penetration

In a separate study with a different set of patients using the same inclusion criteria, lesional AD skin in 4 patients was treated for 3 weeks with pimecrolimus or corticosteroid, as previously described. Skin from 15 healthy volunteers served as a control sample. The dye gentian violet (30 μL, 0.1%) was applied to a paper carrier on the skin. After 60 seconds, the paper carrier was removed, excess dye on the skin was removed by rinsing with water, and the color intensity of the staining was determined with the Minolta Chroma Meter (Konica Minolta, Tokyo, Japan). Measurements (b*-mode) were taken 15 minutes after application (for drying of the dye) and after 10 hours.[30] Color intensity decreased according to the penetration of the dye into the skin.

Histologic analysis

Five-millimeter punch biopsy specimens from representative lesional areas were taken on day 1 (before treatment) from one upper limb and on day 22 (end of the treatment) from both upper limbs (treated either with pimecrolimus or betamethasone cream) from the first 5 study patients. Samples were used for light microscopy, immunohistochemistry, and ultrastructural analysis.

Immunohistochemistry and proliferation assay

Skin samples were fixed in formalin and embedded in paraffin. After deparaffinization and rehydration, 5-μm-thick sections were incubated with 3% H_2O_2 for 5 minutes to block endogenous peroxidase activity, and the rinsed sections were exposed to 5 × 5 minutes of microwave irradiation (650 W) for antigen retrieval, according to the method of Hazelbag et al.[31] After blocking nonspecific antibody binding by means of incubation with 20% normal pig serum (DAKO, Hamburg, Germany), the primary antibodies (anti-Ki-67, anti-involucrin, anti-loricrin, anti-filaggrin, and anti-keratin 6, 10, 14, 16, and 17) were applied.[14] A strep-AB-complex/HRP (DAKO, Hamburg, Germany) was used as a third antibody, followed by incubation with diaminobenzidine as peroxidase substrate. Slides incubated with the Ki-67 antibody were examined microscopically (×160 magnification) by counting the labeled nuclei of interfollicular keratinocytes in 7 microscopic fields per section.

Chemical fixation and ultramicrotomy for transmission electron microscopy

Skin samples were prefixed overnight in modified Karnovsky medium at 4°C, washed twice with 0.2 mol/L sodium cacodylate buffer for 10 minutes, and postfixed with 1% (wt/vol) OsO_4 or RuO_4 in 0.133 mol/L sodium cacodylate buffer containing 0.5% (wt/vol) $K_4Fe(CN)_6$ at 4°C for 45 minutes.[32] Specimens were dehydrated in ethanol and embedded in Epon 812 (Plano, Wetzlar, Germany).[33] Polymerization was carried out overnight at 60°C. Thin sections were cut with a Reichert Jung Ultracut S microtome with a diamond knife (Diatome, Nidau, Switzerland), counterstained with uranyl acetate and lead citrate,[34] and examined in a TEM 910 (Zeiss, Oberkochen, Germany). OsO_4 fixation was used to show lamellar body extrusion, and RuO_4 was used to show stratum corneum lipid bilayers. More than 200 lamellar bodies were analyzed for quantification. The percentage of accumulated, unextruded lamellar bodies in patients with AD after treatment with betamethasone versus pimecrolimus was counted, and the numbers were presented as a percentage.

Statistical analysis

Statistical analyses were carried out with SPSS (version 9.0; SPSS GmbH, Munich, Germany) and SAS (version 8.2; SAS, Inc, Cary, NC) software. Descriptions contain the mean or median values for groups as appropriate by distribution of data together with their SD or 95% CI, respectively. Statistical analysis of group differences was performed by using the 2-tailed Student *t* test or nonparametric *U* test (Wilcoxon/Mann-Whitney), as appropriate. A *P* value of less than .05 was considered statistically significant.

RESULTS

Clinical assessment and stratum corneum hydration

Clinical assessments were performed before the treatment period (day 1), during the treatment period (days 8, 15, and 22), and after a 1-week follow-up period (day 29) to correlate clinical response with possible alterations in skin barrier function. On day 8, considerable clinical improvement was seen after treatment with both betamethasone and pimecrolimus, as assessed by using the pEASI, which includes erythema, infiltration, excoriation, and lichenification. Symptoms of patients treated with betamethasone continued to improve over the entire treatment period (Fig 1, *A*). Pruritus decreased significantly after 1 week of treatment by 2.4 visual score points in the betamethasone arm ($P = .0015$) and by 2.6 points in the pimecrolimus arm ($P = .0003$). After 2 and 3 weeks, both groups showed further slight improvement in pruritus. Improvement in pruritus was quite similar after both treatments, but slightly better values were obtained for betamethasone compared with pimecrolimus. After termination of treatment, pruritus reduction was sustained for several days longer in the betamethasone group than in the pimecrolimus group (Fig 1, *B*).

Reduced stratum corneum hydration is found in atopic lesional and nonlesional skin.[14,35] Dry skin predisposes to pruritus. Therefore we examined the effect of both treatments on hydration. Stratum corneum hydration in lesional skin increased slightly, but not significantly, after 1 week of treatment with pimecrolimus but not with betamethasone. Hydration increased after 2 and 3 weeks with both preparations, but there was no statistically significant difference between the drugs. During the 1-week follow-up period, hydration remained almost constant in the pimecrolimus group, whereas it showed a nonsignificant tendency to decrease in the betamethasone group (Fig 1, *C*).

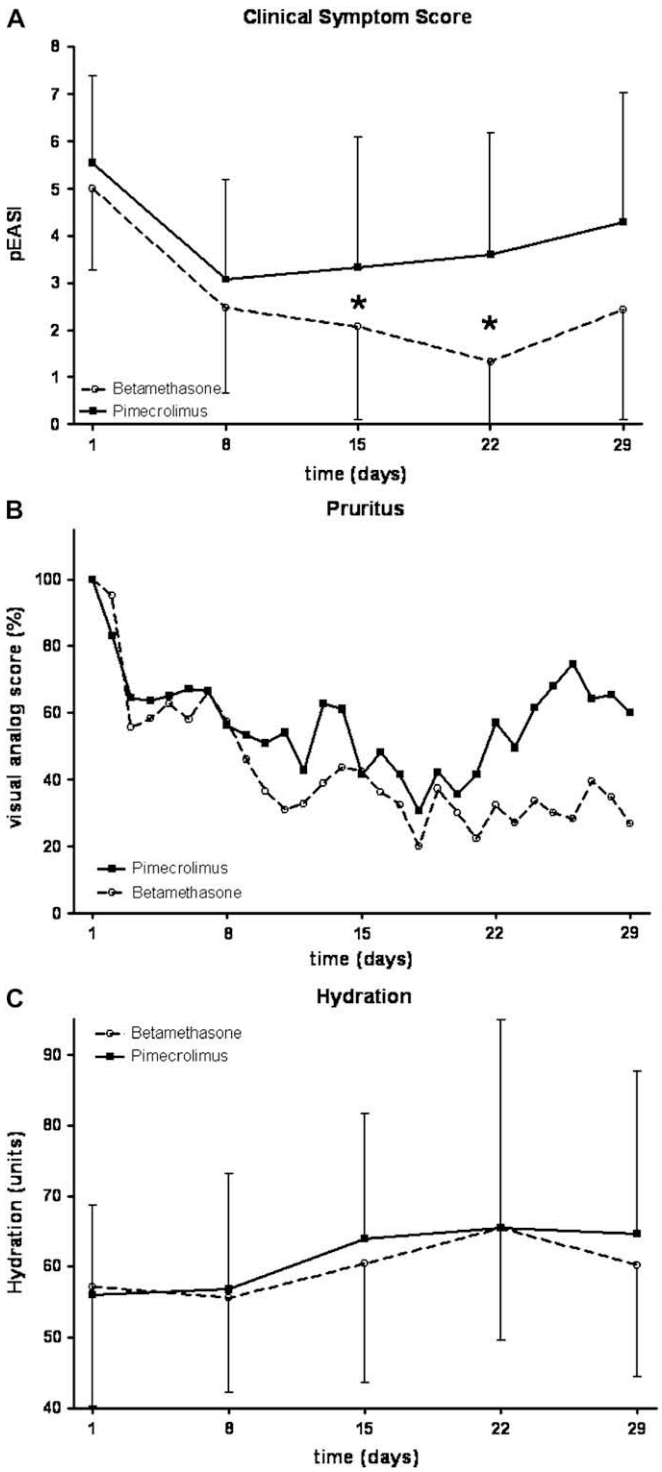

FIG 1. Clinical scoring, pruritus, and stratum corneum hydration were assessed before the treatment period (day 1), during the treatment period of 3 weeks (days 8, 15, and 22), and after the 1-week follow-up period (day 29). Clinical scoring was performed by using the pEASI, with only the upper limbs evaluated **(A)**. Pruritus was evaluated based on patients' self-reporting of their pruritus symptoms on diary cards according to a visual analog scale (range, 1-10; **B**). Stratum hydration was evaluated by using biophysical measurements obtained with a Corneometer **(C)**. *Error bars* represent the mean ± SD.

TEWL and dye penetration

TEWL is a marker of the inside-outside barrier. Increased TEWL values are reported in the nonlesional and lesional skin of patients with AD.[14] In patients with lesional AD, TEWL was reduced after 1 week of treatment in both the betamethasone (P = .002) and pimecrolimus (P = .01) groups. In the pimecrolimus group no further reduction was seen after 2 and 3 weeks of treatment. In the betamethasone group TEWL values continued to decrease (Fig 2, *A*).

Dye penetration is a marker of the outside-inside barrier.[30] A significantly lower value in Chroma Meter reading was measured in patients with untreated AD after 10 hours compared with that seen at time point zero, indicating a significant dye penetration caused by a disrupted outside-inside barrier. Dye penetration was significantly reduced by betamethasone and even more so by pimecrolimus treatment compared with that seen in untreated control skin. There was no significant difference between the pimecrolimus and betamethasone groups. In healthy skin no dye penetration occurred (Fig 2, *B*).

Epidermal proliferation and thickness

Increased epidermal proliferation was previously observed in patients with AD[14] and confirmed in this study. A set of age- and sex-matched healthy patients served as control subjects. Immunohistochemical evaluation of the expression of the proliferation marker Ki-67 in keratinocytes revealed substantially reduced proliferation rates after 3 weeks of treatment with both drugs. Effects were less pronounced after pimecrolimus treatment than after betamethasone treatment (Fig 3, *A*). The suppression of epidermal proliferation led to a significant reduction of epidermal thickness by 49% in the pimecrolimus group to a value within the normal range for healthy skin. The betamethasone group showed an even more significant high reduction of epidermal thickness by 74% to a value less than that seen in healthy skin (Fig 3, *B*).

Epidermal differentiation

Disturbed epidermal differentiation is a hallmark feature of epidermal alterations in patients with AD.[14] In this study we found that disturbed differentiation was normalized by both treatments. The broadened band for involucrin staining in lesional AD skin was reduced to a small band in the upper spinous and granular layers (Fig 4). This effect was slightly more pronounced in the betamethasone group than in the pimecrolimus group. Epidermal thinning resulting from corticosteroid treatment might have contributed to this finding. Loricrin was only focally expressed in patients with AD. After treatment with both betamethasone and pimecrolimus, the entire granular layer was stained with the anti-loricrin antibody, indicating homogenous re-expression. Expression of filaggrin was also focally reduced in patients with AD but completely restored on treatment with either betamethasone or pimecrolimus. Staining of the basal keratins K5 and K14, which was extended to the spinous layer in AD lesional skin, was reduced after both treatments but still clearly visible in the suprabasal layers (Fig 4). In untreated AD skin the suprabasal keratin K10 was also expressed in the mid and lower parts of the spinous layer. This broad expression was reduced by treatment with both betamethasone and pimecrolimus. Focal expression of hyperproliferation-associated keratin K16 in lesional AD skin was reduced or absent after both treatments (Fig 4). Expression of the

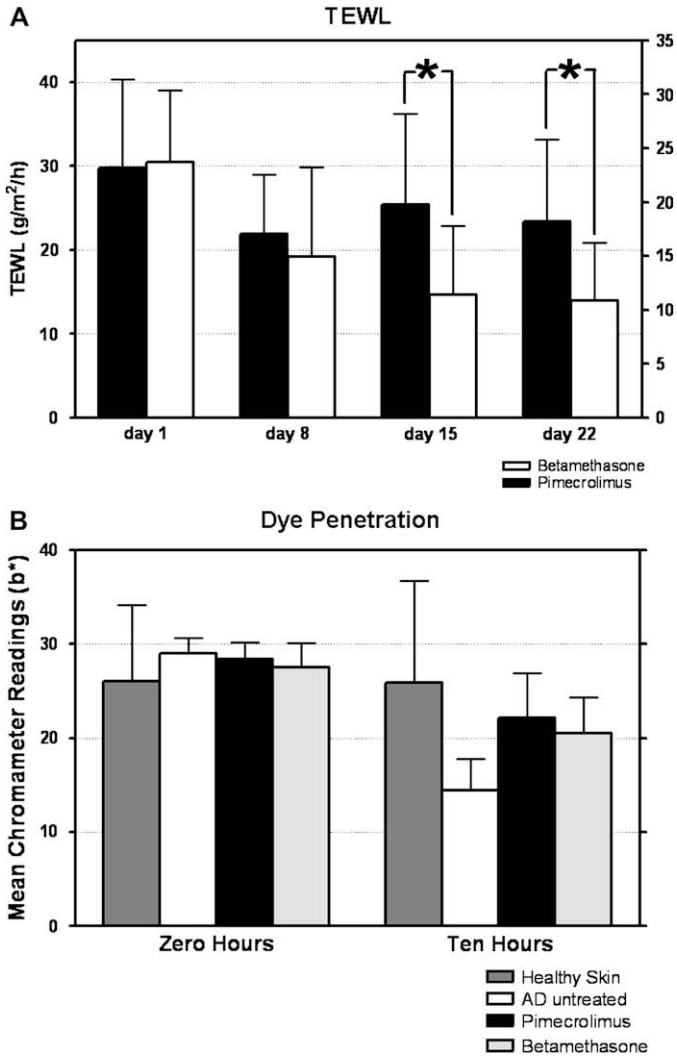

FIG 2. TEWL and dye penetration. TEWL was evaluated based on biophysical measurements obtained with a Tewameter. TEWL values were assessed on skin lesions of both upper limbs. Measurements were taken in triplicates **(A)**. In a separate study with a different set of patients (selected with identical inclusion and exclusion criteria as those of the main study), after 3 weeks of treatment of lesional AD with pimecrolimus or corticosteroid, the dye gentian violet was applied, and the color intensity was determined with a Minolta Chroma Meter immediately and after 10 hours. Color intensity was reduced after 10 hours because of penetration of the dye into the skin. In healthy (control and untreated) skin no penetration of the dye occurred. Compared with untreated AD lesional skin, a substantial reduction in dye penetration after treatment with both pimecrolimus and betamethasone occurred **(B)**. Values are presented as the means ± SDs.

inflammation-associated keratin K17 was only slightly reduced after both treatment regimens (data not shown).

Skin barrier structure and lamellar body extrusion evaluated by means of transmission electron microscopy

Stratum corneum structure is crucial for skin barrier function. Stratum corneum barrier structure, including the extrusion of lamellar body content, can be visualized by means of transmission electron microscopy. After pimecrolimus treatment, formation of regular and continuous extracellular lipid bilayer structures were noted (Fig 5, *A*, *arrows*). After betamethasone treatment, skin barrier structure and lipid bilayer formation were highly irregular, and the lipid layers were disrupted (Fig 5, *B*, *arrow heads*). Clear, multilayered lipid bilayers at the stratum granulosum/stratum corneum interface were only rarely found (Fig 5, *B*, *arrows*).

After pimecrolimus treatment, lamellar body extrusion was normal. Lamellar bodies were predominantly filled with lamellar lipid layers and were more frequently bound to the cell membranes of the keratinocytes at the transition zone between stratum granulosum and stratum corneum (Fig 5, *C*, *arrows*). In contrast, in betamethasone-treated skin lamellar bodies in the upper stratum granulosum were often empty or only partially filled. Also, the size of the lamellar bodies was reduced compared with those seen in pimecrolimus-treated skin. Intracellular accumulation of lamellar bodies was observed before their fusion with cell membranes (Fig 5, *D*, *arrowheads*). Also, intracellular lamellar deposits were frequently seen in corneocytes.

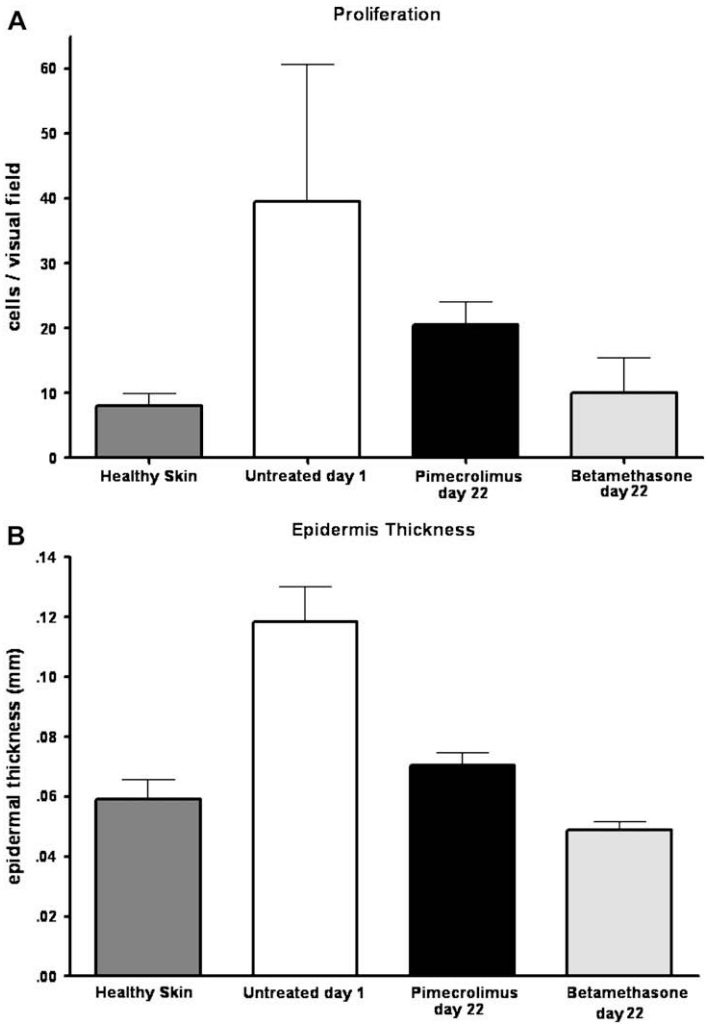

FIG 3. Proliferation rate and epidermal thickness. Epidermal proliferation was determined immunohistologically with the Ki-67 antibody, and epidermal thickness was determined histologically. A set of age- and sex-matched healthy patients served as control subjects. Both treatment regimens reduce proliferation rate (pimecrolimus, $P = .08$; betamethasone, $P < .05$; n = 5; **A**). Significant reduction in epidermal thickness appeared in both treatment groups, whereas betamethasone treatment achieved levels less than those of healthy skin ($P < .05$ and n = 5, respectively; **B**). Values are presented as the mean ± SD.

Quantification of transmission electron microscopic findings revealed 91% physiologic lamellar bodies in healthy skin and 9% physiologic lamellar bodies in AD lesional skin. After treatment with betamethasone, only 9% physiologic lamellar bodies were noted, as in untreated AD. In contrast, 82% physiologic lamellar bodies were found after pimecrolimus treatment (Fig 6, *A*). When we examined the number of accumulated, unextruded (cytoplasmic) lamellar bodies in the upper stratum granulosum, we found 43% accumulated lamellar bodies after betamethasone treatment compared with 20% accumulated lamellar bodies after pimecrolimus treatment (Fig 6, *B*). Because of the complexity of the method, only 3 sample sets could be evaluated in this study. Therefore the results are not subject to formal statistical evaluation.

DISCUSSION

It has now become clear that defects in the epidermal barrier might be as important as immune dysregulation, which has long been considered the primary cause of AD. It has recently been proposed that inflammation in patients with AD results from inherited and acquired insults to the barrier, and the therapeutic implications of this paradigm have been discussed.[36] Repair of the epidermal barrier might become an important objective in the development of new drugs for the treatment of AD. Hence it is of central importance to understand how drugs already in use address both the epidermal and immunologic aspects of the disease. Topical corticosteroids and calcineurin inhibitors both clinically improve AD and exert anti-inflammatory effects but differ greatly in their modes of action. Remarkable differences in the effects of corticosteroids and pimecrolimus on skin immune responses and antigen-presenting function of Langerhans cells have been described.[27,37]

Thus we evaluated skin barrier function, stratum corneum structure, epidermal proliferation, and differentiation in patients with AD after treatment with pimecrolimus compared with betamethasone. Pimecrolimus and betamethasone ameliorated clinical parameters of AD. pEASI scoring improved significantly

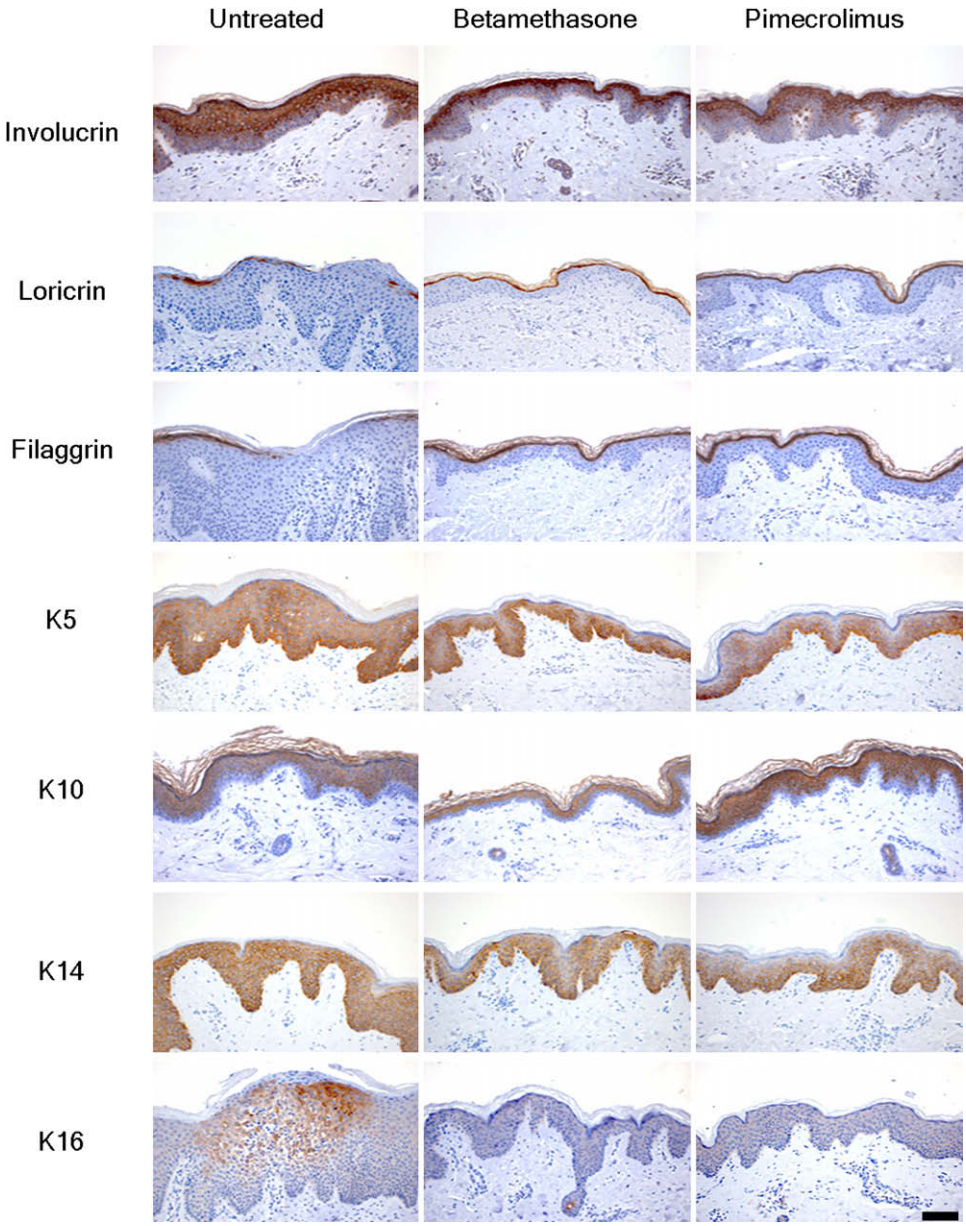

FIG 4. Epidermal differentiation. Epidermal differentiation was determined immunohistologically by using specific antibodies. An average and representative set of slides was chosen. *K,* Keratin.

during the treatment period, whereby betamethasone was significantly more effective than pimecrolimus. After application of betamethasone, the known increased epidermal proliferation rate in patients with AD[14] was significantly reduced. Pimecrolimus significantly reduced proliferation as well, but the effect was less pronounced than with betamethasone. Betamethasone reduced the proliferation rate to less than normal levels, indicating the atrophogenic effects, including epidermal thinning, of corticosteroids.[38] Pimecrolimus does not show atrophogenic qualities (Fig 3, *B*).[39]

Disturbed epidermal expression of involucrin, loricrin, filaggrin, and keratins in AD patients[13,14,40] was almost normalized by both treatments. This indicates that both corticosteroids and calcineurin inhibitors are able to restore disturbed differentiation in patients with AD. The involucrin staining band was smaller after treatment with betamethasone than after treatment with pimecrolimus. This might be related to epidermal thinning after betamethasone treatment.

Focally expressed filaggrin, level of which are known to be reduced in patients with AD,[4-6,13,14] was homogeneously re-expressed after both treatments. This effect was slightly more weakly pronounced in the betamethasone group, which might be related to the global reduction in protein synthesis caused by corticosteroids. Filaggrin breakdown products are important for water binding and skin hydration.[41] Accordingly, both regimens enhanced stratum corneum hydration, but the values were still less than those seen in healthy control subjects.[14] To our knowledge, no study has examined treatment results in patients with or without filaggrin mutations. Also, the presence of a filaggrin mutation was not an inclusion or exclusion criterion in the present study.

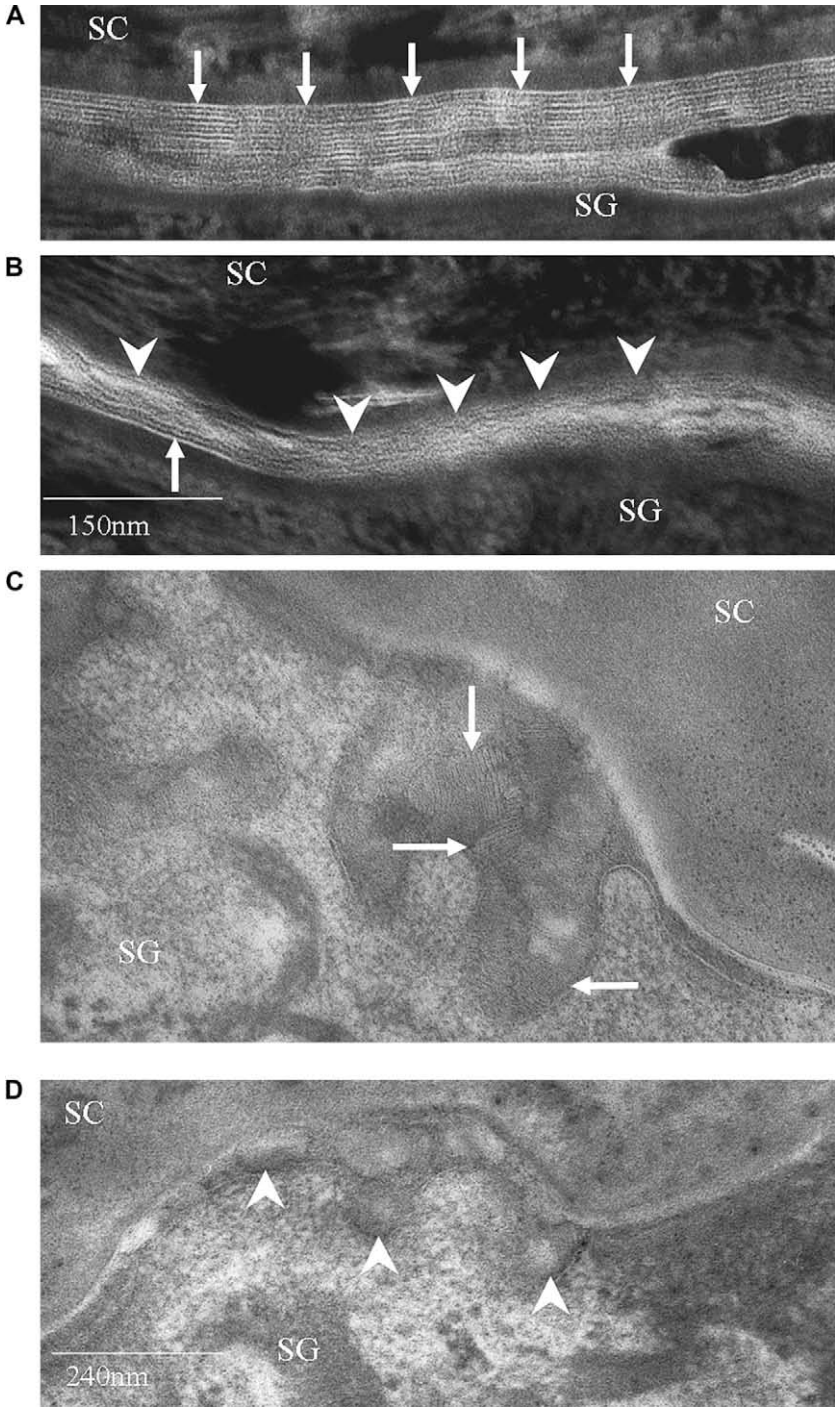

FIG 5. Skin barrier structure. Transmission electron microscopy of the transition zone between the stratum granulosum and the stratum corneum revealed inconsistent extracellular lipid bilayers *(arrowheads)* and rarely regular layers *(arrows)* after betamethasone treatment **(A)**. After pimecrolimus treatment, regular lipid bilayers *(arrows)* were noted **(B)**. Partially filled lamellar bodies in the stratum granulosum were noted after betamethasone treatment *(arrowheads)*, which tended to accumulate rather than extrude **(C)**. Largely regular lamellar body content *(arrows)* and extrusion were seen after pimecrolimus treatment **(D)**. *SG*, Transition zone of the granular cell layer; *SC*, stratum corneum.

Enhanced TEWL values, a well-known finding in patients with lesional AD, were significantly reduced after 1 week of both betamethasone and pimecrolimus treatment but were still greater than control levels,[14] implying improvement in skin barrier function with both regimens. However, when we examined the stratum corneum structure, regular lipid bilayers, one of the most important signs of an intact skin barrier, were detected after pimecrolimus treatment but not after betamethasone treatment.

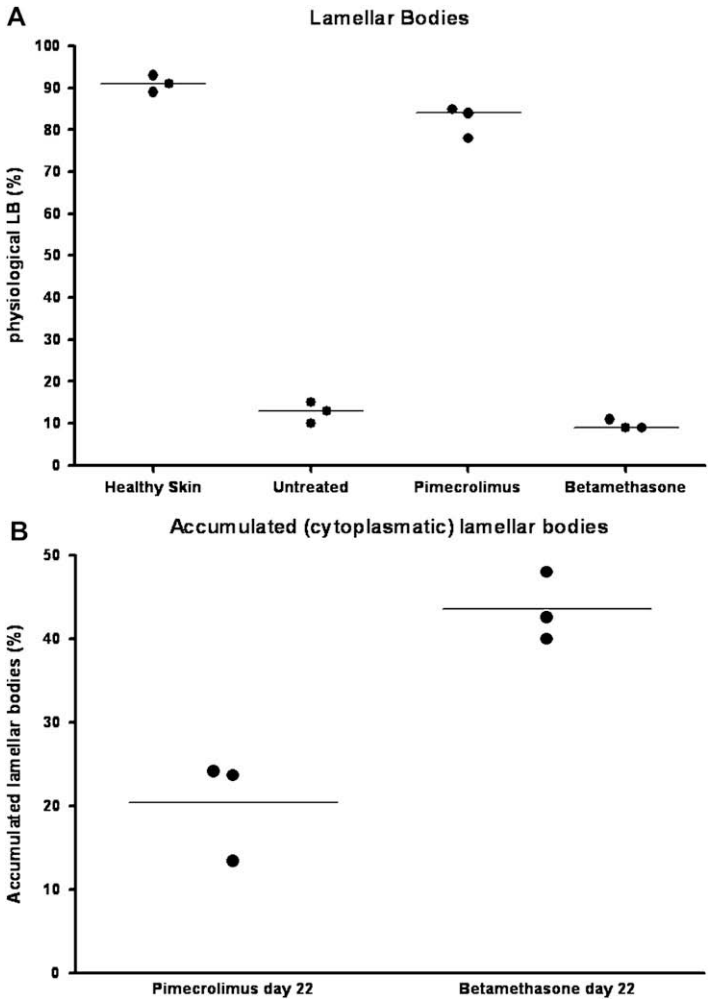

FIG 6. Lamellar body quantification. Quantification of 200 lamellar bodies *(LB)* was performed to determine the number of completely filled lamellar bodies after pimecrolimus treatment **(A)**. Also, the number of accumulated (unprocessed) lamellar bodies in the transition zone of the granular cell layer toward the stratum corneum was determined **(B)**. Because of the complexity of the method, only 3 sample sets could be evaluated in this study. Therefore the results are not subject to formal statistical evaluation. However, the results are impressive and, to our understanding, of significance.

TEWL, as measured with the Tewameter, an evaporimeter, or a similar device, is a marker for the inside-outside barrier. The inside-outside barrier often, but not always, correlates with the outside-inside barrier.[42]

The decrease in TEWL after betamethasone treatment might be explained in part by the decrease of blood flow caused by vasoconstriction after corticosteroid treatment.[43] Vasoconstriction causes reduced fluid flow into the dermis and the epidermis and conceivably reduces TEWL. TEWL depends on the barrier component plus a driving force component. The essential part of this component is the blood flow, as determined by means of laser Doppler flowmetry.[44]

Measurement of the outside-inside barrier is very important because a disturbed barrier could enable environmental allergens, such as house dust mites, animal dander, and grass pollen, to penetrate into the skin and induce immunologic reactions in patients with AD. Reduced penetration in patients with AD after hydrocortisone treatment has already been shown, suggesting that hydrocortisone might improve the outside-inside barrier.[45] However, such studies have not yet been reproduced with more potent corticosteroids. Hence we performed separate dye-penetration studies in a different set of patients to address this issue. In healthy skin dye penetration did not occur, whereas substantial penetration was noted in untreated AD skin, indicating an intact versus a disrupted outside-inside barrier. Dye penetration was substantially reduced after treatment with betamethasone and even slightly (but not significantly) more reduced with pimecrolimus compared with that seen in patients with untreated AD. This corresponds with electron microscopic studies after pimecrolimus treatment but not with those performed after betamethasone treatment.

The electron microscopic studies showed long-term disruption of the stratum corneum lipid layers and disturbed lamellar body extrusion after treatment with betamethasone, which, at the first glance, might not be compatible with the dye experiments. This again might be due to the vasoconstriction caused by betamethasone. Previous data from *in vivo* studies with radioactivity conducted in human subjects in the 1970s indicated that vasoconstriction induced by topical application of hydrocortisone limited

skin penetration of the drug itself with time.[46] This effect is most probably more pronounced when applying more potent corticosteroids, such as betamethasone (the vasoconstriction test is used to classify the potency of corticosteroids). *In vivo* studies involving radioactivity can no longer be performed for ethical reasons. Alternative methods do not exhibit the same accuracy.

Electron microscopic studies show that the stratum corneum is constituted by lipid lamellae located between the corneocytes. Lamellar bodies of the keratinocytes are extruded to the transition zone between the stratum granulosum and stratum corneum, where the content is used to form the extracellular lipid bilayers.[47] Disturbed lamellar body extrusion has been described in patients with AD.[11] We found that lipid bilayers in the stratum corneum were only focally seen after betamethasone treatment of AD. Empty or incompletely filled and accumulated, unextruded lamellar bodies were observed. In contrast, predominantly normal lamellar bilayers in the stratum corneum and normal extrusion of the lamellar body content at the stratum granulosum/stratum corneum interface were seen after pimecrolimus treatment, implying that pimecrolimus, but not betamethasone, improved skin barrier structure. However, pimecrolimus did not lead to the complete restoration of the barrier, as indicated by a lower number of physiologic lamellar bodies (Fig 6) and enhanced dye penetration compared with that seen in healthy skin. Because of the complexity of the method, only 3 sample sets could be evaluated in this study. We did not perform formal statistical calculations. However, the impressive differences between the intraindividual treatment groups are of significance.

Previous publications have shown that corticosteroid treatment of normal human and mouse skin leads to a defect in barrier function and structure.[38,43,48] We suggest that protein synthesis and lipid synthesis,[49] both of which are essential for skin barrier repair and formation, are suppressed by the antiproliferative and antimetabolic effects of corticosteroids. Skin barrier repair after pimecrolimus treatment of lesional AD skin might be related to the higher selectivity of pimecrolimus compared with that of corticosteroids, whereas corticosteroid treatment reduces dermal blood flow and inflammatory cell responses. In contrast to steroids, pimecrolimus induces epidermal differentiation without suppressing epidermal proliferation to less than normal levels and without a global reduction in protein synthesis. How pimecrolimus exerts this effect on epidermal differentiation is unclear. It might reflect the consequence of a direct action on keratinocytes. However, we cannot rule out that pimecrolimus first influences immune cells, which then affect keratinocytes and skin barrier function.[50-52]

The present study indicates that pimecrolimus and betamethasone differ in their effects on the epidermal barrier. Betamethasone exerted a more potent antiproliferative and anti-inflammatory effect, causing a more rapid reduction in TEWL but leading to epidermal thinning. In previous and present clinical scoring, betamethasone was superior to pimecrolimus, confirming clinical observations. Although betamethasone appeared to improve the skin barrier, as judged based on TEWL and dye penetration, it did not restore the structure of the lamellar body extrusion and lipid bilayer formation in the lower stratum corneum, which are known as epidermal barrier structures. Pimecrolimus induced regular lipid layer formation and lamellar body extrusion, indicating restoration of the epidermal barrier. Barrier repair might prevent the influx of environmental allergens into the skin and thus prevent immunologic reactions and subsequent inflammation. Because of the beneficial effect and the fact that, in contrast to steroids, it does not cause skin atrophy, pimecrolimus might be more suitable for long-term treatment of AD. Corticosteroid treatment leads predominantly to a reduction in inflammation and blood flow, which supports its role in the acute and short-term treatment of inflammatory skin diseases, such as AD.

We thank Anton Stütz and Josef Meingassner, Novartis Vienna (Austria), for helpful discussions.

Clinical implications: Pimecrolimus improves the epidermal barrier without causing atrophy and therefore might be suitable for long-term treatment of AD.

REFERENCES

1. Bos JD, Kapsenberg ML, Smitt JH. Pathogenesis of atopic eczema. Lancet 1994; 343:1338-41.
2. Leung DY, Bieber T. Atopic dermatitis. Lancet 2003;361:151-60.
3. Morar N, Willis-Owen SA, Moffatt MF, Cookson WO. The genetics of atopic dermatitis. J Allergy Clin Immunol 2006;118:24-34.
4. Palmer CN, Irvine AD, Terron-Kwiatkowski A, Zhao Y, Liao H, Lee SP, et al. Common loss-of-function variants of the epidermal barrier protein filaggrin are a major predisposing factor for atopic dermatitis. Nat Genet 2006;38:441-6.
5. Weidinger S, Illig T, Baurecht H, Irvine AD, Rodriguez E, Diaz-Lacava A, et al. Loss-of-function variations within the filaggrin gene predispose for atopic dermatitis with allergic sensitizations. J Allergy Clin Immunol 2006;118:214-9.
6. Ruether A, Stoll M, Schwarz T, Schreiber S, Fölster-Holst R. Filaggrin loss-of-function variant contributes to atopic dermatitis risk in the population of Northern Germany. Br J Dermatol 2006;155:1093-5.
7. Weidinger S, Rodriguez E, Stahl C, Wagenpfeil S, Klopp N, Illig T, et al. Filaggrin mutations strongly predispose to early-onset and extrinsic atopic dermatitis. J Invest Dermatol 2007;127:724-6.
8. Elias PM, Wood LC, Feingold KR. Epidermal pathogenesis of inflammatory dermatoses. Am J Contact Dermat 1999;10:119-26.
9. Elias PM, Feingold KR. Does the tail wag the dog? Role of the barrier in the pathogenesis of inflammatory dermatoses and therapeutic implications. Arch Dermatol 2001;137:1079-81.
10. Yoshiike T, Aikawa Y, Sindhvananda J, Suto H, Nishimura K, Kawamoto T, et al. Skin barrier defect in atopic dermatitis: increased permeability of the stratum corneum using dimethyl sulfoxide and theophylline. J Dermatol Sci 1993;5:92-6.
11. Fartasch M, Bassukas ID, Diepgen TL. Disturbed extruding mechanism of lamellar bodies in dry non-eczematous skin of atopics. Br J Dermatol 1992;127:221-7.
12. Sugarman JL, Fluhr JW, Fowler AJ, Bruckner T, Diepgen TL, Williams ML. The objective severity assessment of atopic dermatitis score: an objective measure using permeability barrier function and stratum corneum hydration with computer-assisted estimates for extent of disease. Arch Dermatol 2003;139:1417-22.
13. Seguchi T, Cui CY, Kusuda S, Takahashi M, Aisu K, Tezuka T. Decreased expression of filaggrin in atopic skin. Arch Dermatol Res 1996;288:442-6.
14. Jensen JM, Fölster-Holst R, Baranowsky A, Schunck M, Winoto-Morbach S, Neumann C, et al. Impaired sphingomyelinase activity and epidermal differentiation in atopic dermatitis. J Invest Dermatol 2004;122:1423-31.
15. Ogawa H, Yoshiike TJ. A speculative view of atopic dermatitis: barrier dysfunction in pathogenesis. Dermatol Sci 1993;5:197-204.
16. Proksch E, Jensen JM, Elias PM. Skin lipids and epidermal differentiation in atopic dermatitis. Clin Dermatol 2003;21:134-44.
17. Cookson W. The immunogenetics of asthma and eczema: a new focus on the epithelium. Nat Rev Immunol 2004;4:978-88.
18. Proksch E, Fölster-Holst R, Jensen JM. Skin barrier function, epidermal proliferation and differentiation in eczema. J Dermatol Sci 2006;43:159-69.
19. Jakasa I, de Jongh CM, Verberk MM, Bos JD, Kezic S. Percutaneous penetration of sodium lauryl sulphate is increased in uninvolved skin of patients with atopic dermatitis compared with control subjects. Br J Dermatol 2006;155:104-9.
20. Jakasa I, Verberk MM, Esposito M, Bos JD, Kezic S. Altered penetration of polyethylene glycols into uninvolved skin of atopic dermatitis patients. J Invest Dermatol 2007;127:129-34.
21. Guillet G, Guillet MH. Natural history of sensitizations in atopic dermatitis: a 3-year follow-up in 250 children: food allergy and high risk of respiratory symptoms. Arch Dermatol 1992;128:187-92.
22. Fölster-Holst R, Pape M, Buss YL, Christophers E, Weichenthal M. Low prevalence of the intrinsic form of atopic dermatitis among adult patients. Allergy 2006;61:629-32.

23. Allam JP, Novak N. The pathophysiology of atopic eczema. Clin Exp Dermatol 2006;31:89-93.
24. Howell MD, Kim BE, Gao P, Grant AV, Boguniewicz M, Debenedetto A, et al. Cytokine modulation of atopic dermatitis filaggrin skin expression. J Allergy Clin Immunol 2007;120:150-5.
25. Stütz A, Baumann K, Grassberger M, Wolff K, Meingassner JG. Discovery of topical calcineurin inhibitors and pharmacological profile of pimecrolimus. Int Arch Allergy Immunol 2006;141:199-212.
26. Meingassner JG, Aschauer H, Stütz A, Billich A. Pimecrolimus permeates less than tacrolimus through normal, inflamed, or corticosteroid-pretreated skin. Exp Dermatol 2005;14:752-7.
27. Hoetzenecker W, Meingassner JG, Ecker R, Stingl G, Stütz A, Elbe-Bürger A. Corticosteroids but not pimecrolimus affect viability, maturation and immune function of murine epidermal Langerhans cells. J Invest Dermatol 2004;122: 673-84.
28. Hashimoto-Kumasaka K, Takahashi K, Tagami H. Electrical measurement of the water content of the stratum corneum in vivo and in vitro under various conditions: comparison between skin surface hygrometer and corneometer in evaluation of the skin surface hydration state. Acta Derm Venereol 1993;73:335-9.
29. Pinnagoda J, Tupker RA, Agner T, Serup J. Guidelines for transepidermal water loss (TEWL) measurement. A report from the Standardization Group of the European Society of Contact Dermatitis. Contact Dermatitis 1990;22:164-81.
30. Tate M, Grove G, Joch R, Laabs J, Menard K, Nelson B, et al. Dye exclusion as a means to measure wetness protection of human skin. Skin Res Technol 2007;13: 293-8.
31. Hazelbag HM, Laforga JB, Roels HJ, Hogendoorn PC. Dedifferentiated adamantinoma with revertant mesenchymal phenotype. Am J Surg Pathol 1995;27:1530-7.
32. Elias PM, Friend DS. The permeability barrier in mammalian epidermis. J Cell Biol 1975;65:180-91.
33. Luft JH. Improvements in epoxy resin embedding methods. J Biophys Biochem Cytol 1961;9:409-14.
34. Reynolds ES. The use of lead citrate at high pH as an electron-opaque stain in electron microscopy. J Cell Biol 1963;17:208-12.
35. Agner T. Noninvasive measuring methods for the investigation of irritant patch test reactions. A study of patients with hand eczema, atopic dermatitis and controls. Acta Derm Venereol Suppl (Stockh) 1992;173:1-26.
36. Elias PM, Hatano Y, Williams ML. Basis for the barrier abnormality in atopic dermatitis: outside-inside-outside pathogenic mechanisms. J Allergy Clin Immunol 2008;121:1337-43.
37. Meingassner JG, Kowalsky E, Schwendinger H, Elbe-Bürger A, Stütz A. Pimecrolimus does not affect Langerhans cells in murine epidermis. Br J Dermatol 2003;149: 853-7.
38. Hengge U, Ruzicka T, Schwartz RA, Cork MJ. Adverse effects of topical glucocorticosteroids. Am Acad Dermatol 2006;54:1-15.
39. Queille-Roussel C, Paul C, Duteil L, Lefebvre MC, Rapatz G, Zagula M, et al. The new topical ascomycin derivative SDZ ASM 981 does not induce skin atrophy when applied to normal skin for 4 weeks: a randomized, double-blind controlled study. Br J Dermatol 2001;144:507-13.
40. Kim BE, Leung DY, Boguniewicz M, Howell MD. Loricrin and involucrin expression is down-regulated by Th2 cytokines through STAT-6. Clin Immunol 2008;126: 332-7.
41. Scott IR, Harding CR. Filaggrin breakdown to water binding compounds during development of the rat stratum corneum is controlled by the water activity of the environment. Dev Biol 1986;115:84-92.
42. Tunggal JA, Helfrich I, Schmitz A, Schwarz H, Günzel D, Fromm M, et al. E-cadherin is essential for in vivo epidermal barrier function by regulating tight junctions. EMBO J 2005;24:1146-56.
43. Kolbe L, Kligman AM, Schreiner V, Stoudemayer T. Corticosteroid-induced atrophy and barrier impairment measured by non-invasive methods in human skin. Skin Res Technol 2001;7:73-7.
44. Endo K, Suzuki N, Yoshida O, Sato H, Fujikura Y. The barrier component and the driving force component of transepidermal water loss and their application to skin irritant tests. Skin Res Technol 2007;13:425-35.
45. Aalto-Korte K. Improvement of skin barrier function during treatment of atopic dermatitis. J Am Acad Dermatol 1995;33:969-72.
46. Zesch A, Schaefer H. Penetration of radioactive hydrocortisone in human skin from various ointment bases. II. In vivo-experiments [author's translation]. Arch Dermatol Forsch 1975;252:245-56.
47. Elias PM, Menon GK. Structural and lipid biochemical correlates of the epidermal permeability barrier. Adv Lipid Res 1991;24:1-26.
48. Sheu HM, Lee JY, Chai CY, Kuo KW. Depletion of stratum corneum intercellular lipid lamellae and barrier function abnormalities after long-term topical corticosteroids. Br J Dermatol 1997;136:884-90.
49. Kao JS, Fluhr JW, Man MQ, Fowler AJ, Hachem JP, Crumrine D, et al. Short-term glucocorticoid treatment compromises both permeability barrier homeostasis and stratum corneum integrity: inhibition of epidermal lipid synthesis accounts for functional abnormalities. J Invest Dermatol 2003;120:456-64.
50. Stütz A, Grassberger M, Meingassner JG. Pimecrolimus (Elidel, SDZ ASM 981)—preclinical pharmacologic profile and skin selectivity. Semin Cutan Med Surg 2001;20:233-41.
51. Luger T. Treatment of immune-mediated skin diseases: future perspectives. Eur J Dermatol 2001;11:343-7.
52. Novak N, Kwiek B, Bieber T. The mode of topical immunomodulators in the immunological network of atopic dermatitis. Clin Exp Dermatol 2005;30:160-4.