Letter to the Editor

Hemophagocytic lymphohistiocytosis in 2 patients with underlying IFN-γ receptor deficiency

To the Editor:

Hemophagocytic lymphohistiocytosis (HLH) is a severe hyperinflammatory disorder, caused by mutations in genes required for lymphocyte cytotoxicity or may be secondary to infections, malignancy, and autoimmunity.[1,2] Animal models have indicated a central role for IFN-γ produced by $CD8^+$ T cells in the pathophysiology of HLH,[3] and a possible clinical efficacy of anti–IFN-γ antibody therapy for the control of HLH.[4]

Here, we detail 2 unrelated cases of fatal IFN-γ receptor (IFN-γR) deficiency with mycobacterial infections who were initially diagnosed with HLH. Patient A, a 2-month-old girl, and patient B, a 4-year-old girl (see Case Reports and Fig E1, *A* and *B*, in this article's Online Repository at www.jacionline.org), fulfilled, respectively, 7 of 8 and 5 of 6 HLH diagnostic criteria[1] (see Table E1 in this article's Online Repository at www.jacionline.org).

For information on methods, see this article's Online Repository at www.jacionline.org.

In patient A, cytotoxic lymphocyte function was evaluated twice with the consistent finding of pathologically low natural killer (NK)-cell cytotoxic function, even after IL-2 stimulation (see Fig E2, *A* and *B*, in this article's Online Repository at www.jacionline.org). This reflected low NK cell numbers (Fig 1, *A*), possibly caused by antithymocyte globulin treatment. NK-cell cytotoxic activity was not evaluated in patient B because of the very low frequency of peripheral blood NK cells, already present at admission (Fig 1, *B*). In both patients, additional characterization of NK-cell and T-cell function did not reveal defects consistent with primary HLH caused by an impairment in lymphocyte cytotoxicity (Fig 1, *C-F*; also see Fig E2, *C* and *D*). Accordingly, no mutations were found in known HLH-associated genes.

After the diagnosis of HLH, the patients were found positive for cytomegalovirus and *Mycobacterium bovis* infections, and for EBV and *Mycobacterium tuberculosis* (MTB) infections, respectively. Moreover, in patient B, plasma IFN-γ levels were constitutively elevated, without increasing further on stimulation with mitogen or MTB antigen (see Fig E3, *A* and *B* in this article's Online Repository at www.jacionline.org). In light of a disseminated mycobacterial infection, a differential diagnosis of Mendelian

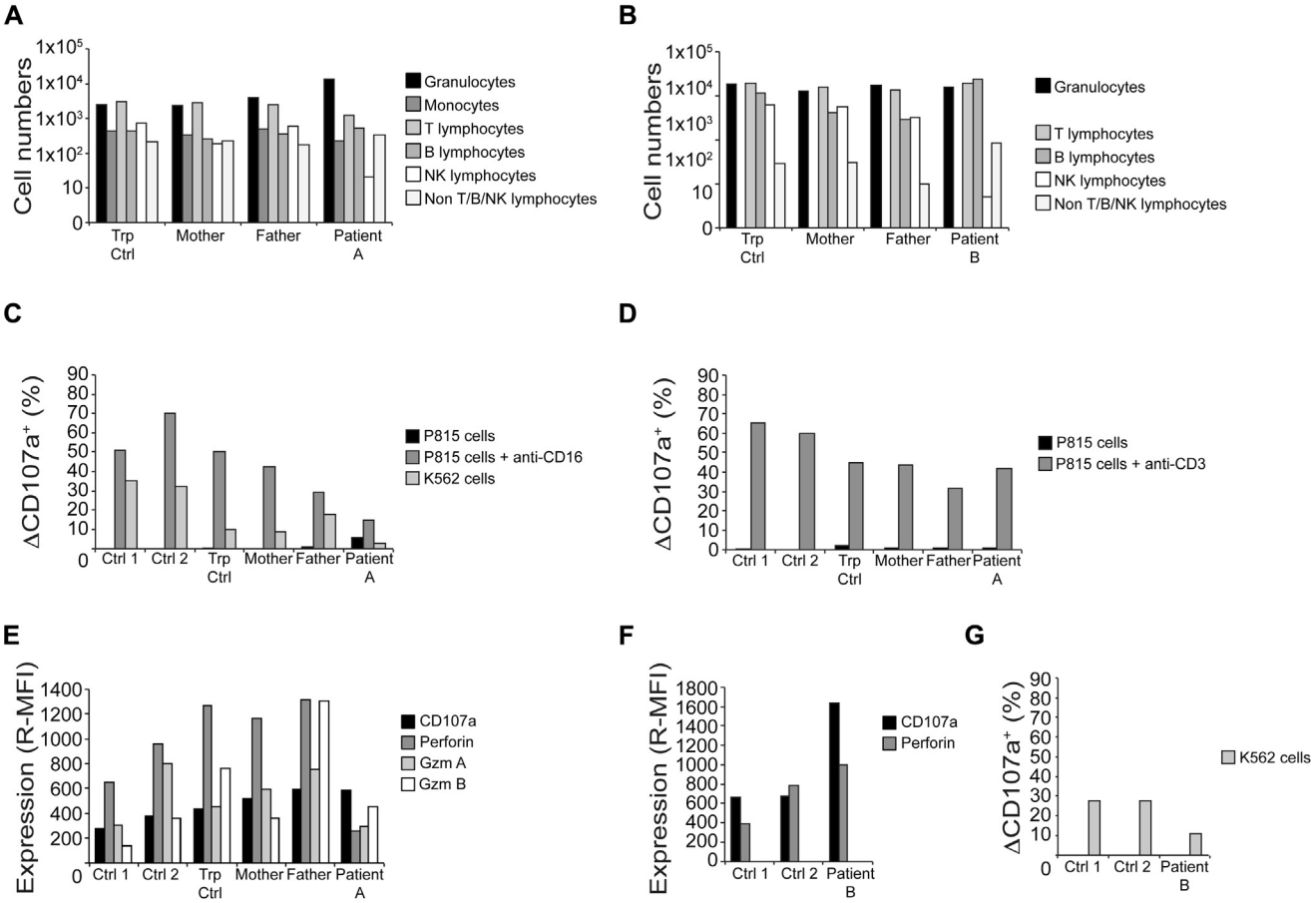

FIG 1. Immunologic analyses. Both patients (**A** and **B**) displayed a low number of NK cells. Neutrophil counts in patient B were lower at initial diagnosis of HLH compared with this later measurement. Flow-cytometric analyses of patient A showed abnormal NK-cell degranulation toward K562 **(C)**, normal T-cell degranulation **(D)**, and normal granule content **(E)**. Granule content (Fig 1, *B*) and NK-cell degranulation toward K562 (Fig 1, *C*) were normal in patient B. *Ctrl*, Control; *R-MFI*, relative median fluorescence intensity; *Trp*, transport.

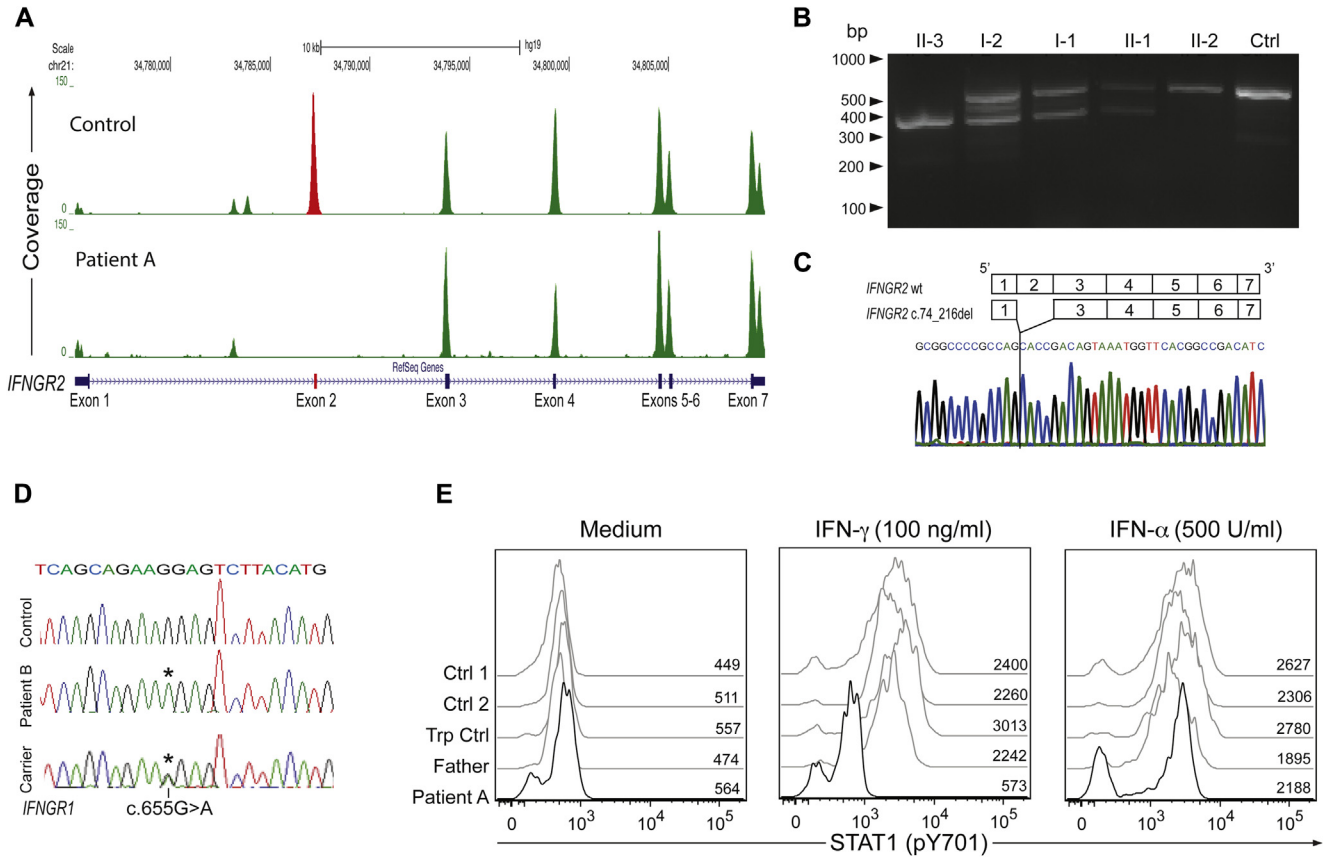

FIG 2. Coverage analysis in patient A suggests an exonic deletion of exon 2 of *IFNGR2* **(A)**, validated by RT-PCR of *IFNGR2* **(B)** and cDNA sequencing **(C)**, which showed lack of exon 2. **D,** Sanger electropherograms of G219R *IFNGR1* missense mutation in patient B. **E,** STAT1 phosphorylation on IFN-γ stimulation is defective in patient A, but not in the controls. *Ctrl*, Control; *STAT1*, signal transducer and activator of transcription 1; *Trp*, transport.

susceptibility to mycobacterial disease (MSMD) was considered, although fulminant HLH in the context of defective IFN-γ signaling was deemed unlikely.

In patient A, Sanger sequencing of *IFNGR1* and *IFNGR2* was followed by whole exome sequencing. Variant calling did not identify mutations able to explain the phenotype. Only a homozygous missense variant in *FANCA* (p.H1417D), described in patients with Fanconi anemia, was found. Instead, analysis of copy number variation revealed a possible homozygous deletion of exon 2 of *IFNGR2* (Fig 2, *A*). Of note, exon 2 was not amplified by PCR. On evaluation of *IFNGR2* transcripts, the patient expressed only a truncated *IFNGR2* transcript lacking exon 2 (c.74_216del, p.Asp25Alafs*38; Fig 2, *B* and *C*). In patient B, sequencing of *IFNGR1* and *IFNGR2* revealed a homozygous *IFNGR1* c.655G>A (p.G219R) missense variant, affecting a conserved residue in the second domain of the extracellular region of IFN-γR1. The parents and the healthy sister were heterozygous carriers (Fig 2, *D*). The G219R variant was predicted damaging and was not found in the 1000 Genomes database and in 150 healthy Chinese individuals. An in-frame deletion affecting residue 218 of IFN-γR1 was described in a patient with MSMD carrying compound heterozygous *IFNGR1* mutations (the other mutation being p.V61Q), resulting in normal IFN-γR1 surface expression but severely impaired IFN-γ binding.[5] The G219R mutation may have a similar effect. With mycobacterial infections and mutations in *IFNGR1* or *IFNGR2*, the patients fulfilled a diagnosis of MSMD in addition to HLH. A molecular defect in either chain of the IFN-γR heterodimer impairs signaling and causes increased susceptibility to severe *Mycobacterium* species infections.[6] After IFN-γ stimulation, no signal transducer and activator of transcription 1 phosphorylation was observed by flow cytometry in monocytes from patient A (Fig 2, *E*), establishing a diagnosis of complete IFN-γR deficiency. In patient B, it is not clear whether the IFN-γR1 G219R mutation causes complete or partial IFN-γR1 deficiency because such data were not available. Nonetheless, the high levels of IFN-γ found in patient B may suggest a complete deficiency. Both the identified genetic aberrations were novel. Importantly, this represents the first report of HLH in patients with genetic aberrations impairing IFN-γ signaling. Because IFN-γ is considered a cardinal cytokine in the development of HLH, a link between HLH and defects in IFN-γ signaling is surprising.

Mouse models indicate a crucial role of IFN-γ for the development of primary HLH.[3] Fatal HLH-like disease in *Prf1* knockout mice infected with lymphocytic choriomeningitis virus can be treated by antibody-mediated IFN-γ neutralization.[3] Intriguingly, antibody-mediated TNF neutralization ameliorated organ damage in *Prf1* knockout mice challenged with murine cytomegalovirus.[7] Moreover, in wild-type mice, high levels of IL-4 or repeated Toll-like receptor 9 (TLR9) stimulation can induce the development of an HLH-like or macrophage activation

syndrome–like disease.[8,9] On TLR9 stimulation, IFN-γ–knockout mice developed macrophage activation syndrome–like disease with a severity comparable to that of wild-type mice, suggesting that immune pathology may arise independent of IFN-γ.[9] This model may provide an explanation for HLH in our patients. DNA from *M tuberculosis* is a potent stimulus for TLR9-dependent responses.[10] We speculate that genetic susceptibility to severe and sustained mycobacterial infection may predispose to strong TLR stimulation, resulting in HLH. The low NK cell numbers in our patient may have also enhanced the risk of developing HLH.

Interestingly, hemophagocytosis was not found in both cases. Hemophagocytosis is often viewed as a late symptom and is not required for a diagnosis of HLH.[1] In mice, infusion of IFN-γ can induce hemophagocytosis by macrophages.[11] Notably, such macrophage-mediated macropinocytosis depends on IFN-γR signaling in macrophages.[11] Therefore, our patients may further support a role for IFN-γR signaling in driving hemophagocytosis, but not other pathologic features of the HLH syndrome.

Based on experiments in animal models, a clinical efficacy of anti–IFN-γ antibody treatment in patients with primary HLH has been proposed.[3,4] Clinical trials are ongoing, notably with active infections, including mycobacterial, representing exclusion criteria. Our findings suggest that other cytokines, for example, TNF, may be important drivers of immune pathogenesis. In patients infected by multiple pathogens, blocking IFN-γ may accommodate other infections, leading to TLR stimulation and HLH. Therefore, at least in settings of HLH associated with primary defects in immune function other than lymphocyte cytotoxicity, immune suppression besides anti–IFN-γ antibody should be considered. It is noteworthy that antithymocyte globulin controlled HLH in both patients.

In conclusion, we report 2 cases of HLH in children with novel IFN-γR mutations. Importantly, our results highlight the significance of IFN-γ–independent mechanisms in the immune pathology of HLH, provide new views on pathogenic mechanisms of human hyperinflammatory syndromes, and expand the spectrum of genetic conditions conferring susceptibility to HLH. Clinically, because different mechanisms seem to be involved in HLH pathogenesis, novel therapies, beside anti–IFN-γ therapy, should be investigated.

Bianca Tesi, MD[a,b]*
Elena Sieni, MD[c]*
Conceição Neves, MD[d]
Francesca Romano, BSc[e]
Valentina Cetica, PhD[c]
Ana Isabel Cordeiro, MD[d]
Samuel Chiang, MSc[f]
Heinrich Schlums, MSc[f]
Luisa Galli, MD[g]
Stefano Avenali, MD[h]
Annalisa Tondo, MD[c]
Clementina Canessa, MD[e]
Jan-Inge Henter, MD, PhD[a]
Magnus Nordenskjöld, MD, PhD[b]
Amy P. Hsu, BA[i]
Steven M. Holland, MD[i]
João F. Neves, MD[d]*
Chiara Azzari, MD, PhD[e]*
Yenan T. Bryceson, PhD[f,j]*

From [a]the Childhood Cancer Research Unit, Department of Women's and Children's Health, Karolinska Institute, Karolinska University Hospital Solna, Stockholm, Sweden; [b]the Clinical Genetics Unit, Department of Molecular Medicine and Surgery, and Center for Molecular Medicine, Karolinska Institute, Karolinska University Hospital, Stockholm, Sweden; [c]the Department of Pediatric Hematology Oncology, Anna Meyer Children's University Hospital, Florence, Italy; [d]the Primary Immunodeficiencies Unit, Hospital Dona Estefania, Pediatric University Hospital, and CEDOC, Chronic Diseases Research Center, NOVA Medical School, Lisboa, Portugal; [e]the Department of Pediatric Immunology, University of Florence, and Anna Meyer Children's University Hospital, Jeffrey Modell Center for Primary Immunodeficiencies, Florence, Italy; [f]the Centre for Infectious Medicine, Department of Medicine, Karolinska Institute, Karolinska University Hospital Huddinge, Stockholm, Sweden; [g]the Department of Pediatric Infectious Diseases, Anna Meyer Children's University Hospital, Florence, Italy; [h]the Department of Pediatric Intensive Care, Anna Meyer Children's University Hospital, Florence, Italy; [i]the National Institute of Allergy and Infectious Diseases, National Institutes of Health, Bethesda, Md; and [j]Broegelmann Research Laboratory, Department of Clinical Sciences, University of Bergen, Norway. E-mail: Yenan.Bryceson@ki.se.

*These authors contributed equally to this work.

This work was supported by the European Research Council (ERC) under the European Union's Seventh Framework Programme (FP/2007-2013) (ERC grant agreement no. 311335), Swedish Research Council, Swedish Foundation for Strategic Research, Swedish Cancer Foundation, Swedish Children's Cancer Foundation, and the Karolinska Institute Research Foundation (to Y.T.B.) and the Jeffrey Modell Foundation (to C.A.). B.T. was supported by a PhD student scholarship awarded by the Board of Postgraduate Studies at Karolinska Institute.

Disclosure of potential conflict of interest: L. Galli has received payment for the development of educational presentations from Janssen and has received travel support from Glaxo. J.-I. Henter has received research support from the Swedish Research Council, the Swedish Cancer Foundation, the Swedish Children's Cancer Foundation, the Stockholm County Council (ALF Project), and the Cancer and Allergy Foundation. Y. T. Bryceson has received research support from the European Research Council (Starting Grant), the Swedish Research Council, and the Swedish Society for Strategic Research and is employed by Karolinska Institute and the University of Bergen. The rest of the authors declare that they have no relevant conflicts of interest.

REFERENCES

1. Henter JI, Horne A, Aricó M, Egeler RM, Filipovich AH, Imashuku S, et al. HLH-2004: diagnostic and therapeutic guidelines for hemophagocytic lymphohistiocytosis. Pediatr Blood Cancer 2007;48:124-31.
2. Faitelson Y, Grunebaum E. Hemophagocytic lymphohistiocytosis and primary immune deficiency disorders. Clin Immunol 2014;155:118-25.
3. Jordan MB. An animal model of hemophagocytic lymphohistiocytosis (HLH): $CD8^+$ T cells and interferon gamma are essential for the disorder. Blood 2004;104:735-43.
4. Schmid JP, Ho CH, Chrétien F, Lefebvre JM, Pivert G, Kosco-Vilbois M, et al. Neutralization of IFNγ defeats haemophagocytosis in LCMV-infected perforin- and Rab27a-deficient mice. EMBO Mol Med 2009;1:112-24.
5. Jouanguy E, Dupuis S, Pallier A, Doffinger R, Fondaneche MC, Fieschi C, et al. In a novel form of IFN-γ receptor 1 deficiency, cell surface receptors fail to bind IFN-γ. J Clin Invest 2000;105:1429-36.
6. Filipe-Santos O, Bustamante J, Chapgier A, Vogt G, de Beaucoudrey L, Feinberg J, et al. Inborn errors of IL-12/23- and IFN-γ-mediated immunity: molecular, cellular, and clinical features. Semin Immunol 2006;18:347-61.
7. Van Dommelen SL, Sumaria N, Schreiber RD, Scalzo AA, Smyth MJ, Degli-Esposti MA. Perforin and granzymes have distinct roles in defensive immunity and immunopathology. Immunity 2006;25:835-48.
8. Milner JD, Orekov T, Ward JM, Cheng L, Torres-Velez F, Junttila I, et al. Sustained IL-4 exposure leads to a novel pathway for hemophagocytosis, inflammation, and tissue macrophage accumulation. Blood 2010;116:2476-83.
9. Canna SW, Wrobel J, Chu N, Kreiger PA, Paessler M, Behrens EM. Interferon-γ mediates anemia but is dispensable for fulminant Toll-like receptor 9–induced macrophage activation syndrome and hemophagocytosis in mice. Arthritis Rheum 2013;65:1764-75.
10. Bafica A, Scanga CA, Feng CG, Leifer C, Cheever A, Sher A. TLR9 regulates Th1 responses and cooperates with TLR2 in mediating optimal resistance to *Mycobacterium tuberculosis*. J Exp Med 2005;202:1715-24.
11. Zoller EE, Lykens JE, Terrell CE, Aliberti J, Filipovich AH, Henson PM, et al. Hemophagocytosis causes a consumptive anemia of inflammation. J Exp Med 2011;208:1203-14.

http://dx.doi.org/10.1016/j.jaci.2014.11.030

CASE REPORTS

Patient A, a 2-month-old girl, born to consanguineous Portuguese parents (Fig E1, *A*), was initially admitted for impetiginized atopic eczema treated with flucloxacilin, which triggered an episode resembling a drug reaction with eosinophilia and systemic symptoms syndrome. Subsequently, she developed worsening fever, hepatosplenomegaly with cholestatic hepatitis, hyperferritinemia, hypofibrinogenemia, as well as thrombocytopenia, anemia, and elevated sCD25 level (Table E1). Hemophagocytosis was not evident in bone marrow, liver, or skin. The patient fulfilled 7 of 8 HLH diagnostic criteria,[E1] establishing a diagnosis of HLH (Table E1). HLH treatment was initiated with dexamethasone, antithymocyte globulin, and cyclosporine, resulting in partial control of disease. Subsequently, the patient was found positive for cytomegalovirus (>10,000,000 viral copies/mL) and for *Mycobacterium bovis* in bone marrow and hepatic culture. Despite treatment for the infections, the clinical conditions worsened and the patient developed acute respiratory distress syndrome with fatal outcome at the age of 4.5 months.

Patient B, a 4-year-old girl, was born in Italy to apparently nonconsanguineous Chinese parents (Fig E1, *B*). The patient was admitted for persistent fever, leucocytosis, and a mediastinal mass. She subsequently developed hepatosplenomegaly, anemia, neutropenia, thrombocytopenia, hypertriglyceridemia, and hyperferritinemia. Bone marrow aspirate, performed twice, did not show hemophagocytosis. However, the patient fulfilled 5 of 6 HLH diagnostic criteria examined (Table E1). The patient was positive for EBV infection (180,000 viral copies/mL), while tuberculin skin and Quantiferon-TB test results were, respectively, negative and indeterminate. Interestingly, plasma IFN-γ levels were constitutively high, without further increase in response to mitogen or TB-antigen stimulation (Fig E3, *A* and *B*). Dexamethasone, anti-CD20, and cyclophosphamide and gancyclovir were administrated, leading to partial remission of HLH and infection control. Two weeks later, the patient reactivated (with ferritin up to 395,644 ng/mL) and developed life-threatening conditions. Rabbit antithymocyte globulin was administered with sudden improvement, albeit persistent fever and the onset of ocular and neurologic symptoms. At this point, disseminated infection by *M tuberculosis* was diagnosed by PCR and cultures of blood, cerebral spinal fluid, and eye swab. A 5-drug antitubercular therapy was started with transient control followed by death from multiorgan failure.

METHODS

The studies were approved by the Regional Ethical Review Board in Stockholm, Sweden, and by the Regional Committee in Florence, Italy.

Genetic analyses

Genomic DNA was isolated from peripheral blood according to a standard procedure. Informed consent was obtained from the patients and their relatives. Genes responsible for familial HLH, *IFNGR1*, and *IFNGR2* were analyzed by direct sequencing. For patient A, whole exome sequencing was performed on a HiSeq2000 Illumina machine. Agilent SureSelect v5+UTRs kit was used for target enrichment. The sequencing reads were aligned to the human genome build37 (*hg19)* using BWA/0.7.4.[E2] Unified Genotyper GATK (v.2.5)[E3] and Annovar software (version 2013Jun21)[E4] were used for variant calling and annotation, respectively. Copy number variations were analyzed with the R package ExomeDepth.[E5] RNA was isolated from blood or fibroblasts of patient A and her family members and used for cDNA synthesis and evaluation of *IFNGR2* transcripts according to standard procedures. Primers are available on request. One hundred and fifty healthy controls of Chinese ethnicity were analyzed for the missense variant in *IFNGR1* identified in patient B. Primers are available on request.

Immunologic analyses

Absolute lymphocyte counts were performed according to standard procedures (Trucount, BD Biosciences, San Jose, Calif). PBMCs were isolated by density gradient centrifugation (Lymphoprep, Axis-Shield, Dundee, United Kingdom) and maintained in complete medium (RPMI-1640 supplemented with 2 mM L-glutamine and 10% FBS; all Hyclone, South Logan, Utah). Intracellular expression of perforin was evaluated by using flow cytometry in both patients as previously described.[E6] NK-cell and cytotoxic T lymphocytes degranulation was assessed by using flow cytometry as previously described.[E7] NK-cell cytotoxicity against K562 target cells was evaluated in patient A with a standard 4-hour ^{51}Cr-release assay using PBMCs, as previously described.[E8] To evaluate signal transducer and activator of transcription 1 signaling, PBMCs from patient A were thawed and stained, after overnight incubation, with fixable dead cell stain (Invitrogen, Carlsbad, Calif). PBMCs (1×10^6) were resuspended and either left untreated or stimulated with 500 U/mL IFN-α (PBL Interferon Source, Logan, Utah) or 100 ng/mL IFN-γ (Peprotech, Rocky Hill, NJ) for 30 minutes. The cells were fixed, washed in PBS, and permeabilized for 30 minutes at −20°C (Perm Buffer III, BD Biosciences). The cells were thereafter stained with anti-CD14 and anti–signal transducer and activator of transcription 1 pY701 antibodies (both BD Biosciences). The cells were washed and analyzed by using flow cytometry (LSR Fortessa, BD Biosciences). Dead cells were excluded and monocytes identified by forward scatter and side scatter characteristics and CD14 staining. All analyses were performed using FlowJo software (v9.7.5; Tree Star, Ashland, Ore). IFN-γ release assay was performed using the Quantiferon-TB Gold test (Qiagen, Hilden, Germany) following the manufacturer's instructions. Briefly, whole blood was incubated for 16 hours at 37°C with mitogen (positive control), TB antigen, or nothing (negative control), respectively. Plasma IFN-γ levels were then quantified using an ELISA plate.

REFERENCES

E1. Henter JI, Horne A, Aricó M, Egeler RM, Filipovich AH, Imashuku S, et al. HLH-2004: diagnostic and therapeutic guidelines for hemophagocytic lymphohistiocytosis. Pediatr Blood Cancer 2007;48:124-31.

E2. Li H, Durbin R. Fast and accurate short read alignment with Burrows–Wheeler transform. Bioinformatics 2009;25:1754-60.

E3. DePristo MA, Banks E, Poplin R, Garimella KV, Maguire JR, Hartl C, et al. A framework for variation discovery and genotyping using next-generation DNA sequencing data. Nat Genet 2011;43:491-8.

E4. Wang K, Li M, Hakonarson H. ANNOVAR: functional annotation of genetic variants from high-throughput sequencing data. Nucleic Acids Res 2010;38:e164.

E5. Plagnol V, Curtis J, Epstein M, Mok KY, Stebbings E, Grigoriadou S, et al. A robust model for read count data in exome sequencing experiments and implications for copy number variant calling. Bioinformatics 2012;28:2747-54.

E6. Kogawa K. Perforin expression in cytotoxic lymphocytes from patients with hemophagocytic lymphohistiocytosis and their family members. Blood 2002;99:61-6.

E7. Bryceson YT, Rudd E, Zheng C, Edner J, Ma D, Wood SM, et al. Defective cytotoxic lymphocyte degranulation in syntaxin-11-deficient familial hemophagocytic lymphohistiocytosis 4 (FHL4) patients. Blood 2007;110:1906-15.

E8. Chiang SC, Theorell J, Entesarian M, Meeths M, Mastafa M, Al-Herz W, et al. Comparison of primary human cytotoxic T-cell and natural killer cell responses reveal similar molecular requirements for lytic granule exocytosis but differences in cytokine production. Blood 2013;121:1345-56.

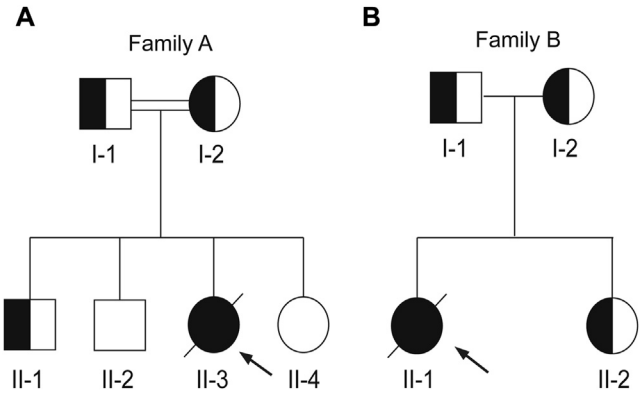

FIG E1. Family pedigree of patient A (II-3) **(A)** and patient B (II-1) **(B)**.

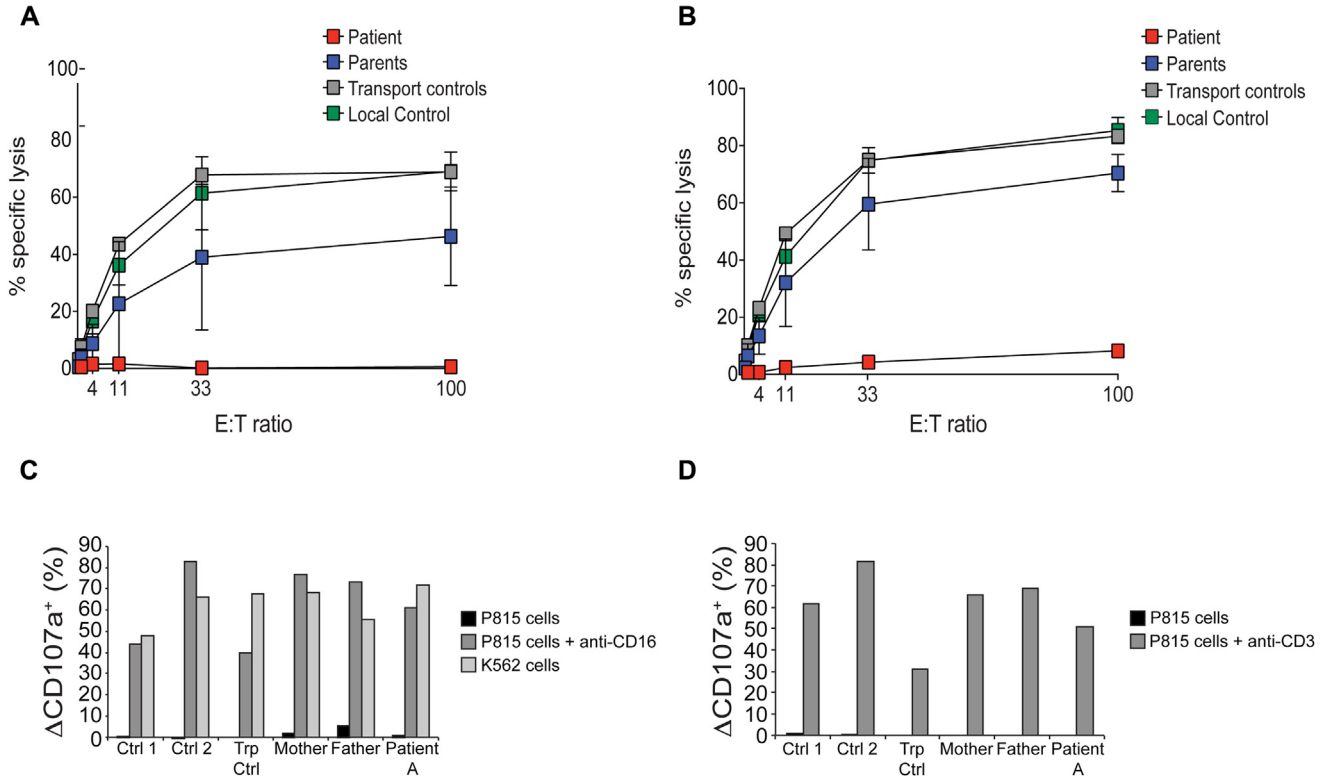

FIG E2. NK-cell cytotoxic activity measured in patient A in resting NK cells **(A)** and after stimulation with IL-2 **(B)**. Flow-cytometry analyses of NK-cell (Fig E2, *A*) and T-cell (Fig E2, *B*) degranulation after stimulation with IL-2 in PBMCs from patient A. *Ctrl*, Control; *Trp*, transport.

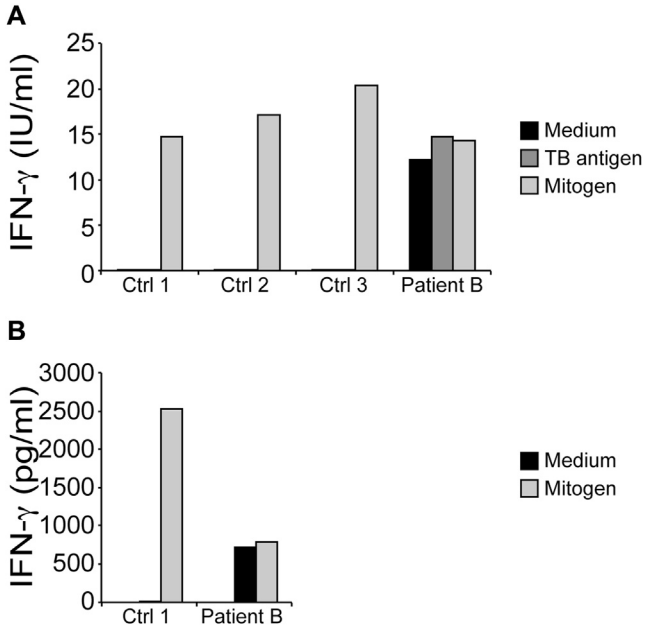

FIG E3. IFN-γ release by patient B and control PBMCs. IFN-γ release was evaluated with 2 different assays that quantified IFN-γ by active units **(A)** or concentration **(B)**. *Ctrl*, Control.

TABLE E1. Clinical and laboratory findings of the patients at disease onset

Finding	A	B
Ethnical origin	Portuguese	Chinese
Familial disease	No	No
Parental consanguinity	Yes	No
Sex	Female	Female
Age at diagnosis of HLH	2 mo	4 y
Fever	Yes	Yes
Splenomegaly	Yes	Yes
Hepatomegaly	Yes	Yes
Hb (g/L)	67	77
Neutrophils (109/L)	2.5	6.7
Platelets (109/L)	10	21
Triglycerides (mmol/L)	15.2	7.4
Fibrinogen (g/L)	0.9	2.7
Hemophagocytosis	No	No
Ferritin (ng/mL)	5,434	36,292
sCD25 (U/mL)	>200,000	nd
NK-cell activity*	Defective	nd
NK-cell degranulation	Normal	Normal
Neurologic manifestations†	None	None
Pathologic CSF	nd	nd
Treatment of active disease	Dexa, CsA, ATG	Dexa, VP16, ATG
Remission at 2 mo	Yes	No
Age at HSCT	Not done	Not done
Outcome	Deceased	Deceased

ATG, Antithymocyte globulin; *CsA*, cyclosporine A; *Dexa*, dexamethasone; *HSCT*, hematopoietic stem cell transplantation; *nd*, no data; *VP16*, ethoposide.
*Defective: 10 lytic units or less.
†Reported at some point during the course of the disease.