World Journal of Clinical Cases

Submit a Manuscript: http://www.f6publishing.com

World J Clin Cases 2018 November 6; 6(13): 707-715

DOI: 10.12998/wjcc.v6.i13.707

ISSN 2307-8960 (online)

CASE REPORT

Highlighting the importance of early diagnosis in progressive multi-organ involvement of IgG4-related disease: A case report and review of literature

Jing Xue, Xue-Mei Wang, Yan Li, Li Zhu, Xiao-Ming Liu, Juan Chen, Shu-Hong Chi

Jing Xue, Xue-Mei Wang, Shu-Hong Chi, Department of Rheumatology, General Hospital of Ningxia Medical University, Yinchuan 750004, Ningxia Hui Autonomous Region, China

Jing Xue, Xiao-Ming Liu, Institute of Human Stem Cell Research, General Hospital of Ningxia Medical University, Yinchuan 750004, Ningxia Hui Autonomous Region, China

Yan Li, Li Zhu, Department of Radiology, General Hospital of Ningxia Medical University, Yinchuan 750004, Ningxia Hui Autonomous Region, China

Juan Chen, Department of Pulmonary and Critical Care Medicine, General Hospital of Ningxia Medical University, Yinchuan 750004, Ningxia Hui Autonomous Region, China

ORCID number: Jing Xue (0000-0002-7143-0011); Xue-Mei Wang (0000-0003-3564-7907); Yan Li (0000-0002-0449-3792); Li Zhu (0000-0002-0368-8985); Xiao-Ming Liu (0000-0002-3902-9105); Juan Chen (0000-0001-5801-9124); Shu-Hong Chi (0000-0003-1141-7605).

Author contributions: Xue J collected patient's clinical data, made a review of the literature and drafted the manuscript; Wang XM, Zhu L, Li Y and Chen J contributed to the acquisition, analysis and interpretation of histopathological findings; Liu XM revised the manuscript and Chi SH participated in collecting patient's clinical data and critically revised the manuscript for intellectual contents; all authors read and approved the final manuscript.

Informed consent statement: Written informed consent was obtained from the patient for publication of this case.

Conflict-of-interest statement: The authors declare that they have no competing interests.

CARE Checklist (2013) statement: The authors have read the CARE Checklist (2013), and the manuscript was prepared and revised according to the CARE Checklist (2013).

Open-Access: This article is an open-access article which was selected by an in-house editor and fully peer-reviewed by external reviewers. It is distributed in accordance with the Creative Commons Attribution Non Commercial (CC BY-NC 4.0) license, which permits others to distribute, remix, adapt, build upon this work non-commercially, and license their derivative works on different terms, provided the original work is properly cited and the use is non-commercial. See: http://creativecommons.org/licenses/by-nc/4.0/

Manuscript source: Unsolicited manuscript

Correspondence to: Shu-Hong Chi, MD, MSc, Associate Professor, Chief Doctor, Department of Rheumatology, General Hospital of Ningxia Medical University, 804 Shengli South Street, Xingqing District, Yinchuan 750004, Ningxia Hui Autonomous Region, China. chi794613@163.com
Telephone: +86-951-6744457

Received: July 31, 2018
Peer-review started: July 31, 2018
First decision: August 24, 2018
Revised: September 16, 2018
Accepted: October 11, 2018
Article in press: October 11, 2018
Published online: November 6, 2018

Abstract

IgG4-related disease (IgG4-RD) is an increasingly recognized pathological entity that tends to involve multiple organs with an elevated level of serum IgG4, which is easily misdiagnosed owing to sharing common clinical features with a variety of other diseases. Here, we report an interesting IgG4-RD case of a woman with progressive multi-organ involvement for over 19 years, started with swollen eyelids, dry eye and mouth, and polydipsia and hydruria. Imaging diagnosis revealed diffuse enlargement of the parotid glands, enlargement of the head of the pancreas, pulmonary infection and interstitial lung. Serological tests showed a remarkable

elevation of the serum IgG4, and cytological analysis further revealed a large amount of lymphoplasmacytic infiltration into the focal lobule, and IgG4-positive cell infiltration in bladder mucosa. Therapeutically, the patient responded well to steroid therapy, and thus, she was diagnosed as IgG4-RD suspicious. This report highlights the importance of an early diagnosis in this autoimmune disease and suggests that patients with a clinically unclear cause of inflammation, swelling and refractory glands, rhinitis, pancreatitis, hypophysitis, and/or interstitial pneumonia should be considered for IgG4-RD. The plasma IgG4 level and lymphoplasmacytic infiltration may be useful indexes for screening, and a low dose of steroid maintaining therapy may offer benefits for patients with IgG4-RD.

Key words: IgG4; IgG4-related disease; Autoimmune disease; Steroid therapy

© The Author(s) 2018. Published by Baishideng Publishing Group Inc. All rights reserved.

Core tip: IgG4-related disease (IgG4-RD) is an easily misdiagnosed immune disorder with an elevated serum IgG4 and multiple organ involvements. Hence, it is important in early diagnosis for guiding clinical treatments. Here, we report an interesting case of a woman with progressive multi-organ involvement of IgG4-RD for 19 years. The 67-year-old woman has suffered from progressive diseases of multiple organs, including lacrimal glands, kidneys, parotid glands, submandibular glands, salivary glands, pituitary, pancreas and lung. Patients with IgG4-RD normally respond well to steroid therapy; however, the broad spectrum of manifestation with commonly clinical features of other diseases easily leads to misdiagnosis and improper treatment in clinical settings. Therefore, this report highlights the importance of early diagnosis in this autoimmune disease.

Xue J, Wang XM, Li Y, Zhu L, Liu XM, Chen J, Chi SH. Highlighting the importance of early diagnosis in progressive multi-organ involvement of IgG4-related disease: A case report and review of literature. *World J Clin Cases* 2018; 6(13): 707-715 Available from: URL: http://www.wjgnet.com/2307-8960/full/v6/i13/707.htm DOI: http://dx.doi.org/10.12998/wjcc.v6.i13.707

INTRODUCTION

IgG4-related disease (IgG4-RD) is a systemic and clinical entity with autoimmune pathogenesis, which is characterized by a high level of circulating IgG4 and a dramatic response to steroid therapy[1]. It was first identified in patients with autoimmune pancreatitis (AIP) that was initially described in patients with chronic pancreatitis[2,3]. Although its etiology has not yet been fully determined, the clinical spectrum of this disorder is extremely broad from manifestation in a single organ (pancreas, kidneys, salivary gland, orbit, skin, lungs, prostate, biliary tree, liver, and pituitary gland) to involvement of multiple organs[4,5]. Tumefactive lesions of involved organs (mainly lacrimal glands, pancreas and salivary glands) with pseudotumoral swelling and sclerosis are often its main clinical manifestation. Histopathologically, the involved organs of IgG4-RD are infiltrated with lymphocytes, IgG4-positive plasma cells and variable degrees of fibrosis[1].

Most cases of IgG4-RD occur in middle-aged and elderly males, and here, we retrospectively report a female case with progressive multi-organ involvement of IgG4-RD with over 19 years of disease duration, which highlights the importance in early diagnosis and intervention of IgG4-RD in clinical settings.

CASE REPORT

Written informed consent was obtained from the patient for publication of this case. The ethics committee of the human research of the General Hospital at Ningxia Medical University approved the informed consent for reporting this case. Table 1 lists the clinical history, examinations and treatment of this patient.

A 60-year-old woman who had no medical history was admitted because of the traumatic rib fracture to our hospital in November of 2011. She observed an ophthalmologist at a local hospital for left eyelid swelling with a feeling of sand in the eye without any known cause late in 1999. She was first diagnosed with "allergic rhinitis" and was externally treated with eye drops (an ointment) of dexamethasone and sodium chromate. However, no obvious efficacy was observed. The symptoms gradually worsened. Computed tomography (CT) showed an enlargement of double lacrimal glands (Figure 1A) and was treated as "non-specific, non-infective orbital inflammatory pseudotumor" by taking prednisone 60 mg/d, together with roxithromycin and eye drops. The efficacy was only observed at the beginning of the treatment. There was no obvious improvement observed. Follow up CT) 2 years late showed an enlargement of double lacrimal glands, and the pathological findings showed a double lacrimal lymphoid pseudotumor in surgical resections of the bilateral lacrimal glands and fat pads. Although the symptom of swelling of the eyelids was improved after the surgery, the dryness of the eyes, nasal cavity and mouth required the patient for a long-term application of artificial tears.

In May 2005, the patient had symptoms of repeated diffuse swelling of the parotid glands as diagnosed by CT (Figure 1B), but no treatment was undertaken until she was admitted to our hospital with repeated severe gastric pains in November of 2005. Abdominal CT showed an enlargement of the head of pancreas (Figure 2), and the blood routine examination showed a neutrophil count of LYM%: 50.9% (20.0-50.0), LYM#: 2.11 × 10^{-9}/L (1.10-3.20), EOS%: 13.6% (0.4-8.0), EOS#: 0.78 × 10^{-9}/L (0.02-0.50), NEUT%: 68.0% (50.0-70.0), NEUT#: 6.62 × 10^{-9}/L (2.00-7.00) (Table 1). The endoscopic retrograde cholangiopancreatography

Table 1 Main laboratory work-up, imaging and histology studies from 2000 to 2018

Time	Investigations	Results
February 10, 2000	Physical examination	Non-specific, non-infective orbital inflammatory pseudotumor
July 9, 2003	CT	Enlargement of double lacrimal glands, parotid glands
	Lacrimal glands biopsy	Lymphonid pseudotumor of double lacrimal glands
May 21, 2005	CT	Enlargement of parotid glands
	B-ultrasonography	Diffused enlargement of parotid glands
November 2, 2005	Blood routine examination	LYM%: 50.9% (20.0-50.0), LYM#: 2.11 × 10^{-9}/L (1.10-3.20), EOS%: 13.6% (0.4-8.0), EOS#: 0.78 × 10^{-9}/L (0.02-0.50), NEUT%: 68.0% (50.0-70.0), NEUT#: 6.62 × 10^{-9}/L (2.00-7.00)
	Biochemistry	AST: 628.5 U/L (13.0-35.0), ALT: 648.4 U/L (7.0-40.0), ALP: 356 U/L (50-135), GGT: 422.9 U/L (7.0-45.0)
	CT	Enlargement of the head of pancreas
December 4, 2005	ERCP	Implantation of a biliary stent
March 6, 2006	IGG, RF	High levels of serum IgG, RF, Ig light chain KAP, Ig light chain LAM
March 31, 2006	ERCP	Implantation of two biliary stents
	Biopsy	Extensive lymphatic plasma cell infiltrated in focal lobular, salivary gland tissue was under the squamous mucosa
July 8, 2006	IGG, RF	Low levels of serum complement C3 and IgG and Ig light chain KAP, high level of Ig light chain LAM
November 4, 2006	Complement	Low level of serum complement C3
	ENA antibody, ANA	HEp2-ANA: positive 1:100 (< 1;100), ENA-AbSSA: negative, ENA-AbSSB: negative
November 8, 2006	ERCP	Remove of the biliary stent
November 26, 2006	CT	No enlargement of the head of pancreas
	Physical examination	Normal eyeball, normal conjunctiva, eyelids without edema, normal light reaction
September 4, 2007	Blood routine examination	Normal parameters
September 6, 2007	Endocrine examinations	Details seen in Table 2
October 10, 2007	Renal function examination	Normal function
May 17, 2008	MRI	Pituitary stalk thickening
October 7, 2009	CT	Enlargement of the head of pancreas
November 13, 2009	Blood routine examination	LYM%: 46.0% (20.0-50.0), LYM#: 1.92 × 10^{-9}/L (1.10-3.20), EOS%: 23.1% (0.4-8.0), EOS#: 0.89 × 10^{-9}/L (0.02-0.50), NEUT%: 49.0% (50.0-70.0), NEUT#: 5.83 × 10^{-9}/L (2.00-7.00)
December 14, 2009	MRI	Enlargement of the head of pancreas
September 20, 2011	CT	Normal volume of the head of pancreas
November 22, 2011	Bone scan	Rib fracture
November 23, 2011	Blood routine examination	LYM%: 22.6% (20.0-50.0), LYM#: 1.85 × 10^{-9}/L (1.10-3.20), EOS%: 11.1.% (0.4-8.0), EOS#: 0.97 × 10^{-9}/L (0.02-0.50), NEUT%: 59.0% (50.0-70.0), NEUT#: 4.83 × 10^{-9}/L (2.00-7.00)
	IGG, RF	High levels of IgE, RF
November 24, 2011	IGG	IgG1: 7.670 g/L (4.900-11.400), IgG2: 3.540 g/L (1.500-6.400), IgG3: 0.103 g/L (0.200-1.100), IgG4: 8.650 g/L (0.020-2.000)
	IGG, RF	High levels of serum IgE and RF
July 5, 2012	Blood routine examination	LYM%: 38.9% (20.0-50.0), LYM#: 3.99 × 10^{-9}/L (1.10-3.20), EOS%: 1.6% (0.4-8.0), EOS#: 0.16 × 10^{-9}/L (0.02-0.50), NEUT%: 51.8% (50.0-70.0), NEUT#: 5.32 × 10^{-9}/L (2.00-7.00)
July 10, 2012	MRI	Normal shapes of pituitary gland, lung and pancreas
April 3, 2018	Blood routine examination	EOS%: 0.0% (0.4-8.0), EOS#: 0.00 × 10^{-9}/L (0.02-0.50), LYM%: 15.0% (20.0-50.0), LYM#: 1.72 × 10^{-9}/L (1.10-3.20), NEUT%: 82.6% (50.0-70.0), NEUT#: 9.44 × 10^{-9}/L (2.00-7.00)
	Urinalysis	Normal, Only the WBC count 26.3/uL (0.0-23.0)
	Biochemistry	UREA: 2.10 mmol/L (3.10-8.80), ALB: 36.10 g/L (40.00-55.00), AST: 43.6U/L (13.0-35.0), ALP: 43U/L (50-135), GGT: 5.1 U/L (7.0-45.0)
	IGG, Complement, RF	IgG: 25.10 g/L (7.00-16.00), IgA:1.51 g/L (0.70-4.00), IgM: 0.45 g/L (0.40-2.30g/l), C3: 0.56 g/L (0.90-1.80), C4: 0.088 g/L (0.100-0.400), RF: 356.00 IU/mL (0.00-19.00), IgG4: 23.300 g/L (0.020-2.000)
	CT	Severe interstitial lung lesions
	Bladder biopsy	Chronic inflammation
May 7,2018	IGG	IgG4: 5.280 g/L (0.020-2.000)
	CT	Normal

ANA-HEp-2: Anti-Nuclear Antibodies HEp-2; CT: Computed tomography; ERCP: Endoscopic retrograde cholangio pancreatography; ENA: Extractable nuclear antigens; NEUT: Neutrophil count; AST: Aspartate transferase; ALT: Alanine aminotransferase; ALP: Alkaline phosphatase; GGT: Gamma glutamyl transpeptidase; Ig: Immunoglobulin; KAP: Kappa; LAM: Lambda; MRI: Nuclear magnetic resonance image; RF: Rheumatoid factor; WBC: White blood cell; RBC: Red blood cell; EOS: Eosinophils; LYM: Lymphocyte; LYM#: The absolute value of lymphocyte; PCT: Platelet distributing width; ESR: Erythrocyte sedimentation rate; ALB: Albumin; IgG: Immunoglobulin G; IgA: Immunoglobulin A; IgM: Immunoglobulin M; C3: Complement 3; C4: Complement 4.

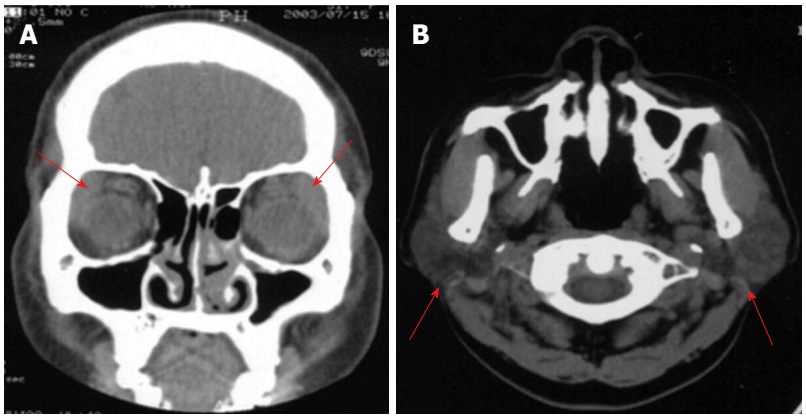

Figure 1 Involvement of the lacrimal gland parotid gland. A: Computed tomography (CT) showing double lacrimal gland swelling on both sides; B: CT showing enlargement of the parotid gland.

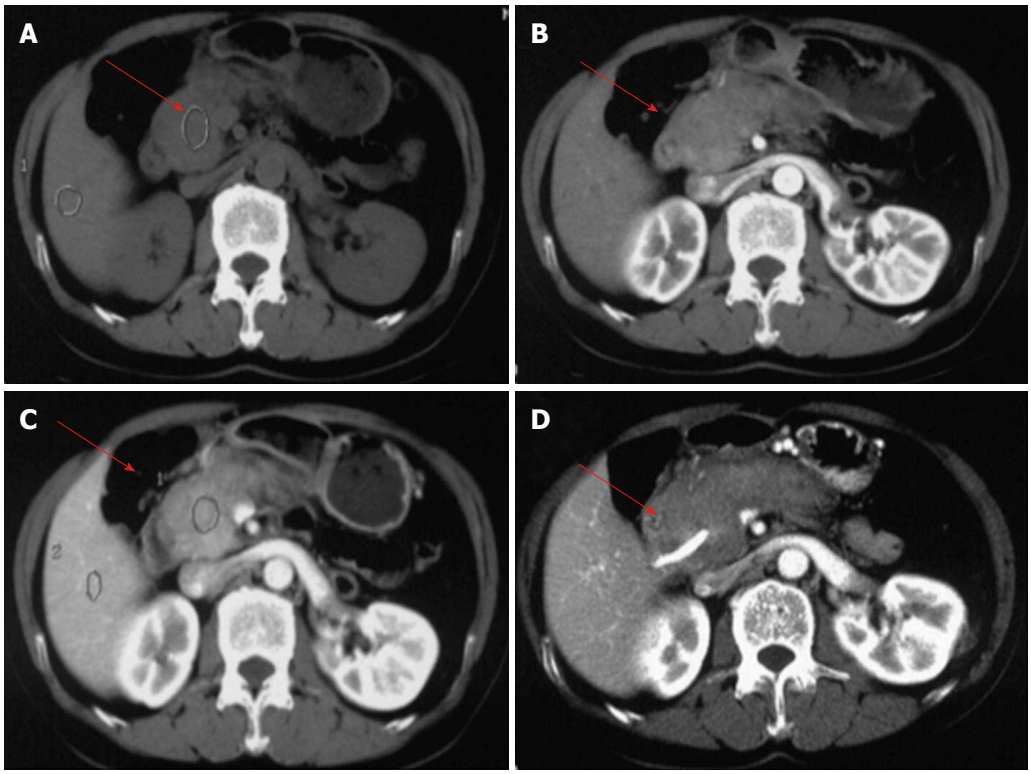

Figure 2 Involvement of pancreas and bile duct. Abdominal computed tomography (CT) showed enlargement of the head of the pancreas. A: Plain scan showing the enlargement of the head of pancreas; B: Arterial phase showed a slight homogeneous enlargement; C: Portal phase showed an obvious enlargement of the pancreas; D: CT showed the bile duct stricture.

(ERCP) further showed bile duct (biliary) stricture and biliary sludge, and thus, severe acute cholestasis pancreatitis was diagnosed. The patient underwent bile duct dredging and a biliary stent implantation. However the patient was re-admitted to hospital because of severe abdominal pains, along with complications of fever, and obvious swelling of the left parotid gland and both sides of the submandibular glands four month late. A second ERCP showed no obvious tumor signs. Thus, an additional two biliary stents were implanted. The pathology of labial gland biopsy showed lymphoplasmacytic infiltration into the focal lobules of the salivary gland tissue beneath the squamous mucous epithelia, with low level of serum complement C3, positive HEp2-ANA 1:100 (< 1;100), but negative ENA-AbSSA: negative, ENA-AbSS (Table 1). Therefore, Sjogren's syndrome was considered. A pulse therapy of a combination of steroid and gamma globulin with 200 mg, 500 mg, 500 mg of methylprednisolone, respectively, and 20 g of gamma globulin was performed for three consecutive days. In addition, she was prescribed oral prednisone, hydroxychloroquine sulfate, total glucosides of paeony and methotrexate until her symptoms were significantly relieved. The above oral medicines were then gradu-

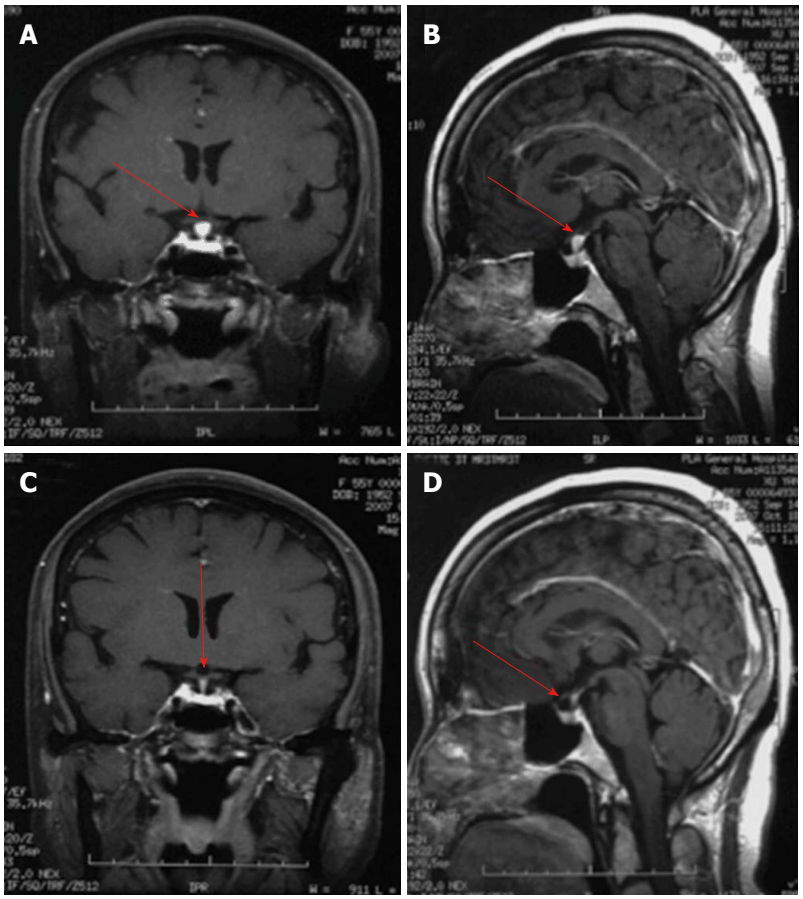

Figure 3 Involvement of the pituitary gland. Magnetic resonance imaging showed the change of pituitary stalk nodular thickening. A: Coronal view clearly showed pituitary stalk nodular thickening (arrow); B: Sagittal view clearly showed pituitary stalk nodular thickening (arrow); C: Coronal view showing a significantly reduced pituitary stalk (arrow); D: Sagittal view showed a significantly reduced pituitary stalk (arrow).

ally tapered after her clinical condition had improved. Together with the efficacy of steroid treatments, CT, laboratory results and symptoms, she was finally diagnosed with Sjogren's syndrome with AIP. A six-month follow-up demonstrated a stable condition, and CT showed no enlargement of the head of pancreas, and therefore, a third ERCP was performed to remove the three implanted biliary stents.

However, she was re-admitted to hospital because of symptoms of polydipsia and polyuria, accompanied with fatigue and weight loss in August 2007. Remarkably, she could drink water as much as 11000 mL/d and urinate as much as 10400 mL/d. Magnetic resonance imaging (MRI) showed pituitary stalk nodular thickening (Figure 3). Endocrinal examinations revealed an increased concentration of N-acetyl-β-D-glucosaminidase (NAG) and serum follicle stimulating hormone (FSH), with a decreased level of serum luteinizing hormone (LH) and prolactin (PRL) (Table 2). However, the renal examination suggested normal renal function. She was considered to have lymphocytic hypophysitis and diabetes insipidus and was given methylprednisolone pulse therapy for 12 d (600 mg × 3 d, 400 mg × 3 d, 200 mg × 3 d, 100 mg × 3 d), and oral desmopressin acetate tablets (Minirin®). Afterward, the patient was given oral prednisone 60 mg/d and gradually tapered. The above clinical conditions were significantly improved. Unexpectedly, the patient revisited the hospital with right lung infection in May 2008. The condition improved after an antibiotics treatment but showed symptoms of polydipsia and polyuria. The cranial brain MRI examination showed pituitary stalk thickening. She was given 500 mg of methylprednisolone pulse therapy for 3 d, and continuously took oral leflunomide, prednisone, hydroxychloroquine sulfate, total elixir (Pavulin), desmopressin acetate tablets and calcium supplements until her condition was improved. The oral prednisone was taken and gradually tapered as she was discharged from the hospital. The patient continued to take a low dose of prednisone (5.0 mg/d) and her condition was stable.

Of note, follow-up CT and MRI examinations revealed that the enlargement of the head of the pancreas was not significantly improved with low signal intensity on T2WI and T1WI in 2009, although the head of pancreas became normal as evaluated by abdominal CT when she was re-admitted to the hospital with nasal congestion with coughing and chest pain (but without fever and chilling) in November 2011 (Table 1). Chest CT showed right lung infection and interstitial lung lesions (Figure 4A). Antibiotic therapy did not improve her clinical conditions. Bone scan showed a rib fracture; blood tests demonstrated high neutrophil and eosinophilic cell cou-

Table 2 Endocrine examinations in September 2007

Date	Serum osmotic pressure (270-300 mOsm/L)	Urine osmotic pressure (400-1200 mOsm/L)	Urine NAG enzyme (0-21 U/gCr)
September 24	289 mOsm/L	62 mOsm/L	-
September 25	298 mOsm/L	65 mOsm/L	87.5 U/gCr
September 28	300 mOsm/L	148 mOsm/L	106.5 U/gCr

	Serum prolactin (PRL) (μg/L)					
September 30	Pre-stimulation with metoclopramide (10 mg)		Post-stimulation with metoclopramide (10 mg)			
	15 min	0 min	15 min	30 min	60 min	90 min
	28.66	29.28	38.78	35.22	38.66	39.84

September 30	Changes of serum hormone levels							
	Testosterone	Estrogen	LH	PRL	FSH	Progestone	Cortisol	
	-	-	↓	↑	↓	-	12:00 AM	8:00 AM
							-	-

FSH: Follicle stimulating hormone; LH: Luteinizing hormone; NAG: N-acetyl-β-D-glucosaminidase; PRL: Prolacin.

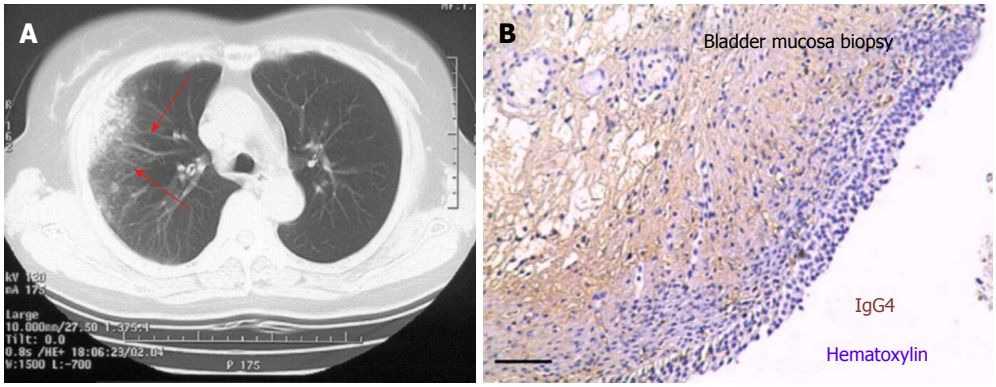

Figure 4 Involvement of lung and bladder mucosa. A: Chest computed tomography showing interstitial pulmonary lesions (arrows) in the lung; B: Immunohistochemical (IHC) staining of IgG4 showed detectable IgG protein and IgG4-positive cell infiltration in bladder mocosa biopsy (bar = 50 μm).

nts and high levels of serum IgE and rheumatic factor (RF); IgG examination further revealed strikingly higher levels of serum IgG4 at 8.65 g/L compared to the normal range of 0.02 g/L-2.00 g/L (Table 1). The patient was thus diagnosed as IgG4-RD suspicious. The patient was then given pulse therapy by intravenously infusion with 200 mg of methylprednisolone and 20 g of gamma globulin for 3 d, combined with intravenous injection of 10 mg of incadronate disodium for anti-osteoporosis therapy. She was discharged from the hospital after her condition had improved. During 2012 to 2014, she was given steroids and immunosuppressants as maintenance therapy.

In May 2015, the patient was re-admitted to the hospital because of double traumatic rib fractures, along with complications of cough. She was diagnosed as with an IgG4-RD relapse, chronic obstructive pulmonary disease, diabetes mellitus type Ⅱ, severe osteoporosis, rib fracture, cervical degeneration and lumbar disc herniation. The patient was treated with methylprednisolone 16 mg/d, lefluramide 20 mg/d and hydroxychloroquine 0.2 g/d to control the primary disease, and other agents for osteoporosis treatment for one month. She was stable for one year before being considered as the relapse of IgG4-RD. The treatment of orally giving methylprednisolone 4.0 mg/d, lefluramide 20 mg/d, hydroxychloroquine 0.2 g/d and thymopentin on a routine base, along with anti-infective, anti-diabetic agents and a calcium supplement, was effective.

Most recently, the patient was re-admitted to the hospital because of symptoms of polydipsia and polyuria, burning and pain in April 2018. The serum IgG examination further revealed a strikingly higher level of serum IgG4 at 23.3 g/L, urine tests showed a high number of white blood cell (WBC) counts, and chest CT showed severe interstitial lung lesions. A bladder biopsy showed chronic inflammation with IgG4-positive infiltration (Figure 4B). The patient was given oral prednisolone 60 mg/d, iguratimod 50 mg/d and antibiotic therapy for three weeks. One month later, the serum concentration of IgG4 was decreased to 5.28 g/IgG (Table 1), Chest CT also showed a normal lung image. The condition of this patient is currently stable with a maintenance steroid therapy.

DISCUSSION

IgG consists of four subclasses, and among them IgG4 is the least abundant subclass in the serum with an average concentration of 0.30-0.465 g/L[6]. Functionally, IgG4 can react with hapten exchanges owing to its special structure and function in biochemistry. Chemically, disulfide bonds between IgG4 heavy chains are not stable, leading to the heavy chain separating and

recombining randomly. Therefore, IgG4 is theoretically incapable of effectively activating the immune effector cell and classical pathway of complements. However, the immune imbalance and autoantibody induced by allergen exposure may trigger IgG4-RD[7]. In this regard, IgG4 can enhance Th2 and Treg-mediated immunoreactions[8]. The Th2 cell-produced IL-4/IL-13 can in turn convert B cells to produce IgG4 and IgE, and the IL-10 produced by Th2 and Treg cells also tends to transform IgG4[9]. In addition, the repeated allergen exposure also enhances Th2 reactions that results in the clearance of plentiful B cells from IgE conversion. B cells survive after IgG4 conversion, TGF-β from Treg-facilitated fibrosis. These processes may contribute to pathological manifestations of special IgG4-RD to some extent. In this context, IgG4-RD can be involved in multiple organs, without a specific clinical symptom in the early stages of this disease. Therefore, an early diagnosis of IgG4-RD has an important clinical significance. However, the broad spectrum of clinical manifestations of IgG4-RD in different organs, *i.e.*, each organ may demonstrate special manifestations, and present various clinical symptoms, may cause misdiagnosis and prevent early diagnosis of this disease.

Clinically, an early diagnosis of IgG4-RD remains a challenge, owing to its symptoms and pathology mimicking several other diseases such as infections and malignancies, even if the IgG4-RD diagnostic criteria are followed[10]. For example, clinically, IgG4-RD often presents with multifocal tumor-like masses that leads to confusions with malignancy. In the present report, we present a female patient who suffered from progressive IgG4-RD in multi-organs for nineteen years (1999-2018), before and after her IgG4-RD was confirmed. Obviously, in addition to the typical pancreas involvement (AIP), the patient was affected in other organs including the eye orbit, lacrimal gland, parotid gland, pituitary and lung. Although the main complaint was gastric pain with yellow jaundice in this case, progressive disorders of other involved organs occurred.

IgG4-RD is considered to be a rare disorder, but it is often overlooked and misdiagnosed. It may take several years before the diagnosis is made. From the diagnostic standpoint, although it may be difficult to establish a diagnostic criteria covering all IgG4-RD, the "Japanese Research Committee of IgG4-RD" proposed the comprehensive diagnostic criteria (CDC) for IgG4-RD in 2011[11]. These criteria included: (1) one or more organs experience diffuse/focal swelling; (2) serum IgG4 > 135 mg /dL; (3) the histological pattern of lesions is fibro-inflammatory, with a lymphoplasmocytic infiltration of IgG4-positive plasma cells and storiform pattern of fibrosis, and the ratio of IgG4/IgG-positive plasma cell is above 40% in tissues; and (4) immunohistochemistry showed more than 10 IgG4-positive plasma cells per high powered field (HPF). A patient who conforms to all above four criteria can be diagnosed as IgG4-RD, those who conform to three of above four criteria can be diagnosed as IgG4-RD probable, and any who conform to the above two of above four criteria can be diagnosed as IgG4-RD suspicious[4,12,13]. In the same year at the "IgG4-RD" international conference held in the United States, researchers reached a consensus that the diagnosis of IgG4-RD should primarily rely on pathological features rather than IgG-positive plasma cell count and ratio, although they are an essential condition of diagnosis[14]. In this case, the patient at least fulfills two of above criteria: (1) one or more organs experience diffuse/focal swelling; and (2) serum IgG4 > 135 mg /dL, and therefore was diagnosis as diagnosed as IgG4-RD suspicious.

This patient was very responsive to steroid and immunosuppressant therapies, but the patient reported in this case was misdiagnosed as a single involved organ disorder many times, highlighting the importance of systemic and comprehensive evaluation of symptoms, CT and MRI imaging results, laboratory data and histology of biopsies in the diagnosis of IgG4-RD. Unfortunately, a determination of infiltrated IgG4-positive plasma cells was not performed in biopsies of involved organs of this patient. In addition, the overlooking concentration of serum IgG4 was another main reason to delay the clinical diagnosis of IgG4-RD in this case.

In conclusion, IgG4-RD is a complicated clinical syndrome that is currently short of diagnostic criteria, and is easy to be misdiagnosed. The present case is a typical IgG4-RD in a woman with progressive multiple organ involvement, including lacrimal glands, parotid glands, pancreas, lungs and pituitary during the long course of the disease progression. From therapeutic standpoint, patients with IgG4-RD respond well to steroid therapy, and/or immunosuppressive agents resulted in a significant remission of disease and improved patient conditions. However, the disease can easily recur after the steroid is reduced or withdrawn.

Importantly, adverse effects of severe clinical complications such as osteoporotic fractures and infections were observed in this patient during the long-term steroid therapy. Therefore, it is critical to give pulse therapy with high doses of steroid in combination with immunosuppressive agents during the active disease period of the disease in clinical settings, which may avoid disease recurrence during the reduction of the steroid. Equally noteworthy, in addition to clinical symptoms, concentrations of serum IgG4, IgE, ESR, CRP and other laboratory results may allow us to identify disease activity early. An early identification of disease activity may allow us to adjust the treatment regimen and avoid severe complications caused by an overdose of steroid treatment. From a diagnostic standpoint, the early disease symptoms are generally mild with an involvement of one or two organs for a long time period, before it gradually develops to involve multiple organs with life-threatening complications. Thus, this case emphasizes a clinical importance in the early diagnosis and interventions for IgG4-RD. In this regard, patients with a clinically unclear cause of inflammation, swelling and refractory glands (such as the lacrimal gland, parotid

gland and thyroid), rhinitis, pancreatitis, hypophysitis, and/or interstitial pneumonia should be considered as to the possibility of IgG4-RD and recommended for the plasma IgG4 test, which may provide important diagnostic data and clues for this disease, although the immunohistological examination is required for confirmation.

ARTICLE HIGHLIGHTS

Case characteristics

A sixty-seven-year-old female presented with a progressive multi-organ involvement of IgG4-related disease (IgG4-RD) for over 19 years.

Clinical diagnosis

As a disorder with multiple organ involvement, IgG4-RD presents no specifically clinical manifestation for an early diagnosis, and the diagnosis largely relies on a combination of clinical manifestation, histology, imaging, and serology.

Differential diagnosis

IgG4-RD has a broad spectrum of clinical manifestations and it is important to differentially diagnosis it from various diseases of the involved organs, such as Mikuri's disease, autoimmune pancreatitis, interstitial pneumonia and retroperitoneal fibrosis.

Laboratory diagnosis

A significantly increased serum IgG4 level (> 1350 mg/L) is a signal for serological diagnosis in IgG4-RD.

Imaging diagnosis

Computed tomography, magnetic resonance imaging or endoscopic retrograde cholangiopancreatography imaging showed a swollen feature or tumor-like structure in the involved organs.

Pathological diagnosis

IgG4-positive lymphocyte infiltration and sclerosis in the involved organs.

Treatment

The patient was given methylprednisolone 200 mg/d pulse therapy for 3 d, a large dose of gamma globulin (20 g/d) intravenous infusion for 3 d and taking oral prednisolone 30 mg/d for three weeks. The prednisolone was then gradually tapered.

Related reports

Patients with a clinically unclear cause of inflammation, swelling and refractory glands (such as the lacrimal gland, parotid gland and thyroid), rhinitis, pancreatitis, hypophysitis, and/or interstitial pneumonia should be considered for the possibility of IgG4-RD and recommended for plasma IgG4 test.

Term explanation

IgG4-RD is a systemic and clinical entity with autoimmune pathogenesis, which is characterized by high levels of circulating IgG4 and a dramatic response to steroid therapy.

Experiences and lessons

Since the clinical manifestations of IgG4-RD are commonly similar to features of other diseases, it is easily misdiagnosed and improperly treated. This case emphasizes a clinical importance of the early diagnosis and interventions for IgG4-RD. From a diagnostic standpoint, the early disease symptoms are generally mild with an involvement of one or two organs for a long time before they gradually develop into multiple organ involvements with life-threatening complications. Apart from clinical symptoms, concentrations of serum IgG4, IgE, ESR, CRP and other laboratory results may provide important diagnostic data and clues for early identity disease activities. From a therapeutic standpoint, patients with IgG4-RD respond well to steroid therapy, and/or immunosuppressive agents resulting in a significant remission of disease and improved patient conditions. Notably, the disease can easily recur after the steroid is reduced or withdrawn. To reduce the adverse effects of long-term steroid therapy, it is critical to give pulse therapy with high doses of steroids in combination with immunosuppressive agents during the active disease period of the disease in clinical settings.

ACKNOWLEDGEMENTS

The authors cordially thank the patient for her acceptance to publish her personal medical data and all members participated in the diagnosis and treatment of this case in the General Hospital at Ningxia Medical University, China.

REFERENCES

1 **Umehara H**, Okazaki K, Nakamura T, Satoh-Nakamura T, Nakajima A, Kawano M, Mimori T, Chiba T. Current approach to the diagnosis of IgG4-related disease - Combination of comprehensive diagnostic and organ-specific criteria. *Mod Rheumatol* 2017; **27**: 381-391 [PMID: 28165852 DOI: 10.1080/14397595.2017.1290911]

2 **Aithal GP**, Breslin NP, Gumustop B. High serum IgG4 concentrations in patients with sclerosing pancreatitis. *N Engl J Med* 2001; **345**: 147-148 [PMID: 11450670 DOI: 10.1056/NEJM200103083441005]

3 **Yoshida K**, Toki F, Takeuchi T, Watanabe S, Shiratori K, Hayashi N. Chronic pancreatitis caused by an autoimmune abnormality. Proposal of the concept of autoimmune pancreatitis. *Dig Dis Sci* 1995; **40**: 1561-1568 [PMID: 7628283 DOI: 10.1007/BF02285209]

4 **Kamisawa T**, Okazaki K, Kawa S, Ito T, Inui K, Irie H, Nishino T, Notohara K, Nishimori I, Tanaka S, Nishiyama T, Suda K, Shiratori K, Tanaka M, Shimosegawa T; Working Committee of the Japan Pancreas Society and the Research Committee for Intractable Pancreatic Disease supported by the Ministry of Health, Labour and Welfare of Japan. Amendment of the Japanese Consensus Guidelines for Autoimmune Pancreatitis, 2013 III. Treatment and prognosis of autoimmune pancreatitis. *J Gastroenterol* 2014; **49**: 961-970 [PMID: 24639058 DOI: 10.1007/s00535-014-0945-z]

5 **Xiao X**, Lian M, Zhang W, Eric Gershwin M, Ma X. The Immunologic Paradoxes of IgG4-Related Disease. *Clin Rev Allergy Immunol* 2018; **54**: 344-351 [PMID: 29460058 DOI: 10.1007/s12016-018-8679-y]

6 **Rungsakulkij N**, Sornmayura P, Tannaphai P. Isolated IgG4-related sclerosing cholangitis misdiagnosed as malignancy in an area with endemic cholangiocarcinoma: a case report. *BMC Surg* 2017; **17**: 17 [PMID: 28202062 DOI: 10.1186/s12893-017-0214-1]

7 **Celis IM**, Kriekaart RL, Aliredjo RP, van Lochem EG, van der Vorst MJ, Hassing R. IgG4-related disease: a disease we probably often overlook. *Neth J Med* 2017; **75**: 27-31 [PMID: 28124667]

8 **Zen Y**, Fujii T, Harada K, Kawano M, Yamada K, Takahira M, Nakanuma Y. Th2 and regulatory immune reactions are increased in immunoglobin G4-related sclerosing pancreatitis and cholangitis. *Hepatology* 2007; **45**: 1538-1546 [PMID: 17518371 DOI: 10.1002/hep.21697]

9 **Robinson DS**, Larché M, Durham SR. Tregs and allergic disease. *J Clin Invest* 2004; **114**: 1389-1397 [PMID: 15545986 DOI: 10.1172/JCI200423595]

10 **Xiao J**, Li G, Yang G, Jia C, Li B. Case report: A female case of isolated IgG4-related sclerosing cholangitis mimicking cholangiocarcinoma. *Medicine* (Baltimore) 2017; **96**: e6542 [PMID: 28422840 DOI: 10.1097/MD.0000000000006542]

11 **Okazaki K**, Umehara H. Are Classification Criteria for IgG4-RD Now Possible? The Concept of IgG4-Related Disease and Proposal of Comprehensive Diagnostic Criteria in Japan. *Int J Rheumatol* 2012; **2012**: 357071 [PMID: 22690221 DOI: 10.1155/2012/357071]

12 **Kawano M**, Saeki T, Nakashima H, Nishi S, Yamaguchi Y, Hisano S, Yamanaka N, Inoue D, Yamamoto M, Takahashi H, Nomura H, Taguchi T, Umehara H, Makino H, Saito T. Proposal for diagnostic criteria for IgG4-related kidney disease. *Clin Exp Nephrol* 2011; **15**: 615-626 [PMID: 21898030 DOI: 10.1007/s10157-011-0521-2]

13 **Matsuda K**, Saito A, Takeuchi Y, Fukami H, Sato H, Nagasawa T. IgG4-Related Disease Manifesting as Interstitial Nephritis Accompanied by Hypophysitis. *Am J Case Rep* 2017; **18**: 593-598 [PMID: 28552902 DOI: 10.12659/AJCR.902187]

14 **Mikumo H**, Hamada N, Harada E, Yanagihara T, Ogata S, Yabuuchi H, Ijichi K, Takayama K, Nakanishi Y. A case of immunoglobulin G4-related respiratory disease with multiple lung cysts: A case report. *Respir Med Case Rep* 2017; **21**: 89-92 [PMID: 28443233 DOI: 10.1016/j.rmcr.2017.03.023]

P- Reviewer: Ferrante A, Kai K, Rosales C **S- Editor**: Ji FF
L- Editor: A **E- Editor**: Tan WW

Published by **Baishideng Publishing Group Inc**
7901 Stoneridge Drive, Suite 501, Pleasanton, CA 94588, USA
Telephone: +1-925-223-8242
Fax: +1-925-223-8243
E-mail: bpgoffice@wjgnet.com
Help Desk: http://www.f6publishing.com/helpdesk
http://www.wjgnet.com

© 2018 Baishideng Publishing Group Inc. All rights reserved.