DOI: 10.1111/exd.12463
www.wileyonlinelibrary.com/journal/EXD

Original Article

Topical application of rapamycin ointment ameliorates *Dermatophagoides farina* body extract-induced atopic dermatitis in NC/Nga mice

Fei Yang[1]*, Mari Tanaka[1]*, Mari Wataya-Kaneda[1], Lingli Yang[1], Ayumi Nakamura[2], Shoji Matsumoto[2], Mostafa Attia[3], Hiroyuki Murota[1] and Ichiro Katayama[1]

[1]Department of Dermatology, Course of Integrated Medicine, Graduate School of Medicine, Osaka University, Osaka, Japan; [2]Laboratory of Pharmaceutical Sciences, Graduate School of Medicine, Osaka University, Osaka, Japan; [3]Department of Dermatology, Cairo University, Cairo, Egypt
Correspondence: Mari Wataya-Kaneda, Department of Dermatology, Course of Integrated Medicine, Graduate School of Medicine, Osaka University, 2-2 Yamadaoka, Suita, Osaka 565-0871, Japan, Tel.: +81-668-79-3031, Fax: +81-668-79-3039, e-mail: mkaneda@derma.med.osaka-u.ac.jp
**These authors contributed equally to this work.*

Abstract: Atopic dermatitis (AD), a chronic inflammatory skin disease characterized by relapsing eczema and intense prurigo, requires effective and safe pharmacological therapy. Recently, rapamycin, an mTOR (mammalian target of rapamycin) inhibitor, has been reported to play a critical role in immune responses and has emerged as an effective immunosuppressive drug. In this study, we assessed whether inhibition of mTOR signalling could suppress dermatitis in mice. Rapamycin was topically applied to inflamed skin in a murine AD model that was developed by repeated topical application of *Dermatophagoides farina* body (Dfb) extract antigen twice weekly for 7 weeks in NC/Nga mice. The efficacy of topical rapamycin treatment was evaluated immunologically and serologically. Topical application of rapamycin reduced inflammatory cell infiltration in the dermis, alleviated the increase of serum IgE levels and resulted in a significant reduction in clinical skin condition score and marked improvement of histological findings. In addition, increased mTOR phosphorylation in the lesional skin was observed in our murine AD model. Topical application of rapamycin ointment inhibited Dfb antigen-induced dermatitis in NC/Nga mice, promising a new therapy for atopic dermatitis.

Key words: atopic dermatitis – mTOR – rapamycin

Accepted for publication 3 June 2014

Introduction

Atopic dermatitis (AD) is a chronic and relapsing skin disease, histopathologically characterized by the selective accumulation of inflammatory cells (1). The skin inflammation is thought to result partly from a complicated interaction between activated Th2 lymphocytes, eosinophils and mast cells (2). Although immunological or hereditary abnormalities in AD have become clear in recent years, topical glucocorticoid application is still the most effective therapy and is the standard treatment in many guidelines (3,4). Prolonged use of topical glucocorticoids could result in long-term risks such as telangiectatic lesions, cutaneous atrophy and steroid acne, and a relapse often occurs within several days after discontinuation of their prolonged use. Therefore, there is a need for more effective alternative therapies without negative side effects.

Rapamycin was discovered in 1965 from fungi in the remote Easter Island, and it shows potential beyond its obvious antiproliferative and immunosuppressant activities (5,6). It is well known as a second-generation immunosuppressive agent (7). Rapamycin has potential to be used in various conditions including tuberous sclerosis (8), Kaposi's sarcoma (9), psoriasis (10), and keloids and scars (11). In addition, rapamycin has also been reported to decrease keratinocyte proliferation and may help patients with psoriasis (12). Rapamycin, although similar in structure to cyclosporine and tacrolimus, is not a calcineurin inhibitor (5). Rapamycin binds to the immunophilin FK506-binding protein-12 to create an immunosuppressive complex that attaches to inhibit the activation of the mammalian target of rapamycin (mTOR), an important regulatory kinase. The inhibition of mTOR prevents cell cycle progression from G1 to S phase, leading to suppression of T lymphocyte activation and proliferation and of antibody production. It had also been previously reported that a targeted approach selectively inhibiting mTORC2 can effectively reduce proliferation of mast cells associated with inflammation (13). The kinase mTOR regulates differentiation of helper T cells through selective activation of signalling by mTORC1 and mTORC2 (14). However, the precise mechanisms underlying anti-inflammatory actions of rapamycin are still largely unknown, and effects of rapamycin on cutaneous immune responses have yet to be addressed.

In this study, we evaluated the effect of topical rapamycin in a murine model of AD, developed by repeated application of *Dermatophagoides farina* body (Dfb) extract ointment on skin of NC/Nga mice. Our data show that topical rapamycin regulates epidermal thickening and inflammatory cell infiltration into the dermis in this murine model. Interestingly, a pattern of increased mTOR phosphorylation was observed in lesional skin of the Dfb-induced NC/Nga mice.

Materials and methods

Animals

Female 6-week-old NC/Nga mice were purchased from SLC (Shizuoka, Japan) and were maintained under specific pathogen-free conditions. Every experimental group contained seven mice, and more than three repetitions were performed for each experiment.

© 2014 John Wiley & Sons A/S. Published by John Wiley & Sons Ltd

Experiments were conducted in accordance with the Guiding Principles for the Care and Use of Laboratory Animals, and the experimental protocol used in this study was approved by the Committee for Animal Experiments at Osaka University (Osaka, Japan).

Drugs and materials

Bulk powder GMP-grade rapamycin purchased from Fujian Kerin Pharmaceutical Co. Ltd. (Fuzhou, China) was mixed with petrolatum mixture to constitute the rapamycin ointment. The rapamycin ointment was then divided into aliquots and stored at −80°C until application. In addition, we performed the preliminary experiments using 0.03% rapamycin, 0.1% rapamycin, 0.2% rapamycin and 0.03% tacrolimus to evaluate whether rapamycin was effective and to identify the optimal concentration to improve atopic dermatitis in mice. As data shown in Figure S1, 0.2% rapamycin ointment was shown best effective, and we finally selected rapamycin ointment with this concentration in the present study.

Experimental protocols

Experimental protocols are illustrated in Figure S2. NC/Nga mice were treated topically with Dfb extract twice weekly for 7 weeks to induce AD-like lesions. They were concomitantly given topical vehicle ointment or rapamycin ointment during the last 4 weeks. Samples of back skin and blood were collected 24 h after the final treatment.

Clinical skin score

Dorsal lesions were evaluated for four symptoms: erythema/haemorrhage, oedema, excoriation/erosion and scaling/dryness. Each symptom was graded from 0 to 3 (none, 0; mild, 1; moderate, 2; and severe, 3). Clinical skin score was defined as the sum of the individual scores, ranging from 0 to 12, in a blinded manner by three observers, as previously reported (15–17).

Histological analysis

The skin samples were embedded in paraffin by a conventional method and stained with either haematoxylin and eosin or toluidine blue. The thickness of the epidermis and number of toluidine blue-stained cells were expressed as mean values from five fields per mouse.

Immunohistochemistry

Formalin-fixed, paraffin-embedded skin sections were stained with polyclonal rabbit antibody against CD3 (Abcam, Cambridge, MA, USA, #5690, at 1:100, 4°C, overnight) as described previously (18). T cells were counted in five fields per mouse in the lesional skin.

ELISA analysis

Serum IgE levels were determined using a commercial sandwich Mouse ELISA Kit (Yamasa Soy Sauce, Chiba, Japan). The IL-4 and IL-13 protein levels in lesional skin were determined using commercial ELISA kits (R&D Systems, Minneapolis, MN, USA) according to the manufacturer's instructions.

Western blot analysis

Proteins were extracted from skin samples, and 10 μg of extracted protein was used for Western blot analysis as described previously (18). The primary antibodies and dilutions used were anti-phospho-mTOR (Cell Signaling Technology, Beverly, MA, USA), 1:1000; anti-total-mTOR (Cell Signaling Technology), 1:1000; and anti-GAPDH (Santa Cruz Biotechnology, Santa Cruz, CA, USA), 1:500. The GAPDH signal detected with antibody was used as a loading control.

Statistical analysis

Data were presented as means ± SD. Student's *t*-test was used for the analysis of differences between two groups. Values of $P < 0.05$ were considered statistically significant.

Results

Rapamycin macroscopically improved AD

To investigate the effect of rapamycin on AD, NC/Nga mice that were treated topically with Dfb twice weekly for 7 weeks to induce AD-like lesions were concomitantly given topical vehicle ointment or rapamycin ointment during the last 4 weeks. Samples of skin and blood were collected 24 h after the final treatment, as shown in Figure S2. Lesions were evaluated by clinical skin scores as described previously (15,16). Macroscopically, the topical application of rapamycin markedly improved the lesions in a time-dependent fashion, leading to a significant reduction in the clinical skin score. Rapamycin tended to decrease the clinical skin score at day 17, and the score was lowest at day 42 (Fig. 1a,b). The improvement of skin lesions was only observed in those lesions to which rapamycin was applied and not elsewhere.

Besides, although the accurate number of scratching was not counted, the increase of scratching was observed in Dfb-induced atopic dermatitis mice, and a markedly reduction in scratching was found in mice receiving rapamycin ointment, compared with mice in non-treatment or vehicle group (data not shown). Furthermore, as a sign of scratching, the excoriation in the face, ears and anterior part of their back, which was scratched by their hind paws, was found alleviated in rapamycin-treated mice (Figure S3). By histoimmunochemical staining, rapamycin ointment treatment inhibited the increase of nerve growth factor (NGF) expression in lesional skin, which is known to reflect the severity of itch and eruption (Figure S4). These results indicated that treatment with rapamycin improved itch and scratching in Dfb-induced atopic dermatitis mice.

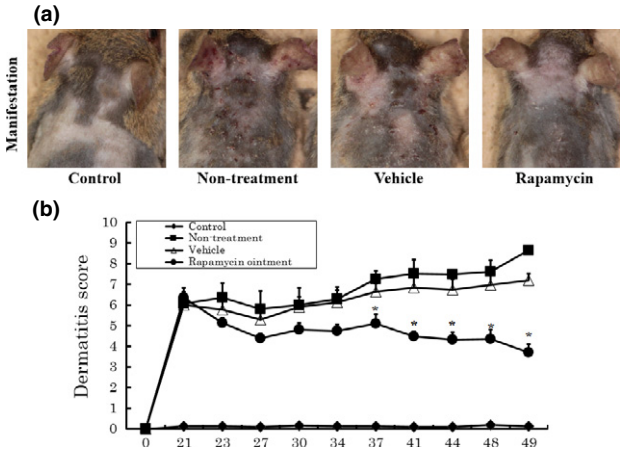

Figure 1. Rapamycin improves atopic dermatitis (AD)-like skin lesions of NC/Nga mice. (a) Rapamycin treatment markedly suppressed erythema, scaling, erosion and crust formation in the skin. Mice were treated either by no application, or application of ointment base (vehicle) or rapamycin ointment every day from day 22 to day 49. (b) The improvement of lesional skin was evaluated by clinical dermatitis score. A decrease in the clinical skin score was observed only in the rapamycin-treated group. Values are mean ± SD ($n = 7$). *$P < 0.05$ by *t*-test, compared with the non-treatment group.

© 2014 John Wiley & Sons A/S. Published by John Wiley & Sons Ltd

Rapamycin histologically improved AD

Acanthosis and the infiltration of inflammatory cells, including lymphocytes, mast cells and eosinophils, are histopathological changes that occur in skin lesions of AD patients and Dfb-treated NC/Nga mice (19,20). After completion of a 47-day observation period, lesions of each group were subjected to biopsy, fixation and staining with hematoxylin and eosin. Decreases in the epidermal thickness and in the number of infiltrating cells in the dermis were observed only in the rapamycin-treated skin areas (Fig. 2a, b). Using toluidine blue staining, we also observed a significant decrease in the number of infiltrating mast cells only in the dermis of rapamycin-treated skin areas (Fig. 2c,d). These results indicate that histological as well as macroscopic improvement of AD was achieved by the topical application of rapamycin.

Rapamycin suppresses T-cell infiltration and IgE production

To investigate the effect of rapamycin on skin T cells, immunostaining was used. A decrease in the number of infiltrating T cells was observed in rapamycin-treated skin area (Fig. 3a,b). To prove the therapeutic efficacy of rapamycin, we measured serum IgE concentration in NC/Nga mice treated with rapamycin versus control mice. In control mice, which showed no AD symptoms, IgE was present at a low basal level. However, in mice with AD symptoms, at least an eightfold increase in serum IgE level was detected (Fig. 3c). Moreover, application of rapamycin on AD skin lesions resulted in a significant reduction of serum IgE (Fig. 3c).

Rapamycin suppresses increased IL-4 and IL-13 levels and phosphorylation of mTOR in lesional skin

Protein extracted from mouse dorsal skin lesion was subjected to both ELISA and Western blot analyses. The expression of Th2 cytokines IL-4 and IL-13 was significantly increased in skin lesions of AD-induced NC/Nga mice. Compared to untreated mice or those treated with vehicle only, the increase of IL-4 and IL-13 in skin lesions was suppressed in the mice treated topically with rapamycin ointment (Fig. 4a,b). Furthermore, by histoimmunochemical staining, thymic stromal lymphopoietin (TSLP) expression in lesional skin was markedly decreased with rapamycin treatment, compared with vehicle ointment treatment (Figure S5).

In NC/Nga mice, higher phosphorylation of mTOR was observed in lesional skin than in non-lesional skin. The increased phosphorylation of mTOR in lesional skin declined to the same level as that in non-lesional skin after repeated application of rapamycin (Fig. 4c).

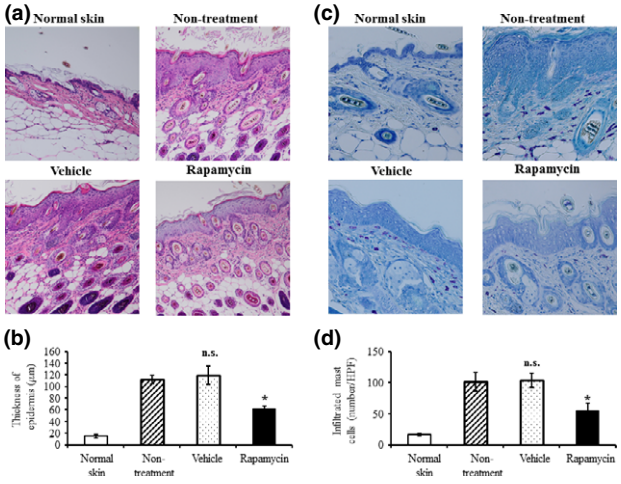

Figure 2. Rapamycin suppresses acanthosis and lymphocyte and mast cell infiltration in atopic dermatitis (AD)-like skin lesions. (a, b) Hematoxylin–eosin staining showed an improvement of acanthosis and a decrease in the number of invasive lymphocytes in the dermis only in the rapamycin-treated group. (c, d) Toluidine blue staining showed a significant decrease in the dermal mast cell count only in the rapamycin-treated group. The number of infiltrating mast cells in the dermis was counted. Values are mean ± SD (n = 7). *P < 0.05 by t-test, compared with the non-treatment group. Original magnification, ×200.

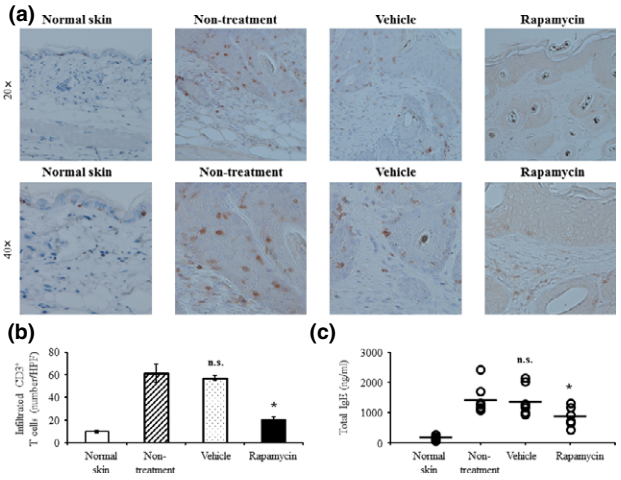

Figure 3. Rapamycin suppresses CD3$^+$ T-cell infiltration and serum IgE levels. (a, b) To investigate the effects of rapamycin on skin inflammatory infiltrate, we immunostained CD3$^+$ T cells. A decrease in the number of infiltrating CD3$^+$ T cells was observed in rapamycin-treated skin areas. (c) A decrease in total IgE levels in murine sera, quantified by ELISA assay, was observed (n = 7/group). The black bar represents mean value. *P < 0.05 by t-test, compared with the non-treatment group.

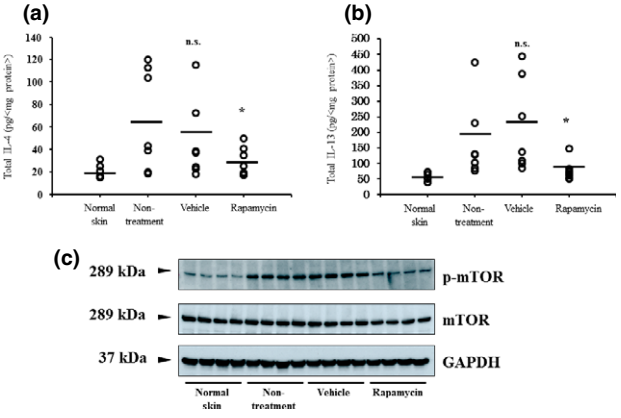

Figure 4. Rapamycin suppresses increased IL-4 and IL-13 levels and phosphorylation of mTOR in lesional skin. (a, b) ELISA analysis of IL-4 and IL-13 levels in protein extracted from lesional skin of NC/Nga mice (n = 7/group). The black bar represents mean value. *P < 0.05 by t-test, compared with the non-treatment group. (c), Western blot analysis of p-mTOR and mTOR levels in mouse skin extracts.

Discussion

Previous studies of rapamycin effects in regulating mast cell function and homoeostasis have implicated a central involvement of mTOR signalling (21–23). In particular, attention has been given to the fact that rapamycin plays several critical roles in the immune system. Furthermore, rapamycin has been demonstrated

© 2014 John Wiley & Sons A/S. Published by John Wiley & Sons Ltd

to induce a reduction in keratinocyte proliferation and neutrophil infiltration in a dose-dependent manner (24). It has also been demonstrated that dendritic cell migration into the draining lymph node can be influenced by rapamycin (25). Mammalian target of rapamycin complex 1 (mTORC1) was also reported to modulate the timing of antigen entry in mouse hair follicles (26). Recently, several reports have suggested the therapeutic efficacy of rapamycin for various immunological disorders. Although rapamycin (C51H79NO13) is known as a large molecule with a molecular weight of 914.2 Da, in our previous report (27), good skin penetration of rapamycin ointment was observed using three-dimensional cultured human skin model. Furthermore, in preliminary experiments of the present study, percutaneous penetration of topical rapamycin in various ointment concentrations (0.03–0.2%) was evaluated using liquid chromatography–electrospray ionization/mass spectrometry (LC-ESI/MS). A dose-dependent absorption was observed (Figure S6).

Here, it was demonstrated for the first time that topical application of rapamycin remarkably improved AD symptoms in skin lesions of NC/Nga mice. Histopathological examinations of the rapamycin-treated skin area revealed a significant reduction in the epidermal thickness and a decrease of inflammatory infiltrate, including mast cells and T cells in the dermis, as well as decreased IL-4, and IL-13 expression levels in the lesional skin. In addition, the levels of serum IgE were reduced, which is an indicator of improved AD symptoms. In NC/Nga mice, higher phosphorylation of mTOR was observed in lesional than in non-lesional skin tissue. The increased phosphorylation of mTOR in lesional skin declined to the same level as that in non-lesional skin after repeated application of rapamycin.

The present study confirmed that topical rapamycin mitigated the cutaneous inflammation in a mouse model of chronic inflammatory dermatitis induced by repeated challenge of Dfb to the skin of ear and back. Thus, topical rapamycin may offer a novel regimen for treating chronic inflammatory dermatitis such as AD by inhibiting inflammatory cytokines. It has been reported that the level of IL-4, a cytokine promoting IgE production, is enhanced in skin biopsy specimens of patients with AD (28–31). In the present study, topical rapamycin was shown to inhibit the augmented increase of IL-4 and IgE levels in lesional skin. Mast cells are well known to take part in the development of adaptive immune responses (32), and they also serve as an abundant source of Th2 cytokines (33). Atopic dermatitis is characterized by perivascular T-cell infiltrate in the papillary dermis consisting predominantly of activated memory-effector T cells that induce keratinocyte apoptosis (34). Rapamycin inhibits T cell-induced apoptosis of cultured keratinocytes (34). In the present study, mast cells and infiltrating T cells were found to be inhibited by topical application of rapamycin.

Recent studies have demonstrated that rapamycin functions in various reactions of the immune system. In AD, the effects of rapamycin may involve mechanisms other than mTOR in the regulation of the immune and vascular systems, in addition to the suppression of the phosphorylation of mTOR in the epidermis. Consistently, our present study clearly demonstrated that topical rapamycin suppressed T-cell infiltration and IgE production in the dermis of NC/Nga mice, in which dermatitis is closely associated with excessive IgE production as well as inflammatory cell infiltration in the dermis. As it is suggested, there is a bit difference among different AD mice models (35), whether rapamycin ointment is efficient in other AD mice models or humans should be investigated in the future study. Besides, the antipruritic mechanism of tacrolimus was explained by a direct effect on sensory neuronal TRPV1 receptor desensitization (36); however, because TSLP was known to activate neurons to induce itch (37), and the TSLP production was found inhibited by rapamycin ointment in the present study (Figure S5), one of the antipruritic effect of rapamycin ointment in Dfb-induced AD mice was supposed to due to the inhibition of TSLP production. The precise antipruritic mechanism of rapamycin ointment also needs to be further investigated in the future.

Currently, the range of pharmaceutical drugs that can be used to treat AD is limited. Despite the rapid and proven efficacy of topical corticosteroids, the side effects limit their clinical usefulness. Topically, active macrolide immunosuppressants, such as ascomycin and tacrolimus, appear to provide comparable therapeutic potency (38,39). Although data from ongoing studies will be crucial in determining the safety of these agents in the long term, and also their place within the current therapeutic armamentarium available for treating patients with AD, these agents still have potential side effects, such as systemic absorption. There is a report of two severe AD patients, and oral everolimus (rapamycin-derived macrolide) was found ineffective, either in combination with prednisone or with CsA (40). The use of oral everolimus did not control the dermatitis in these two patients despite combinational use with prednisone in one patient and cyclosporine in the other. The authors conclude that everolimus is ineffective at treating atopic dermatitis. However, this conclusion is very controversial (41), and more studies are needed to confirm this result. In the present study, topical rapamycin was demonstrated to be an agent having inhibitory activity against chronic inflammation, possibly resulting from its diminishing effect on the increased cytokines and histamine in lesional skin and serum IgE level. Topical rapamycin may be effective for the treatment of patients with refractory AD, who are resistant to existing drugs.

Overall, rapamycin via topical application should be considered as an alternative treatment to inhibit the progression, and to cause regression, of AD. Further studies are necessary, especially to answer questions about the potential long-term side effects, such as cutaneous infection or carcinogenesis due to local immunosuppression. More controlled clinical trials need to be conducted to further assess the benefits of rapamycin and its analogues.

Acknowledgements

We thank our technical assistant Lanting Teng for her laboratory assistance. This study was supported by a grant from the Ministry of Education, Culture, Sports, Science and Technology of Japan (No. 25461690), and by a grant from the Ministry of Health, Labor and Welfare of Japan (No. H24-Nanchi-ippan-008).

Author contribution

MW-K, HM and IK designed the research; FY, MT, MW-K, LY, AN, AM and MA performed experiments and analysed the data; and FY wrote the paper.

Conflict of interests

The authors have declared no conflicting interests.

© 2014 John Wiley & Sons A/S. Published by John Wiley & Sons Ltd

References

1 Leung D Y, Bieber T. Lancet 2003: **361**: 151–160.
2 Furue M. J Dermatol Sci 1994: **7**: 159–168.
3 Hanifin J M, Cooper K D, Ho V C *et al.* J Am Acad Dermatol 2004: **50**: 391–404.
4 Katayama I, Kohno Y, Akiyama K *et al.* Allergol Int 2011: **60**: 205–220.
5 Jozwiak J, Jozwiak S, Oldak M. Med Res Rev 2006: **26**: 160–180.
6 Koehl G E, Andrassy J, Guba M *et al.* Transplantation 2004: **77**: 1319–1326.
7 Yilmaz R, Akoglu H, Kirkpantur A *et al.* Ren Fail 2007: **29**: 103–105.
8 Bissler J J, McCormack F X, Young L R *et al.* N Engl J Med 2008: **358**: 140–151.
9 Campistol J M, Gutierrez-Dalmau A, Torregrosa J V. Transplantation 2004: **77**: 760–762.
10 Reitamo S, Spuls P, Sassolas B *et al.* Br J Dermatol 2001: **145**: 438–445.
11 Syed F, Sanganee H J, Bahl A *et al.* J Invest Dermatol 2013: **133**: 1340–1350.
12 Ormerod A D, Shah S A, Copeland P *et al.* Br J Dermatol 2005: **152**: 758–764.
13 Smrz D, Kim M S, Zhang S *et al.* Blood 2011: **118**: 6803–6813.
14 Delgoffe G M, Pollizzi K N, Waickman A T *et al.* Nat Immunol 2011: **12**: 295–303.
15 Suto H, Matsuda H, Mitsuishi K *et al.* Int Arch Allergy Immunol 1999: **120**(Suppl 1): 70–75.
16 Takakura M, Takeshita F, Aihara M *et al.* J Invest Dermatol 2005: **125**: 1156–1162.
17 Negi O, Tominaga M, Tengara S *et al.* J Dermatol Sci 2012: **66**: 37–43.
18 Yang L, Serada S, Fujimoto M *et al.* PLoS One 2012: **7**: e41994.
19 Matsuda H, Watanabe N, Geba G P *et al.* Int Immunol 1997: **9**: 461–466.
20 Friedmann P S. Dermatology 1994: **189**(Suppl 2): 42–44.
21 Kuehn H S, Jung M Y, Beaven M A *et al.* J Biol Chem 2011: **286**: 391–402.
22 Kim M S, Kuehn H S, Metcalfe D D *et al.* J Immunol 2008: **180**: 4586–4595.
23 Kitaura J, Asai K, Maeda-Yamamoto M *et al.* J Exp Med 2000: **192**: 729–740.
24 Reitamo S, Rissanen J, Remitz A *et al.* J Invest Dermatol 1998: **111**: 396–398.
25 Baumer W, Sulzle B, Weigt H *et al.* Br J Dermatol 2005: **153**: 136–144.
26 Kellenberger A J, Tauchi M. Exp Dermatol 2013: **22**: 77–80.
27 Tanaka M, Wataya-Kaneda M, Nakamura A *et al.* Br J Dermatol 2013: **169**: 1314–1318.
28 Leung D Y. J Allergy Clin Immunol 1999: **104**: S99–S108.
29 Kimata H. Ann Allergy Asthma Immunol 1999: **82**: 293–295.
30 Iwata Y, Shinomura T, Kurita K *et al.* Biochem J 1998: **331**(Pt 3): 959–964.
31 Elbe-Burger A, Egyed A, Olt S *et al.* J Invest Dermatol 2002: **118**: 767–778.
32 Galli S J, Nakae S, Tsai M. Nat Immunol 2005: **6**: 135–142.
33 Horsmanheimo L, Harvima I T, Jarvikallio A *et al.* Br J Dermatol 1994: **131**: 348–353.
34 Trautmann A, Akdis M, Schmid-Grendelmeier P *et al.* J Allergy Clin Immunol 2001: **108**: 839–846.
35 Hashimoto Y, Takaoka A, Sugimoto M *et al.* Exp Dermatol 2011: **20**: 820–825.
36 Pereira U, Boulais N, Lebonvallet N *et al.* Br J Dermatol 2010: **163**: 70–77.
37 Wilson S R, The L, Batia L M *et al.* Cell 2013: **155**: 285–295.
38 Nakagawa H, Etoh T, Ishibashi Y *et al.* Lancet 1994: **344**: 883.
39 Ong C S. N Engl J Med 1998: **339**: 1788–1789.
40 Van Velsen S G, Haeck I M, Bruijnzeel-Koomen C A. J Dermatolog Treat 2009: **20**: 365–367.
41 Feldman S R. J Dermatolog Treat 2009: **6**: 317–318.

Supporting Information

Additional Supporting Information may be found in the online version of this article:

Figure S1. Rapamycin improves AD-like skin lesions of NC/Nga mice in a dose-dependent manner.

Figure S2. Schematic diagram of experimental protocols used in the study.

Figure S3. Rapamycin improves skin excoritation in Dfb-induced AD mice.

Figure S4. Rapamycin inhibits the increase of nerve growth factor expression in AD-like skin lesions of NC/Nga mice.

Figure S5. Rapamycin inhibits the increase of thymic stromal lymphopoietin expression in AD-like skin lesions of NC/Nga mice.

Figure S6. Rapamycin penetrates into mice skin in a dose-dependent manner.

Data S1. Materials & Methods.

© 2014 John Wiley & Sons A/S. Published by John Wiley & Sons Ltd

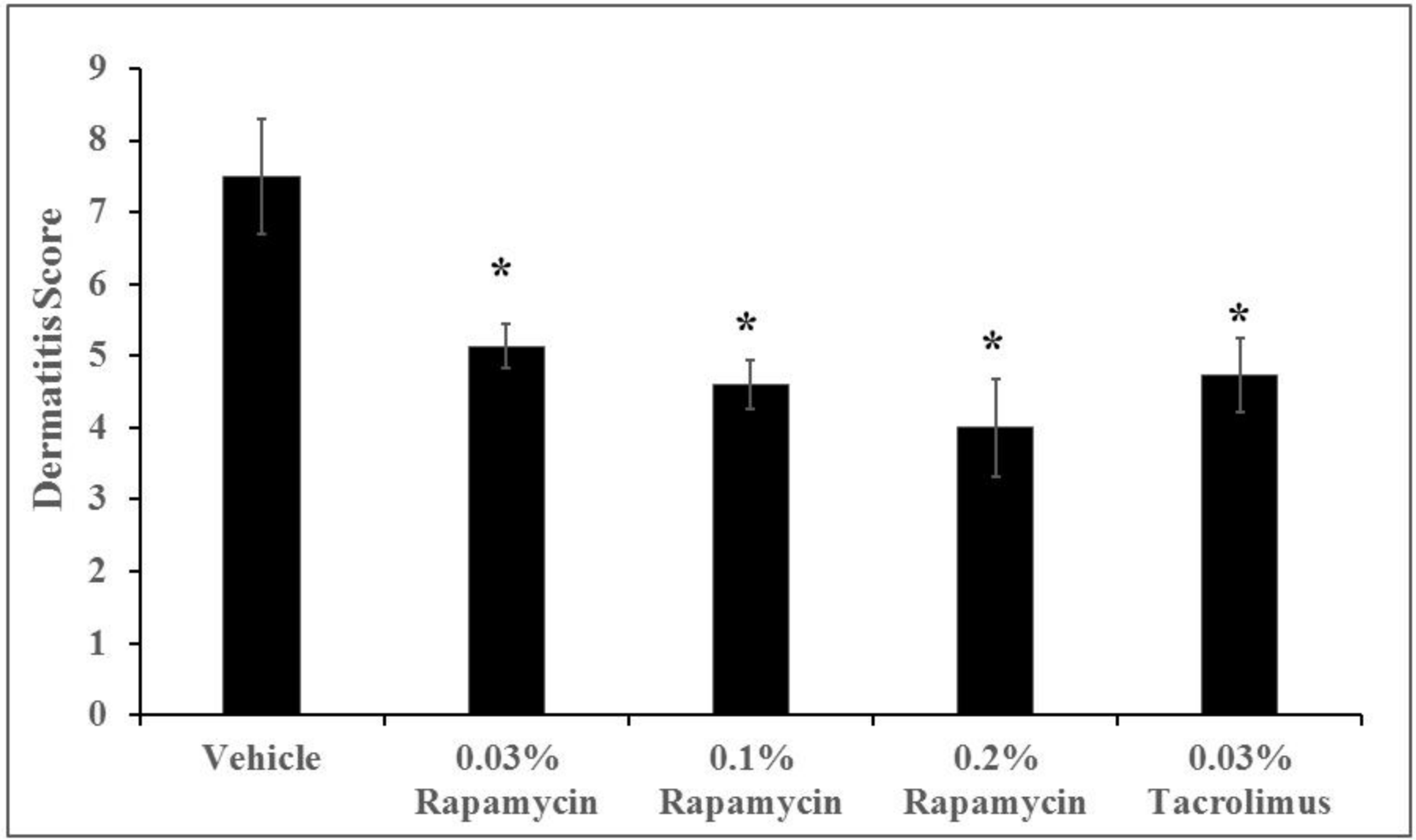
Dermatitis Score
9
8
7
6
5
4
3
2
1
0
*
*
*
*
Vehicle
0.03% Rapamycin
0.1% Rapamycin
0.2% Rapamycin
0.03% Tacrolimus


Hair shaving on the dorsal region
4% SDS/Dfb ointment
0
7
14
21
28
35
42
49 (day)
Treatment with Rapamycin ointment
0
7
14
21
28
35
42
49 (day)
Treatment with ointment base (vehicle)
0
7
14
21
28
35
42
49 (day)
Non-treatment
0
7
14
21
28
35
42
49 (day)

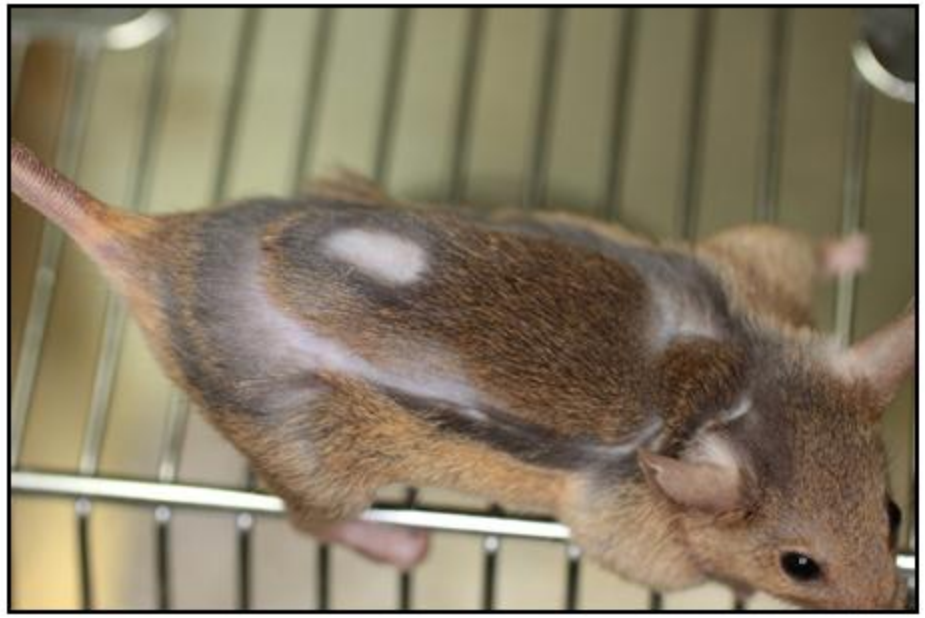

Control

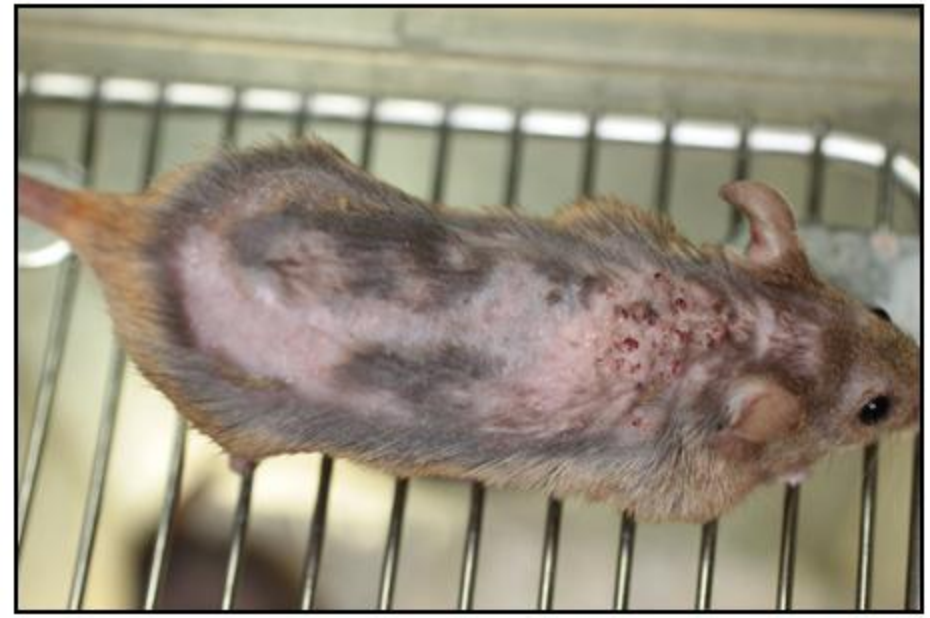

Non-treatment

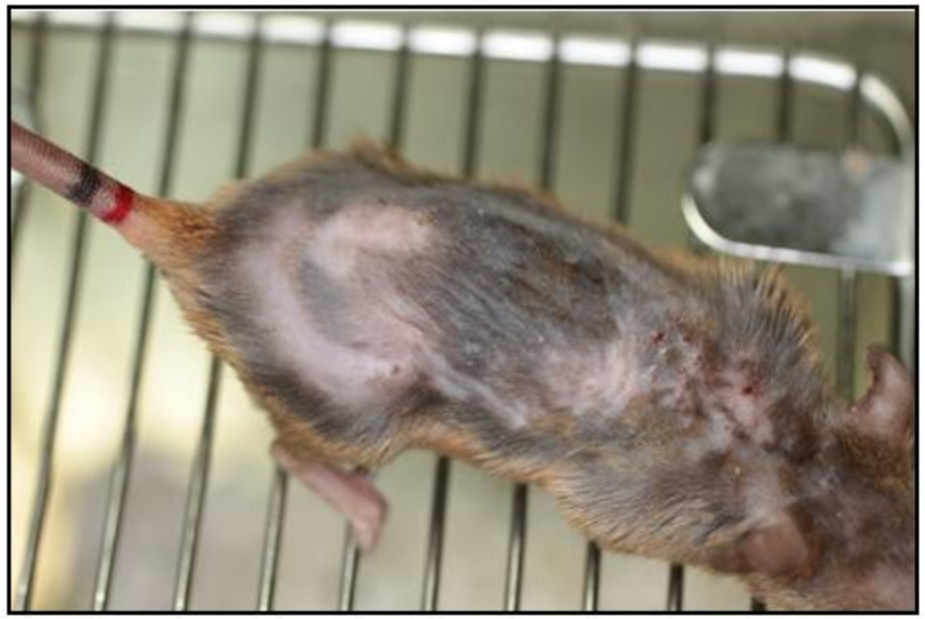

Vehicle

Rapamycin

NGF

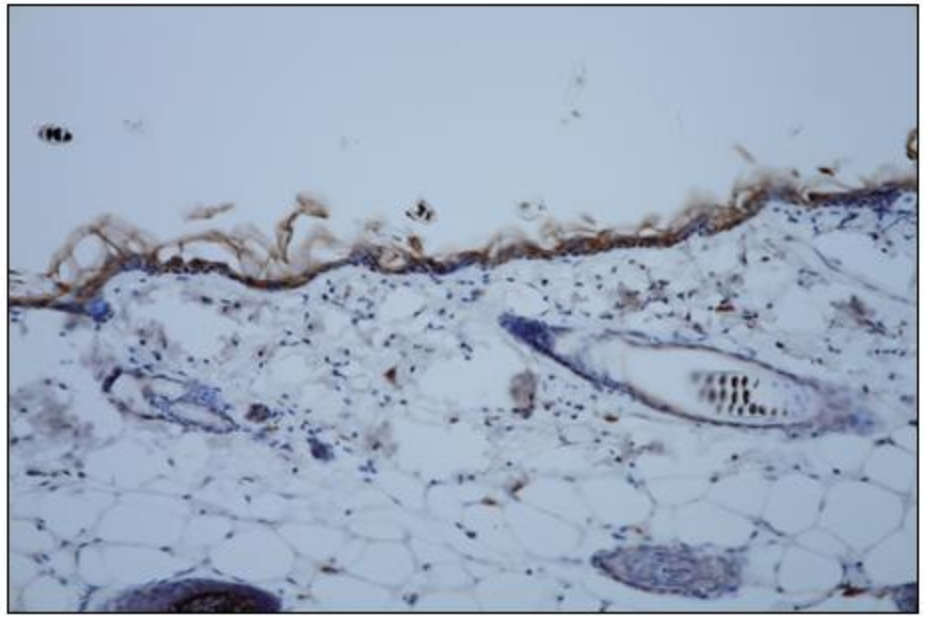

Control

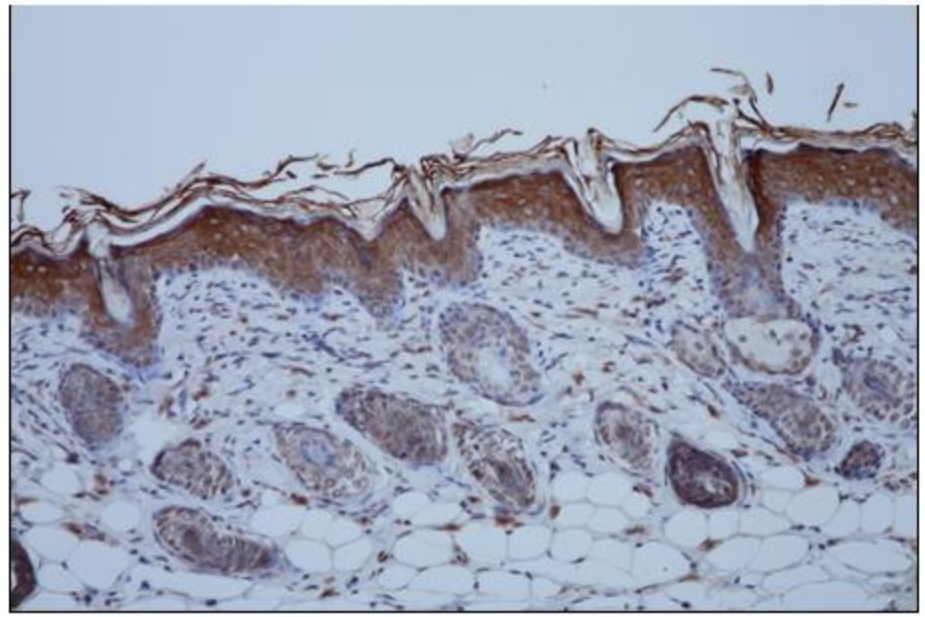

Non-treatment

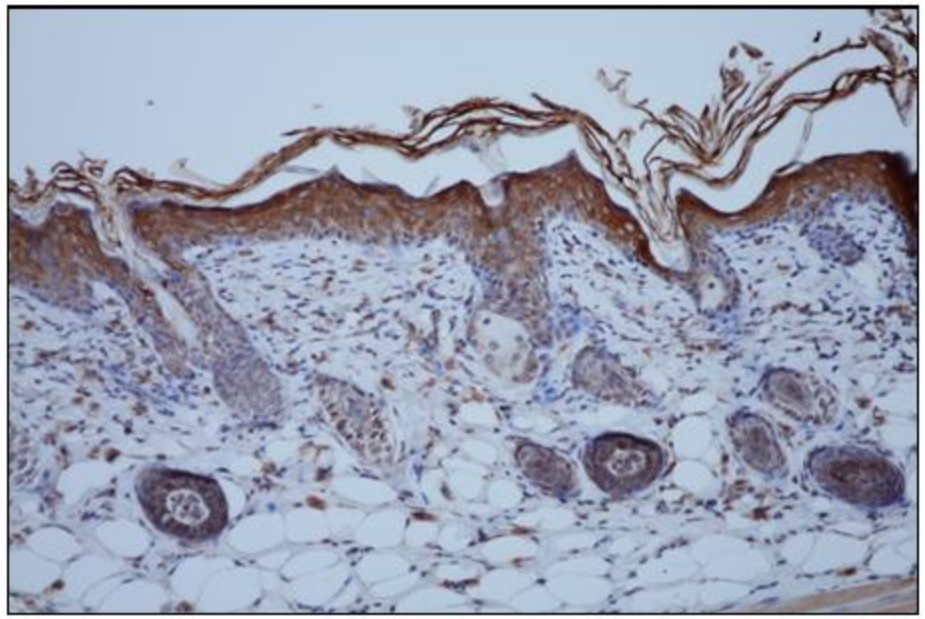

Vehicle

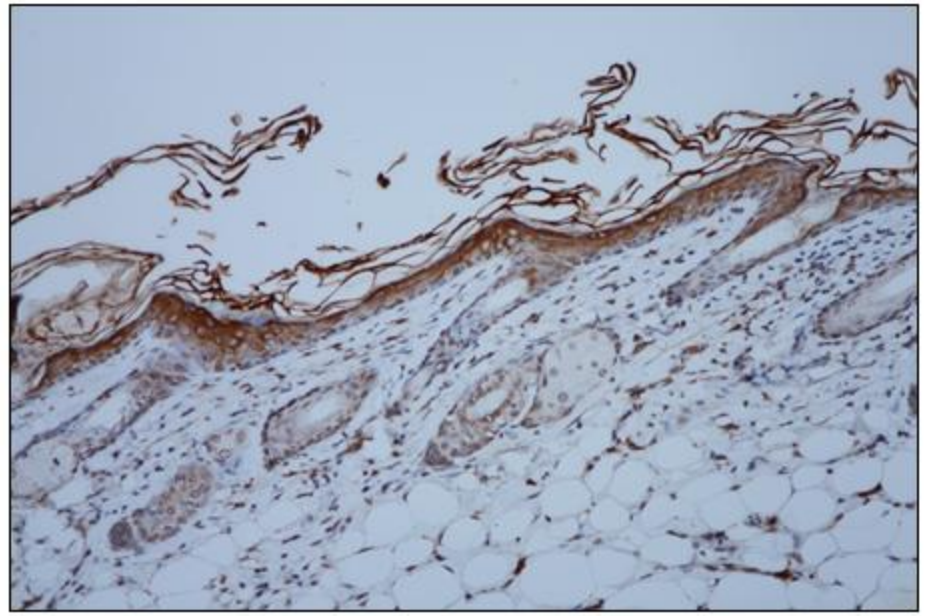

Rapamycin

TSLP

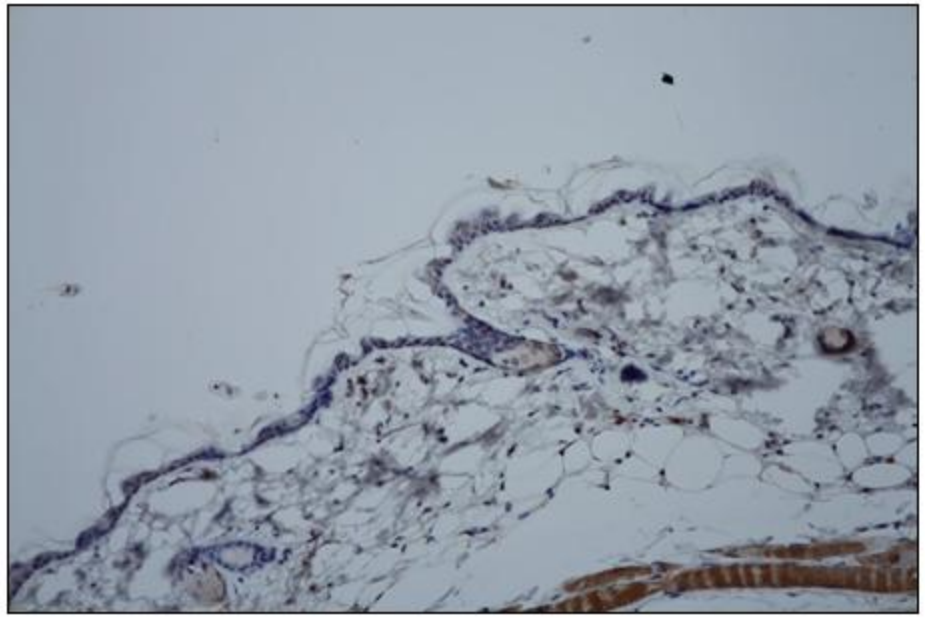

Control

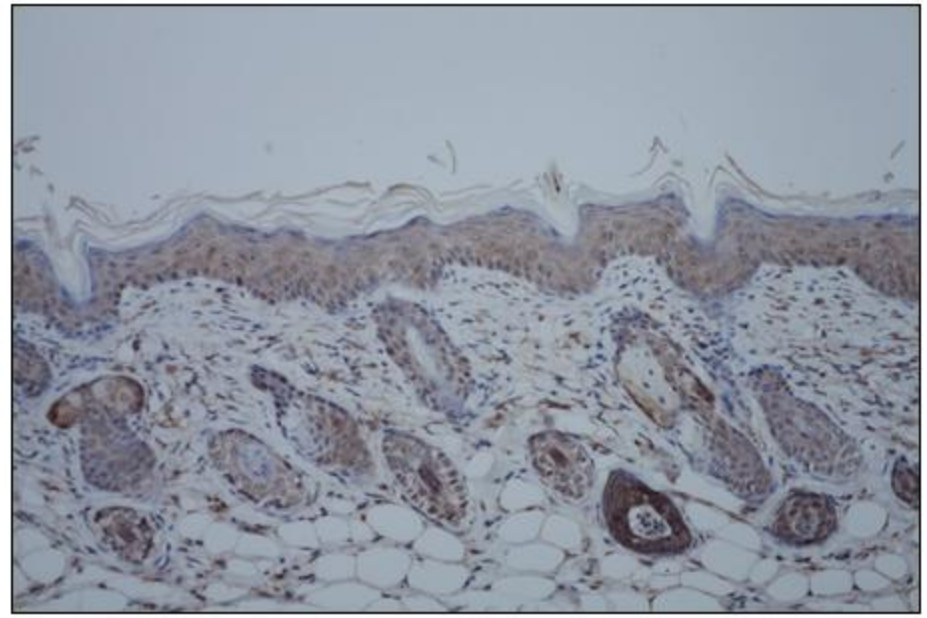

Non-treatment

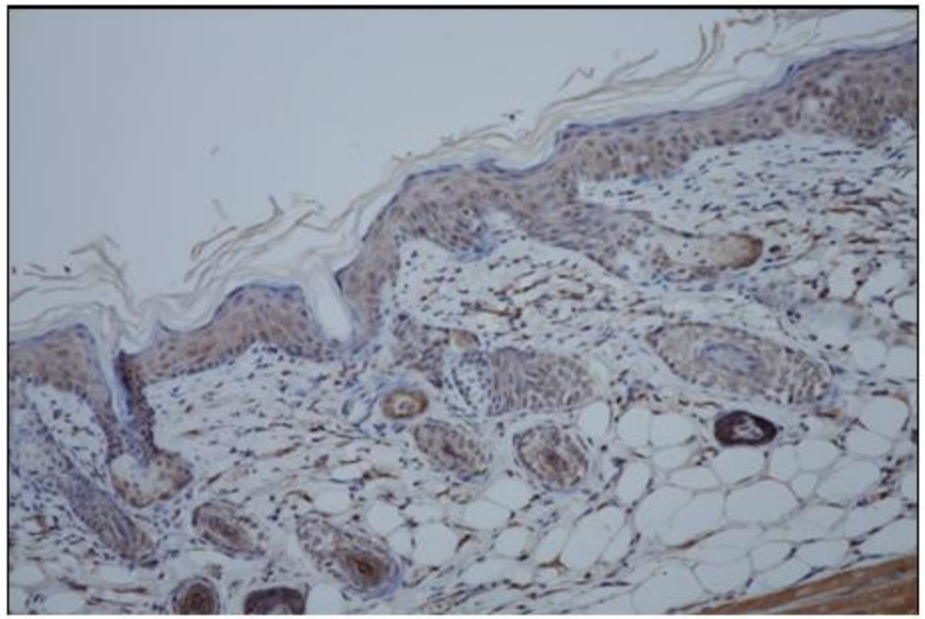

Vehicle

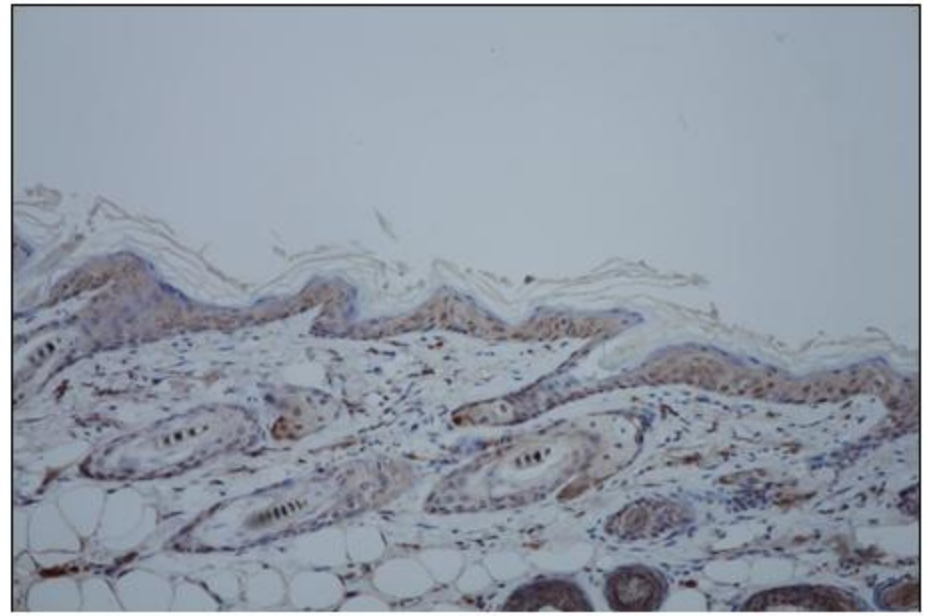

Rapamycin

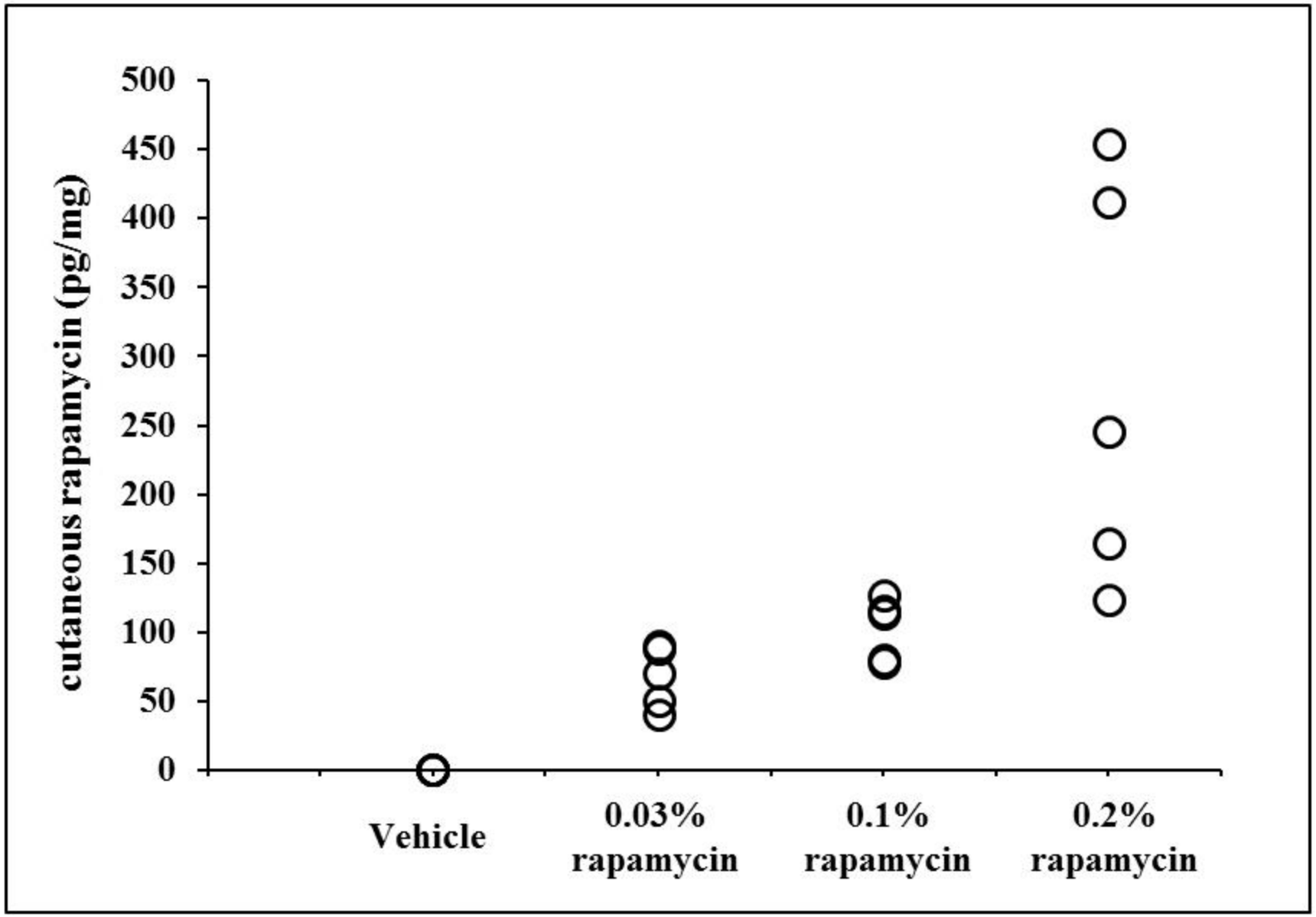
cutaneous rapamycin (pg/mg)
500
450
400
350
300
250
200
150
100
50
0
Vehicle
0.03% rapamycin
0.1% rapamycin
0.2% rapamycin

Supplementary Information

Materials & Methods

The determination of topical rapamycin percutaneous penetration in NC/Nga mice skin

NC/Nga mice were treated topically with Dfb extract for 6 weeks to induce AD-like lesions. Topical vehicle ointment, rapamycin ointment (Fujian Kerin Pharmaceutical Co. Ltd, Fuzhou, China), or tarcrolimus ointment (Fujisawa Pharmaceutical, Osaka, Japan) with the indicated concentrations were concomitantly given during the last 3 weeks. Samples of back skin were collected 24 hours after the final treatment. Percutaneous penetration of topical rapamycin in various ointment concentrations (0.03%-0.2%) was evaluated using liquid chromatography-electrospray ionization/mass spectrometry (LC-ESI/MS).

Immunohistochemistry

Formalin-fixed, paraffin-embedded skin sections were deparaffinized with xylene and graded ethanol. Endogenous peroxidases were blocked with peroxide for 30 min at room temperature. After washing with PBS, sections were incubated in normal goat serum for 15 min at room temperature. Sections were then incubated with polyclonal rabbit antibody against NGF (Abcam; Cambridge, MA, #6199, at 1:300, room

temperature, 1 hour) or polyclonal rabbit antibody against TSLP (Abcam; Cambridge, MA, #115700, at 1:200, room temperature, 1 hour). The sections were washed with PBS and then incubated with avidin-biotinylated peroxidase complex. Peroxidase activity was visualized using stable diaminobenzidine. Staining was monitored by bright-field microscopy, and sections were washed with distilled water to stop the reaction. Sections were then counterstained with hematoxylin, washed, and mounted.

Figure Legend

Figure S1. Rapamycin improves AD-like skin lesions of NC/Nga mice in a dose-dependent manner. NC/Nga mice were treated topically with Dfb extract for 6 weeks to induce AD-like lesions. Topical vehicle ointment, rapamycin ointment, or tarcrolimus ointment with the indicated concentrations were concomitantly given during the last 3 weeks. Samples of back skin were collected 24 hours after the final treatment. The improvement of lesional skin was evaluated by clinical dermatitis score. A decrease in the clinical skin score was observed both in the rapamycin-treated groups (0.03%; 0.1%; 0.2%) and 0.03% tacrolimus-treated group, and the dose-dependent effect was observed in rapamycin treatment. Values are mean ± SD (n

= 5). *P < 0.05 by *t*-test, compared with the vehicle-treatment group.

Figure S2. Schematic diagram of experimental protocols used in the study. Mice were divided into four groups (n = 7 per group). To induce AD-like immunologic and skin lesions, 100 mg Dfb ointment was applied topically on the shaved dorsal skin and both surfaces of each ear, according to the schedule in the upper bar. Barrier disruption was achieved by treatment with 150 μl of 4% (w/v) sodium dodecyl sulfate on each skin area 3 hours before application of Dfb ointment. These procedures were repeated twice a week for 7 weeks. After 3 weeks of Dfb application, rapamycin ointment (0.03%) or ointment base (vehicle ointment) was topically applied to the shaved dorsal skin and both surfaces of each ear every day from day 21 to 49.

Figure S3. Rapamycin improves skin excoritation in Dfb-induced AD mice. Mice were divided into four groups (n = 7 per group). Photos were taken 24 hours after the final treatment. The excoriation in the face, ears and anterior part of their back which was scratched by their hind paws, was found alleviated in rapamycin-treated mice. The representative data was shown here.

Figure S4. Rapamycin inhibits the increase of nerve growth factor expression in AD-like skin lesions of NC/Nga mice. To investigate the effects of rapamycin on

nerve growth factor (NGF) expression, skin sections were immunostained with anti-NGF antibody. Rapamycin inhibited the increase of NGF expression. (n = 7 per group), original magnification, ×20 objective lens.

Figure S5. Rapamycin inhibits the increase of thymic stromal lymphopoietin expression in AD-like skin lesions of NC/Nga mice. To investigate the effects of rapamycin on thymic stromal lymphopoietin (TSLP) expression, skin sections were immunostained with anti-TSLP antibody. Rapamycin inhibited the increase of TSLP expression. (n = 7 per group), original magnification, ×20 objective lens.

Figure S6. Rapamycin penetrates into mice skin in a dose-dependent manner. Percutaneous penetration of topical rapamycin in various ointment concentrations (0.03%-0.2%) was evaluated using liquid chromatography-electrospray ionization/mass spectrometry (LC-ESI/MS). A dose-dependent absorption was observed. (n = 5 per group).