In-office use of a steroid-eluting implant for maintenance of frontal ostial patency after revision sinus surgery

Agnieszka Janisiewicz, M.D.,[1] and Jivianne T. Lee, M.D.[1,2]

ABSTRACT

Achieving long-term, successful outcomes with endoscopic sinus surgery (ESS) can be challenging in patients with recalcitrant chronic rhinosinusitis (CRS). Local complications, including scar formation and ostial stenosis, can lead to recurrent blockage and subsequent relapse. The frontal sinus is particularly vulnerable to surgical failure given its narrow outflow and inaccessibility to topical therapies. The advent of steroid-eluting sinus implants has enhanced ESS outcomes, with significant reductions in synechiae, inflammation, and secondary postoperative interventions when placed in the ethmoid cavity. However, use of this technology in the frontal sinus has yet to be described. The purpose of this report is to present two cases, in which in-office frontal placement of a mometasone furoate (MF)-eluting implant facilitated maintenance of ostial patency after revision ESS. The clinical presentation, in-office intervention, and treatment outcomes were examined. Two patients (male, 63 and 68 years of age) with a history of multiple ESS presented with recurrent unilateral frontal headache refractory to medical therapy. Nasal endoscopy/imaging revealed frontal sinus outflow obstruction. Both declined revision ESS under general anesthesia and underwent endoscopic frontal sinustomy/ostial dilation in the clinic. A MF-eluting implant was placed in the frontal sinus at the end of the procedure, with preservation of ostial patency upon last follow-up at 3 and 11 months, respectively. In-office placement of a MF-eluting implant successfully maintained frontal ostial patency in patients with a history of multiple ESS. Additional randomized trials are necessary to determine statistical significance, cost-effectiveness analysis, and long-term efficacy of frontal sinus implantation.

(Allergy Rhinol 6:e68–e75, 2015; doi: 10.2500/ar.2015.6.0104)

Chronic rhinosinusitis (CRS) represents one of the most common health care problems in the United States, with significant loss of productivity and quality of life associated with the disease.[1,2] In recent years, much knowledge has been gained regarding the multifactorial etiology of CRS, with both host (*i.e.*, allergy, immunodeficiency, ciliary immotility, anatomic obstruction, *etc.*) and environmental factors (*i.e.*, bacterial/viral infections, biofilms, and pollutants) believed to contribute to its pathogenesis. Current treatment of CRS has focused on addressing such underlying issues as well as attenuating inflammation. To that end, a broad spectrum of therapeutic agents have been used in the medical management of CRS, including antibiotics, corticosteroids, antihistamines, saline irrigations, immunomodulators, *etc*.[3,4] When such medical therapy has failed, endoscopic sinus surgery (ESS) has been employed as an effective second-line intervention, with reported success rates of 76%–98%.[5] Focused removal of diseased tissue and judicious widening of natural drainage pathways during ESS help to relieve sinonasal obstruction, reestablish ventilation, and facilitate mucociliary flow.

However, achieving long-term, positive outcomes with ESS is contingent upon optimization of the wound healing environment during the postoperative period.[6] Local complications, such as scar formation, middle turbinate lateralization, and stenosis of surgically enlarged ostia, can lead to recurrent blockage and eventual surgical failure. Residual inflammation can also impede mucosal recovery and incite polypoid disease, further compromising surgical results.[6] A myriad of postoperative strategies, both mechanical and pharmaceutical, have been developed to mitigate such issues, including stents/spacers, steroids, and medicated irrigations.[7]

In 2011 a steroid-eluting sinus implant was developed (PROPEL, Intersect ENT, Palo Alto, CA) and approved by the United States Food and Drug Administration (FDA) for use in the post-ESS ethmoid cavity.[8] The implant is comprised of a biodegradable polyactide-co-glycolide polymer matrix infused with 370 μg of mometasone furoate (MF), which is gradually released to surrounding tissues over a 30-day period. Such technology has enabled targeted steroid delivery directly to sinus mucosa with simultaneous stenting of the sinonasal cavity. This dual functionality has led to significantly enhanced ESS outcomes with implant use,

[1]*Orange County Sinus Institute, Southern California Permanente Medical Group, Irvine, California, and* [2]*Department of Head and Neck Surgery, David Geffen School of Medicine at University of California, Los Angeles, Los Angeles, California*
Presented as a poster at the American Rhinologic Society Annual Meeting, September 20, 2014, Orlando, Florida
The authors have no conflicts of interest to declare pertaining to this article
Address correspondence to Jivianne T. Lee, M.D., 6670 Alton Parkway, Irvine, CA 92618
E-mail address: jivianne@gmail.com
Copyright © 2015, OceanSide Publications, Inc., U.S.A.

Delivered by Publishing Technology to: University of Liverpool IP: 138.253.100.121 On: Sat, 18 Apr 2015 10:07:32
Copyright (c) Oceanside Publications, Inc. All rights reserved.
For permission to copy go to https://www.oceansidepubl.com/permission.htm

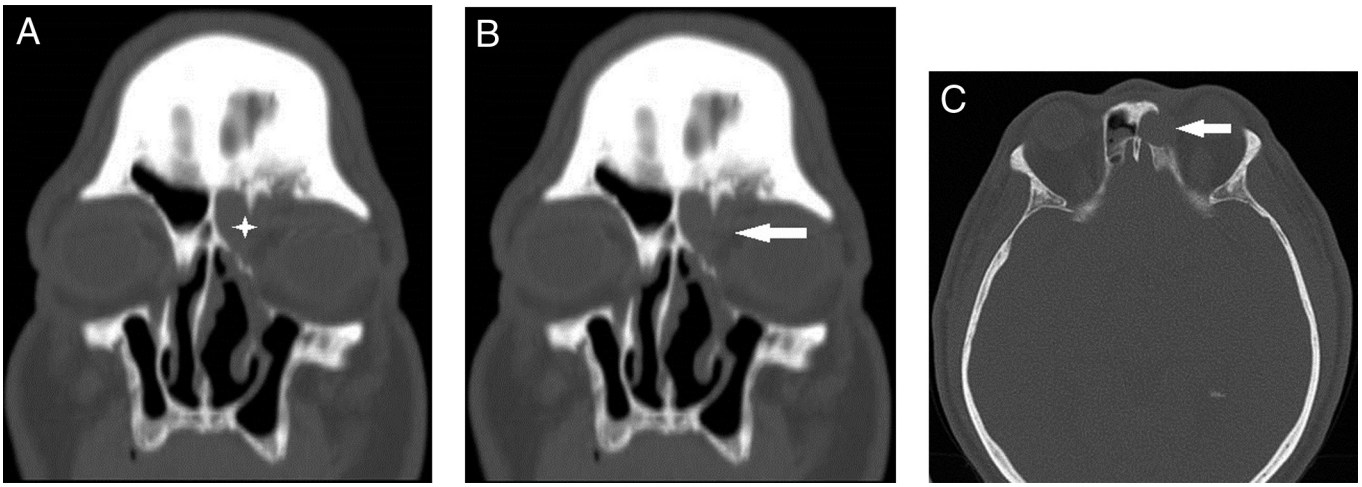

Figure 1. *Preoperative coronal (A and B) and axial (C) CT images demonstrated complete opacification of the left frontal sinus (start) with an absent lateral wall, corresponding to the superomedial aspect of the orbit (arrows).*

as demonstrated in three clinical trials and a meta-analysis of the aggregate data.[8–14] Significant reductions in adhesion formation, middle turbinate lateralization, and polypoid change as well as the need for secondary postoperative medical (oral steroid administration) and surgical interventions (lysis of adhesions) have been reported with ethmoid implantation.[8–14]

In 2012, the FDA approved a smaller version of the ethmoid implant which contained the same dosage of MF as the original product but featured a reduced scaffold size (PROPEL mini, Intersect ENT, Palo Alto, CA). Although designed for deployment in a narrower ethmoid cavity, its diminished profile has made it amenable to off-label application in the frontal sinus. However, use of the steroid-releasing implant for the frontal sinus has yet to be described. The purpose of this report is to present two cases in which in-office placement of a MF-eluting implant successfully maintained frontal ostial patency in patients with a history of revision ESS.

CASE REPORT

A 63-year-old male presented to our clinic with left-sided frontal pressure and headache for six months. He also complained of intermittent purulent rhinorrhea from the left, but denied having any nasal obstruction, nasal congestion, postnasal drip, or visual changes. His previous surgical history was significant for three Lynch procedures (two on the left, one on the right) from 1992 to 1993 as well as a left revision ESS in 1995 for CRS. Since the most recent procedure, the patient noted longstanding anosmia but otherwise had no complaints until the time of presentation.

On nasal endoscopy, the patient was found to have a stenosed antrostomy with a residual uncinate process. There was also evidence of a partial ethmoidectomy with remaining partitions along the anterior skull base. The middle turbinate appeared to have been previously resected. No frontal sinus outflow tract could be visualized, and thick synechiae could be seen obstructing the frontal recess. After a three-week course of broad spectrum antibiotics, a computed tomography (CT) scan was obtained. Complete opacification of the left frontal sinus was shown with an absent lateral wall, corresponding to the superomedial aspect of the orbit (Fig. 1, *A–C*). Due to his persistent symptoms and radiographic findings, the patient elected to proceed with left revision endoscopic sinus surgery. Triplanar stereotactic imaging was performed in preparation for computer-assisted surgical navigation.

Intraoperatively, significant neoosteogenesis was encountered within the frontal recess, requiring extensive drilling to open the frontal sinus outflow tract (Fig. 2 *A*). Once all the bone was removed, copious mucopurulent secretions began to drain from the frontal sinus proper (Fig. 2 *B*). Specimens were sent for aerobic and anaerobic cultures which grew *Staphylococcus aureus*. A Draf 2B frontal sinusotomy was then completed, with a 70° diamond burr and angled instrumentation used to take down the nasofrontal beak and enlarge the frontal sinus ostium (Fig. 2, *C* and *D*). At the conclusion of the procedure, inspection with a 70° 4-mm telescope revealed a patent frontal sinus neostium (Fig. 2 *E*). No stent nor packing materials were placed. There were no complications, and the patient was discharged home with a steroid taper and a three-week course of antibiotics.

However, the patient missed all of his subsequent follow-up visits for postoperative debridement. He then returned to our clinic two months later, complaining of recurrent left-sided frontal pressure and discolored rhinorrhea. On nasal endoscopy, mucopurulent drainage was present, and the frontal sinus outflow

Delivered by Publishing Technology to: University of Liverpool IP: 138.253.100.121 On: Sat, 18 Apr 2015 10:07:32
Copyright (c) Oceanside Publications, Inc. All rights reserved.
For permission to copy go to https://www.oceansidepubl.com/permission.htm

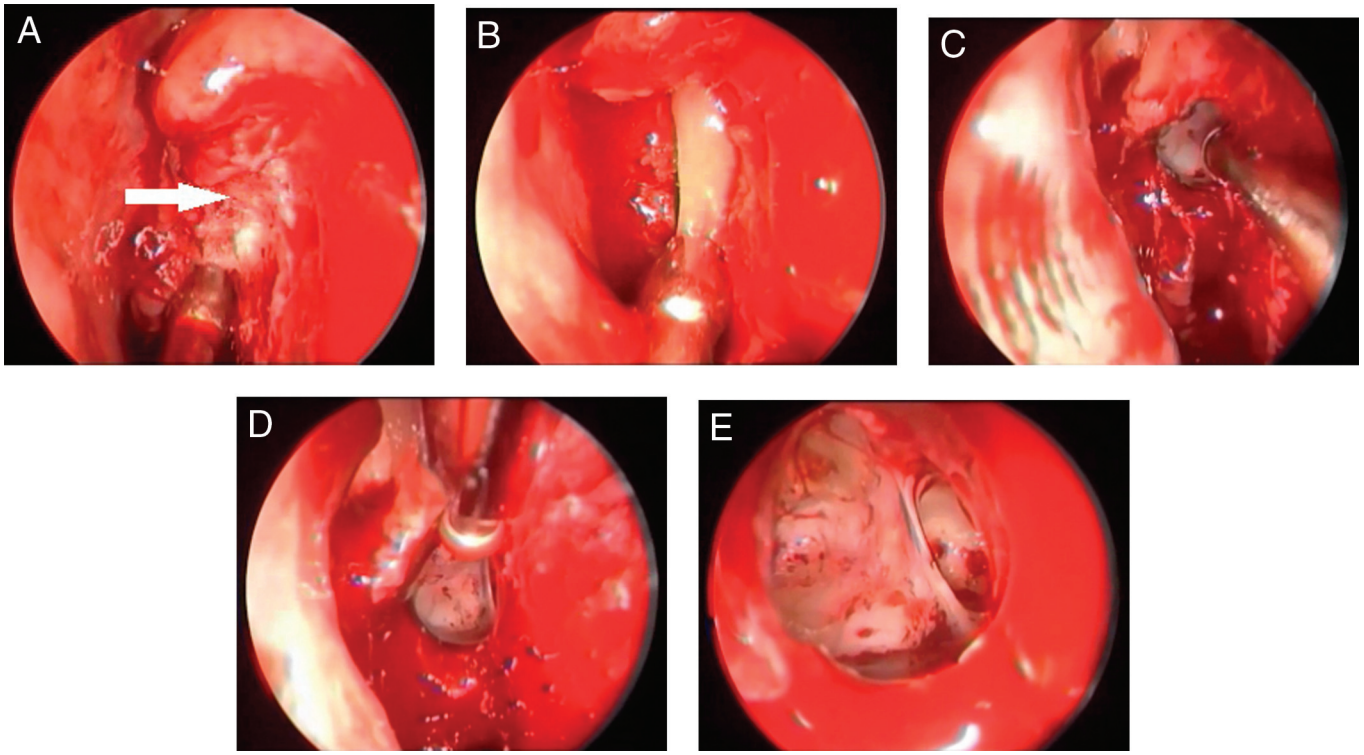

Figure 2. *Intraoperative endoscopic photographs showing neoosteogenesis (arrow) within the frontal recess (A), mucopurulent secretions draining from the frontal sinus (B), enlargement of the frontal sinus outflow tract (C and D), and a patent frontal neostium (E) at the conclusion of surgery.*

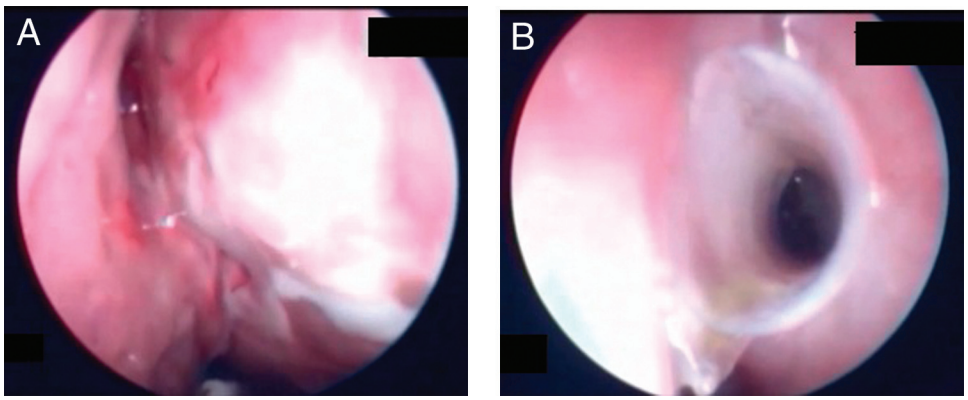

Figure 3. *Postoperative nasal endoscopy revealed mucopurulent discharge with no frontal ostium visualized (A). After reopening of the frontal sinus outflow tract, a silastic stent was placed to maintain ostial patency (B).*

tract could no longer be visualized (Fig. 3 *A*). Cultures were obtained and grew *Streptococcus pneumoniae* and *Pantoea* species. Under local anesthesia, frontal sinus instruments as well as balloon dilation were used to reopen the ostium in the clinic. This was repeated on multiple appointments over the span of six to eight weeks and the patient placed on culture-directed antibiotics. Nevertheless, the ostium continued to close in between visits, leading to persistent infection. Ultimately, due to issues with patient compliance, a silastic stent was placed to maintain frontal sinus ostial patency (Fig. 3 *B*).

The patient did well for eight months, while continuing saline and budesonide rinses, but then returned once again presenting with left-sided forehead/periorbital pressure and discolored rhinorrhea. Inspection with a 70° endoscope revealed the stent to still be in the proper position with a stenosed but patent frontal ostium. However, the stent was clearly infected with yellow, mucopurulent secretions surrounding the foreign body (Fig. 4 *A*). The stent was removed, revealing inflamed mucosa lining the frontal sinus (Fig. 4 *B*). At this point, the patient was offered a Draf III procedure, but he declined to pursue any further surgical intervention. The pus was suctioned and sent for culture, which grew *Pseudomonas putida*, *Stenotrophomonas maltophilia*, and *S. aureus*. The frontal sinus ostium was enlarged using balloon dilation. A steroid-eluting sinus

Delivered by Publishing Technology to: University of Liverpool IP: 138.253.100.121 On: Sat, 18 Apr 2015 10:07:32
Copyright (c) Oceanside Publications, Inc. All rights reserved.
For permission to copy go to https://www.oceansidepubl.com/permission.htm

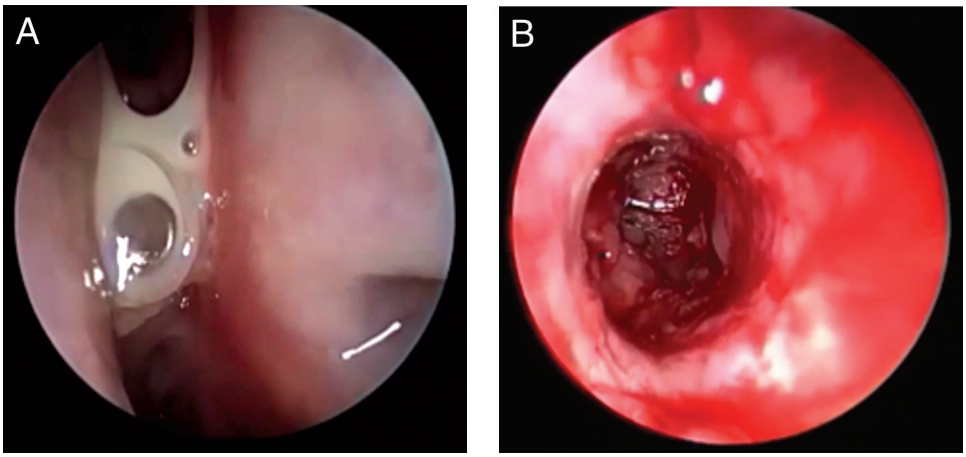

Figure 4. Follow-up nasal endoscopy showed the silastic stent in proper position but with mucopurulent secretions present (A). After stent removal and ostial dilation, inflamed mucosa could be seen lining the frontal sinus (B).

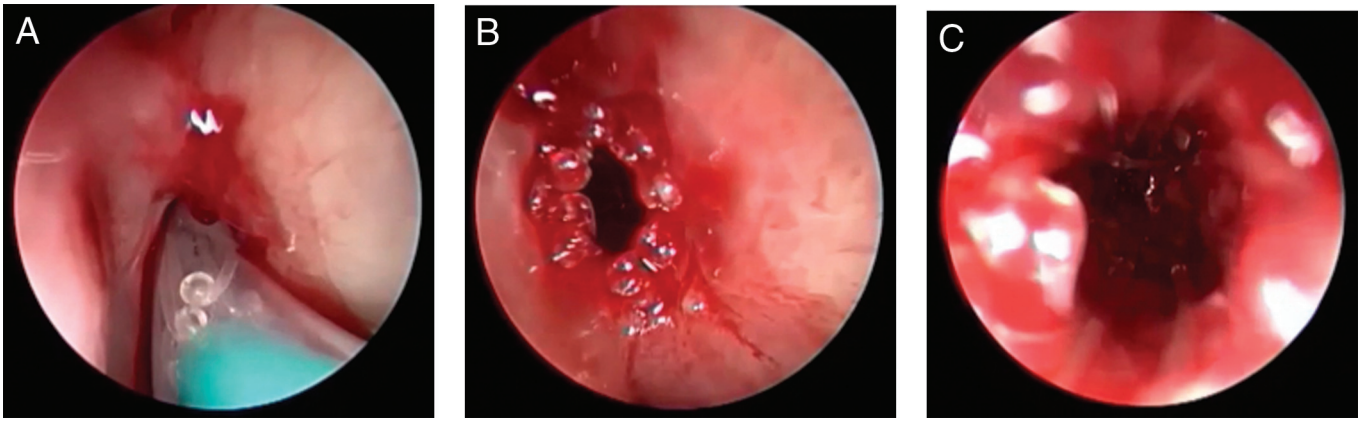

Figure 5. Endoscopic photographs illustrating deployment of the steroid-eluting implant into the frontal sinus (A), with its inferior edge circumferentially abutting the frontal ostium (B) and the remainder interfacing with the mucosa of the frontal sinus (C).

implant (PROPEL mini, Intersect ENT) was then deployed into the frontal sinus (Fig. 5 *A*). The implant was positioned such that its inferior edge abutted the frontal ostium circumferentially (Fig. 5 *B*), and the remainder interfaced with the inflamed frontal sinus mucosa to optimize drug delivery (Fig. 5 *C*).

Three and six weeks after implantation, the frontal ostium remained open with residual fragments still visible (Fig. 6, *A* and *B*). By 10 weeks, the implant had resorbed completely (Fig. 6 *C*), with frontal ostial patency maintained upon last follow-up at 11 months (Fig. 6 *D*). During the follow-up period, clear mucus would be suctioned at times around the ostium, but no crusting ever developed and no debridements were necessary to keep the stent patent before its absorption. The implant resorbed completely by 10 weeks without the need for removal of fragments. The patient has had no evidence of recurrent infection and has not required any further topical or systemic steroids since sinus implantation.

Case Two

A 68-year-old man presented to our clinic with worsening left-sided frontal pressure and headache for one year. He had been treated with multiple courses of antibiotics, oral steroids, and six months of twice daily budesonide irrigations without any improvement in his symptoms. His previous surgical history was significant for four bilateral endoscopic sinus surgeries in 1995, 1998, 2001, and 2006 for CRS. Since the most recent procedure, he had sustained longstanding anosmia but denied having any purulent rhinorrhea, postnasal drip, nasal congestion, obstruction, or visual changes.

Nasal endoscopy showed evidence of a previous ethmoidectomy with a clear posterior skull base, but residual partitions could be appreciated within the frontal recess. A sinus CT was obtained, which demonstrated mucosal thickening of the left frontal sinus (Fig. 7 *A*). Remnants of bone obstructing the frontal sinus outflow tract could also be appreciated on sagittal views (Fig. 7 *B*). Left revision ESS was recommended, but the patient declined to undergo general anesthesia and instead elected to proceed with left revision frontal sinusotomy in the clinic. After topical and local anesthesia were administered, frontal sinus instruments and balloon dilation were used to remove the remaining bony ledges within the frontal recess

Delivered by Publishing Technology to: University of Liverpool IP: 138.253.100.121 On: Sat, 18 Apr 2015 10:07:32
Copyright (c) Oceanside Publications, Inc. All rights reserved.
For permission to copy go to https://www.oceansidepubl.com/permission.htm

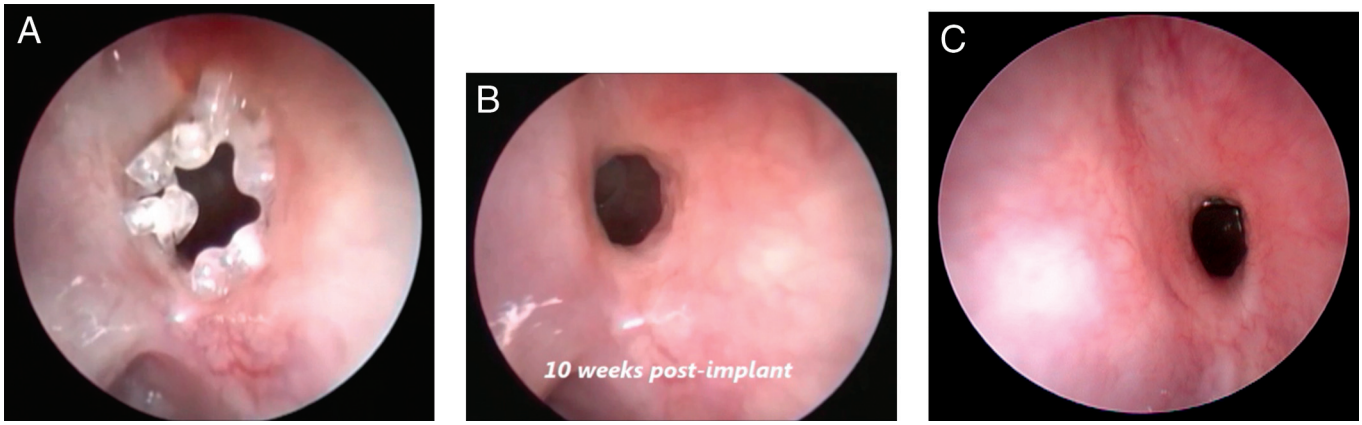

Figure 6. Endoscopic photograph at three weeks (A) postimplant showed an open frontal ostium with residual fragments still present. By 10 weeks (B), the implant had resorbed completely, with frontal ostial patency maintained upon last follow-up at 11 months (C).

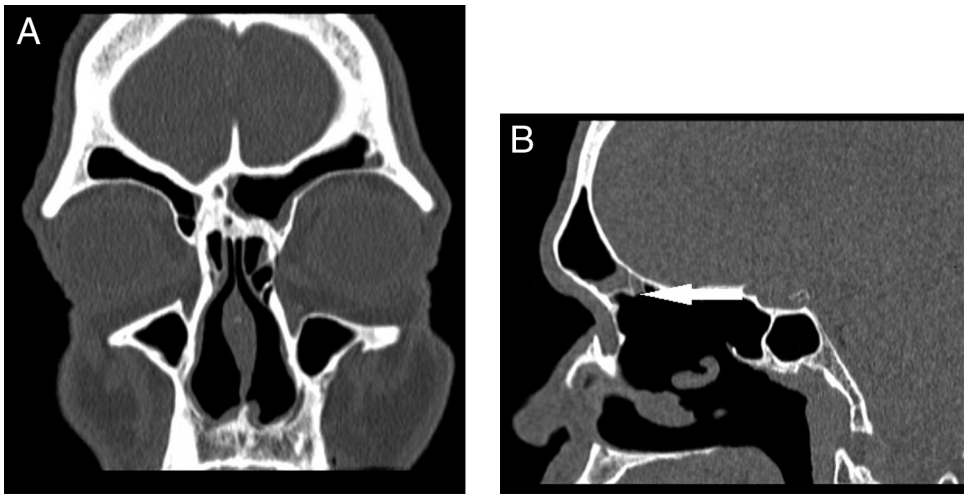

Figure 7. CT images demonstrated mucosal thickening of the left frontal sinus on coronal (A) and sagittal views (B), with residual bony remnants (arrow) obstructing the frontal sinus outflow tract.

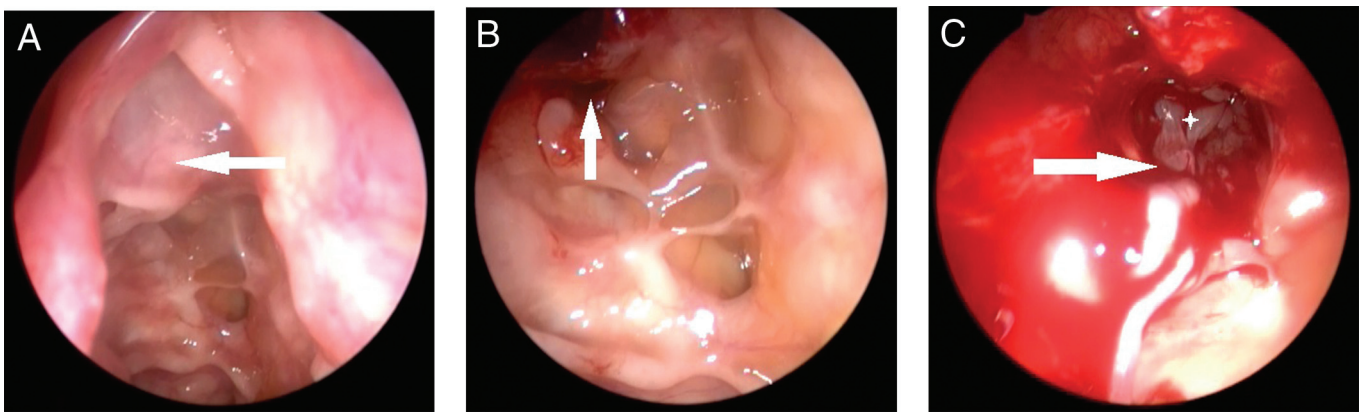

Figure 8. (A) Nasal endoscopy showed residual partitions (arrow) within the frontal recess. (B) After partial removal, the frontal sinus outflow tract could be visualized (arrow). (C) Enlargement of the natural ostium of the frontal sinus (arrow) revealed polyps (star) within the sinus cavity which were debrided.

and enlarge the natural ostium of the frontal sinus (Fig. 8, *A*–*C*). Significant polypoid inflammation was encountered within the frontal sinus (Fig. 8 *C*). Therefore, a steroid-eluting implant (PROPEL mini, Intersect ENT) was placed (Fig. 9).

At three weeks (Fig. 10 *A*) postimplantation, the inflammation within the frontal sinus had subsided considerably and the ostium remained open. By seven weeks (Fig. 10 *B*), the implant had dissolved completely with continued preservation of ostial patency

Delivered by Publishing Technology to: University of Liverpool IP: 138.253.100.121 On: Sat, 18 Apr 2015 10:07:32
Copyright (c) Oceanside Publications, Inc. All rights reserved.
For permission to copy go to https://www.oceansidepubl.com/permission.htm

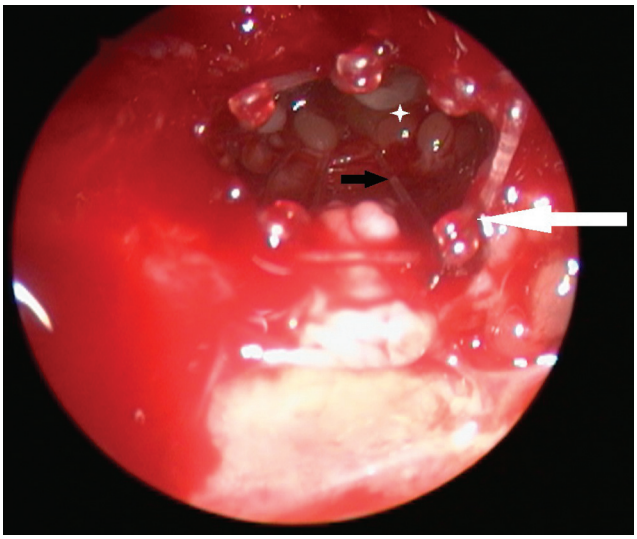

Figure 9. Endoscopic photograph depicting the steroid-eluting implant within the frontal sinus. Its inferior edge approximates the frontal ostium circumferentially (large arrow), whereas the remainder lies flush against the frontal sinus mucosa (small arrow). Note the polypoid inflammation present within the frontal sinus (star).

and no evidence of recurrent polypoid inflammation. No debridements were necessary while the stent was in place to maintain ostial patency, and no topical steroid therapy was given postoperatively. The patient also reported complete resolution of his symptoms after sinus implantation, with no further headaches upon last follow-up at six months.

It should be noted that it is unknown whether balloon dilation and topical steroids, without concurrent sinus implantation would have yielded a similar outcome in this case. The decision to place the steroid-eluting implant was based on the significant amount of polypoid inflammation in the frontal sinus in the context of multiple revision ESS, leading us to suspect he would fail such a trial if attempted.

DISCUSSION

Sinus implantation represents a novel mode of topical drug delivery, in which localized, sustained release of corticosteroids is coupled with mechanical force to facilitate healing of the postsurgical cavity and preserve ostial patency. Currently FDA approved for ethmoid use only, the implant is constructed in an open-lattice configuration, with a unique spring-like design that enables it to physically separate sinonasal tissues as it expands to conform to the shape of the dissected sinus. When compressed, the implant has a diameter of 5.2 mm, which widens to 23 mm once deployed. It is typically inserted intraoperatively under endoscopic visualization at the conclusion of ESS, allowing direct, sustained application of MF to the diseased ethmoid mucosa after surgery.[8]

This dual functionality of mechanical dilation and antiinflammatory therapy in sinus implantation has been shown to safely and effectively improve postoperative ESS outcomes, as demonstrated in three multicenter studies and a metaanalysis of the aggregate data (more than 200 CRS patients).[9–12] In the initial pilot study by Murr *et al.*,[12] a double-blinded randomized controlled trial was performed on 38 CRS patients who had the steroid-eluting implant placed in the post-ESS ethmoid cavity on one side and the identical, non-steroid-eluting implant on the other. At the 60-day follow-up, significant reductions in polyp formation, adhesions, and inflammation were observed on the treatment side compared with controls.[12] Likewise, in a follow-up study by Forwith *et al.* (a single cohort, prospective clinical evaluation of 50 CRS patients, ADVANCE), polypoid tissue, scarring, and middle turbinate lateralization were reported in only 10%, 1.1%, and 4.4% of implanted patients, respectively.[9] Statistically significant improvement in patient-reported outcomes and quality of life (Sinonasal Outcomes Test-22, Rhinosinusitis Disability Index) were also described with no deleterious ocular sequelae noted. Subsequently, in a larger double-blinded randomized controlled trial of 105 CRS patients (ADVANCE II), a decreased need for secondary postoperative medical (oral steroids) and surgical (lysis of adhesions) interventions was reported in implanted ethmoid sinuses versus controls.[10] Most recently, in a metaanalysis of pooled data (143 CRS patients) from the pilot and ADVANCE II trials, independent panel results revealed statistically significant, relative reductions of 46%, 40%, 51%, and 35% in nasal polyposis, oral steroid administration, lysis of adhesions, and overall postsurgical interventions, respectively, compared with controls.[11] Only two device-related adverse events have been reported thus far, an exacerbation of sinus pressure secondary to crusting and granulation tissue leading to implant removal.[13] Although rare, hypersensitivity reactions to stent components have been previously reported. However, these were primarily in association with retained nonabsorbable stents containing metal struts.[15] Collectively, these studies have demonstrated the clinical benefits of localized steroid delivery via sinus implantation during the postoperative period.

However, these trials primarily investigated the effects of ethmoid implant placement intraoperatively during ESS. Although the potential application of this technology in the office has been postulated, only one series has explored sinus implantation in the clinic setting. This was the recently published prospective multicenter study by Lavigne *et al.*, in which 12 patients with a history of previous ESS and recurrent polyposis underwent in-office placement of MF-eluting implants in the ethmoid sinuses.[16] After one month, statistically significant reductions in mean en-

Delivered by Publishing Technology to: University of Liverpool IP: 138.253.100.121 On: Sat, 18 Apr 2015 10:07:32
Copyright (c) Oceanside Publications, Inc. All rights reserved.
For permission to copy go to https://www.oceansidepubl.com/permission.htm

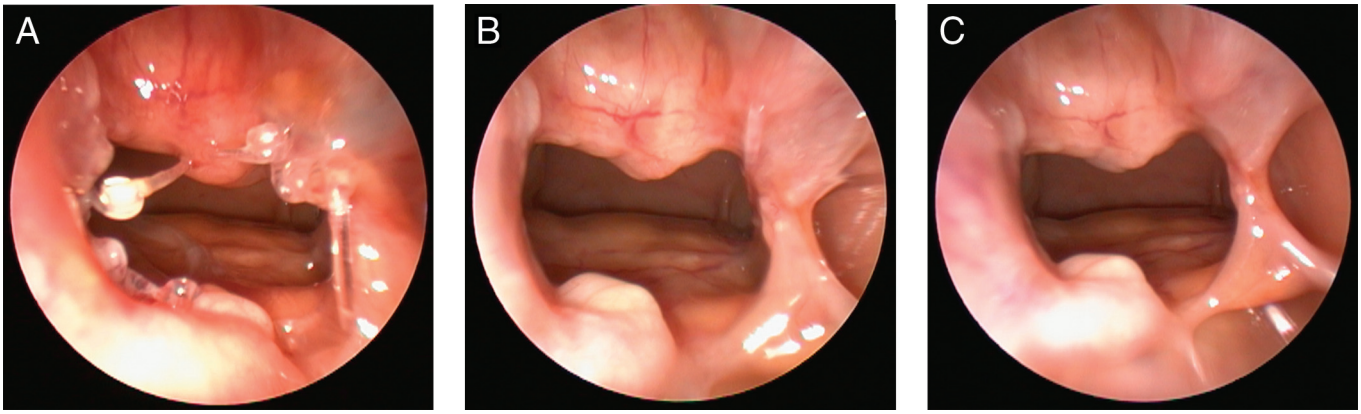

Figure 10. *Endoscopic photograph at three weeks (A) postimplant showed an open frontal ostium with residual fragments still present. Note the marked decrease in polypoid inflammation within the frontal sinus. By seven weeks (B), the implant had resorbed completely with continued maintenance of frontal ostial patency after three months of follow-up (C).*

doscopic polyp grades and Sinonasal Outcomes Test-22 scores were observed, outcomes which were sustained over the course of six months. Furthermore, 64% patients had improved to such a degree that they were no longer deemed candidates for revision ESS.[16]

Thus far, sinonasal application of steroid-eluting implants has been limited to the ethmoid cavity. Use of the MF-releasing spring implant within the frontal sinus has yet to be described. When affected by CRS, the frontal sinus can be particularly problematic secondary to its complex anatomy and narrow outflow tract. Frontal ostial restenosis rates of 33%–50% have been reported after ESS, with 12%–30% requiring revision surgery.[17,18] Multiple strategies have been devised to address such scarring during the postoperative period, including various stents, spacers, pharmacologic dressings, *etc.* with mixed results.[19,20] In-clinic procedures, such as balloon catheter dilations, have also been used to treat such recalcitrant disease and recurrent frontal stenosis. Although success in thwarting revision surgery has been reported, a fair proportion of (17%) patients require repeated dilations due to restenosis as seen in the first patient.[21]

To our knowledge, no studies have been published investigating the use of steroid-eluting implants in the frontal sinus. Here, we report on two patients with a history of multiple sinus surgeries, refractory CRS, and frontal stenosis, in which in-office placement of the MF-releasing implant successfully maintained ostial patency. The PROPEL mini has a compressed diameter of 4.0 mm (versus 5.2 mm), which enlarges to 16 mm (versus 23 mm) upon maximal expansion. Although initially created for patients undergoing less extensive sinus surgery or possessing narrower ethmoid anatomy, its diminished scaffold profile and curved delivery system have made it amenable to frontal sinus delivery. As demonstrated in the cases presented, frontal sinus implantation can be performed in the clinic setting under endoscopic visualization with local anesthesia. Similar to previous published results, the first patient with recurrent frontal sinusitis initially required multiple in-office debridements and balloon dilations to maintain ostial patency.[21] However, after placement of the MF-releasing implant, both patients experienced complete resolution of their symptoms and required no additional procedures or oral steroid therapy.

These two patients exemplify the benefits of simultaneously addressing the anatomic obstruction and inflammation that are often the hallmark of CRS. This synergistic combination of ostial dilation and sinus implantation may represent a minimally invasive, in-office therapeutic alternative for management of select patients with medically and surgically refractory frontal CRS. As technologies involving impregnated, bioresorbable stents evolve, MF-releasing sinus implants may represent just the beginning of an entire new spectrum of devices harboring both drug-eluting and mechanical stenting capabilities. Future implants may be engineered to conform specifically to the maxillary, sphenoid, and frontal sinuses. In addition, the implant polymer matrix could be loaded with different medications, including high-dose antibiotics, other antiinflammatory agents, or various combinations of drugs. This opens the door to a vast array of topical pharmaceutical therapies that could be administered to each of the sinuses for purposes of facilitating postoperative wound healing, treating recurrent infection, or managing persistent inflammation. In a study by Huvenne *et al.*,[22] doxycycline-releasing frontal stents were found to suppress bacterial growth, reduce matrix metalloproteinase-9 levels, and improve postoperative healing of the frontal region. With such technology, the need for systemic medical therapy and revision ESS may be obviated in certain patients. However, limitations of drug-eluting frontal stents must be kept in mind. Long-

Delivered by Publishing Technology to: University of Liverpool IP: 138.253.100.121 On: Sat, 18 Apr 2015 10:07:32
Copyright (c) Oceanside Publications, Inc. All rights reserved.
For permission to copy go to https://www.oceansidepubl.com/permission.htm

term efficacy remains unclear, and establishing a patent outflow tract is still needed before stent placement. Hypersensitivity reactions to implant or drug components may also occur. Furthermore, potential adverse sequelae associated with repeated or multiple sinus implantation must also be elucidated.

CONCLUSION

In-office placement of a MF-eluting implant successfully maintained frontal ostial patency in two patients with a history of multiple ESS and refractory frontal sinusitis. Such intervention may emerge as an effective, office-based therapeutic option for this patient population. Additional randomized trials are necessary to determine statistical significance, cost-effectiveness analysis, and long-term efficacy of frontal sinus implantation.

REFERENCES

1. Bhattacharyya N. Functional limitations and workdays lost associated with chronic rhinosinusitis and allergic rhinitis. Am J Allergy Rhinol 26:120–122, 2012.
2. Rudmik L, Smith TL, Schlosser RJ, et al. Productivity costs in patients with refractory chronic rhinosinusitis. Laryngoscope 124:2007–2012, 2014.
3. Lund VJ. Maximal medical therapy for chronic rhinosinusitis. Otolaryngol Clin N Am 38:1301–1310, 2005.
4. Fokkens W, Lund V, and Mullol J, European Position Paper on Rhinosinusitis and Nasal Polyps Group. EP^{3}OS 2007: European position paper on rhinosinusitis and nasal polyps 2007. A summary for otorhinolaryngologists. Rhinology 45:97–101, 2007.
5. Kennedy DW, Wright ED, and Goldberg AN. Objective and subjective outcomes in surgery for chronic sinusitis. Laryngoscope 110:29–31, 2000.
6. Hosemann W, Wigand ME, Göde U, et al. Normal wound healing of the paranasal sinuses: clinical and experimental investigations. Eur Arch Otorhinolaryngol 248:390–394, 1991.
7. Rudmik L, Soler ZM, Orlandi RR, et al. Early postoperative care following endoscopic sinus surgery: an evidence-based review with recommendations. Int Forum Allergy Rhinol 1:417–430, 2011.
8. Kennedy DW. The PROPEL™ steroid-releasing bioabsorbable implant to improve outcomes of sinus surgery. Expert Rev Respir Med 6:493–498, 2012.
9. Forwith KD, Chandra RK, Yun PT, et al. ADVANCE: a multisite trial of bioabsorbable steroid-eluting sinus implants. Laryngoscope 121:2473–2480, 2011.
10. Marple BF, Smith TL, Han JK, et al. Advance II: a prospective, randomized study assessing safety and efficacy of bioabsorbable steroid-releasing sinus implants. Otolaryngol Head Neck Surg 146:1004–1001, 2012.
11. Han JK, Marple BF, Smith TL, et al. Effect of steroid-releasing sinus implants on postoperative medical and surgical interventions: an efficacy meta-analysis. Int Forum of Allergy Rhinol 2:271–279, 2012.
12. Murr AH, Smith TL, Hwang PH, et al. Safety and efficacy of a novel bioabsorbable, steroid-eluting sinus stent. Int Forum Allergy Rhinol 1:23–32, 2011.
13. Wei CC, and Kennedy DW. Mometasone implant for chronic rhinosinusitis. Medical Devices 5:75–80, 2012.
14. Lee JT, and Han JK. Sinus implants for chronic rhinosinusitis: technology evaluation. Expert Opin Drug Deliv 10:1735–1748, 2013.
15. Kounis NG, Soufras GD, and Hahalis G. Stent hypersensitivity and infection in sinus cavities. Allergy Rhinol 4:e162–e165, 2013.
16. Lavigne F, Miller SK, Gould AR, et al. Steroid-eluting sinus implant for in-office treatment of recurrent nasal polyposis: a prospective, multicenter study. Int Forum Allergy Rhinol 4:381–389, 2014.
17. Hosemann W, Kühnel T, Held P, et al. Endonasal frontal sinusotomy in surgical management of chronic sinusitis: a critical evaluation. Am J Rhinol 11:1–19, 1997.
18. Friedman M, Bliznikas D, Vidyasagar R, et al. Long-term results after endoscopic sinus surgery involving frontal recess dissection. Laryngoscope 116:573–579, 2006.
19. Bednarski KA, and Kuhn FA. Stents and drug-eluting stents. Otolaryngol Clin N Am 42:857–866, 2009.
20. Chan KO, Gervais M, Tsaparas Y, et al. Effectiveness of intraoperative mitomycin C in maintaining the patency of a frontal sinusotomy: a preliminary report of a double-blind randomized placebo-controlled trial. Am J Rhinol 20:295–299, 2006.
21. Luong A, Batra PS, Fakhri S, et al. Balloon catheter dilatation for frontal sinus ostium stenosis in the office setting. Am J Rhinol 22:621–624, 2008.
22. Huvenne W, Zhang N, Tijsma E, et al. Pilot study using doxycycline-releasing stents to ameliorate postoperative healing quality after sinus surgery. Wound Repair Regen. 16:757–767, 2008. □

Delivered by Publishing Technology to: University of Liverpool IP: 138.253.100.121 On: Sat, 18 Apr 2015 10:07:32
Copyright (c) Oceanside Publications, Inc. All rights reserved.
For permission to copy go to https://www.oceansidepubl.com/permission.htm