A case of type I Kounis syndrome caused by double allergens

Yi-Xuan Zhang[1,2], Lu Liu[3], Li-Ping Liu[1,2], Hui Xu[1,2], Yu-Mei Li[1,2]

[1]Research Center of Stem Cell and Regenerative Medicine, Affiliated Hospital of Jiangsu University, Zhenjiang, Jiangsu 212001, China;
[2]Department of Dermatology, Affiliated Hospital of Jiangsu University, Zhenjiang, Jiangsu 212001, China;
[3]Department of Emergency Medicine, The Fourth Affiliated Hospital of Jiangsu University, Zhenjiang, Jiangsu 212001, China.

To the Editor: A 42-year-old Chinese man presented with head trauma caused by a brief loss of consciousness and fell after a bee sting on his nasal root while cycling outdoors. After being rushed to the emergency room, he developed sweats, dizziness, headaches, bosom frowsty, shortness of breath, and urinary incontinence. Blood pressure was 74/47 mmHg, blood oxygen saturation was 81%, and pulse rate was 149 beats/min. Physical examination revealed mental confusion, bilateral pupils diameter at 3 mm, slightly pupil insensitivity to light reflection, and rigid abdomen. 25 mg promethazine and 10 mg dexamethasone were administered immediately. The patient had no previous history of cardiovascular disease or related risk factors. However, he had a history of bee stings with no obvious abnormalities observed before. The electrocardiogram (ECG) showed sinus tachycardia (152 beats/min), ST-segment depression in II-III, and ST-segment elevation in aVR [Figure 1A]. Echocardiography and chest X-ray showed no abnormalities. Laboratory tests revealed the white blood cell count of 17.06×10^9/L (normal range: 3.5–9.5×10^9/L), eosinophil count of 0.73×10^9/L (normal range: 0.02–0.52×10^9/L), creatine kinase-MB (CK-MB) level of 29.5 ng/L (normal range: 0–5 ng/L), cardiac troponin I level of <0.5 ng/mL (normal range: 0–1 ng/mL), and myoglobin level of 249.1 ng/mL (normal range: 0–70 ng/mL); no other indicators showed obvious abnormalities. The patient underwent coronary angiography, but there were no significant abnormalities. A dermatologist performed specific immunoglobulin E (S-IgE) tests after consultation [Figure 1B], which revealed that S-IgE for tree combination (willow/poplar/elm) was 11.4 kU/L (normal range: 0–0.35 kU/L). After anti-allergy medications were administered and fluid infusion, the patient's condition improved, and the ECG and myocardial enzyme abnormalities were normalized. The doctor recommended the patient to avoid exposure to allergens. After follow-up for 1 year, the patient did not have any similar episodes.

In 1991,[1] Kounis and Zavras first proposed the concept of anaphylactic angina and myocardial infarction, namely Kounis syndrome. The condition is a type of cardiac allergic reaction caused by the activation and degranulation of mast cells colonized in the heart.[2] The patients can present symptoms of acute coronary syndrome (such as palpitations, bosom frowsty, nausea, and dyspnea). Physical stimulation, mental stress, food, drugs, chemical agents, venom, etc., can induce the disease.[3] In this case, the anaphylactic shock occurred immediately after the patient was stung by a bee. The ECG showed signs of acute myocardial infarction, while myoglobin and CK-MB levels were significantly elevated (representing early myocardial infarction/myocardial injury). The eosinophil count was also elevated. The combined clinical signs and laboratory and ECG results were consistent with acute myocardial ischemia and a systemic allergic reaction. The patient was diagnosed with Kounis syndrome.

Kounis syndrome can be divided into three categories according to patient's clinical symptoms and laboratory tests.[4] In the type I variation, patients have no previous history of coronary artery diseases, and the acute release of inflammatory mediators induces coronary spasms, which may have angina manifestations. The coronary angiography will show no significant abnormalities, while these patients bear the illness dominantly through the "allergic" mechanism. Considering all the characteristics, the patient we reported in this case belongs to the type I variation of Kounis syndrome. In the type II variation, patients have suffered from cholestasis or occult atherosclerotic diseases. The coronary angiography will show obstructive coronary arteries, in which the "heart" mechanism predominates. Currently, some scholars have classified Kounis syndrome type III as heart reactions caused by stent thrombosis during the period of anaphylaxis after coronary stenting.

Access this article online	
Quick Response Code:	Website: www.cmj.org
	DOI: 10.1097/CM9.0000000000000684

Correspondence to: Dr. Yu-Mei Li, Department of Dermatology, Affiliated Hospital of Jiangsu University, 438 Jiefang Road, Jingkou District, Zhenjiang, Jiangsu 212001, China
E-Mail: yumeili@ujs.edu.cn

Copyright © 2020 The Chinese Medical Association, produced by Wolters Kluwer, Inc. under the CC-BY-NC-ND license. This is an open access article distributed under the terms of the Creative Commons Attribution-Non Commercial-No Derivatives License 4.0 (CCBY-NC-ND), where it is permissible to download and share the work provided it is properly cited. The work cannot be changed in any way or used commercially without permission from the journal.

Chinese Medical Journal 2020;Vol(No)
Received: 10-09-2019 **Edited by:** Pei-Fang Wei

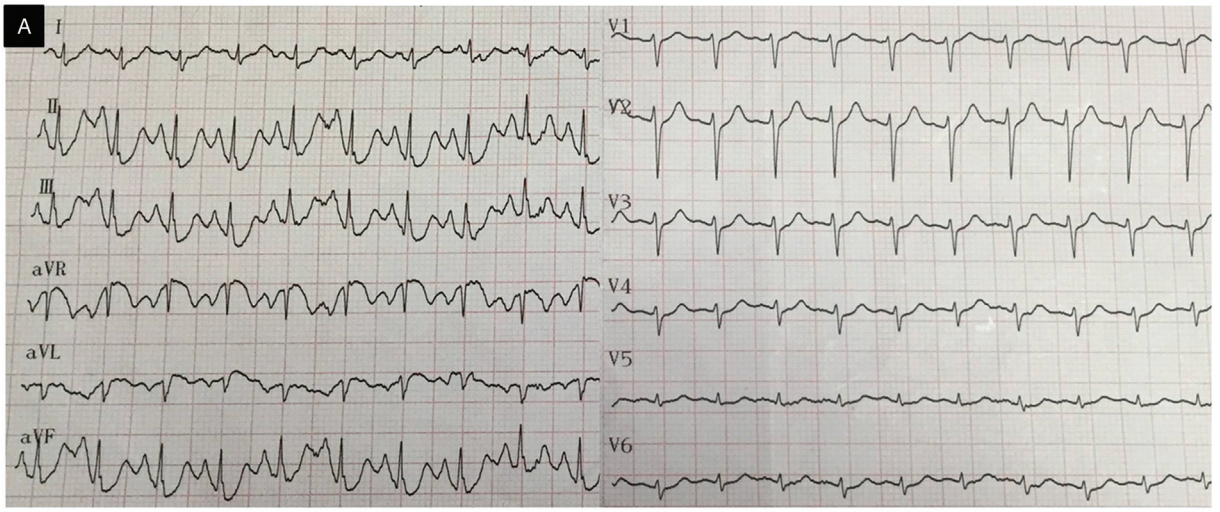

B

	Concentration	Class
Tree mix 2 (ts20)	11.4 kU/l	3
Common ragweed (w1)	10.4 kU/l	3
Mugwort (w6)	1.0 kU/l	2
House dust mite mix 1 (ds1)	< 0.35 kU/l	0
House dust (h1)	< 0.35 kU/l	0
Cat (e1)	< 0.35 kU/l	0
Dog (e2)	0.43 kU/l	1
Cockroach (i6)	0.43 kU/l	1
Mould mix 1 (ms1)	< 0.35 kU/l	0
Hop (u80)	0.52 kU/l	1
Egg white (f1)	< 0.35 kU/l	0
Cow's milk (f2)	< 0.35 kU/l	0
Peanut (f13)	2.7 kU/l	2
Soybean (f14)	0.60 kU/l	1
Beef (f27)	< 0.35 kU/l	0
Mutton/ Lamb (f88)	< 0.35 kU/l	0
Sea fish mix 1 (fs33)	< 0.35 kU/l	0
Shrimp/ Prawn (f24)	< 0.35 kU/l	0
Crab (f23)	0.52 kU/l	1
CCD marker (CCD)	9.5 kU/l	3

Concentration [kU/l]	Class	Explanation
0 ≤ sIgE < 0.35	0	No specific antibodies detected.
0.35 ≤ sIgE < 0.7	1	Very weak antibody detection, often no clinical symptoms with an existing sensitization.
0.7 ≤ sIgE < 3.5	2	Weak antibody detection, existing sensitization, often with clinical symptoms in upper levels.
3.5 ≤ sIgE < 17.5	3	Definite antibody detection, clinical symptoms are often present.
17.5 ≤ sIgE < 50	4	Strong antibody detection, almost always with existing symptoms.
50 ≤ sIgE < 100	5	Very high antibody titer.
sIgE ≥ 100	6	Very high antibody titer.

Figure 1: Valuable examination results of the patient. (A) Electrocardiogram showing acute myocardial infarction, sinus tachycardia (152 beats/min), ST-segment depression in II-III, ST-segment elevation in aVR, and poor R-wave progression in V1-V6 with high and sharp T-wave. (B) S-IgE test results: S-IgE level of tree mix (willow/poplar/elm) and common ragweed at level III (0.7 kU/L ≤ S-IgE < 3.5 kU/L), which means a definite antibody detection, with clinical symptoms often present. CCD: Cross-reactive carbohydrate determinants; S-IgE: Specific immunoglobulin E.

There are no established guidelines for Kounis syndrome treatment. Corticosteroids and histamine H1- and H2-receptor blockers are required in addition to antithrombotic therapy.[4]

Interestingly, the patient had a previous history of bee stings, but he showed no complications before. The onset season for the patient was spring, which is the season of local willow and poplar trees' floating fluff. According to

the S-IgE tests performed on the patient, he was found to be highly sensitized to willow, poplar, and elm. Therefore, we hypothesized that the patient was exposed to a sensitizing environment of trees' fluff when he cycled outside. In addition, the patient was stung by a bee at the same time. The double sensitization might have caused the patient to develop Kounis syndrome. In this case, the combination of allergens is rare. Kounis syndrome itself is not dangerous. The danger is that clinicians lack awareness of the disease. Healthcare professionals should be familiar with Kounis syndrome and should carefully screen for allergens as a treatment guide for the condition.

Declaration of patient consent

The authors certify that they have obtained all appropriate patient consent forms. In the form, the patient has given his consent for his images and other clinical information to be reported in the journal. The patient understands that his name and initials will not be published and due efforts will be made to conceal the identity of the patient, although anonymity cannot be guaranteed.

Acknowledgements

The authors thank all the staff from the Department of Emergency Medicine and Cardiovascular Medicine (The Fourth Affiliated Hospital of Jiangsu University, Zhenjiang, Jiangsu, China) for their help with this study.

Funding

This work was supported by a grant from the National Natural Science Foundation of China (No. 81573053).

Conflicts of interest

None.

References

1. Kounis NG, Zavras GM. Histamine-induced coronary artery spasm: the concept of allergic angina. Br J Clin Pract 1991;45:121–128.
2. Fassio F, Almerigogna F. Kounis syndrome (allergic acute coronary syndrome): different views in allergologic and cardiologic literature. Intern Emerg Med 2012;7:489–495. doi: 10.1007/s11739-012-0754-4.
3. Zavras GM, Papadaki PJ, Kokkinis SE, Kalokairinov K, Kouni SN, Batsolaki M, *et al*. Kounis syndrome secondary to allergic reaction following shellfish ingestion. Int J Clin Pract 2003;57:622–624. doi: 10.1046/j.1445-5994.2003.00459.x.
4. Biteker M. Current understanding of Kounis syndrome. Expert Rev Clin Immunol 2010;6:777–788. doi: 10.1586/eci.10.47.

How to cite this article: Zhang YX, Liu L, Liu LP, Xu H, Li YM. A case of type I Kounis syndrome caused by double allergens. Chin Med J 2020;00:00–00. doi:10.1097/CM9.0000000000000684