Ann Allergy Asthma Immunol 111 (2013) 242–245

Contents lists available at ScienceDirect

Maintenance of certification-CME Review

Imported fire ant allergy: case presentation and review of incidence, prevalence, diagnosis, and current treatment

Daniel A. Steigelman, MD [*]; and Theodore M. Freeman, MD [†]

[*] *Wilford Hall Ambulatory Surgical Center, San Antonio, Texas*
[†] *San Antonio Asthma and Allergy Clinic, San Antonio, Texas*

ARTICLE INFO

Article history:
Received for publication March 27, 2013.
Received in revised form May 31, 2013.
Accepted for publication July 4, 2013.

INSTRUCTIONS

Credit can now be obtained, free for a limited time, by reading the review article in this issue and completing all activity components. Please note the instructions listed below:

- Review the target audience, learning objectives and all disclosures.
- Complete the pre-test online at http://www.annallergy.org (click on the CME heading).
- Follow the online instructions to read the full version of the article, including the clinical vignette; reflect on all content as to how it may be applicable to your practice.
- Complete the post-test/evaluation and claim credit earned; at this time, you will have earned up to 1.0 *AMA PRA Category 1 Credit*™. Please note that the minimum passing score on the post-test is 70%.
- Approximately 4-6 weeks later you will receive an online assessment regarding your application of this article to your practice. Once you have completed this assessment, you will be eligible to receive MOC Part II credit from the American Board of Allergy and Immunology.

Release Date: October 1, 2013
Expiration Date: September 30, 2015
Estimated Time to Complete: 60 minutes
Target Audience: Physicians involved in providing patient care in the field of allergy/asthma/immunology
Learning Objectives:
At the conclusion of this activity, participants should be able to:

- Describe the risk of exposure to the imported fire ant by age and geographic area
- Describe the benefits of imported fire ant whole body extract immunotherapy and reduction in risk of anaphylaxis to future stings

Accreditation: The American College of Allergy, Asthma & Immunology (ACAAI) is accredited by the Accreditation Council for Continuing Medical Education (ACCME) to provide continuing medical education for physicians.
Designation: The American College of Allergy, Asthma & Immunology (ACAAI) designates this journal-based CME activity for a maximum of 1 *AMA PRA Category 1 Credit*™. Physicians should claim only the credit commensurate with the extent of their participation in the activity.
Planning Committee Members:
Theodore M. Freeman, MD (Author)
Michael S. Tankersley, MD (CME Series Editor)
Gailen D. Marshall, Jr, MD, PhD (Editor-in-Chief)
Disclosure of Relevant Financial Relationships:
D.A. Steigelman, T.M. Freeman, M.S. Tankersley, and G.D. Marshall have no relevant financial relationships to disclose. Reviewers and Education/Editorial staff have no relevant financial relationships to disclose. No unapproved/investigative use of a product/device is discussed.
Recognition of Commercial Support: This activity has not received external commercial support.
Copyright Statement: © 2013-2015 ACAAI. All rights reserved.
CME Inquiries: Contact the American College of Allergy, Asthma & Immunology at education@acaai.org or 847-427-1200.

Reprints: Theodore M. Freeman, MD, 9522 Maytum Circle, Helotes, TX; E-mail: TFree95900@aol.com.
Disclosures: Dr Freeman is the author of *Conn's Current Therapy* and *UpToDate*, a reviewer for the Texas Medical Board, on the advisory board of McKeeson Medicare and the board of the American Academy of Allergy, Asthma, and Immunology, and president-elect of the Texas Allergy, Asthma, and Immunology Society.

1081-1206/13/$36.00 - see front matter © 2013 American College of Allergy, Asthma & Immunology. Published by Elsevier Inc. All rights reserved.
http://dx.doi.org/10.1016/j.anai.2013.07.006

Clinical Vignette

A 17-year-old female patient was referred for allergy evaluation and found to have a concerning imported fire ant (IFA) reaction history. At 16 years of age, the patient had 5 stings to the bilateral lower extremities (roughly 10 IFA stings) during Junior Reserve Officer Training Corps summer field training in Texas. She had been feeling perfectly well but within minutes of being stung developed lightheadedness with nausea and emesis. She felt anxious, was too dizzy to walk independently, and was assisted into a vehicle and taken to a medical tent. There, her lightheadedness worsened and she was assisted in ambulation and placed supine on an examination table, where she had complete syncope. She denied other symptoms. Because of the syncope, she did not recall what events had transpired and next recalled waking up several hours later in the treatment tent, released without further instructions or treatments. She developed pseudopustules with large local reactions (LLRs) on the bilateral legs.

She had skin testing for IFA 10 months later and was negative to the skin prick test. Eight minutes after the first 1:1,000,000 weight for volume (wt/vol) intradermal test, she developed globus, lightheadedness, dizziness, difficulty breathing, and chest tightness. She stood to move to the treatment room and collapsed with brief syncope. A technician caught her fall. She was laid supine and received epinephrine 0.3 mg in the thigh. A 3- × 5-mm wheal with flare at the intradermal site was noted. An intravenous line was placed, a normal saline bolus was started, and albuterol 2.5 mg nebulization was given. The first set of vital data obtained 6 minutes after her first epinephrine dose recorded a blood pressure of 129/69 mm Hg and a heart rate of 135 beats/min. Six minutes after the first epinephrine dose, the patient complained of ongoing symptoms and was given epinephrine 0.5 mg in the thigh. Vital signs remained stable. Examination was remarkable for cold clammy pale skin without rash; the lungs were clear. She reported that all symptoms improved within 30 minutes of the second epinephrine dose.

Her serum tryptase level at baseline was 2 ng/mL. Rapid induction of tolerance (RIT) was completed without reactions and she started a program of maintenance immunotherapy with IFA whole body extract (WBE).

Introduction

Fire ants are in the order Hymenoptera, superfamily Vespidae, family Formicidae, subfamily Myrmicinae, tribe Solenopsidini, and genus *Solenopsis*. Species native to the United States include *Solenopsis xyloni*, *Solenopsis geminata*, and *Solenopsis aurea*. The term *imported fire ant* describes 2 non-native species, *Solenopsis richteri* and *Solenopsis invicta*, venomous insects capable of causing clinical reactions ranging from localized pruritic sterile pustules to a spectrum of IgE-mediated hypersensitivity, including death from anaphylaxis. Considered a threat to the southeastern United States through most of the 20th century, the IFA has been found on the continents of Asia, Australia, and North and South America.[1] Native to Uruguay, *S richteri* was introduced into the United States in 1918 in the ballast of cargo ships through the port of Mobile, Alabama. Native to Argentina, *S invicta* was introduced in the 1930s and currently is the dominant species of IFA.[2] The IFA has spread to affect at least 343 million acres in the United States, including the entirety of 6 states and portions of 8 (Fig 1). Annual economic damage in the United States is estimated to exceed $6 billion.[3]

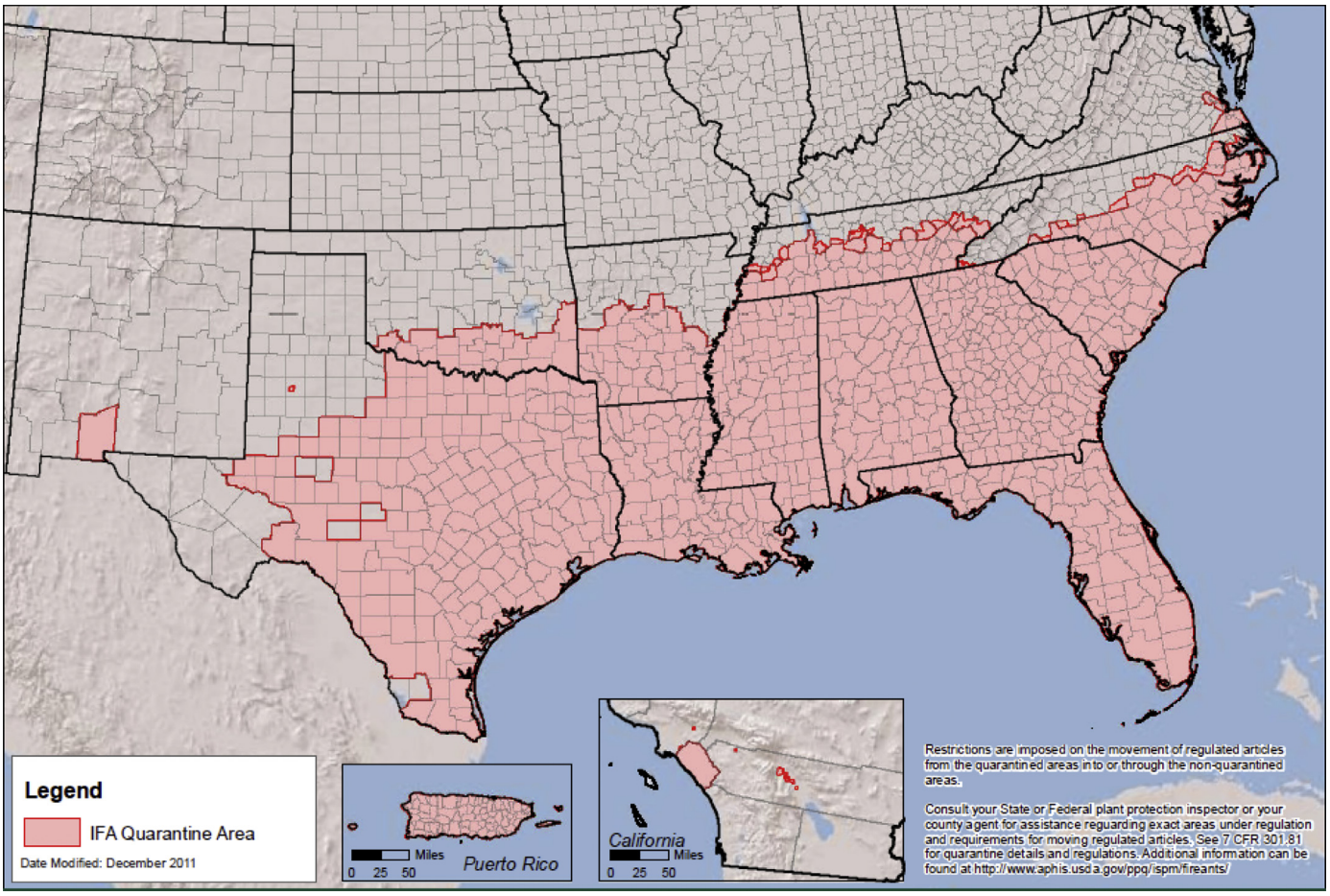

Figure 1. Endemic imported fire ant (IFA) areas in the United States. Adapted from the United States Department of Agriculture Animal and Plant Health Inspection Service.

Beyond the borders of the contiguous United States, the IFA affects the entirety of Puerto Rico and portions of China, Taiwan, Australia, and New Zealand.[1,3]

Fire ants may build in excess of 500 mounds per acre, with multiple queens per colony. Mounds can be built in open areas, such as lawns, playgrounds, and athletic fields, and move underneath pavement and near buildings to overwinter. Disturbance of a mound results in a swarm of thousands of ants that respond by stinging anything the ants contact.[4] Stings from the IFA occur when the insect bites and grasps the skin with its mandible, laterally flexing its abdomen to bring the distal abdomen caudal, and stings. It can sting multiple times in a radial pattern as it moves its abdomen in an arc. The natural reaction to an undisturbed sting is formation of a sterile 1- to 2-mm pseudopustule secondary to piperidine alkaloids, which confer to the venom insecticidal, bactericidal, and fungicidal activity.[5] Four protein allergens have been characterized in *S invicta*. Sol I 2 and 4 are unique to *S invicta*, Sol I 3 is a member of the antigen 5 family but does not cross-react with wasp antigen 5, and Sol I 1 is a phospholipase A_1B similar to wasp venom phospholipases, showing cross-reactivity. *Solenopsis richteri* expresses proteins Sol R 1, 2, and 3 (similar to Sol I 1, 2, and 3) but not a protein similar to Sol I 4.[6]

A prospective study of 107 adults from nonendemic IFA areas visiting San Antonio, Texas for 3 weeks in the summer reported a sting incidence of 51%. None reported generalized cutaneous or systemic reactions (SRs). Seven of those stung (12.7%) developed skin test reactivity; radioallergosorbent testing was positive in only 1.[7] A survey of 182 children living in an IFA-endemic area reported 38.6% stung by IFAs during the previous month, and 23.9% reported more than 6 stings. Of all insect stings reported, IFAs accounted for 92.1% and flying hymenoptera accounted for 7.9%.[8] Children tended to be more at risk for IFA stings in a rural environment than in suburban or city environments.[8]

In endemic areas, the IFA is the leading cause of hypersensitivity among all hymenoptera. Children are at greatest risk of showing sensitization to IFA by specific IgE, and serum sensitization appears to wane after childhood. Random screening of discarded serum in IFA-endemic areas have shown IFA-specific IgE levels higher than 0.35 kUa/L detectable in 38.3% of children, varying with age from 35.7% in children 2 to 5 years old to 57.5% in children 11 to 20 years old.[8] Random screening of adult blood in an IFA-endemic area found IFA-specific IgE levels of at least 0.35 kIU/L detectable in only 17%.[9] By comparison, IgE specific for yellow jacket venom was detectable in random serum screenings of 7.6% of children in an IFA-endemic area and in 10% of adults. This compares with random adult screenings of adult blood in a nonendemic IFA area that found IgE specific for yellow jacket venom more commonly than IFA-specific IgE (6.5% vs 2%, respectively).[9] Of 703 patients in an IFA-endemic area referred to an allergy clinic for venom allergy, the leading cause of hymenoptera hypersensitivity diagnosed by history and/or skin testing was IFA (42% of patients), followed by wasp (29%), white-faced and bald-faced hornets (16%), yellow jacket (15%), and honey bee (12%).[10]

Reactions to IFA stings may include sterile pustules, LLRs, generalized cutaneous reactions consisting solely of pruritus and urticaria, and systemic symptoms of anaphylaxis. From 17% to 56% of patients develop LLRs.[5] Children who initially have large local or cutaneous reaction have not been found to progress to SRs with future stings: of 31 children 16 years or younger evaluated for local or cutaneous reaction to IFA, none of 20 who were later stung developed SRs over a mean follow-up time of 4.9 years.[11] A survey completed by 2,022 physicians who treated 20,755 patients for fire ant stings estimated 413 (2%) had been treated for life-threatening anaphylaxis.[12] As of 1989, 84 deaths were reported by 2,506 physician surveys, most of which resulted from fewer than 5 stings.[13] A 15-year review of newspaper articles showed 10 indoor fire ant stings previously unreported in the medical literature; 10 indoor fire ant stings in the medical literature also were identified. Fourteen of 20 stings occurred in long-term health care facilities, and over half involved patients immobilized by age and/or disease. Six stings resulted in death within 1 week (patients' age, 3 months to 90 years).[14]

Table 1
Example of conventional imported fire ant whole body extract immunotherapy dosing schedule[a,15]

Dose	Concentration (wt/vol)	Volume (mL)
1	1:100,000	0.05
2	1:100,000	0.15
3	1:100,000	0.25
4	1:100,000	0.50
5	1:10,000	0.05
6	1:10,000	0.10
7	1:10,000	0.20
8	1:10,000	0.30
9	1:10,000	0.40
10	1:10,000	0.50
11	1:1,000	0.05
12	1:1,000	0.10
13	1:1,000	0.20
14	1:1,000	0.30
15	1:1,000	0.40
16	1:1,000	0.50
17	1:100	0.05
18	1:100	0.07
19	1:100	0.10
20	1:100	0.15
21	1:100	0.20
22	1:100	0.25
23	1:100	0.40
24	1:100	0.50

[a]Observation time 30 minutes. Injections may be given weekly or, in some cases, 2 times/week after the maintenance dose.

Skin testing is available with IFA WBE. Skin testing is considered positive with a response at a concentration of 1:1,000 wt/vol by skin prick and, if negative, by intradermal testing at serial concentrations ranging from 1:1,000,000 to 1:1,000 wt/vol. Serum specific-IgE to IFA also may provide evidence of sensitization. Treatment of choice for IFA anaphylaxis is epinephrine 0.01 mg/kg for children to a maximum of 0.3 mg and 0.3 to 0.5 mg in adults. Self-administration in the anterolateral thigh is recommended: patients should carry or have available appropriate epinephrine in outdoor and indoor environments. Immunotherapy with IFA WBE is recommended with a maintenance dose of 0.5 mL of a 1:100 wt/vol extract (Table 1). Increases in dose may be considered for treatment failures (SRs while on maintenance IFA immunotherapy). Because of their significant exposure risk, children who develop cutaneous reactions to IFA sting may be considered for IFA immunotherapy.[15]

Because IFA sting incidence is high in endemic areas, rapid attainment of a maintenance immunotherapy dose is desirable compared with conventional dosing schedules. One-day RIT has been shown to be safe and effective in children and adults. Although previous studies have used various maintenance doses, currently 0.5 mL of a 1:100 wt/vol extract is recommended.[15] In a retrospective study that first established IFA WBE efficacy (maintenance doses included 0.2 to 0.5 mL of 1:20 to 1:100 wt/vol), 47 of 65 patients on IFA immunotherapy reported 112 IFA stings and only 1 (2.1% of patients, 0.9% of stings) developed an anaphylactic reaction.[16] In 11 patients for whom IFA immunotherapy was recommended but declined, 2 of 6 who had a repeat sting developed a generalized cutaneous reaction and 4 of 6 developed anaphylaxis.[16] IFA immunotherapy was shown to decrease skin test reactivity in 31 of 31 follow-up patients, whereas skin test reactivity did not change or worsened in 4 of 4 who declined immunotherapy.[16] Thirty patients who completed IFA immunotherapy consented to a sting challenge by *S invicta*: all developed only a local reaction.[16] RIT using IFA WBE was evaluated with and without premedication in a study of 58 patients completing a 2-day protocol (Table 2).

Table 2
Two-day rapid induction of tolerance protocol[17]

Day	Volume (mL)	Concentration (wt/vol)
1	0.1[a]	1:10,000,000
	0.3[a]	1:10,000,000
	0.1[a]	1:1,000,000
	0.3[a]	1:1,000,000
	0.1[a]	1:100,000
	0.3[a]	1:100,000
	0.1[a]	1:10,000
	0.3[b]	1:10,000
2	0.1[a]	1:1,000
	0.2[a]	1:1,000
	0.3[a]	1:1,000
	0.4[a]	1:1,000
	0.5[a]	1:1,000
	0.1[a]	1:100
	0.2[a]	1:100
	0.3[b]	1:100
8	0.25[a]	1:100
	0.25[a]	1:100
15	0.5[a]	1:100
22[c]		
29	0.5[a]	1:100
50	0.5[a]	1:100
Monthly	0.5[a]	1:100

[a]Sixty minutes of observation.
[b]Two hours of observation.
[c]Two imported fire ant sting challenges.

Maintenance dose was 0.5 mL of 1:100 wt/vol IFA WBE. Three patients had an SR during the rush protocol (5.2%), 2 of whom were on placebo premedication and 1 on study premedication (terfenadine, ranitidine, and prednisone). Among clinical sting challenges using *S invicta* and reported field stings by IFA, only 1 of 56 patients reported symptoms of SR, a treatment efficacy rate of 98.2%.[17] A 1-day RIT protocol has been shown in a case series of 3 children 22 to 36 months old as safe without increased systemic effects or reactions, and 2 of the 3 children did not have any premedication (Table 3).[18] Safety of a 1-day RIT without premedication also was confirmed in adults. Thirty-seven adults 18 to 49 years old completed 1-day RIT, 28 of who completed RIT without reaction. Four had objective symptoms including urticaria and tachycardia, and 5 had subjective symptoms including generalized pruritus, dyspnea, and throat scratchiness.[19] A retrospective case–cohort study of 77 patients who received IFA conventional immunotherapy found a SR rate of 9.1% per patient (0.42% per injection). Five SRs occurred within 30 minutes in the office and were successfully treated with epinephrine; 3 SRs were reported by patients after office discharge and resolved without medical intervention. LLRs were found in 20.7% of patients (1.1% of injections). SRs occurred in buildup phase in 2.9% of injections and in maintenance phase in 3.9% of injections (no significant difference). Skin testing for IFA resulted in SRs in 9.5%; SR to IFA immunotherapy had significantly increased odds ratios for those with LLR to IFA sting and in those who had SR to skin testing.[20]

Table 3
One-day rapid induction of tolerance protocols[18,19]

Day	Volume (mL)	Concentration (wt/vol)
1	0.3[a]	1:100,000
	0.1[a]	1:10,000
	0.3[a]	1:10,000
	0.5[a]	1:1,000
	0.15[b]	1:1,000
	0.3[b]	1:1,000
	0.05[b]	1:100
	0.1[b]	1:100
	0.2[b]	1:100
	0.3[c]	1:100
8	0.25 each arm[a]	1:100
15	0.5[a]	1:100
22[d]		
29	0.5[a]	1:100
50	0.5[a]	1:100
Monthly	0.5[a]	1:100

[a]Observation time 30 minutes.
[b]Observation time 60 minutes.
[c]Observation time 2 hours.
[d]Imported fire ant sting challenge only in Dietrich et al.[19]

Conclusion

This clinical vignette shows that life-threatening anaphylaxis may develop in 2% of IFA sting victims in endemic areas. Sting rates range from 38% to 51%, with children often at disproportionate risk, and children show significantly greater prevalence of IgE sensitization to IFA than adults. IFA hypersensitivity is evaluated with WBE skin prick testing and, if negative, intradermal testing and/or IFA-specific serum IgE. Individuals with IFA hypersensitivity should be prescribed an epinephrine auto-injector appropriate for weight and age available indoors and outdoors. IFA immunotherapy is recommended for children and adults who have SRs; duration of therapy may depend on severity of reaction and risk of future reactions. IFA immunotherapy may be safely advanced to maintenance in 1 day using RIT.

References

[1] Ascunce MS, Yang CC, Oakey J, et al. Global invasion history of the fire ant Solenopsis invicta. *Science*. 2011;331:1066–1068.
[2] Lofgren CS, Banks WA, Glancey BM. Biology and control of imported fire ants. *Annu Rev Entomol*. 1975;20:1–30.
[3] Brown CL. USDA APHIS plant health, plant protection and quarantine: imported fire ants. Most recent update August 15, 2012. Available at: http://www.aphis.usda.gov/plant_health/plant_pest_info/fireants/index.shtml. Accessed Febraury 27, 2013.
[4] Kemp SF, deShazo RD, Moffitt JE, Williams DF, Buhner WA II. Expanding habitat of the imported fire ant (Solenopsis invicta): a public health concern. *J Allergy Clin Immunol*. 2000;105:683–691.
[5] Stafford CT. Hypersensitivity to fire ant venom. *Ann Allergy Asthma Immunol*. 1996;77:87–95.
[6] Hoffman DR. Ant venoms. *Curr Opin Allergy Clin Immunol*. 2010;10:342–346.
[7] Tracy JM, Demain JG, Quinn JM, Hoffman DR, Goetz DW, Freeman TM. The natural history of exposure to the imported fire ant (Solenopsis invicta). *J Allergy Clin Immun*. 1995;95:824–828.
[8] Partridge ME, Blackwood W, Hamilton RG, Ford J, Young P, Ownby DR. Prevalence of allergic sensitization to imported fire ants in children living in an endemic region of the southeastern United States. *Ann Allergy Asthma Immunol*. 2008;100:54–58.
[9] Caplan EL, Ford JL, Young PF, Ownby DR. Fire ants represent an important risk for anaphylaxis among residents of an endemic region. *J Allergy Clin Immun*. 2003;111:1274–1277.
[10] Freeman TM. Hymenoptera hypersensitivity in an imported fire ant endemic area. *Ann Allergy Asthma Immunol*. 1997;78:369–372.
[11] Nguyen SA, Napoli DC. Natural history of large local and generalized cutaneous reactions to imported fire ant stings in children. *Ann Allergy Asthma Immunol*. 2005;94:387–390.
[12] Stafford CT, Hutto LS, Rhoades RB, Thompson WO, Impson LK. Imported fire ant as a health hazard. *South Med J*. 1989;82:1515–1519.
[13] Rhoades RB, Stafford CT, James FK Jr. Survey of fatal anaphylactic reactions to imported fire ant stings. Report of the Fire Ant Subcommittee of the American Academy of Allergy and Immunology. *J Allergy Clin Immunol*. 1989;84:159–162.
[14] Rupp MR, deShazo RD. Indoor fire ant sting attacks: a risk for frail elders. *Am J Med Sci*. 2006;331:134–138.
[15] Golden DBK, Moffitt J, Nicklas RA, et al. Stinging insect hypersensitivity: a practice parameter update 2011. *J Allergy Clin Immunol*. 2011;127:852.e23–854.e23.
[16] Freeman TM, Hylander R, Ortiz A, Martin ME. Imported fire ant immunotherapy: effectiveness of whole body extracts. *J Allergy Clin Immunol*. 1992;90:210–215.
[17] Tankersley MS, Walker RL, Butler WK, Hagan LL, Napoli DC, Freeman TM. Safety and efficacy of an imported fire ant rush immunotherapy protocol with and without prophylactic treatment. *J Allergy Clin Immunol*. 2002;109:556–562.
[18] Judd CA, Parker AL, Meier EA, Tankersley MS. Successful administration of a 1-day imported fire ant rush immunotherapy protocol. *Ann Allergy Asthma Immunol*. 2008;101:311–315.
[19] Dietrich JJ, Moore LM, Nguyen S, Hagan LL, Tankersley MS. Imported fire ant hypersensitivity: a 1-day rush immunotherapy schedule without premedication. *Ann Allergy Asthma Immunol*. 2009;103:535–536.
[20] La Shell MS, Calabria CW, Quinn JM. Imported fire ant field reaction and immunotherapy safety characteristics: the IFACS study. *J Allergy Clin Immunol*. 2010;125:1294–1299.