IMMUNOLOGY, HEALTH, AND DISEASE

Polysaccharides from *Pinus massoniana* pollen improve intestinal mucosal immunity in chickens

Zhou Sha,[*,†] Hongqi Shang,[*,†] Yongqiang Miao,[*,†] Jin Huang,[*,†] Xiangyun Niu,[*,†] Ruichang Chen,[*,†] Duo Peng,[‡] Kai Wei,[*,†,1] and Ruiliang Zhu[*,†,1]

**Shandong Provincial Key Laboratory of Animal Biotechnology and Disease Control and Prevention, Shandong Agricultural University, Tai'an, Shandong 271018, China; †Shandong Provincial Engineering Technology Research Center of Animal Disease Control and Prevention, Shandong Agricultural University, Tai'an, Shandong 271018, China; and ‡Department of Immunology and Infectious Diseases, Harvard T.H. Chan School of Public Health, Boston, MA 02115, USA*

ABSTRACT Intestinal mucosa is the largest immune organ in animals, and its immune function is directly related to the resistance against various diseases. Taishan *Pinus massoniana* pollen polysaccharides (**TPPPS**) have been recognized as an effective vaccine adjuvant and potential immune enhancer against viral infections. However, little is known about their direct immune-enhancing activity on intestinal mucosa. In this study, we extracted the polysaccharides from Taishan masson pine pollen to investigate its promotive effect on intestinal mucosal immunity. A total of 120 1-day-old chickens were divided into 4 groups and inoculated with PBS or 3 different doses of TPPPS (10 mg/mL, 20 mg/mL, and 40 mg/mL), respectively. Feces, intestinal specimens, and serum samples were collected from the chickens at 7, 14, and 21 d after inoculation. The antibodies in serum, mucosal secretion of IgA, structure of intestinal villi, and expressions of cytokine genes and mucosal immune-related genes in the chickens were all significantly improved by TPPPS treatments. At 21 d after inoculation following the challenge of Newcastle disease virus, the chickens inoculated with 20 and 40 mg/mL TPPPS exhibited decreased weight loss and reduced intestinal pathologic damage and viral loads in the intestine. In summary, our results demonstrate that TPPPS can enhance mucosal immunity and promote intestinal villi development. This study has established the foundation for the development of novel immune-enhancing agent with immune-regulatory effects on intestinal mucosa.

Key words: intestinal mucosal immunity, chicken, Taishan *Pinus massoniana* pollen polysaccharides, immune-enhancing agent, innate immunity

2021 Poultry Science 100:507–516
https://doi.org/10.1016/j.psj.2020.09.015

INTRODUCTION

Pollen has been used as a dietary supplement in traditional medicine for hundreds of years. *Pinus massoniana* pollen, as a traditional Chinese food supplement and traditional Chinese medicine, has a wide range of health benefits, particularly in relieving fatigue and treating diseases (Yang et al., 2015). These beneficial effects are attributed to the various chemical constituents, including nucleic acids, enzymes and coenzymes, proteins, fats acids, phospholipids, monosaccharides, polysaccharides, flavonoids, vitamins, and so on. (He et al., 2007). Plant-derived compounds (e.g., polysaccharides and flavonoids) are effective in regulating and enhancing immunity (Fan et al., 2010; Licciardi and Underwood, 2011), whereas polysaccharides extracted from herbal medicine are widely used for vaccine development, owing to their excellent advantages in stable efficacy, minimum side effects, and no known toxicity (Kong et al., 2004, 2006; Ung et al., 2007). The international scientific community has proposed that the 21st century is a century of polysaccharides, one of the crucial biological macromolecules with a highly complex chemical structure and species specificity. Moreover, polysaccharides are also key factors for cell surface signal recognition, cell-to-cell signal transmission, and immune-related responses. Various polysaccharides isolated from plants and microorganisms have been used

© 2020 Published by Elsevier Inc. on behalf of Poultry Science Association Inc. This is an open access article under the CC BY-NC-ND license (http://creativecommons.org/licenses/by-nc-nd/4.0/).

Received July 30, 2020.

Accepted September 3, 2020.

[1]Corresponding authors: weikaisdau@163.com (KW); zhurl@sdau.edu.cn (RZ)

as effective biological response modifiers against cancer, immunodeficiency, and chronic infections (Ling et al., 2011; Feng et al., 2015).

The mucosal immune system is well known as one of the important parts of the entire immune network in animals, especially poultry. It is an independent immune system with unique structure–function features and plays critical roles in fighting against infections (Nochi et al., 2018). Intestinal mucosa is not only the crucial site for food digestion and nutrient absorption but also an immune organ with the largest surface area in animal bodies, where the largest number of immune cells are present and collectively form a strict defense system (Zhou et al., 2019). Moreover, mucosal surface also serves as the first line of defense against infections by directly contacting foreign antigens. Therefore, improving intestinal mucosal immunity can enhance the comprehensive immune functions, promote the resistance against various pathogenic invasions, and prevent intestinal damage or injuries (Zhao et al., 2020). Meanwhile, a growing number of relevant studies have shown that a variety of polysaccharides have a positive effect on enhancing mucosal immunity. For example, the uptake of litchi pulp polysaccharides was found to improve intestinal mucosal immune functions by stimulating cell proliferation and serum IgA secretion in mesenteric lymph nodes (Huang et al., 2016). In addition, the treatment of *Hericium erinaceus* polysaccharides in Muscovy ducks effectively and remarkably improved the morphology and relevant parameters of intestinal mucosa, increased the number of immune cells and the amount of secretory IgA (**SIgA**) and cytokines secreted by the intestinal mucosal immune system, as well as reversed the damage on intestine mucosal immune barrier (Wu et al., 2017). Similarly, yupingfeng polysaccharides were demonstrated to possess the aforementioned benefits by markedly enhancing the activation of the induction site on intestinal mucosa, stimulating the secretion of SIgA, and regulating both local and systemic immune responses (Deng et al., 2018). It was also shown that γ-irradiated *Astragalus* polysaccharides could prevent the negative morphologic changes of intestinal mucosa and at the same time, increase the number of immunocompetent cells in jejunal mucosa and upregulated the mRNA expression of certain intestinal cytokines (Li et al., 2019). In summary, the benefits of polysaccharides have attracted more attention for scientific research, and the identification of polysaccharides from new sources would certainly facilitate in-depth studies on the immunomodulatory effects of polysaccharides. Previous studies of Taishan *Pinus massoniana* pollen polysaccharides (**TPPPS**) mostly focused on their role as a natural adjuvant for vaccines against several viral infections. But, little is known about their immune-promotive effects on intestinal mucosa.

In the present study, we first detected the level of lipopolysaccharides (**LPS**) as an endotoxin in TPPPS to ensure that TPPPS itself affected the mucosal immunity of chickens in subsequent experiments and evaluated the promoting effect of TPPPS on the intestinal mucosa by measuring various immunologic indicators of the intestinal mucosa and villi. Furthermore, Newcastle disease virus (**NDV**) infection was induced on chickens to observe their intestinal villi structural changes and identify the efficacy of polysaccharides on enhancing intestinal mucosal resistance against viral pathogens. This study aimed to establish the foundation for developing a novel agent that has regulatory and immune-enhancing effects on intestinal mucosa.

MATERIALS AND METHODS

Ethics Statement

The animal experiments were approved by the Animal Protection and Utilization Committee of Shandong Agricultural University (Permit number: 20010510) and executed in accordance with Guide to Animal Experiments of Ministry of Science and Technology (Beijing, China). This study did not involve any endangered or protected species.

Reagents, Strains, and TPPPS

The following kits were used in this study: End-Point Chromogenic Endotoxin Test Kit (Xiamen Bioendo Technology Co., Ltd., China.) was used to detect LPS in polysaccharides, Chicken SIgA ELISA Kit and Chicken IgG ELISA Kit (Lengton Bioscience Co., Ltd., Shanghai, China) were used to detect the levels of SIgA in feces and IgG in serum, respectively, Ultrapure RNA kit (Beijing ComWin Biotech Co., Ltd., China) was used to extract RNA from intestinal tissue, HiScript II Q RT SuperMix and ChamQ Universal SYBR qPCR Master Mix (Nanjing Vazyme Biotech Co., Ltd., China) were used for Quantitative real-time PCR. Newcastle disease virus as a field strain was isolated in 2019 from a chicken in Shandong Province (A/Chicken/Shandong/06/2019) and was stored in our laboratory. Taishan *Pinus massoniana* pine pollen polysaccharides was extracted by the method of optimized water extraction and ethanol precipitation (Wei et al., 2011), and polysaccharide content was determined by the phenol–sulfuric acid method (Yang et al., 2015). All primers were synthesized by TSINGKE (Beijing TSINGKE Biotech Co., Ltd., China).

Endotoxin Test for TPPPS

The extracted TPPPS was tested for LPS content by the End-Point Chromogenic Endotoxin Test Kit as per the manufacturer's protocol, using LPS as the positive control.

Animal Experiment

A total of 120 1-day-old specific pathogen–free chickens were randomly divided into 4 groups (30 chickens per group). The chickens in the 3 treatment groups were orally administered with 10, 20, and

40 mg/mL TPPPS (0.2 mL/chicken), respectively. The chickens in the control group were orally administered with PBS (0.2 mL/chicken). After daily once administration for 21 consecutive days, all the chickens were intranasally challenged by 10^6 median tissue culture infective dose of NDV (A/Chicken/Shandong/06/2019). The design and procedures of the study are shown in Figure 1.

Mucosal SIgA and Serum IgG Antibodies Detection

Fresh feces from the intestines of chickens in each group were taken at 7, 14, and 21 d postinoculation (**dpi**), which were dissolved in PBS at 1 mL/g, and the samples were shaken on ice for 15 min and then centrifuged at 10,000 × g at 4°C for 5 min. The supernatant was based on the operation instructions of the Chicken SIgA ELISA Kit to detect SIgA levels. Fresh blood from chickens in each group was collected at 7, 14, and 21 dpi and coagulated for 20 min at room temperature. The samples were centrifuged at 3,000 rpm for 20 min; the collected serum was based on the operation instructions of the Chicken IgG ELISA Kit to detect IgG levels.

Real-Time PCR Assays for Detection of Intestinal Mucosal Cytokines and Mucosal Immune-Related Factor

Intestinal mucosal cytokines IL 2 (**IL-2**), IL 4 (**IL-4**), and interferon gamma were detected by real-time PCR. Immune-related factor CD80, CD86, MHC class I (**MHC-I**) genes (BF1 and BF2), and class II (**MHC-II**) genes (BLA, BLB1, and BLB2) were also detected by the same method. Real-time PCR was performed as per the method described by Liu et al. (Liu et al., 2019). The experimental primers are listed in Table 1. The $2^{-\Delta\Delta CT}$ method was used to normalize the data (Pfaffl, 2001).

Measurement of $CD4^+$ and $CD8^+$ T Lymphocyte Counts in Peripheral Blood

The percentage of $CD4^+$ and $CD8^+$ T lymphocytes in peripheral blood was measured by flow cytometry, following the method described in a previously published literature from our laboratory (Sha et al., 2020).

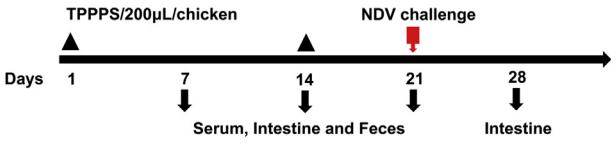

Figure 1. Animal experiment design. Chickens were grouped as described in the "Materials and Methods" and orally administered with TPPPS for 21 d. Multiple samples were collected at 7, 14, and 21 d after inoculation for detecting SIgA, IgG, cytokines, and mucosal immune-related factors, as well as measurement of intestinal villi conditions. Seven day after the final administration, tissue samples from intestine were collected for pathologic evaluation. Abbreviations: NDV, Newcastle disease virus; SIgA, secretory IgA; TPPPS, Taishan *Pinus massoniana* pollen polysaccharides.

Table 1. The primers used in this study.

Primer name	Sequence (5′-3′)
CD80-F	CACTGCATGAAGATGGGGTG
CD80-R	GGAAACCTGCAAAAGTGATC
CD86-F	AAAGAAAGCATCATGGAGGT
CD86-R	CTGGATATCTTTTAGACTGC
BF1-F	GCACAGCCCCATCCTCT
BF1-R	TGGCCCATCATTTTATTTCA
BF2-F	CCATCCGGGGGTATTATCA
BF2-R	TGGTGGGAACTGCCTCTG
BLA-F	TTCCGCAAGTTCTCCTATCTG
BLA-R	ACTTCCGGCTCCCACATC
BLB1-F	ACCGGCTGGCTTGCTAC
BLB1-R	GCGCTCTGTCTCCTCCTG
BLB2-F	TCGGCGTTCTTCTTCTACGG
BLB2-R	TGCCGGTTGTAGATTTGCCT
IL-2-F	CTCGGAGCTCTGCAGCGTGT
IL-2-R	TCCACCACAGTTGCTGGCTCATC
IL-4-F	CCACGGAGAACGAGCTCATC
IL-4-R	GAGAACCCCAGACTTGTTCTTCA
IFN-γ-F	ACAACCCACAGATCCAGC
IFN-γ-R	TCAGCACCGACTCCTTTT

Measurements of Villi Length and Width, Crypt Depth and Length, and Villus/Intestinal Crypt Value

The intact intestinal villi (n = 6–8 per group) were randomly selected to examine the length, width of villi, and the depth of crypts by using Digimizer Image Analysis software (Wang et al., 2020). Villi length was defined as the distance from the midpoint of the top villi point to the midpoint of mucosal fold point at both ends. Villi width was defined as the average value of the base, middle, and apex sections of intestinal villi. Crypt depth was defined as the distance between the midpoint of the mucosal reentry point at both ends and the inner surface of submucosa. The **V/C** value was defined as the ratio of the villi length to the crypt depth (Wang et al., 2019a).

Analysis of Protective Immune Responses

Fifteen randomly selected chickens from each group were challenged intranasally with NDV (A/Chicken/Shandong/06/2019), the same numbers of nonchallenge chickens served as negative controls in the mock group. The deaths of each group were recorded in the next 7 d. Five chickens were randomly selected to collect intestinal tissue on the seventh day. Villus mucosal inflammation and integrity were visualized by hematoxylin and eosin staining, and changes in BW of each chicken after challenge were recorded. And, quantitative real-time PCR was performed to detect intestinal mucosal viral loads, referring to the previous study (Zhang et al., 2010).

Statistical Analysis

The data from 3 independent experiments were expressed as means ± SD and analyzed using SPSS 23.0 software (SPSS Incorporated, Chicago, IL). A one-way ANOVA followed by an least significant difference mean separation was used to determine the

significance of differences. Values at $P < 0.05$ were considered statistically significant.

RESULTS

Endotoxin Content (LPS) in TPPPS

To exclude the effect of confounding factors, we measured LPS of pine pollen polysaccharides. The results showed that the LPS content of TPPPS (1,000 μg/mL) was 1.153 EU/mL, while 0.01 μg/mL of LPS was 1.562 EU/mL, which was 1.35-fold higher than that of TPPPS. However, the concentration of TPPPS is 10^5 times higher than that of LPS, so it shows that there is minimum LPS contamination in TPPPS, and its various effects come from itself.

Detection of Mucosal SIgA and Serum IgG

Overall, the SIgA contents in all the chickens were continuously increased. At 21 dpi, the intestinal levels of SIgA in the 20 and 40 mg/mL TPPPS groups reached 4.29, and 4.54 μg/mL respectively, which were 1.64- and 1.73-fold ($P < 0.01$) higher than that in the PBS group respectively. No significant ($P > 0.05$) difference was observed between these 2 TPPPS groups (Figure 2A), while their intestinal SIgA levels were significantly ($P < 0.01$) higher than that in the 10 mg/mL TPPPS group. Similarly, at 21 dpi, the serum levels of IgG in the 20 and 40 mg/mL TPPPS groups were significantly ($P < 0.01$) higher than that in the PBS or 10 mg/mL TPPPS group, respectively (Figure 2B).

Detection of Intestinal Mucosal Cytokines

At 7 dpi, the levels of IL-2, IL-4, and interferon gamma in the 40 mg/mL TPPPS group were significantly ($P < 0.01$) higher than those in the PBS group, whereas the IL-2 and IL-4 levels were not significantly ($P > 0.05$) different from those in the 20 mg/mL TPPPS groups. At 14 dpi, the levels of IL-4 and interferon gamma in the TPPPS treatment groups were higher than that in the PBS control group. At 21 dpi, the levels of these 3 cytokines were significantly ($P < 0.01$) elevated by TPPPS treatment in a dose-dependent manner (Figures 3A–C).

Detection of Mucosal Immune-Related Factors

Mucosal immune factors can directly reflect the overall intestinal mucosal immune functions in animals. The statistical analysis outcomes of CD80, CD86, MHC-I (BF1 and BF2), and MHC-II (BLA, BLB1, and BLB2) are shown in Figures 4A–G, respectively. The CD80 level was significantly ($P < 0.01$) elevated by TPPPS treatment in a dose-dependent manner at 7 dpi. Although no significant ($P > 0.05$) difference in the CD86 levels was observed among the 3 TPPPS treatment groups, they were significantly ($P < 0.01$) higher than that in the PBS control group. At 21 dpi, the levels of CD80 and CD86 in the 20 and 40 mg/mL TPPPS groups were statistically ($P > 0.05$) similar. Meanwhile, the levels of BF1 and BF2 in all the TPPPS treatment groups were significantly ($P < 0.01$) higher than those in the PBS control group at 14 dpi and that in the 40 mg/mL TPPPS group was higher ($P < 0.05$) than that in the 20 mg/mL TPPPS, whereas, no significant ($P > 0.05$) difference between these 2 groups was found at 21 dpi. In addition, the TPPPS treatments significantly ($P < 0.01$) upregulated the BLA, BLB1, and BLB2 levels in the chickens at 7 dpi. At 14 dpi, the chickens treated by 20 and 40 mg/mL TPPPS exhibited significantly higher levels of these 3 immune factors, than those treated with 10 mg/mL TPPPS. Specifically, the BLA and BLB1 levels in the 40 mg/mL TPPPS group were significantly ($P < 0.01$) higher than those in the 20 mg/mL TPPPS group, whereas no significant ($P > 0.05$) difference was observed between these 2 groups at 21 dpi.

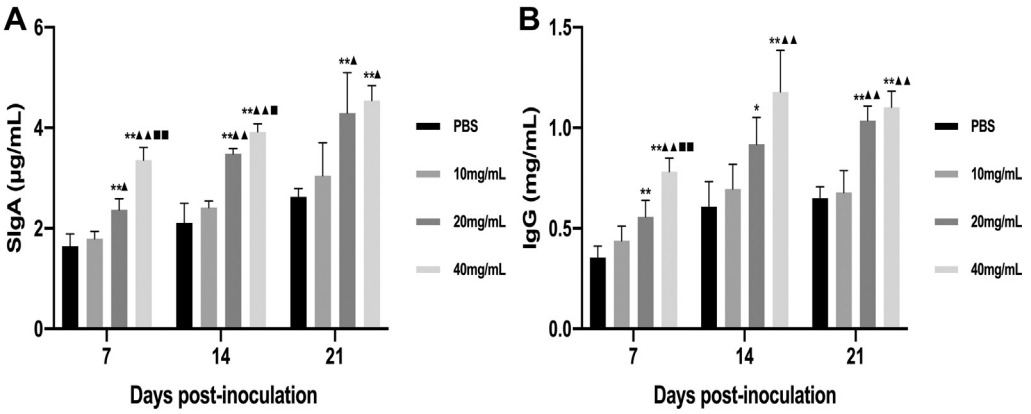

Figure 2. Mucosal levels of antibodies at different time points. (A) Total SIgA (n = 5/group) in feces at 7, 14, and 21 d after inoculation was assessed by ELISA. (B) Total IgG in serum was measured by ELISA. Bars represent the means ± SD for individual group (n = 5). "*Represents the comparison with the PBS group; ▲ and ■ represent the comparisons with the 10 mg/mL TPPPS group and 20 mg/mL TPPPS group, respectively. One significance symbol represents $P < 0.05$, and double symbols represent $P < 0.01$. All values are shown as means ± SD. Abbreviations: SIgA, secretory IgA; TPPPS, Taishan *Pinus massoniana* pollen polysaccharides.

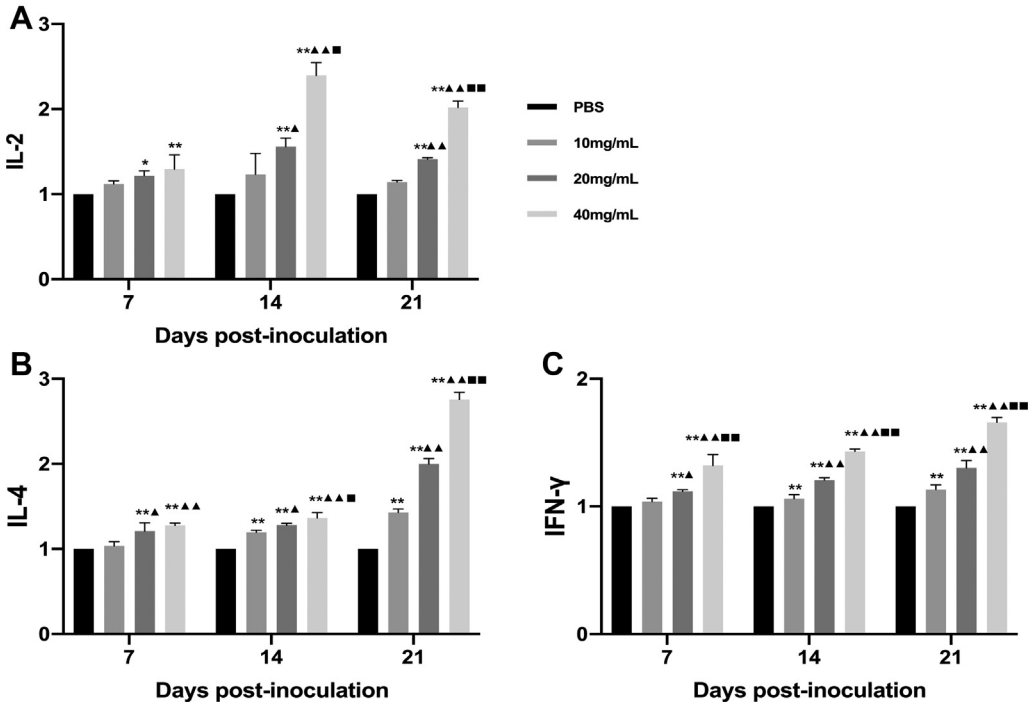

Figure 3. Changes of cytokines in chickens. Chickens were orally administered with 10 mg/mL TPPPS, 20 mg/mL TPPPS, 40 mg/mL TPPPS, and PBS in individual group. Intestinal tissues were collected at 7, 14, and 21 d after inoculation. IL-2 (A), IL-4 (B), and IFN-γ (C) levels were quantified by real-time PCR. "*Represents the comparison with the PBS group; ▲ and ■ represent the comparisons with the 10 mg/mL TPPPS group and 20 mg/mL TPPPS group, respectively. One significance symbol represents statistical significant at $P < 0.05$, and double symbols represent $P < 0.01$. All values are shown as means ± SD. Abbreviations: IFN-γ, interferon gamma; TPPPS, Taishan *Pinus massoniana* pollen polysaccharides.

Cell-Mediated Immune Response

The percentage of $CD4^+$ and $CD8^+$ T cells directly reflects the entire immune functions of animals (Torti et al., 2012). The statistical analysis results of $CD4^+$ and $CD8^+$ T lymphocytes in peripheral blood are shown in Tables 2 and 3, respectively. The levels of $CD4^+$ and $CD8^+$ in the 20 and 40 mg/mL TPPPS groups were significantly higher than those in the PBS and 10 mg/mL TPPPS groups at 7 dpi ($P < 0.05$). Furthermore, the percentages of $CD8^+$ in the 40 mg/mL TPPPS group were significantly higher than those in other groups at 14 dpi ($P < 0.05$); however, the percentages of $CD4^+$ in the 40 mg/mL TPPPS group were higher than those in the 20 mg/mL TPPPS group, and the difference was insignificant ($P > 0.05$). Similarly, the percentages of $CD4^+$ and $CD8^+$ T lymphocytes in the 20 and 40 mg/mL TPPPS groups did not show a difference at 21dpi, which were higher than those in other 2 groups ($P < 0.05$).

Measurement of Villi Length, Width, Crypt Depth, and V/C Value

To verify the benefits of polysaccharides on intestinal villi, we measured the length, width, crypt depth, and V/C value of the duodenum, jejunum, and ileum. At 21 dpi, the villi length of the chickens in the 20 and 40 mg/mL TPPPS groups were significantly ($P < 0.01$) higher than those in the other 2 groups, whereas 10 mg/mL TPPPS treatment failed ($P > 0.05$) to stimulate the villi length. The duodenal and ileal crypt depths of the chickens in the 40 mg/mL TPPPS group were significantly ($P < 0.05$ and $P < 0.01$, respectively) higher than those in the PBS group. The villi width of the chickens in the 40 mg/mL TPPPS group was significantly ($P < 0.01$) higher than that in the 10 mg/mL TPPPS or PBS group. Moreover, the width of jejunal and ileal villi in the 20 mg/mL TPPPS group was also significantly ($P < 0.01$) higher than that in the 10 mg/mL TPPPS group (Figures 5). In addition, the V/C values across different groups are shown in Table 4. The V/C values of the chickens in the 20 and 40 mg/mL TPPPS groups were significantly ($P < 0.01$) higher than those in the other 2 groups, whereas no significant ($P > 0.05$) difference was observed between jejunal and ileal V/C values.

Protective Effects of TPPPS Treatment on NDV

To evaluate the anti-NDV effect of TPPPS, the changes in chicken BW and percent survival of the chickens in each group after NDV challenge were statistically analyzed. We found that the BW of all the chickens was continuously decreased. Although no significant difference was observed between the 20 and 40 mg/mL TPPPS groups, the chicken BW in these 2 groups was significantly ($P < 0.01$) higher than that in the other 2 groups (Figure 6A). In addition, we also detected that the percent survival rates of the chickens in both the PBS and 10 mg/mL TPPPS groups were

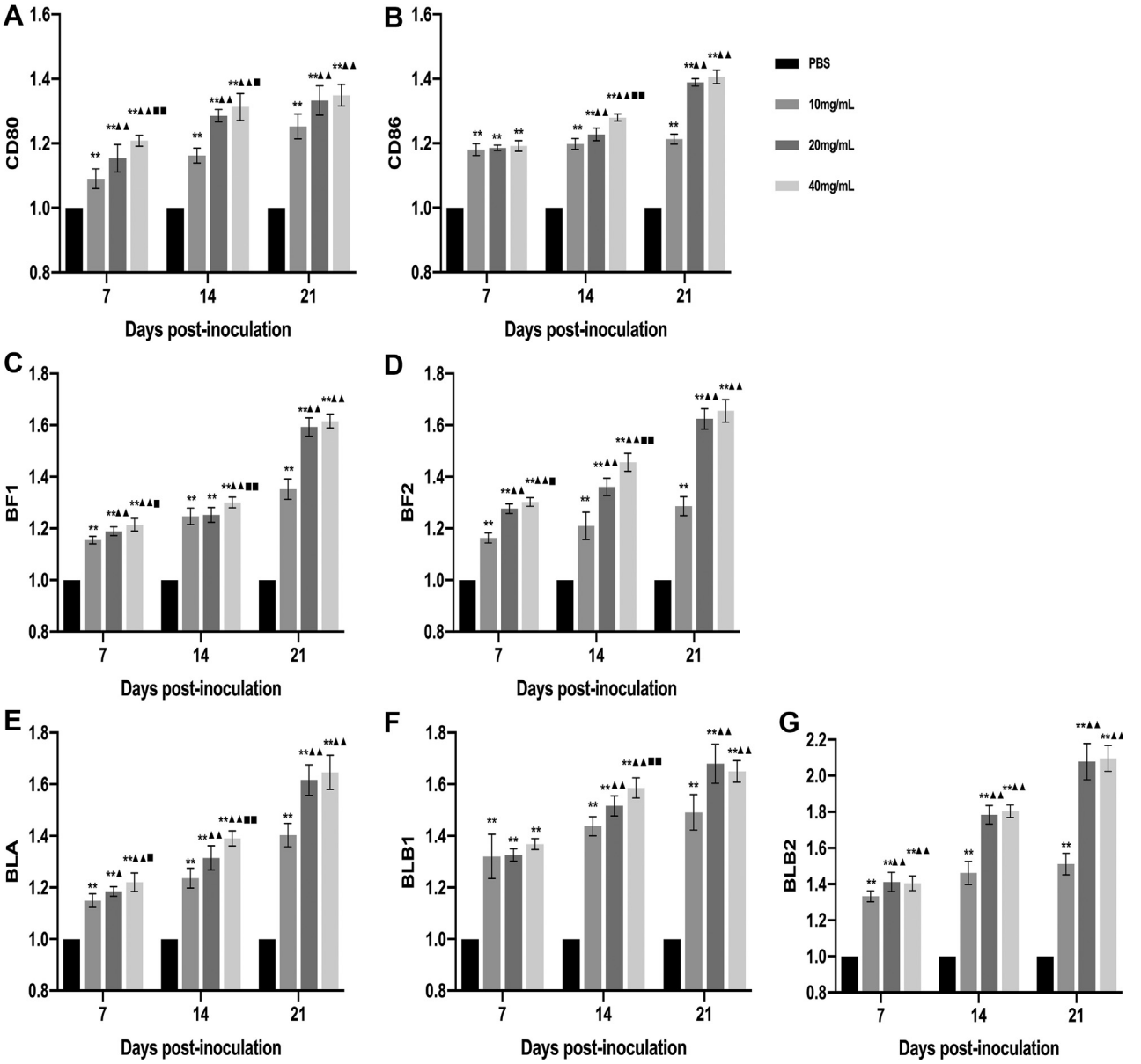

Figure 4. Changes of mucosal immune-related factor in chickens. Chickens were orally administered with 10 mg/mL TPPPS, 20 mg/mL TPPPS, 40 mg/mL TPPPS, and PBS in individual group. Intestinal tissues were collected at 7, 14 and 21 d after inoculation. CD80 (A), CD86 (B), BF1 (C), BF2 (D), BLA (E), BLB1 (F), and BLB2 (G) were quantified by real-time PCR. "*Represents the comparison with the PBS group; ▲ and ■ represent the comparisons with the 10 mg/mL TPPPS group and 20 mg/mL TPPPS group, respectively. One significance symbol represents statistical significant at $P < 0.05$, and double symbols represent $P < 0.01$. All values are shown as means ± SD. Abbreviation: TPPPS, Taishan *Pinus massoniana* pollen polysaccharides.

0 at seventh day after challenge (Figure 6B). Viral copies detected from intestinal tissues of each group after challenge were shown in Figure 6C. Viral loads of the PBS and 10 mg/mL TPPPS groups were higher ($P < 0.01$) than those of the 20 and 40 mg/mL TPPPS groups. However, there was no significant difference between

Table 2. Changes of $CD4^+$ T lymphocyte counts in the peripheral blood.

	Days after inoculation[1]			
Group	0	7	14	21
PBS	18.38 ± 0.47	18.95 ± 0.41[b]	20.28 ± 0.44[c]	22.67 ± 0.52[c]
TPPPS (10 mg/mL)	17.87 ± 0.31	19.87 ± 0.45[b]	21.80 ± 0.91[b]	24.73 ± 0.75[b]
TPPPS (20 mg/mL)	17.77 ± 0.30	22.73 ± 0.67[a]	25.58 ± 0.36[a]	29.37 ± 0.44[a]
TPPPS (40 mg/mL)	17.82 ± 0.82	22.78 ± 0.75[a]	26.20 ± 0.38[a]	29.14 ± 0.25[a]

Abbreviation: TPPPS, Taishan *Pinus massoniana* pollen polysaccharides.

[1]Different lowercase letters in the same column represent significant differences at the same dpi ($P < 0.05$). Data are expressed as percentage ± SD.

Table 3. Changes of $CD8^+$ T lymphocyte counts in the peripheral blood.

Group	Days after inoculation[1]			
	0	7	14	21
PBS	11.51 ± 0.22	12.60 ± 0.15[b]	12.83 ± 0.17[d]	13.19 ± 0.20[c]
TPPPS (10 mg/mL)	11.58 ± 0.41	12.91 ± 0.53[b]	13.64 ± 0.35[c]	14.65 ± 0.34[b]
TPPPS (20 mg/mL)	12.01 ± 0.13	13.68 ± 0.27[a]	14.25 ± 0.22[b]	15.79 ± 0.29[a]
TPPPS (40 mg/mL)	11.71 ± 0.21	13.64 ± 0.14[a]	15.02 ± 0.40[a]	15.93 ± 0.27[a]

Abbreviation: TPPPS, Taishan *Pinus massoniana* pollen polysaccharides.
[1]Different lowercase letters in the same column represent significant differences at the same dpi ($P < 0.05$). Data are expressed as percentage ± SD.

the first 2 groups and so did the latter 2 groups ($P > 0.05$).

Histopathologic Observation of Intestines

To further confirm the antiviral effect of TPPPS, we evaluated and compared the pathologic changes of the intestinal sections in all chicken groups (Figures 7A–O). We observed no obvious intestinal lesion or severe change of individual villi structure in the 20 and 40 mg/mL TPPPS groups and the mock group, whereas the uniformity and integrity of intestinal villi of the chickens in the other 2 groups were compromised, showing both sparse villi and swollen mucosa. In comparison with the severely damaged jejunal villi of the chickens in the PBS group, the intestinal villi of the chickens in the 10 mg/mL TPPPS group were moderately damaged or shortened, and the mucosa and submucosa were also mildly affected.

DISCUSSION

Recently, biomedicinal studies have been carried out on various polysaccharides isolated from plant sources. These polysaccharides possess unlimited medical potential owing to their various biological activities. The identification of more plant-source polysaccharides has a great significance for the improvement of animal immunity. Masson pine pollen was recognized thousands of years ago in China and being as an excellent bioactive substance for immune function improvement. Currently, masson pine pollen is being produced at an industry scale (in China). Taishan *Pinus massoniana* pine pollen polysaccharides extracted from masson pine pollen might have a broad application prospect as a high-performance immune enhancer. Previously, we have demonstrated that TPPPS is composed of 3 polysaccharides (i.e., TPPPS 1–3) and that each polysaccharide component is composed of different monosaccharides, serving as both antioxidants and antiviral agents. Meanwhile, TPPPS has a synergistic effect in promoting immune functions in animals (Yang et al., 2015). In this study, we further verified the bioactive roles of TPPPS in promoting intestinal immune functions.

Intestinal mucosa, as an integral and essential part of the animal body, constitutes an independent immune system and a unique structure and function. It actively participates in combating viral infections and preventing the gastrointestinal tract of animals from invasion by pathogenic microbes. Physical barriers and mucosal immunity are at the first line of defense against microbial infections. The Ig SIgA is an important component of mucosal immunity (Wang et al., 2012), which can form a protective barrier by adhering to the epithelial cells or interfere with the assembly of viral particles by adhering to the newly synthesized viral proteins in the infected cells. The protective potential of SIgA is attributed to its polymerization properties, which results in a higher affinity with viruses and prevents their adhesion onto the epithelial cells. Our results indicate that the extracted TPPPS can induce large amounts of SIgA. Moreover, TPPPS promoted cellular response and we also detected an upregulation of IL-2, IL-4, and

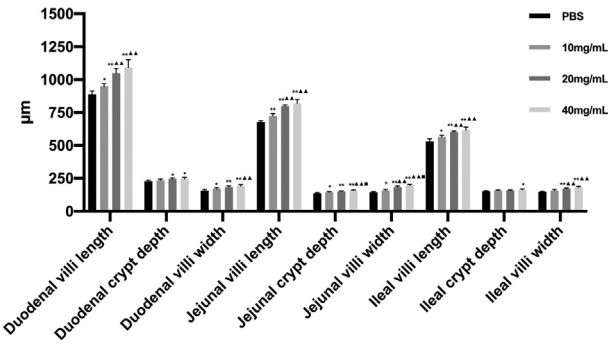

Figure 5. Measurements of villi length, width, crypt depth, and villi length/crypt depth (V/C) value. Intestinal tissues were collected at 21 d after inoculationfor the measurement of villi length, width, crypt depth, and V/C value of the duodenum, jejunum, and ileum . "*Represents the comparison with the PBS group; ▲ and ■ represent the comparisons with the 10 mg/mL TPPPS group and 20 mg/mL TPPPS group, respectively. One significance symbol represents statistical significant at $P < 0.05$, and double symbols represent $P < 0.01$. All values are expressed as means ± SD. Abbreviation: TPPPS, Taishan *Pinus massoniana* pollen polysaccharides.

Table 4. Effects of TPPPS on the V/C values of intestinal villi.

Group	V/C[1]		
	Duodenum	Jejunum	Ileum
PBS	3.87 ± 0.06[c]	4.94 ± 0.14[b]	3.48 ± 0.20[b]
TPPPS (10 mg/mL)	4.05 ± 0.25[c]	4.98 ± 0.11[b]	3.54 ± 0.13[b]
TPPPS (20 mg/mL)	4.28 ± 0.04[b]	5.30 ± 0.12[a]	3.77 ± 0.04[a]
TPPPS (40 mg/mL)	4.44 ± 0.34[a]	5.15 ± 0.15[a]	3.78 ± 0.27[a]

Abbreviations: TPPPS, Taishan *Pinus massoniana* pollen polysaccharides; V/C, villi length/crypt depth.
[1]Different lowercase letters in the same column represent significant differences at 21 dpi ($P < 0.05$). Data are expressed as percentage ± SD.

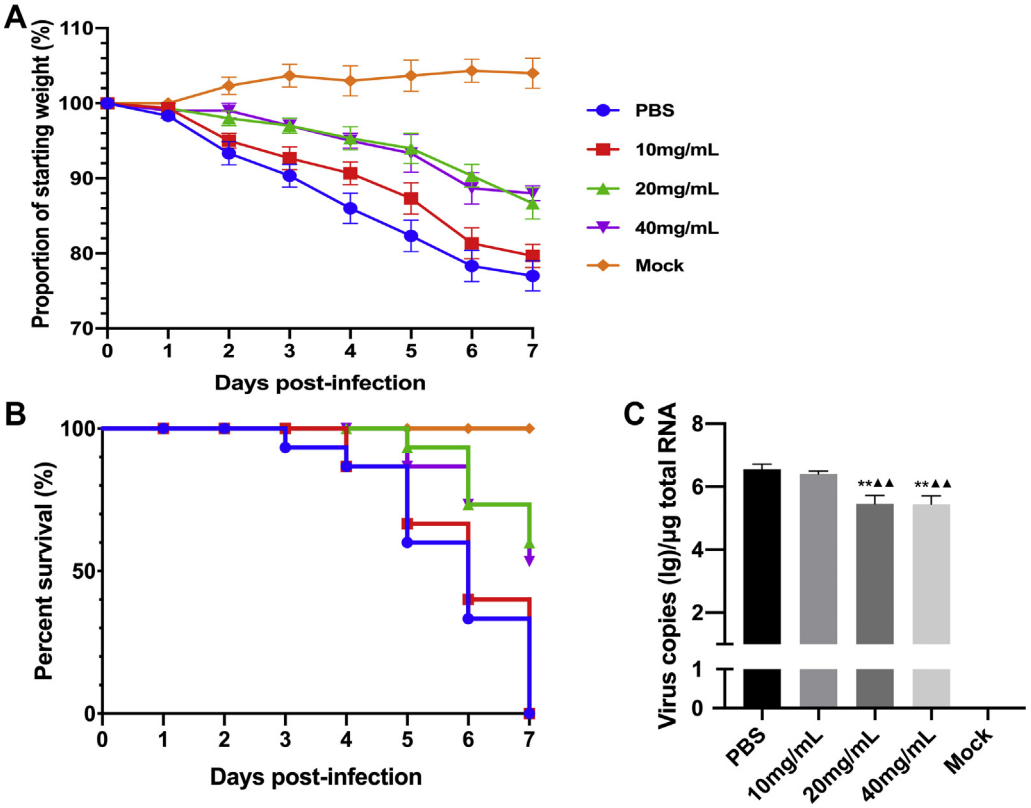

Figure 6. Effect of TPPPS against NDV challenge. Chickens in groups were orally administered for 21 d with 10 mg/mL TPPPS, 20 mg/mL TPPPS, 40 mg/mL TPPPS, and PBS (0.2 mL/chicken) in individual group. And, the chickens were infected with 10^6 $TCID_{50}$ of NDV through nasal inoculation. Noninfected chickens treated with PBS served as a mock group. (A) Chicken weight loss (%) after challenged with NDV. (B) The percent survival of chickens in each individual group within 7 d after challenge (n = 15). (C) Normalized NDV copies (lg) per 1 μg total RNA in the intestinal issues of experimentally infected chickens collected after 7-d challenge. Bars represent means ± SD for individual groups. "*Represents the comparison with the PBS group; ▲ represent the comparisons with the 10 mg/mL TPPPS group, and double symbols represent $P < 0.01$. All values are expressed as means ± SD. Abbreviations: NDV, Newcastle disease virus; $TCID_{50}$, 10^6 median tissue culture infective dose; TPPPS, Taishan *Pinus massoniana* pollen polysaccharides.

interferon gamma cytokines, which is consistent with the results that *Astragalus* polysaccharides can activate immune cells and increase the secretion of cytokines (Jiang et al., 2010). Another recent finding is that IL are the key molecules involved in MHC pathways in chickens and indicate the importance of MHC in immune function (Truong et al., 2020). Therefore, we also evaluated the effects of different doses of TPPPS on MHC-I genes (BF1 and BF2) and MHC-II genes (BLA, BLB1, and BLB2). Our results revealed that the gene expression levels of MHC increased with the increase of polysaccharide concentration, but finally at 21 dpi, there was no significant difference between the 20 mg/mL and 40 mg/mL groups. It showed that the effects of TPPPS on MHC-I and MHC-II gene expression did not increase in a dose-dependent manner. And, molecules called activation markers induced by cell stimulation are closely related to immune function (Feng et al., 2008), such as the gene levels of CD80 and CD86 molecules in this study which presented the same trend as MHC genes. In addition, the aforementioned upregulation of MHC-II can promote the presentation of foreign antigen to $CD4^+$ T cells by antigen-presenting cells to drive the activation of naive T cells. The present study demonstrated that TPPPS significantly promote the conversion rate of the $CD4^+$ and $CD8^+$ T lymphocytes. Together, our results of immunologic indicators clarified the positive effect of TPPPS on mucosal immunity.

The gastrointestinal tract, especially the small intestine, is the main site of chemical digestion in the poultry gut. It is also an important site for various nutrient absorption and transportation to the bloodstream. The structure and condition of intestinal villi reflect the overall health condition of the intestine. The length, width, crypt depth, and V/C value of intestinal villi are important indicators reflecting their growth, development, and the resistance to bacterial infections (Lu et al., 2016). The length and width of intestinal villi, which increase along with the development of the villi, directly determine their contact area with pathogens. Villi crypt depth reflects the formation rate of intestinal epithelial cells. The decreased depth and the shallow crypt of the villi indicate an increasing maturation rate of the small intestinal cells, and the cells continue to migrate and differentiate from the base of the crypt toward the end of the villi, thereby enhancing nutrient absorption. The V/C value can fully reflect the overall condition of intestinal villi and indicate changes in intestinal functions that affect the growth and development of animal bodies. The results of this study showed that TPPPS

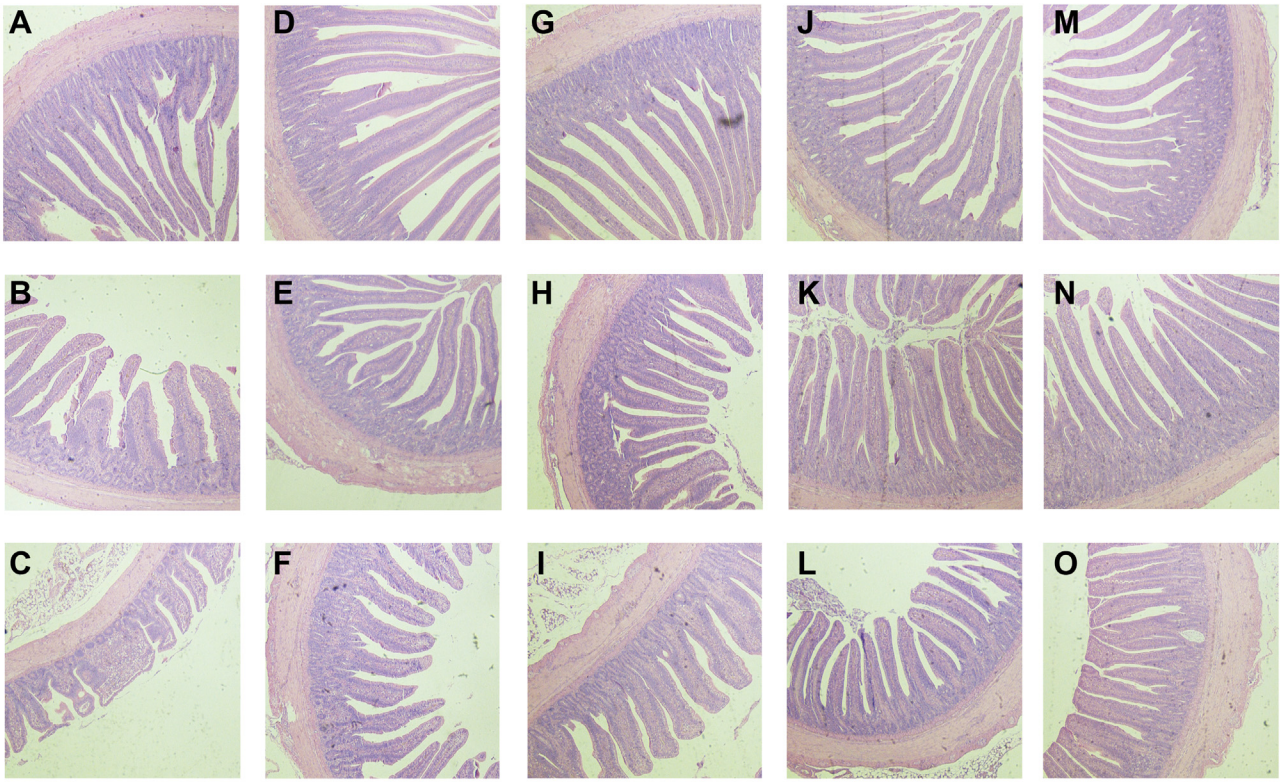

Figure 7. Effect of TPPPS against intestinal injury induced by NDV infection. (A–C) PBS, (D–F) 10 mg/mL TPPPS, (G–I) 20 mg/mL TPPPS, (J–L) 40 mg/mL TPPPS, (M–O) mock. Intestinal tissues were collected from each individual group 7 d after NDV challenge for H&E staining and histopathologic analysis. Abbreviations: H&E, hematoxylin and eosin; NDV, Newcastle disease virus; $TCID_{50}$, 10^6 median tissue culture infective dose; TPPPS, Taishan *Pinus massoniana* pollen polysaccharides.

intervention with different doses from 10 to 40 mg/mL can effectively promote the healthy development and growth of chicken intestinal villi. However, only few significant differences were found between 20 and 40 mg/mL TPPPS treatments, indicating that the immune-stimulatory effect of TPPPS does not always increase in a dose-dependent manner.

Our previous research has shown that TPPPS can effectively inhibit the infections of several animal viruses, including the infectious bursal disease virus (Wang et al., 2018), avian leukosis virus subgroup B (Yang et al., 2015), and avian leukosis virus subgroup J (Wang et al., 2019b; Yu et al., 2017). In this study, we selected the NDV that has a greater impact on the intestinal mucosa as the infectious agent to examine the protective effect of TPPPS on the mucosa. Taishan *Pinus massoniana* pine pollen polysaccharides can significantly reduce the weight loss and histopathologic damage, as well as improve the immune functions in the chickens with NDV challenge. One of the possible antiviral mechanisms of TPPPS is through activating innate immunity of the chickens to protect them from potential NDV infection, similar to the mechanism by which *Astragalus* polysaccharides exhibit antiviral activities (Kallon et al., 2013). Another potential mechanism is through enhancing the capability of intestinal mucosa in resisting viral invasion and strengthening the intestinal mucosal barrier. Our findings on TPPPS establish the foundation for future development of this novel effective immune enhancer, which possesses regulatory and stimulatory effects on intestinal mucosa, for improving intestinal mucosal immunity and preventing or treating immunosuppressive diseases.

In summary, the ingestion of TPPPS by animals can promote their intestinal epithelial cell renewal, improve the intestinal mucosal barrier, activate intestinal mucosal immune system, and enhance the overall immune functions. Based on its regulatory effects on gut intestinal health, TPPPS may possess a substantial value to be applied in animal husbandry and production. Considering the current trend of antibiotic-free farming, the application of TPPPS can provide an alternative and effective strategy to improve the intestinal immune functions of poultry.

ACKNOWLEDGMENTS

This project was supported by National Science Foundation of China (3177130834), The National Key Research and Development Program of China (2017YFD0500706).

DISCLOSURES

The authors declare that there is no conflict of interest.

REFERENCES

Deng, H., H. Yang, Y. Jiang, G. Chen, S. Wang, Z. Zhou, H. Liang, and Y. Lu. 2018. Regulatory effects of yupingfeng polysaccharides on intestinal mucosal immune response and immune injury in mice. Chin. J. Vet. Drug 52:47–52.

Fan, Y., Y. Hu, D. Wang, Z. Guo, X. Zhao, L. Guo, B. Zhao, J. Zhang, Y. Wang, and T. L. Nguyen. 2010. Epimedium polysaccharide and propolis flavone can synergistically stimulate lymphocyte proliferation in *vitro* and enhance the immune responses to ND vaccine in chickens. Int. J. Biol. Macromol. 47:87–92.

Feng, H., J. Fan, X. Du, Z. Song, and J. Liu. 2015. Sulfated radix cyathulae officinalis polysaccharides act as adjuvant via promoting the dendritic cell maturation and suppressing treg frequency. Immunol. Invest. 44:288–308.

Feng, X., N. Liu, S. Yang, L. Hu, X. Chen, Z. Fang, Q. Ren, S. Lu, B. Liu, and Z. Han. 2008. Regulation of the class II and class I MHC pathways in human THP-1 monocytic cells by interleukin-27. Biochem. Biophys. Res. Commun. 367:553–559.

He, X. Y., X. Y. Sun, and Z. Y. Yu. 2007. Effective components and pharmacological function of pine pollen. J. Northeast For. Univ. 35:78–80.

Huang, F., R. Zhang, J. X. Yang Liu, L. Liu, Z. Wei, Y. Yi, M. Zhang, and D. Liu. 2016. Dietary litchi pulp polysaccharides could enhance immunomodulatory and antioxidant effects in mice. Int. J. Biol. Macromol. 92:1067–1073.

Jiang, J., C. Wu, H. Gao, J. Song, and H. Li. 2010. Effects of astragalus polysaccharides on immunologic function of erythrocyte in chickens infected with infectious bursa disease virus. Vaccine 28:5614–5616.

Kallon, S., X. Li, J. Ji, C. Chen, Q. Xi, S. Chang, C. Xue, J. Ma, Q. Xie, and Y. Zhang. 2013. Astragalus polysaccharide enhances immunity and inhibits H9N2 avian influenza virus in *vitro* and in *vivo*. J. Anim. Sci. Biotechnol. 4:325–335.

Kong, X., Y. Hu, R. Rui, D. Wang, and X. Li. 2004. Effects of Chinese herbal medicinal ingredients on peripheral lymphocyte proliferation and serum antibody titer after vaccination in chicken. Int. Immunopharmacol. 4:975–982.

Kong, X. F., Y. L. Hu, Y. L. Yin, G. Y. Wu, and C. B. Yang. 2006. Chinese herbal ingredients are effective immune stimulators for chickens infected with the Newcastle disease virus. Poult. Sci. 85:2169–2175.

Li, S., X. F. Wang, L. N. Ren, J. L. Li, X. D. Zhu, T. Xing, L. Zhang, F. Gao, and G. H. Zhou. 2019. Protective effects of γ-irradiated astragalus polysaccharides on intestinal development and mucosal immune function of immunosuppressed broilers. Poult. Sci. 98:6400–6410.

Licciardi, P. V., and J. R. J. I. I. Underwood. 2011. Plant-derived medicines: a novel class of immunological adjuvants. Int. Immunopharmacol. 11:390–398.

Ling, Y., S. Li, J. Yang, J. Yuan, and C. He. 2011. Co-administration of the polysaccharide of Lycium barbarum with DNA vaccine of Chlamydophila abortus augments protection. Immunol. Invest. 40:1–13.

Liu, L., X. Zhao, Y. Liu, H. Zhao, and F. Li. 2019. Dietary addition of garlic straw improved the intestinal barrier in rabbits. J. Anim. Sci. 97:4248–4255.

Lu, X., X. Wang, G. Zheng, S. Li, Z. Sha, Z. Li, Z. Bu, H. Cheng, and X. Wang. 2016. Effect of Saccharomyces cerevisiae and EtpA gene-engineering S. cerevisiae on intestinal mucosal structure in rats. Anim. Husbandry Vet. Med. 48:1–6.

Nochi, T., C. A. Jansen, M. Toyomizu, and W. E. Van. 2018. The well-developed mucosal immune systems of birds and mammals allow for similar approaches of mucosal vaccination in both types of animals. Front. Nutr. 5:60.

Pfaffl, M. W. 2001. A new mathematical model for relative quantification in real-time RT-PCR. Nucleic Acids Res. 29:e45.

Sha, Z., H. Shang, Y. Miao, J. Huang, and R. Zhu. 2020. Recombinant *Lactococcus lactis* expressing M1-HA2 fusion protein provides protective mucosal immunity against H9N2 avian influenza virus in chickens. Front. Vet. Sci. 7:153.

Torti, C., M. Prosperi, D. Motta, S. Digiambenedetto, F. Maggiolo, G. Paraninfo, D. Ripamonti, G. Cologni, M. Fabbiani, and S. L. Caputo. 2012. Factors influencing the normalization of CD4+ T-cell count, percentage and CD4+/CD8+ T-cell ratio in HIV-infected patients on long-term suppressive antiretroviral therapy. Clin. Microbiol. Infect. 18:449–458.

Truong, A. D., Y. Hong, V. D. Ly, H. T. Nguyen, C. T. Nguyen, H. T. Vu, N. T. Chu, T. V. Hoang, H. T. T. Tran, H. V. Dang, and Y. H. Hong. 2020. Interleukin-dependent modulation of the expression of MHC class I and MHC class II genes in chicken HD11 cells. Dev. Comp. Immunol. 110:103729.

Ung, C. Y., H. Li, C. Y. Kong, J. F. Wang, and Y. Z. Chen. 2007. Usefulness of traditionally defined herbal properties for distinguishing prescriptions of traditional Chinese medicine from non-prescription recipes. J. Ethnopharmacol. 109:21–28.

Wang, Q., Y. Miao, Y. Xu, X. Meng, and R. Zhu. 2019b. Taishan pinus massoniana pollen polysaccharide inhibits the replication of acute tumorigenic ALV-J and its associated tumor growth. Vet. Microbiol. 236:108376.

Wang, J., B. Wang, H. Du, H. Zhang, H. Li, F. Wang, and X. Zhao. 2019a. Effects of diutina rugosa SD-17 on growth performance, intestine morphology, and immune status of chickens. Poult. Sci. 8:6311–6318.

Wang, C., Y. Wang, M. Ren, H. Chang, S. He, and G. Zhang. 2020. Adobe Photoshop combined with digimizer software for endoscopic submucosal dissection specimen measurement and restoration. J. Xi'an Jiaotong Univ. (Med. Sci.) 41:124–127.

Wang, S., K. Wei, H. Huang, H. Zhang, H. Wang, L. Ma, J. Zhang, H. Wang, and R. Zhu. 2018. The mechanism of resistance tovery virulent infectious bursal disease virus by Taishan pinus masoniana polen polysacharide in *vitro*. Chin. J. Vet. Sci. 38:1670–1676.

Wang, Q., B. Zhang, S. Wang, L. Zhang, and J. Tan. 2012. Impact of glutamine on the expression of sIgA of the intestinal mucosal barrier on the acute global cerebral ischemia-reperfusion injury in rats. Chin. J. Pract. Nerv. Dis. 15:6–9.

Wei, K., Z. Sun, Z. Yan, Y. Tan, H. wang, X. Zhu, X. Wang, P. Sheng, and R. Zhu. 2011. Effects of Taishan pinus massoniana pollen polysaccharide on immune response of rabbit haemorrhagic disease tissue inactivated vaccine and on production performance of rex rabbits. Vaccine 29:2530–2536.

Wu, Y., H. Jiang, E. Zhu, J. Li, Q. Wang, W. Zhou, T. Qin, X. Wu, B. Wu, and Y. Huang. 2017. Hericium erinaceus polysaccharide facilitates restoration of injured intestinal mucosal immunity in Muscovy duck reovirus-infected Muscovy ducklings. Int. J. Biol. Macromol. 107:1151–1161.

Yang, S., K. Wei, F. Jia, X. Zhao, G. Cui, F. Guo, and R. Zhu. 2015. Characterization and biological activity of Taishan pinus massoniana pollen polysaccharide in *vitro*. PLoS One 10:e0115638.

Yu, C., K. Wei, L. Liu, S. Yang, L. Hu, P. Zhao, X. Meng, M. Shao, C. Wang, L. Zhu, H. Zhang, Y. Li, and R. Zhu. 2017. Taishan pinus massoniana pollen polysaccharide inhibits subgroup J avian leucosis virus infection by directly blocking virus infection and improving immunity. Sci. Rep. 7:44353.

Zhang, Y., T. Cheng, Y. Cai, Q. Yuan, C. Liu, T. Zhang, D. Xia, R. Li, L. Yang, Y. Wang, A. E. T. Yeo, J. W.-K. Shih, J. Zhang, and N. Xia. 2010. RNA Interference inhibits hepatitis B virus of different genotypes in *vitro* and in *vivo*. BMC Microbiol. 10:214.

Zhao, X., J. Yang, Z. Ju, J. Wu, L. Wang, H. Lin, and S. Sun. 2020. Clostridium butyricum ameliorates salmonella enteritis induced inflammation by enhancing and improving immunity of the intestinal epithelial barrier at the intestinal mucosal level. Front. Microbiol. 11:299.

Zhou, L., S. Huang, X. Luo, and Y. Su. 2019. Advances in intestinal mucosal immunity provides an opportunity for traditional Chinese medicine immunity research. Chin. J. Immunol. 35:2945–2952.