Alberto Sicilia
Susana Cuesta
Gerardo Coma
Ignacio Arregui
Cristina Guisasola
Eduardo Ruiz
Antonio Maestro

Titanium allergy in dental implant patients: a clinical study on 1500 consecutive patients

Authors' affiliations:
Alberto Sicilia, Cristina Guisasola, Eduardo Ruiz, Clinica Sicilia, Oviedo, Spain
Alberto Sicilia, Susana Cuesta, Eduardo Ruiz, Section of Periodontology, Department of Surgery, University of Oviedo, Oviedo, Spain
Gerardo Coma, Allergologic Center, Oviedo, Spain
Ignacio Arregui, Private practice, Leon, Spain
Antonio Maestro, FREMAP, Gijón, Spain

Correspondence to:
Prof. Dr Alberto Sicilia
Clínica Sicilia
Uría 5
Oviedo 33003
Spain
Tel.: +34 985253622
Fax: +34 985270532
e-mail: asicilia@clinicasicilia.com

Key words: cutaneous tests, dental implants, epicutaneous tests, titanium allergy

Abstract

Background: In dentistry, allergic reactions to Ti implants have not been studied, nor considered by professionals. Placing permanent metal dental implants in allergic patients can provoke type IV or I reactions. Several symptoms have been described, from skin rashes and implant failure, to non-specific immune suppression.

Objective: Our objective was to evaluate the presence of titanium allergy by the anamnesis and examination of patients, together with the selective use of cutaneous and epicutaneous testing, in patients treated with or intending to receive dental implants of such material.

Material and methods: Thirty-five subjects out of 1500 implant patients treated and/or examined (2002–2004) were selected for Ti allergy analysis. Sixteen presented allergic symptoms after implant placement or unexplained implant failures [allergy compatible response group (ACRG)], while 19 had a history of other allergies, or were heavily Ti exposed during implant surgeries or had explained implant failures [predisposing factors group (PFG)]. Thirty-five controls were randomly selected (CG) in the Allergy Centre. Cutaneous and epicutaneous tests were carried out.

Results: Nine out of the 1500 patients displayed positive (+) reactions to Ti allergy tests (0.6%): eight in the ACRG (50%), one in the PFG (5.3%)($P = 0.009$) and zero in the control group. Five positives were unexplained implant failures (five out of eight).

Conclusions: Ti allergy can be detected in dental implant patients, even though its estimated prevalence is low (0.6%). A significantly higher risk of positive allergic reaction was found in patients showing post-op allergy compatible response (ACRG), in which cases allergy tests could be recommended.

Given its high resistance to corrosion in a physiological environment and the excellent biocompatibility that gives it a passive, stable oxide film, titanium is considered the material of choice for intraosseous use in the medical field (Smith et al. 1997; Sykaras et al. 2000; Frisken et al. 2002; Akagawa & Abe 2003). This metal has been somewhat surrounded by mysticism in the world of dentistry (Parr et al. 1985), to the extent that there is a general belief, biologically inexplicable, yet still shown in some publications (Hensten-Pettersen 1992; Basketter et al. 2000; El Salam El Askary 2003), that it cannot cause allergic reactions.

An allergic reaction, or hypersensitization, is defined as an excessive immune reaction that occurs when coming into contact with a known antigen (Roitt & Delves 2001). According to this, in order for titanium to provoke an allergic reaction

Date:
Accepted 19 November 2007

To cite this article:
Sicilia A, Cuesta S, Coma G, Arregui I, Guisasola C, Ruiz E, Maestro A. Titanium allergy in dental implant patients: a clinical study on 1500 consecutive patients. *Clin. Oral Impl. Res.* **19**, 2008; 823–835
doi: 10.1111/j.1600-0501.2008.01544.x

© 2008 The Authors. Journal compilation © 2008 Blackwell Munksgaard

it must have antigenic properties and must be in contact with the organism. First of all, we know that in their ionic form, metals can be bonded with native proteins to form haptenic antigens, or can trigger the degranulation of mastocytes and basophiles, being capable of developing type I or type IV hypersensitive reactions (Schramm & Pitto 2000; Hallab et al. 2001). Secondly, our external exposure, in this case to titanium, is massive. Its excellent properties and resistance to corrosion have extended its use into aerospace, chemical and nuclear industries, desalination plants, marine equipment, car manufacturing, sports, jewellery, home furnishings and the medical industry, used particularly in the field of orthopaedic and dental implants. However, 95% (Weighed 2002) of the global use of titanium is not in its metal form, but as titanium dioxide, for its whitening effect (in all kinds of paints and whitening agents), sunscreen properties and use as a safe excipient in the cosmetic, pharmaceutical and food industries. This exposure means our body usually has a titanium content of around 50 ppm (Parr et al. 1985).

Additionally, the insertion of titanium implants and their permanence in the human body can also cause internal exposure. It has been proven that titanium ions concentrate in tissues surrounding dental and orthopaedic implants, as well as in regional lymph nodes and pulmonary tissue. Concentrations of between 100 and 300 ppm have been discovered in peri-implant tissues, often accompanied by discolorations, which can be well tolerated (Parr et al. 1985; Abdallah et al. 1994; Torgersen et al. 1995, 1995b; Haug 1996; Matthew & Frame 1998b), or by type IV hypersensitivity reactions, with titanium particles inside the macrophage lysosomes (Mitchell et al. 1990; Lalor et al. 1991; Revell & Lalor 1995; Katou et al. 1996; Matthew & Frame 1998; Frisken et al. 2002).

In blood, given its poor solubility (Lalor et al. 1991; Bianco et al. 1996), no significant rise of titanium levels was detected after placing three dental implants in humans (Smith et al. 1997); however, a significant rise has been show in patients with a failed, loose titanium hip prosthesis compared with controls (Jacobs et al. 1991). In this area, patients with a metal-on-metal total joint replacement – both joint surfaces made from titanium – have shown an increase in friction-induced corrosion, with a consequent rise in the internal release of particles, which can lead to cell sensitization, granulomatous infiltration and osteolysis (Elves et al. 1975; Lalor et al. 1991; Witt & Swann 1991; Case et al. 1994; Revell & Lalor 1995). There are even authors who consider this type of prosthesis (metal-on-metal) a non-indicated device (Merritt & Brown 1996), and it is nowadays used with little frequency. Animal studies show an increased presence of titanium ions after placing dental implants, not only in peri-implant tissues (Brune 1986; Wennerberg et al. 2004), but also in the regional lymph nodes (by lymphatic transport) and in the lungs (the first capillary filter of blood passing through the venae cavae) (Brune 1986; Schliephake et al. 1993; Weingart et al. 1994; Frisken et al. 2002). In one of the studies, two implants failed, coming loose but with no infection, and in these particular patients a presence of titanium in the lungs was observed to be 2.2–3.8 times higher, and 7–9.4 times higher in the lymph nodes, which were enlarged (Frisken et al. 2002).

Hypersensitivity reaction to a metal comes from the presence of ions following ingestion, skin or mucosal contact, or from implant corrosion processes (Ahnlide et al. 2000; Hallab et al. 2001). These ions, although not sensitizers, form complexes with native proteins and act as allergens causing hypersensitivity reactions (Schramm & Pitto 2000; Hallab et al. 2001). Their clinical effects are difficult to assess due to their infrequent appearance and subtle symptoms (Hallab et al. 2001). In the case of titanium allergy, medical literature has described cases where it has mainly appeared as the fundamental cause of urticaria, eczema, oedema, redness and pruritus of the skin or mucosa, either localized, at distant sites, or generalized (Hensten-Pettersen 1992; Haug 1996; Lhotka et al. 1998; Thomas 2000; Tamai et al. 2001; Valentine-Thon & Schiwara 2003; Thomas et al. 2006). In special cases, allergic reactions have been associated with more serious problems such as atopic dermatitis (Tamai et al. 2001), impaired healing of fractures (Thomas et al. 2006), pain, necrosis and weakening of orthopaedic implants (Haug 1996) and tolerance phenomena (Thomas 2000). Non-specific immune suppression or overaggressive immune responses cannot be disregarded in particularly sensitive patients (Hallab et al. 2001). In the field of dental implants, the appearance of facial erythaema (Matthew & Frame 1998; Bircher & Stern 2001) and non-keratinized, oedematous, proliferative hyperplastic tissue (Mitchell et al. 1990) have been described.

Many of these investigations have been carried out with titanium orthopaedic implants; therefore it is not certain as to what extent the discoveries can be extrapolated to the oral cavity and dental implants. On the one hand, the intraosseus contact surface is smaller in dental implants than in orthopaedic ones (Brunski et al. 2000; Akagawa & Abe 2003), which may be particularly important considering that bone has a very low reactivity potential (Schramm & Pitto 2000). On the other hand, oral mucosa and the skin behave very differently from an immunological point of view, partially because of the influence of specific immune systems for each organ, such as skin-associated lymphoid tissue and mucosa-associated lymphoid tissue. A practical application is that, in mucosa, the number of Langerhans' cells, which act as antigen-presenting cells, is much smaller (Bass et al. 1993; Schramm & Pitto 2000; Thomas 2000). It is because of this, and perhaps also because of its reduced permeability, that oral mucosa must be exposed to allergen concentrations 5–12 times greater than the skin in order to cause tissular microscopic reactions. Moreover, contact between the metal and the host is hampered, as the implant and prosthetic structures in the oral cavity are coated with a layer of salivary glycoproteins, which act as a protective barrier (Bass et al. 1993).

The diagnosis of metal allergy is typically based on the patient's medical record, clinical findings and the results from epicutaneous tests (Bass et al. 1993; Kusy 2004). It has been described that people have a susceptibility to suffer from metal allergy – possibly genetically based (Thomas 2000) – as it has been observed that many patients can suffer from multiple allergies and that individuals with previous reactions to metals or jewellery have a greater risk of developing a hypersensitivity reaction to a metal implant (Hallab et al. 2001). In light of this, although the tita-

 © 2008 The Authors. Journal compilation © 2008 Blackwell Munksgaard

nium allergy has a low prevalence rate, for patients with a history of previous significant allergies, it may be particularly advisable to carry out a metal allergy assessment and specific allergy tests before placing permanent implants of such material (Cook et al. 1991; Tamai et al. 2001).

Results from epicutaneous tests are acceptable as proof of sensitivity to a specific allergen (Bass et al. 1993). This is considered a standard procedure (Thomas 2000) and is widely used to assess type IV hypersensitivity reactions to titanium (Lalor et al. 1991; Lhotka et al. 1998; Okamura et al. 1999; Ahnlide et al. 2000; Schramm & Pitto 2000; Yamauchi et al. 2000; Bircher & Stern 2001; Suhonen & Kanerva 2001; Kusy 2004; Thomas et al. 2006). These tests can also be used in combination with the intradermal inoculation of the antigen (Yamauchi et al. 2000) to assess type I hypersensitivity reaction. Tests based on the use of patient blood samples have also been used, the most common being the lymphocyte transformation test (Carando et al. 1985; Cook et al. 1991; Torgersen et al. 1993; Yamauchi et al. 2000; Hallab et al. 2001; Valentine-Thon & Schiwara 2003; Thomas et al. 2006), the memory lymphocyte immunostimulation assay (MELISA) (Valentine-Thon & Schiwara 2003) and the lymphocyte migration inhibition test (LMI or LIF) (Cook et al. 1991; Merritt & Rodrigo 1996b; Hallab et al. 2001). Finally, histological studies have also been carried out on peri-implant tissues (Mitchell et al. 1990; Torgersen et al. 1995b; Thewes et al. 2001), the use of which is restricted to cases in which an implant is surgically removed, simultaneously taking a sample of the surrounding tissue, or soft tissue biopsy. Anecdotally, alternative assessments have also been carried out, such as the Bi-Digital O-ring test (Tamai et al. 2001).

Scientific evidence on the clinical features of a metal allergy is based on cohort studies, case series and isolated clinical cases. It is estimated that cutaneous hypersensitivity to metals fluctuates between 10% and 15% (Hallab et al. 2001). There are no epidemiological studies on the prevalence rate of titanium allergy in the general population, although the fact that external exposure to titanium is so important, and that related pathology is scarce, makes one suspect it to be low (Lalor et al. 1991). Studies performed with epicutaneous tests show a percentage of Ti-sensitive individuals between 1% and 3% (Lhotka et al. 1998; Okamura et al. 1999); one study with the LMI test reached 4% (Merritt & Rodrigo 1996b), while those performed with the MELISA test fluctuated between 1.5% and 28%, with authors indicating that the most recent studies have shown an increase in sensitizations (Valentine-Thon & Schiwara 2003). Titanium allergy has been described in deodorant and cosmetics users (Basketter et al. 2000; Tamai et al. 2001), after local reactions to pacemakers (Peters et al. 1984; Verbov 1985; Buchet et al. 1992; Abdallah et al. 1994; Yamauchi et al. 2000; Akaki & Dekio 2002), in patients with bronchopulmonary pathology through exposure to titanium powder (Redline et al. 1986; Shirakawa et al. 1989; Nemery 1990; Breton et al. 1992; Bircher & Stern 2001), in monitored hip prosthesis patients (Merritt & Rodrigo 1996b), in failed hip and knee prostheses (Cook et al. 1991; Lalor et al. 1991) and in patients with titanium plate osteosynthesis (Matthew & Frame 1998; Thomas et al. 2006). In the maxillofacial area, titanium allergy has been described in patients with miniplates to treat mandibular fractures (Katou et al. 1996), with few and inaccurate references to titanium-allergenic processes in patients with dental implants (Mitchell et al. 1990; Matthew & Frame 1998; Bircher & Stern 2001).

There is a complex relation between the failure of a metal implant and allergy to its components. A greater concentration of titanium ions in the regional nodes and in pulmonary tissue in specimens with failed implants has been described in an animal study (Frisken et al. 2002), and a greater blood concentration of titanium has been described in patients with failed loose hip prostheses (Jacobs et al. 1991; Witt & Swann 1991). Several studies show a greater sensitization to titanium in patients with a failed titanium orthopaedic prosthesis than in those with successful prostheses (Cook et al. 1991; Lalor et al. 1991), which coincides with findings from classic cohort studies in patients with metal implants: a prevalence of metal allergy six times greater in patients with failed orthopaedic implants than in the general population (Hallab et al. 2001). Furthermore, it has been observed that the percentage of sensitizations to metals used in orthopaedic prostheses that failed without explanation (not including fractures and infections) was 74%, against 17% in the control group, made up of failed prostheses with explanation (Elves et al. 1975). The fact that hypersensitization can take months or even years to develop (Haug 1996), along with its infrequency and the uncertainty of its symptomatic expression (Hallab et al. 2001), makes it difficult to perform deeper studies in this field. In the area of dental implantology, the failure of implants has been widely studied (Esposito et al. 1999, 1999b, 1999c), as has their use in compromised patients (van Steenberghe 2003; van Steenberghe et al. 2003b), with the main causes for failure being infection, impaired healing and overload (Esposito et al. 1999). However, not all failures can be explained by these three factors; some are more difficult to explain, such as implant spontaneous rapid exfoliation (Deas et al. 2002) and other situations in which the effect of a possible hypersensitivity reaction to titanium may be taken into consideration.

Taking all these points into account, it seems there is a problem – somewhat infrequent – but nevertheless one that has been systematically overlooked by the profession. Nowadays, the great biocompatibility of titanium has caused the emergence of techniques, which, in various fields of medicine, imply the permanent retention (Haug 1996) of implants in the body. This requires the assessment not only of the general biological suitability of the implant material (biocompatibility) but also of the individual, seeking out methods to identify any patients sensitized to its components, as well as alternative materials in allergic patients (Schramm & Pitto 2000), such as tantalum (Johansson et al. 1990; Matsuno et al. 2001), hydroxyapatite (Schwartz-Arad et al. 2005; Simunek et al. 2005; Artzi et al. 2006) or zirconium (Kohal et al. 2004; Sennerby et al. 2005).

Once the gaps in this field have been taken into account, this study aims at evaluating the presence of titanium allergy by the anamnesis and medical examination, as regards to selective use of cutaneous and epicutaneous testing, in consecutive patients that have consulted or that have been treated with titanium dental implants at a centre specialized in

© 2008 The Authors. Journal compilation © 2008 Blackwell Munksgaard

periodontal surgery and implantology. The study also aims at analysing eventual positive results that may occur regarding the possible clinical indicators evoked in the bibliography.

Material and methods

Between December 2001 and December 2004, 1500 patients in need of dental implant treatment, or surgery for peri-implant pathology, were examined at a centre specialized in periodontal surgery and implantology (Clinica Sicilia, Oviedo, Spain). To detect the presence of Ti allergy, a two-stage assessment was carried out (Bass et al. 1993; Kusy 2004): an initial clinical evaluation and assessment of the patient's medical history and clinical findings, and a further study with an allergy test on preselected patients (Fig. 1).

Clinical assessment: The presence of the following clinical indicators of titanium allergy (inclusion criteria) was evaluated:

Allergy-compatible reactions group:

Presence of allergic symptoms after implant surgery (intra- or extra-oral and local or general redness, urticaria, pruritus, rash, dermatitis and eczematous skin reactions).

De-keratinized hyperplastic lesions of peri-implant soft tissues.

Unexplained implant failures (including spontaneous rapid exfoliation).

Predisposing factors group:

History of multiple allergies (allergy to more than two elements or serious allergic reactions such as glottis oedema or anaphylactic shock).

Extensive surgical internal exposure to titanium (having undergone at least three implant surgeries, including interventions for treating implants with peri-implantitis or removing failed implants with a clear aetiology).

Composition of test and control groups

At this clinical stage, 35 patients were selected for the test group. All patients showing at least one of the previous clinical indicators of titanium allergy (inclusion criteria) were included in this group. The remaining examined patients were excluded. Once the selection of patients was completed, they were referred to the allergy centre for cutaneous and epicutaneous testing. At the same time, a further 800 control patients were examined, of which 35 were randomly selected to form the control group for the second phase of our study.

Thirty-five people were selected for the test group of which 10 were male (28.57%) and 25 female (71.4%), aged between 21 and 68, with an average age of 50.2 (38.9–61.5). The control group included 16 males (45.7%) and 18 females (51.4%), aged between 21 and 70, with an average age of 47.69 (36.31–59.07).

Clinical allergy study

Patients were subjected to cutaneous and epicutaneous tests, following criteria of the International Contact Dermatitis Research Group, the Deutsche Kontakt Dermititis Gruppe and the Grupo Español de Dermatitis de Contacto (Vilaplana et al. 1999; Conde-Salazar-Gómez 2000) and the Modified European Standard Series (Suhonen & Kanerva 2001).

Cutaneous tests were performed using the Prick technique, with immediate readings at 10, 20 and 30 min, to assess type I hypersensitivity. Oxide titanium was used in 0.1% and 5% vaseline (Laboratorios C.B.F. Leti, S.A. Madrid, Spain), titanium oxide in 5% vaseline (Laboratorio Martí Tor, Barcelona, Spain) and metallic titanium in a 0.1% and 5% aqueous solution.

A drop of the allergen or test substance was placed on the forearm skin surface (if the allergen was in vaseline, an amount the size of a grain of rice was used). The allergen was introduced into the epidermis by means of a lancet puncture. The lancet used in this technique has a 1 mm tip with side stops so that only the tip penetrates the skin. A test is carried out each time with a 0.1% histamine solution, which serves as a positive control and helps, by comparison, to interpret the results.

Epicutaneous tests were carried out with delayed readings at 24, 48 and 72 h to evaluate type IV hypersensitivity. The study involved the use of titanium oxide in 0.1% and 5% vaseline (Laboratorios C.B.F. Leti S.A.), titanium oxide in 5% vaseline (Laboratorio Martí Tor) and metallic titanium in a 0.1% and 5% aqueous solution. The test substance was deposited on an area of the skin, normally on the back, and covered with a waterproof dressing. The results were read at 24, 48 and 72 h. Vaseline was used as a control.

The test substance was applied using patches or test units. These patches have a marked area (of at least 0.8 cm^2) in which the antigen is placed. These specific areas can be cellulose, aluminium or plastic. Two types of patches were used: one with a cellulose area with polypropylene insulation (Curatest®, Lohman & Rauscher International GMBH & CO. KG, Neuwied, Germany) and another with an aluminium area (Finn Chambers on Scanpor®, Epitest Ltd, Tuusula, Finland). The titanium aqueous solution was prepared using metallic titanium powder, and its concentration was determined by means of atomic absorption spectrophotometry techniques (Alfa Aesar GMBH & CO. KG, Karslruhe, Germany).

All tests were carried out by the same examiner (G. C.), who was uninformed of

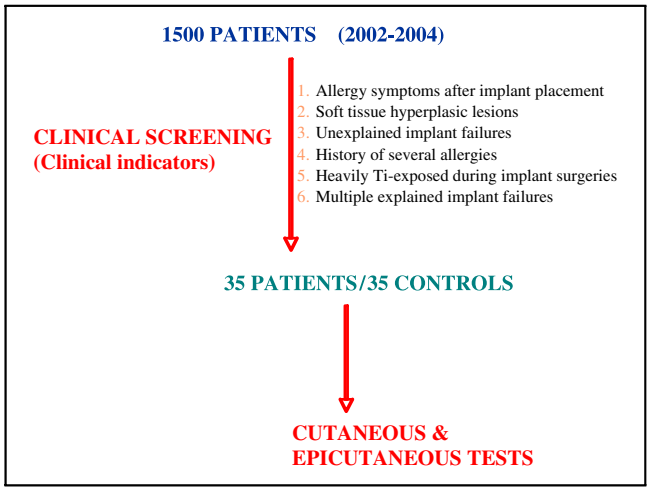

Fig. 1. Study diagram.

© 2008 The Authors. Journal compilation © 2008 Blackwell Munksgaard

the group to which the patient belonged. The first cases also included the use of titanium chloride, titanium sulphate and serum with titanium oxide, although this was not continued due to the little benefit of chloride and sulphate and the absolute equivalence of the serum with titanium oxide and the titanium in aqueous solution.

The results were shown in the form of type I or type IV hypersensitivity and by the level of intensity, according to the following scale:

*mild
**moderate
***significant to strong
****intense

At the same time, a control study was carried out on 800 patients without suspected titanium allergy to check the absence of irritative reactions to the substances used in the titanium allergy study. With these participants, selected among the guests of voluntary patients, the same protocol as in the case of suspected titanium allergy was used, using four groups: 200 non-allergic subjects, 200 subjects with respiratory allergy (type I reaction), 200 subjects with cutaneous allergy (type IV reaction) and 200 subjects allergic to other metals.

Simultaneously, as well as the results from additional tests deriving from specific patient needs (e.g. allergy to aspirin and its derivatives, or to penicillin), patients from the test group were subjected to supplementary tests using alternative implant materials such as tantalum (Ta) or zirconium (Zi) and hydroxyapatite, as well as frequently used dental materials (FUDM), which may mask our results: chrome, nickel, palladium, copper, mercury, zinc, barium, gallium, indium, gold, silver, platinum, acrylic monomers (methyl-methacrylate, BIS-GMA, BIS-M, EGDMA, TEGMA), acrylic polymers (methacrylate, dimethacrylate), silicon, thermoplastic nylon resin (Flexite® New York, USA; Valplast® New York, USA), epoxy resin, rubber components (mercapto and thiuram M rubber mixtures), formaldehyde, para-tertiary-butylphenol-formaldehyde resin (*p*-tert-butylphenol-formaldehyde resin) and paraphenylenediamine (PPD). All patients were subjected to a negative (glycerol saline solution) and a positive control (0.1% histamine).

Statistical analysis

The statistical analysis was performed using the SPSS 14.0 (SPSS Inc., Chicago, IL, USA) program. The estimated prevalence of the 'titanium allergy' variable was expressed as a percentage, with the corresponding 95% confidence range (CR) to facilitate the interpretation of the generalization of the results. Given the low incidence of titanium allergy and, consequently, the low number of cases observed, the association between the dichotomic qualitative variable 'titanium allergy' and the remaining variables was made with the chi square test with Yates correction, when the applicable conditions were ideal, or with the Fisher exact test. The relative risk of the appearance of titanium allergy was calculated in the groups of interest.

Results

After the clinical diagnostic process and allergy tests, nine out of the 1500 patients assessed showed a positive reaction to titanium, representing a prevalence of 0.6%, which the 95% confidence interval would fluctuate between 0.2% and 1%. All patients that tested positive to the Ti concentration at 5% also tested positive at 0.1% even though, logically, on a smaller scale.

Cutaneous and epicutaneous tests were performed on 35 cases and on 800 voluntary control patients at the allergology centre. The cutaneous and epicutaneous tests were negative in all control subjects, and no irritative reactions were observed. Positive reactions to titanium allergy were only discovered in the test group (nine individuals), which make up 25.7% of the pre-selected individuals, with at least a positive clinical indicator (95% CR: 11.2–40.2); obviously, no positive cases were discovered among the 35 control subjects selected at random ($P = 0.002$) (Table 1).

Within the test group, 16 patients were selected, having displayed a clinical indicator from the allergy compatible response group (ACRG), while the remaining 19 were selected for showing an indicator from the predisposing factor group (PFG). After analysing the data from this angle, we noticed that the appearance of subjects with titanium allergy in the ACRG group was almost 10 times greater than in the PFG group (eight cases, 50%/one case, 5.3%, $P = 0.009$). From an exploratory point of view, if we analyse the relation between the three possible groups (ACRG, PFG and control) head to head, we find the proportion of patients with a positive response to titanium allergy to be much higher in the ACRG group than in both the PFG and control groups ($P = 0.005$ and $P < 0.009$); however, there were no significant differences found between the predisposing factors group (one case, 5.3%) and the control group (zero case) (Table 2).

The analysis of the results obtained for the different clinical indicators, despite the groups being progressively smaller, showed interesting data when compared with the control group. Six patients were selected for having shown signs of allergy after dental implant surgery, with three positive cases in this subgroup (50%) ($P = 0.002$). Eight cases were included for unexplained failed implants, five of which were positive (62.5%, $P < 0.001$). Just one of the patients with a previous record of multiple allergies proved positive (10%) (NS, $P = 0.222$), while none of the subgroups selected for all other indicators (de-keratinized soft tissue hyperplasic lesions, high exposure to titanium from surgery, or explained failures) turned out positive, the results coinciding with those of the control group (Table 3).

Tables 4a and b show the most significant characteristics of the medical and

Table 1. **Positive reaction to titanium allergy tests in the group with clinical indicators (test group) vs. control group**

	Patients	+	−	+95% CR
Test group (TG)	35	9 (25.7%)	26 (74.3%)	11.2–40.2
Control group (CG)	35	0 (0%)	35 (100%)	

A significantly higher prevalence is observed in the test group.
χ^2 (Yates correction) = 8.160, df = 2, $P = 0.004$.
Fisher exact test: TG vs. CG, $P = 0.002$.
+, cutaneous and/or epicutaneous positive result; −, cutaneous and/or epicutaneous negative result; +95% CR, 95% confidence range.

© 2008 The Authors. Journal compilation © 2008 Blackwell Munksgaard

***Table 2*. Positive reaction to titanium allergy tests in the 'allergy compatible reactions', 'predisposing factors' and control groups**

	Total	+	−	+95% CR
Allergy compatible response group (ACRG)	16	8 (50%)	8	25.5–75.5
Predisposing factors group (PFG)	19	1 (5.3%)	18	0–15.3
Control group (CG)	35	0 (0%)	35	

A significantly higher prevalence is observed in the 'allergy compatible reactions' group with regard to the 'predisposing factors' and control groups.
χ^2(Yates correction) (ACRG vs. PFG) = 25.843, df = 2, $P<0.009$.
Fisher exact test: ACRG vs. PFG $P=0.005$; ACRG vs. CG $P<0.009$; PFG vs. CG $P=0.352$ NS. Relative risk of a positive result ACRG/PFG: 9.45.
+, cutaneous and/or epicutaneous positive result; −, cutaneous and/or epicutaneous negative result; +95% CR, 95% confidence range.

***Table 3*. Positive reaction to titanium allergy test in selected subgroups with different clinical indicators vs. control group**

Clinical Indicators	Total	+	−	+95%CR
Allergy symptoms after implant placement	6	3** (50%)	3	(10–90)
Soft tissue hyperplasic lesions	2	0 (0%)	2	
Unexplained implant failures	8	5* (62.5%)	3	(29–96)
History of several allergies	10	1 (10%)	9	(0–7.2)
Heavily Ti-exposed during implant surgeries	6	0 (0%)	6	
Explained implant failures	3	0 (0%)	3	
Control group	35	0	35	

A higher significant prevalence was observed in subgroups associated to the clinical indicators 'allergy symptoms after implant placement' and 'unexplained implant failures' with respect to control group.
Statistically significant differences with respect to control group.
Fisher exact test
*$P<0.001$,
**$P=0.002$.
+, cutaneous and/or epicutaneous positive result; −, cutaneous and/or epicutaneous negative result; 95% CR, 95% confidence range.

dental records of patients with positive results. The identity of the patients is protected by alphanumeric code, made up of the table number, 4a or 4b, and their number in sequence. This code should be quoted when making reference to a specific case in the text. Medically, seven patients displayed a good general condition, and two showed considerable pathologies (epilepsy 4A4, and liver cancer and type II diabetes 4B1). Three of the patients showed previous allergies (one case of multiple allergies) and three were heavy smokers. Two were male (22%) and seven female (78%).

Medical records showed four cases of patients suffering from clear allergic symptoms (redness, pruritus, oedema and eczema of the face, mouth, chest and limbs, and in one case glottis oedema, which led to admission in the Emergency Department 4A3), two of which were discovered after showing spontaneous rapid implant exfoliation (4B1 and 4B2) and the other two after receiving several interventions in implants with mobility and for implant complications in external centres.

In seven cases, patients showed type I and IV positive reactions simultaneously, the most prevalent being type I, with the great majority (six out of seven or 85.7%). Only in two cases was a pure type IV reaction discovered, in the two male patients, one of which was of an advanced age and with an immune condition affected by successive and complex oncology treatments (4B1). Of the seven female patients, further multiple allergies were found which involved other compounds: Cr and Ni in all cases, and in other isolated cases penicillin (two), spiramycin, propionic anti-inflammatories, barbiturates, PPD, mites and anisakis. In the two males from our study, neither showed multiple allergies.

The three patients who at the first visit showed suspected titanium allergy, which was confirmed before the start of any treatment, did not accept treatment with alternative implants made of zirconium or coated with hydroxyapatite or tantallum. One of these patients, after requesting a second opinion, opted for titanium implants at a different centre. We have no data on the subsequent progress of this patient (4B4).

The remaining six patients were diagnosed due to the occurrence of complications during treatment. In one patient (4B1), no additional treatments could be carried out given the patient's complicated medical condition, and the patient passed away in 2006. Two patients suffered loss of implants, and replacements were attempted using alternative implants. The first (4B2) had undergone multiple successful implant procedures since 1998. After suffering spontaneous rapid exfoliation of implant in position 42 (Fig. 2a and b), this was successfully replaced in 2002 with a hydroxyapatite-coated implant (Calcitek, Zimmer Dental, Carlsbad, CA, USA) with gold-plated tailored components (Fig. 2c–f). Later on, a root fracture of tooth 33 forced the insertion of a new zirconium implant, which also proved successful (Fig. 3a–d). The second patient (4A3) suffered the only serious medical emergency in this patient category, which led to admission to the Emergencies Department with glottis oedema. The treatment plan included the placement of eight implants in the upper jaw with a one-stage surgical approach, which were occlusally protected with a conventional fixed prosthesis, using teeth of bad prognosis as abutments. Those teeth would be later extracted to place an additional implant in position 23 and to prepare a complete, fixed implant-supported prosthesis, designed with three different sections. The implant in position 24 was extracted 4 months after the surgery, during the prosthesis elaboration phase, due to asymptomatic implant mobility. A new provisional acrylic-reinforced implant-supported prosthesis was elaborated after extracting the remaining teeth, and a few months later an additional Zi implant was placed in position 23, which, like the

 © 2008 The Authors. Journal compilation © 2008 Blackwell Munksgaard

Table 4. **Medical and dental history summary and test results of patients with hypersensitization to titanium**

Patient	Relevant medical and dental history	Group/clinical indicator	Previous treatments	Tests' date	Tests' results	Subsequent treatments
(a)						
4A1 47-year-old woman	Good general health Allergy to metals and shellfish Allergic rhinitis	PFG History of several allergies	No	03/11/2004	(+) Ti, type I (**) and IV (****), Cr, Ni and Anisakis simples (−) Ta, Zi, HA and FUDM	No Zi implant not accepted
4A2 35-year-old woman	Good general health Severe periodontal disease 50 cigarettes/day Anovulatory drugs	ACRG Allergy symptoms after implant placement	10-03, IS 7 implants, 3 flaps: 11–21, 37–38, and 46–48 ACR: facial erythema, irritation, redness and eczema on cheeks and on space between the eyebrows at 1 month post-surgery Reappearing at 4 months MKIV	16/01/2004	(+) Ti, type I (***) and IV (*). Type IV Cr, Ni. (−) Other metals and FUDM	Implant-supported prosthesis SPT Follow up during 3 years No implant complications Keeps smoking
4A3 49-year-old woman	Good general health Frequent cephalalgia, allergy to penicillin Benign cementoblastoma	ACRG Allergy symptoms after implant placement	09-03, IS 8 implants in the upper jaw Teeth-supported fixed provisional 1st ACR: at 1 week, redness and glottis oedema, led to admission in emergencies 01-04, implant 24 removed (unstable) New set of implant-supported fixed provisionals MKIII and MKIV	30/09/2003 16/01/2004 09/03/2006	(+) Ti, type I (****) and IV (**), Cr, Ni, penicillin and spiramycin. (−)Ta Zi and FUDM (+) Ti, type I(**) and(**) Cr, Ni. (+) Ti, type I (****) and IV (*) Cr, Ni	02-06 implant surgery: Zi impl 23 ZSI 2nd ACR: at 24 h, pruritus, dorsal hands, extremities and chest eczema Final full upper jaw prostheses supported by 7 implants SPT Follow-up during 3 years No further complications in the remaining implants
4A4 Mujer 54a.	Epileptic Depression Neosidantoina and ASA daily	ACRG Allergy symptoms after implant placement	04-98, IS 6 implants in lower jaw with HP Patient developed mucositis and hyperplasia 11-02, hyperplasia reduction surgery Amoxicillin, metamizol and CHX Recurring rush and oral burning symptoms after suspending amoxicillin BIS	21/11/2002	(+) Ti, type I (*) and IV (**) Cr, Ni, & penicillin. (−) Other metals and FUDM	SPT Follow-up during 5 years No follow-up after 2003
(b)						
4B1 68-year-old man	Hepatitis C, Liver cancer, Type II diabetes, Mod Chronic Periodontitis PST+	ACRG Unexplained implant failures	05-00, IS 6 implants in the lower jaw Immediate relining of a full lower denture SR exfoliation in 2 implants, in 3–4 weeks Remaining 4 implants removed in 11-00 BIS	04/12/2001	(+) Ti, type IV (***). (−) HA other metals and FUDM	Nor further procedures were scheduled due to his medical condition In 2006, patient dies of heart failure and liver cancer complications

© 2008 The Authors. Journal compilation © 2008 Blackwell Munksgaard

Table 4. **(Continued)**

Patient	Relevant medical and dental history	Group/clinical indicator	Previous treatments	Tests' date	Tests' results	Subsequent treatments
4B2 43-year-old woman (Figs 2 and 3)	Good general health Hypercholesterolemia Fenofibrate	ACRG Unexplained implant failures	09-98/03-99, IS 6 implants in upper jaw 10-98/11-98, IS Implants 34-36, 44-46 12-00, PIS in upper jaw 11-01, IS Immediate implant 32, 42 Non-loaded Implant 42 SR exfoliation in 3 weeks BIS, MKIII	17/01/2002 04/11/2002	(+) Ti, type I (****) and IV (**), Cr, Ni, and *p*-phenylenediamine (PPD). (−) Ta and FUDM Absence of changes	10-02 IS: Impl 42 HA cylinder (platinated gold cover screw and healing abutment) HAC 04-03 implant prosthesis 32-42 10-05 Fracture 33, Zi impl. ZSI.vImplant-supported prosthesis SPT Follow-up during 8 years No further implant complications
4B3 29-year-old man	Good general health 20 cigarettes/day	ACRG Unexplained implant failures	1986 Traumatism #11 Fracture and tooth loss 1995, IS implant 11 (EXT) 2002 the implant was extracted (EXT) Implant brand unknown	08/01/2003	(+) Ti, type IV (***). (−) Other metals and FUDM	No Patient did not accept treatment with a Zi implant
4B4 41-year-old woman	Good general health Moderate C periodontitis	ACRG Unexplained implant failures	02-96, IS Implant 11 (EXT) 05-96, the implant was extracted (EXT) BIS	05/12/2002	(+) Ti, type I (****) and IV (*) Cr, Ni and Zn. (−) Ta, other metals and FUDM	No Patient did not accept treatment with a Zi implants Ti implants were placed (EXT) No follow-up
4B5 45-year-old woman	Good general health Varicose vein surgery Allergy to barbiturates 20 cigarettes/day	ACRG Unexplained implant failures	Childhood: endo treatment and Cyst surgery #21 06-02, tooth extraction 06-03, IS implant flapless 21 (ISQ 59) 09-03, provisional prosthesis (EXT) 03-04, implant infection and allergic reaction, implant with clinical mobility (ISQ 47) O3I	17/03/2004	(+) Ti, type I (**) and IV (**) Cr, Ni, mites, barbiturates and propionic acid derivatives. (−) Ta, Zi, other metals and FUDM	Patient does not allow extraction of implant #21 for aesthetic reasons Keeps smoking Progressive peri-implant bone loss and secondary complications (fistula)

ACR, allergy compatible reaction; ACRG, allergy compatible reactions Group; ASA, acetyl salicylic acid; PFG, predisposing factors group; BIS, Branemark System Standard Implants; CHX, clorhexidine rinses; FUDM, frequently used dental materials; HA, hydroxyapatite; HP, hybrid prosthesis; IS, implant surgery; MKIII–MKIV, MKIII and MKIV Implants (NobelBiocare); SPT, supportive periodontal treatment; ZSI, Z Systems Implants (Constance); 4A1–4A4, patient identification code; EXT, medical–dental treatments performed in external clinics, incomplete information; HAC, Calcitek Implants (Zimmer Dental); ISQ, Ostell® Implant Stability Quotient; O3I, Osseotite NT implant (3I); PIS, peri-implant surgery; PST+, tested positive for the IL-1 genotype; SR exfoliation, spontaneous rapid exfoliation; 4B1–4B4, patient identification code; (+), cutaneous and/or epicutaneous positive result; (−), cutaneous and/or epicutaneous negative result. Reactions to cutaneous and epicutaneous tests:
*mild,
**moderate,
***important,
****intense.

© 2008 The Authors. Journal compilation © 2008 Blackwell Munksgaard

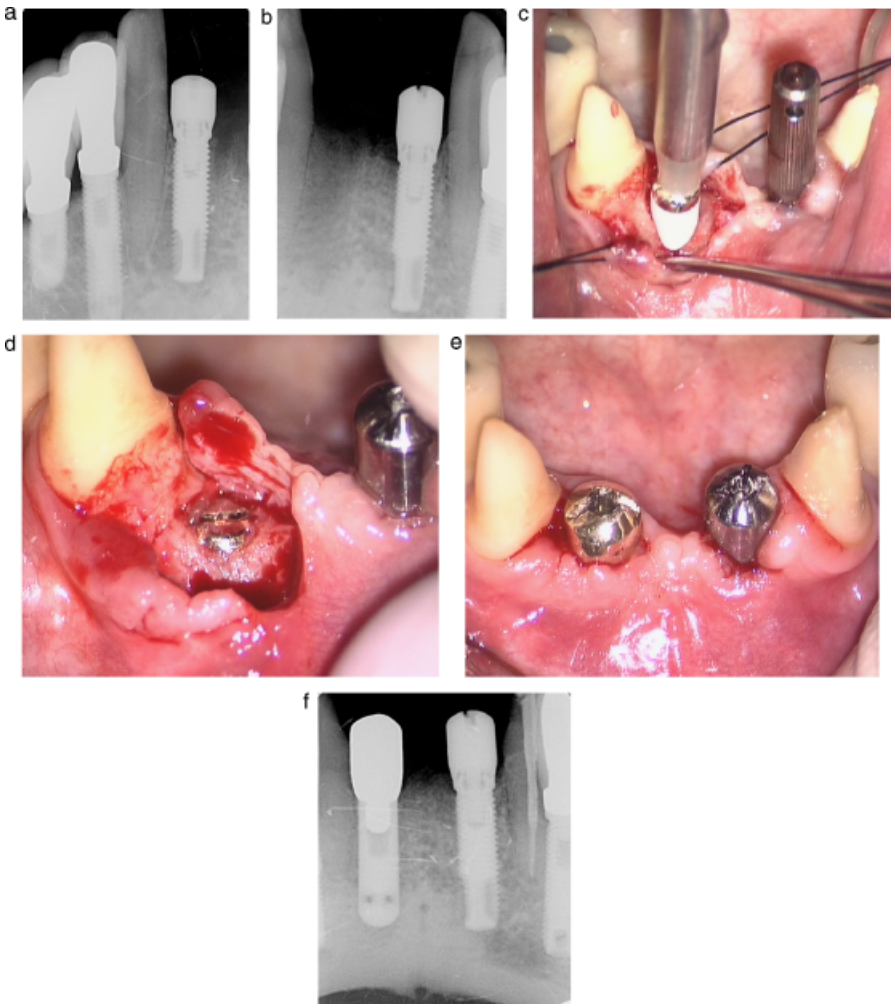

Fig. 2. A female patient (patient 4B2, Table 4b) who had undergone multiple successful implant surgeries during the last 4 years had two immediate implants placed after dental extraction of lower incisors in November 2001 (a). Implant in position 42 showed spontaneous rapid exfoliation at 3 weeks after placement (b) and tested positive to Ti allergy. In October 2002, a cylindrical hydroxyapatite-coated implant was placed (Calcitek Implants, Zimmer Dental) (c), for which a specific cover screw (d) and gold-plated healing abutment (e) were produced. The case was finally restored without further complications.

previous Ti implant, was not integrated and was later removed. Following the Zi implant procedure, in which a small flap was raised that did not come to affect the neighboring asymptomatic titanium implants in positions 21 and 25, the patient suffered another allergic flare-up, with oedema, pruritus and urticaria of the feet, wrists and chest. The new allergy tests showed an increased intensity of type I hypersensitivity (++++), but a negative reaction to Zi. During the years of follow-up for these two cases (3 and 8 years), no abnormal behaviour was detected in peri-implant tissues around all other fixtures.

One of the patients (4B5) who received a flapless implant in position 21 with an immediate provisional prosthesis, showing good clinical stability (ISQ 59), a few months later suffered a mixed infectious and allergic flare-up, with the allergic response recurring a few weeks after stopping all medication. The implant displayed a peri-implant bone lesion, which affected a significant part of its perimeter, as shown by the periapical radiography, and an ISQ of 41. The implant was declared failed and the patient informed of her allergy, although she decided not to have it removed. Its development to date has consisted of progressive bone loss and the appearance of a secondary fistula, but it has remained clinically stable. Finally, two additional patients displayed an allergic flare-up: one of them after the placement of seven implants (4A2) and the other after the surgical treatment of a fibrous hyperplasia of the peri-implant soft tissues, presumably associated with taking antiepileptic medication (4A4). None of them suffered additional implant failures, nor further complications or peri-implant bone loss.

No relation could be established between the type of implant and the appearance of cutaneous allergic reactions, implant failures or complications. In patients with positive tests, implants with machined surfaces (Branemark System Standard®, NobelBiocare, Göteborg, Sweden), oxidized titanium (MKIII® and MKIV®, NobelBiocare) and SLA (Osseotite Nt®, 3I, Palm Beach, FL, USA) have been placed, before the described allergic episodes. Additionally, no discoveries of allergic reactions to zirconium, tantalum or hydroxyapatite were found in the test group.

Discussion

Performing a metal allergy assessment in a high number of patients, expecting a low prevalence of subjects showing positive results, does not justify carrying out allergy tests on all individuals, whereas a two-stage assessment would be more reasonable (Bass et al. 1993; Kusy 2004). The first phase was aimed at identifying potentially allergic patients based on medical records (predisposing factors) (Brune 1986; Cook et al. 1991; Bass et al. 1993; Schliephake et al. 1993; Weingart et al. 1994; Thomas 2000; Hallab et al. 2001; Tamai et al. 2001; Frisken et al. 2002), on the examination of signs and symptoms associated with titanium allergy (Hensten-Pettersen 1992; Haug 1996; Lhotka et al. 1998; Matthew & Frame 1998; Thomas 2000; Bircher & Stern 2001; Tamai et al. 2001; Valentine-Thon & Schiwara 2003; Thomas et al. 2006) and on clinical events such as unexplained failures (Elves et al. 1975; Cook et al. 1991; Jacobs et al. 1991; Lalor et al. 1991; Hallab et al. 2001; Frisken et al. 2002) and de-keratinized hyperplasic reactions of the peri-implant mucosa (Mitchell et al. 1990), associated with titanium allergy in the literature (titanium allergy compatible reactions). The second phase was used to perform specific allergy tests, in this case cutaneous and epicutaneous, because these are the tests of choice in assessing type I and IV reactions in clinical allergology (Thomas 2000; Yamauchi et al.

© 2008 The Authors. Journal compilation © 2008 Blackwell Munksgaard

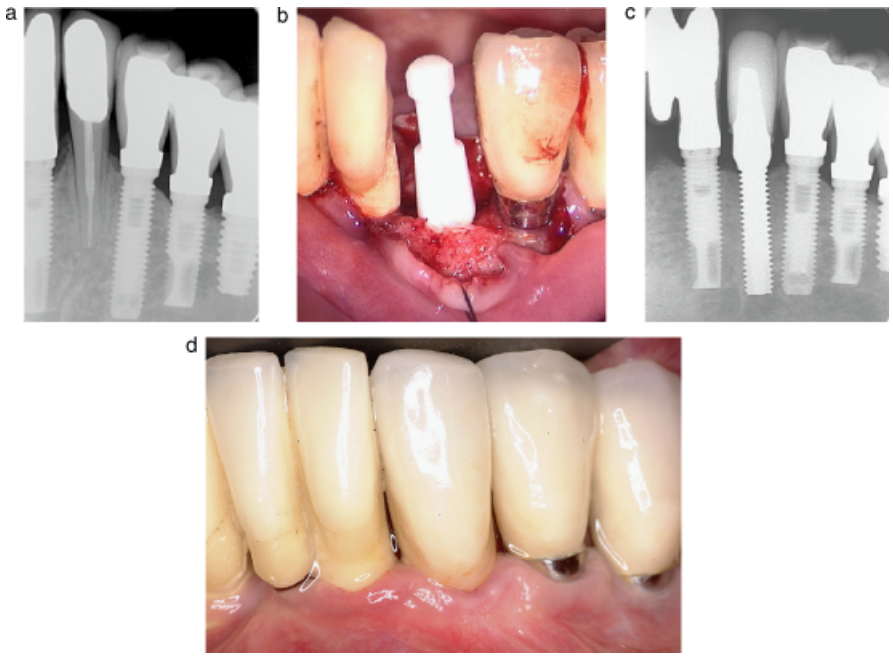

Fig. 3. In October 2005, the same patient (4B2) had a root fracture of tooth 33 (a). After extraction and adequate healing, the tooth could be replaced by a Zi implant (Z Systems Implants, Constance, Germany) (b), and a single unit implant-supported cemented prosthesis was made (Dr José Suárez Feito) (c and d).

2000; Kusy 2004; Thomas et al. 2006). With this protocol we have discovered a prevalence of titanium allergy that fluctuates from 0.2% to 1% of patients either participating or treated with implants in a specialized clinic. Studies carried out with the patch test on small subpopulations, such as 185 consecutive patients from an orthopaedic clinic (Lhotka et al. 1998), or 145 patients with suspected metal allergy (Okamura et al. 1999) and 50 healthy control subjects, show prevalence rates of between 1% and 3% in test cases and 0% in control subjects, found to be in-line with our results. Our two-phase diagnostic system could underestimate the prevalence of allergy, should we neglect to analyse the 1465 patients not preselected in the first phase with specific tests. However, the fact that there were no positive results found in the 800 healthy control subjects examined at the allergy centre, as with the 50 Okamura control patients, justifies our decision not to test all 1500 assessed patients. Possible restrictions deriving from the use of cutaneous and epicutaneous tests (Valentine-Thon & Schiwara 2003), the fact that some hypersensitive reactions appear over the long-term and the differences between cutaneous reactivity and that of other organs (Schramm & Pitto 2000; Thomas 2000), as well as the potential yet unlikely appearance of immunological tolerance or non-specific immunosuppression caused by implant degradation products (Hallab et al. 2001), may also contribute to reducing our study's prevalence rate.

Nonetheless, our results are similar to the data obtained in a study carried out with immunologic techniques performed in blood samples, such as the LMI (Merritt & Rodrigo 1996b), where a prevalence of 4% was reached. Another alternative for comparison would be data obtained through the MELISA test, carried out on blood samples from patient data banks, but this shows highly variable results (Valentine-Thon & Schiwara 2003), fluctuating from 1.5% to 28%, possibly overestimating the actual prevalence.

From a clinical point of view, it seems interesting to select patients based on clinical criteria and to carry out specific tests in preselected cases (Kusy 2004) in order to determine the suitability of a material that will be used in a permanent implant (Haug 1996; Schramm & Pitto 2000). It proves complicated, given the low number of positive reactions – in just nine individuals – to establish an association between the existence of positive cases and some clinical indicators. However, this would perhaps be useful to prepare questionnaires (Kusy 2004) and clinical examination protocols to improve the orientation of pre- and post-operative assessments on these patients. Taking these restrictions into account, it seems more worthwhile to give priority to the assessment of allergy compatible reactions (ACRG) after fitting dental implants, rather than to the possible predisposing factors (PFG) assessed in our study (Table 2).

Analysing the results from the PFG group, literature revision suggests that we could expect patients having experienced extensive surgical exposure to titanium and therefore further internal exposure to the metal (Jacobs et al. 1991; Schliephake et al. 1993; Weingart et al. 1994; Frisken et al. 2002) to show a greater frequency of titanium allergy reactions. However, this was not the case, and none of the nine patients from this group proved positive. Likewise, and within the same predisposing factors group, patients with an allergy profile (Cook et al. 1991; Thomas 2000; Hallab et al. 2001; Tamai et al. 2001) could represent a collective sensitive to these types of complications. It is eventually paradoxical to find just a single positive case in the group of patients having shown a previous allergy to more than two elements (Table 3).

On the other hand, in the titanium allergy compatible response group we found eight positive cases. The symptoms compatible with an allergic reaction have been widely described (Hensten-Pettersen 1992; Haug 1996; Lhotka et al. 1998; Thomas 2000; Tamai et al. 2001; Valentine-Thon & Schiwara 2003; Thomas et al. 2006), and although the symptoms are not allergen specific, their appearance after a titanium dental implant procedure could be very useful to detect potential allergy patients (Matthew & Frame 1998; Bircher & Stern 2001). In our study, 50% of the patients with these characteristics proved positive after performing the specific tests (Table 3). Another interesting subgroup were the patients who had failed implants with no clear explanation, also referred to as unexplained failures, in accordance with the current accepted criteria (Esposito et al. 1999, 1999b, 1999c). Previous discoveries, such as increased internal exposure in control animals with failed metallic implants and in humans with loose hip prosthesis (Frisken et al. 2002; Jacobs et al. 1991;

 © 2008 The Authors. Journal compilation © 2008 Blackwell Munksgaard

Witt & Swann 1991), as well as a greater sensitization of patients with a failed orthopaedic prosthesis (Cook et al. 1991; Lalor et al. 1991), which is particularly elevated when the failure is unexplained (Elves et al. 1975), together with data obtained from longitudinal studies, which show a percentage of metal sensitizations six times greater in patients with failed metallic orthopaedic implants (Hallab et al. 2001), let us establish the hypothesis of a possible connection between the inexplicable failed dental implant and sensitivity to titanium. We found in this group that five out of eight patients (62.5%) showed a positive reaction to titanium (Table 3). Finally, there are reports (Mitchell et al. 1990) of two cases of de-keratinized hyperplasic reactions of the peri-implant tissues, whose histological characteristics could be compatible with a type IV titanium allergy; after proving resistant to treatment, these began to disappear after the titanium abutments were replaced with others made of gold. In our study we found two patients with similar characteristics, although none of them proved positive to the tests performed (Table 3).

Although we know that titanium allergy is uncommon (Tamai et al. 2001) and that not all patients sensitized to a metal display complications following an endosseous implant (Thomas 2000), the appearance of significant complications in particularly sensitive patients cannot be disregarded (Hallab et al. 2001). In our study, one patient suffered from glottis oedema, and this led to admission in the Emergency Department, while two other patients showed cases of spontaneous rapid exfoliation of the implants (Tables 4a and b), complications that may be considered important and that can cause repercussions to the health of the patient as well as medical/legal implications for the professionals.

It is traditionally believed that a hypersensitive reaction to a metal is essentially type IV or, more rarely, type I (Haug 1996). From our revision, there were very few authors who assessed the type I reaction (Thomas 2000; Yamauchi et al. 2000), with the majority of studies performed on works aimed at detecting type IV hypersensitivity (Lalor et al. 1991; Lhotka et al. 1998; Okamura et al. 1999; Ahnlide et al. 2000; Schramm & Pitto 2000; Yamauchi et al. 2000; Bircher & Stern 2001; Suhonen & Kanerva 2001; Kusy 2004; Thomas et al. 2006). However, we have systematically assessed both type I and type IV outcomes, which has helped us to identify an elevated number of cases (seven) with type I reactions (Tables 3 and 4). Disregarding the fact that two of them were cases not treated at our centre (4A1 and 4B4), the remaining five proved to have suffered some form of acute reaction, post-implant surgery allergic reaction or short-term complications, or spontaneous rapid exfoliation of an implant (Tables 3 and 4), which seem to support the type I hypersensitivity reaction component in these patients.

Finally, it is perhaps contradictory that patients sensitive to titanium – having already lost implants – should retain others, presumable integrated, without further evidence of bone loss, looseness or complications. Of five patients still retaining titanium implants, with a follow-up between 3 and 8 years, four progressed without bone loss or complications in the peri-implant tissues, with just one case showing a progressive bone loss (Tables 3 and 4). Particularly interesting is a case showing a reactivated allergy flare-up after surgery to place an additional implant, which involved none of the surviving implants, to remove the provisional prosthesis and to place titanium abutments during the surgery; all the same, it has progressed for 3 years without showing complications in the original implants (4A3). Today, we know that just a small percentage of sensitized patients show complications with orthopaedic implants (Thomas 2000), and dental implants have special conditions that could prevent them from being affected by an allergic reaction despite developing a cutaneous reaction: the implant–host contact surface is very limited (Brunski et al. 2000; Akagawa & Abe 2003), the prosthetic structures and implants are partially isolated by a layer of glycoproteins (Bass et al. 1993) and the bone and oral mucosa have a low reactivity (Bass et al. 1993; Schramm & Pitto 2000; Thomas 2000).

With data from a non-experimental research study such as this, cause–effect relations cannot be established, and so the conclusions must be interpreted as hypotheses to be confirmed later on. Nonetheless, it appears reasonable to conclude that titanium allergy can be detected, albeit with a low prevalence (0.6%), in dental implant patients. Bearing this in mind, perhaps it should be considered as a clinical diagnostic process for suspected titanium allergy in patients intending to receive implants made from such material, with allergy tests performed on those patients at risk. There is scarce information on the frequency of substantiable clinical complications in patients with metallic implants and cutaneous reactivity to the same material. Nevertheless, once the allergy has been diagnosed, the professional must then determine whether it is suitable to place a titanium implant in patients with a positive reaction to it, given the potential medical and legal complications that could derive from such a procedure. From the authors' point of view, and following a basic principle of deontological prudence, until research shows otherwise, it would be convenient to use implants of alternative materials in patients proving allergic to titanium.

Acknowledgements: The authors would like to thank José María Suárez Feito, Lorena Hernández, Luis Vázquez, Angel Álvarez (Prodesmédica), Pepita Pérez (Zimmer Dental), and María Muñiz and Manuel González (Socinser) for their generous collaboration, and María de la Fuente (www.visverbi.com) for the translation and review of the English manuscript.

References

Abdallah, H.I., Balsara, R.K. & O'Riordan, A.C. (1994) Pacemaker contact sensitivity: clinical recognition and management. *Annals of Thoracic Surgery* **57**: 1017–1018.

Ahnlide, I., Bjorkner, B., Bruze, M. & Moller, H. (2000) Exposure to metallic gold in patients with contact allergy to gold sodium thiosulfate. *Contact Dermatitis* **43**: 344–350.

Akagawa, Y. & Abe, Y. (2003) Titanium: the ultimate solution or an evolutionary step? *International Journal of Prosthodontics* **16** (Suppl.): 28–29; discussion 47–51.

© 2008 The Authors. Journal compilation © 2008 Blackwell Munksgaard

Akaki, T. & Dekio, S. (2002) Pacemaker dermatitis: report of a case. *Environmental Dermatology* **9**: 153–157.

Artzi, Z., Carmeli, G. & Kozlovsky, A. (2006) A distinguishable observation between survival and success rate outcome of hydroxyapatite-coated implants in 5–10 years in function. *Clinical Oral Implants Research* **17**: 85–93.

Basketter, D.A., Whittle, E. & Monk, B. (2000) Possible allergy to complex titanium salt. *Contact Dermatitis* **42**: 310–311.

Bass, J.K., Fine, H. & Cisneros, G.J. (1993) Nickel hypersensitivity in the orthodontic patient. *American Journal of Orthodontics and Dentofacial Orthopedics* **103**: 280–285.

Bianco, P.D., Ducheyne, P. & Cuckler, J.M. (1996) Local accumulation of titanium released from a titanium implant in the absence of wear. *Journal of Biomedical Materials Research* **31**: 227–234.

Bircher, A.J. & Stern, W.B. (2001) Allergic contact dermatitis from 'titanium' spectacle frames. *Contact Dermatitis* **45**: 244–245.

Breton, J.L., Louis, J.M. & Garnier, G. (1992) Asthma caused by hard metals: responsibility of titanium. *Presse Médicale* **21**: 997.

Brune, D. (1986) Metal release from dental biomaterials. *Biomaterials* **7**: 163–175.

Brunski, J.B., Puleo, D.A. & Nanci, A. (2000) Biomaterials and biomechanics of oral and maxillofacial implants: current status and future developments. *International Journal of Oral & Maxillofacial Implants* **15**: 15–46.

Buchet, S., Blanc, D., Humbert, P., Girardin, P., Vigan, M., Anguenot, T. & Agache, P. (1992) Pacemaker dermatitis. *Contact Dermatitis* **26**: 46–47.

Carando, S., Cannas, M., Rossi, P. & Portigliatti-Barbos, M. (1985) The lymphocytic transformation test (L.T.T.) in the evaluation of intolerance in prosthetic implants. *Italian Journal of Orthopaedics and Traumatology* **11**: 475–481.

Case, C.P., Langkamer, V.G., James, C., Palmer, M.R., Kemp, A.J., Heap, P.F. & Solomon, L. (1994) Widespread dissemination of metal debris from implants. *Journal of Bone and Joint Surgery – British Volume* **76**: 701–712.

Conde-Salazar-Gómez, L. (2000) Dermatosis profesionales por metales. In: Conde-Salazar-Gómez, L., ed. *Dermatosis Profesionales*, 79–88. Madrid: Signament Ediciones SL.

Cook, S.D., McCluskey, L.C., Martin, P.C. & Haddad, R.J. Jr (1991) Inflammatory response in retrieved noncemented porous-coated implants. *Clinical Orthopaedics and Related Research* **264**: 209–222.

Deas, D.E., Mikotowicz, J.J., Mackey, S.A. & Moritz, A.J. (2002) Implant failure with spontaneous rapid exfoliation: case reports. *Implant Dentistry* **11**: 235–242.

El Salam El Askary, A. (2003) *Reconstructive Aesthetic Implant Surgery*. Oxford, UK: Blackwell Publishing Ltd.

Elves, M.W., Wilson, J.N., Scales, J.T. & Kemp, H.B. (1975) Incidence of metal sensitivity in patients with total joint replacements. *British Medical Journal* **4**: 376–378.

Esposito, M., Hirsch, J., Lekholm, U. & Thomsen, P. (1999) Differential diagnosis and treatment strategies for biologic complications and failing oral implants: a review of the literature. *International Journal of Oral & Maxillofacial Implants* **14**: 473–490.

Esposito, M., Lausmaa, J., Hirsch, J.M. & Thomsen, P. (1999b) Surface analysis of failed oral titanium implants. *Journal of Biomedical Materials Research* **48**: 559–568.

Esposito, M., Thomsen, P., Ericson, L.E. & Lekholm, U. (1999c) Histopathologic observations on early oral implant failures. *International Journal of Oral & Maxillofacial Implants* **14**: 798–810.

Frisken, K.W., Dandie, G.W., Lugowski, S. & Jordan, G. (2002) A study of titanium release into body organs following the insertion of single threaded screw implants into the mandibles of sheep. *Australian Dental Journal* **47**: 214–217.

Hallab, N., Merritt, K. & Jacobs, J.J. (2001) Metal sensitivity in patients with orthopaedic implants. *Journal of Bone and Joint Surgery – American Volume* **83A**: 428–436.

Haug, R.H. (1996) Retention of asymptomatic bone plates used for orthognathic surgery and facial fractures. *Journal of Oral and Maxillofacial Surgery* **54**: 611–617.

Hensten-Pettersen, A. (1992) Casting alloys: side-effects. *Advances in Dental Research* **6**: 38–43.

Jacobs, J.J., Skipor, A.K., Black, J., Urban, R. & Galante, J.O. (1991) Release and excretion of metal in patients who have a total hip-replacement component made of titanium-base alloy. *Journal of Bone and Joint Surgery – American Volume* **73**: 1475–1486.

Johansson, C.B., Hansson, H.A. & Albrektsson, T. (1990) Qualitative interfacial study between bone and tantalum, niobium or commercially pure titanium. *Biomaterials* **11**: 277–280.

Katou, F., Andoh, N., Motegi, K. & Nagura, H. (1996) Immuno-inflammatory responses in the tissue adjacent to titanium miniplates used in the treatment of mandibular fractures. *Journal of Cranio-maxillo-facial Surgery* **24**: 155–162.

Kohal, R.J., Weng, D., Bachle, M. & Strub, J.R. (2004) Loaded custom-made zirconia and titanium implants show similar osseointegration: an animal experiment. *Journal of Periodontology* **75**: 1262–1268.

Kusy, R.P. (2004) Clinical response to allergies in patients. *American Journal of Orthodontics and Dentofacial Orthopedics* **125**: 544–547.

Lalor, P.A., Revell, P.A., Gray, A.B., Wright, S., Railton, G.T. & Freeman, M.A. (1991) Sensitivity to titanium. A cause of implant failure? *Journal of Bone and Joint Surgery – British Volume* **73**: 25–28.

Lhotka, C.G., Szekeres, T., Fritzer-Szekeres, M., Schwarz, G., Steffan, I., Maschke, M., Dubsky, G., Kremser, M. & Zweymuller, K. (1998) Are allergic reactions to skin clips associated with delayed wound healing? *American Journal of Surgery* **176**: 320–323.

Matsuno, H., Yokoyama, A., Watari, F., Uo, M. & Kawasaki, T. (2001) Biocompatibility and osteogenesis of refractory metal implants, titanium, hafnium, niobium, tantalum and rhenium. *Biomaterials* **22**: 1253–1262.

Matthew, I. & Frame, J.W. (1998) Allergic responses to titanium. *Journal of Oral and Maxillofacial Surgery* **56**: 1466–1467.

Matthew, I.R. & Frame, J.W. (1998b) Ultrastructural analysis of metal particles released from stainless steel and titanium miniplate components in an animal model. *Journal of Oral and Maxillofacial Surgery* **56**: 45–50.

Merritt, K. & Brown, S.A. (1996) Distribution of cobalt chromium wear and corrosion products and biologic reactions. *Clinical Orthopaedics and Related Research* **S264**: S233–S243.

Merritt, K. & Rodrigo, J.J. (1996b) Immune response to synthetic materials. Sensitization of patients receiving orthopaedic implants. *Clinical Orthopaedics and Related Research* **326**: 71–79.

Mitchell, D.L., Synnott, S.A. & VanDercreek, J.A. (1990) Tissue reaction involving an intraoral skin graft and CP titanium abutments: a clinical report. *International Journal of Oral & Maxillofacial Implants* **5**: 79–84.

Nemery, B. (1990) Metal toxicity and the respiratory tract. *European Respiratory Journal* **3**: 202–219.

Okamura, T., Morimoto, M., Fukushima, D. & Yamane, G. (1999) A Skin Patch Test for the Diagnosis of Titanium Allergy. *Journal of Dental Research* **78**: 1135.

Parr, G.R., Gardner, L.K. & Toth, R.W. (1985) Titanium: the mystery metal of implant dentistry. Dental materials aspects. *Journal of Prosthetic Dentistry* **54**: 410–414.

Peters, M.S., Schroeter, A.L., van Hale, H.M. & Broadbent, J.C. (1984) Pacemaker contact sensitivity. *Contact Dermatitis* **11**: 214–218.

Redline, S., Barna, B.P., Tomashefski, J.F. Jr & Abraham, J.L. (1986) Granulomatous disease associated with pulmonary deposition of titanium. *British Journal of Industrial Medicine* **43**: 652–656.

Revell, P.A. & Lalor, P.A. (1995) Massive exposition to titanium, but without sensitization. *Acta Orthopaedica Scandinavica* **66**: 484.

Roitt, I.M. & Delves, P.J. (2001) *Essential Immunology*. 10th edition. London: Blackwell Science Ltd.

Schliephake, H., Reiss, G., Urban, R., Neukam, F.W. & Guckel, S. (1993) Metal release from titanium fixtures during placement in the mandible: an experimental study. *International Journal of Oral & Maxillofacial Implants* **8**: 502–511.

Schramm, M. & Pitto, R.P. (2000) Clinical relevance of allergological tests in total hip joint replacement. In: Willmann, G. & Zweymüller, K., eds. *Bioceramics in Hip Joint Replacement*, 101–106. Thieme, New York, USA.

Schwartz-Arad, D., Mardinger, O., Levin, L., Kozlovsky, A. & Hirshberg, A. (2005) Marginal bone loss pattern around hydroxyapatite-coated versus commercially pure titanium implants after up to 12 years of follow-up. *International Journal of Oral & Maxillofacial Implants* **20**: 238–244.

Sennerby, L., Dasmah, A., Larsson, B. & Iverhed, M. (2005) Bone tissue responses to surface-modified zirconia implants: a histomorphometric and removal torque study in the rabbit. *Clinical Implant Dentistry and Related Research* **7** (Suppl. 1): S13–S20.

© 2008 The Authors. Journal compilation © 2008 Blackwell Munksgaard

Shirakawa, T., Kusaka, Y., Fujimura, N., Goto, S., Kato, M., Heki, S. & Morimoto, K. (1989) Occupational asthma from cobalt sensitivity in workers exposed to hard metal dust. *Chest* **95**: 29–37.

Simunek, A., Kopecka, D., Cierny, M. & Krulichova, I. (2005) A six-year study of hydroxyapatite-coated root-form dental implants. *West Indian Medical Journal* **54**: 393–397.

Smith, D.C., Lugowski, S., McHugh, A., Deporter, D., Watson, P.A. & Chipman, M. (1997) Systemic metal ion levels in dental implant patients. *International Journal of Oral & Maxillofacial Implants* **12**: 828–834.

Suhonen, R. & Kanerva, L. (2001) Allergic contact dermatitis caused by palladium on titanium spectacle frames. *Contact Dermatitis* **44**: 257–258.

Sykaras, N., Iacopino, A.M., Marker, V.A., Triplett, R.G. & Woody, R.D. (2000) Implant materials, designs, and surface topographies: their effect on osseointegration. A literature review. *International Journal of Oral & Maxillofacial Implants* **15**: 675–690.

Tamai, K., Mitsumori, M., Fujishiro, S., Kokubo, M., Ooya, N., Nagata, Y., Sasai, K., Hiraoka, M. & Inamoto, T. (2001) A case of allergic reaction to surgical metal clips inserted for postoperative boost irradiation in a patient undergoing breast-conserving therapy. *Breast Cancer* **8**: 90–92.

Thewes, M., Kretschmer, R., Gfesser, M., Rakoski, J., Nerlich, M., Borelli, S. & Ring, J. (2001) Immunohistochemical characterization of the perivascular infiltrate cells in tissues adjacent to stainless steel implants compared with titanium implants. *Archives of Orthopaedic and Trauma Surgery* **121**: 223–226.

Thomas, P. (2000) Allergological aspects of implant biocompatibility. In: Willmann, K.Z.G., ed. *Bioceramics in Hip Joint Replacement*, 117–121. Thieme, New York, USA.

Thomas, P., Bandl, W.D., Maier, S., Summer, B. & Przybilla, B. (2006) Hypersensitivity to titanium osteosynthesis with impaired fracture healing, eczema, and T-cell hyperresponsiveness in vitro: case report and review of the literature. *Contact Dermatitis* **55**: 199–202.

Torgersen, S., Gilhuus-Moe, O.T. & Gjerdet, N.R. (1993) Immune response to nickel and some clinical observations after stainless steel miniplate osteosynthesis. *International Journal of Oral and Maxillofacial Surgery* **22**: 246–250.

Torgersen, S., Gjerdet, N.R., Erichsen, E.S. & Bang, G. (1995) Metal particles and tissue changes adjacent to miniplates. A retrieval study. *Acta Odontologica Scandinavica* **53**: 65–71.

Torgersen, S., Moe, G. & Jonsson, R. (1995b) Immunocompetent cells adjacent to stainless steel and titanium miniplates and screws. *European Journal of Oral Sciences* **103**: 46–54.

Valentine-Thon, E. & Schiwara, H.W. (2003) Validity of MELISA for metal sensitivity testing. *Neuro Endocrinology Letters* **24**: 57–64.

van Steenberghe, D. (2003) The use of oral implants in compromised patients. *Periodontology 2000* **33**: 9–11.

van Steenberghe, D., Quirynen, M. & Molly, L. (2003b) Impact of systemic diseases and medication on osseointegration. *Periodontology 2000* **33**: 163–171.

Verbov, J. (1985) Pacemaker contact sensitivity. *Contact Dermatitis* **12**: 173.

Vilaplana, J., Espiell, F. & Miranda-Romero, A. (1999) Dermatitis de contacto por metales. In: Camarasa, J.M., ed. *Dermatitis de Contacto*, 157–182. Madrid: Aula Medica.

Weighed, P. (2002) *Geode. Geodynamics and Ore Deposit Evolution*. European Science Foundation, Strasbourg, France.

Weingart, D., Steinemann, S., Schilli, W., Strub, J.R., Hellerich, U., Assenmacher, J. & Simpson, J. (1994) Titanium deposition in regional lymph nodes after insertion of titanium screw implants in maxillofacial region. *International Journal of Oral and Maxillofacial Surgery* **23**: 450–452.

Wennerberg, A., Ide-Ektessabi, A., Hatkamata, S., Sawase, T., Johansson, C., Albrektsson, T., Martinelli, A., Sodervall, U. & Odelius, H. (2004) Titanium release from implants prepared with different surface roughness. *Clinical Oral Implants Research* **15**: 505–512.

Witt, J.D. & Swann, M. (1991) Metal wear and tissue response in failed titanium alloy total hip replacements. *Journal of Bone and Joint Surgery-British Volume* **73**: 559–563.

Yamauchi, R., Morita, A. & Tsuji, T. (2000) Pacemaker dermatitis from titanium. *Contact Dermatitis* **42**: 52–53.

© 2008 The Authors. Journal compilation © 2008 Blackwell Munksgaard