Austin Journal of Allergy

Open Access

Austin Publishing Group

Case Report

Immediate Hypersensitivity Reaction to Radiocontrast Media

Miranda García M[1]*, Chico Civera R[1] and Castell Benito D[1]

[1]Department of Emergency,Torrejon University Hospital, Spain

***Corresponding author:** Miranda García M, Department of Emergency, Torrejon University Hospital. Mateo Inurria Street. Torrejón de Ardoz.28850, Spain, Tel: 654731010; E-mail: mariomiranda7@hotmail.es

Received: August 27, 2014; **Accepted:** November 01, 2014; **Published:** November 03, 2014

Abstract

Radiocontrast media (RCM) is a major cause of hypersensitivity reactions as the medical application of RCM is increasing recently1. The pathophysiology of most of immediate hypersensitivity reactions is poorly understood and it´s still under investigation. We present a clinical case and a review of immediate hypersensitivity reactions to RCM.

Keywords: Immediate reaction; Iodinated contrast media; Skin tests

Case Report

A 31 year-old man came to our emergency department because of epigastric and periumbilical pain in the right lower quadrant of the abdomen and nausea. In the physical examination the temperature was 37, 2º, his blood pressure was 120/80 mmHg, the pulse 90 beats per minute and the oxygen saturation 100%. Good general condition, well hydrated and perfused, eupneic Normal pharynx. No lymphadenopathies.Thyroid exploration within normal limits. Cardiac auscultation was rhythmic, no murmurs. Pulmonary auscultation showed vesicular murmur conserved. Abdominal exploration: tenderness on palpation in the right iliac fossa over the McBurney's point. The haemogram test showed leukocytosis (16.800 leucocytes) with neutrophilia. The creatinine was 1,1mg/dl. Acute appendicitis was suspected and urgent abdominal computerized tomography (CT) scan with intravenous contrast (iopromide) was done. Five minutes later it´s administration the patient started presenting generalized pruritus, urticaria (Figures 1,2) and slight edema of the uvula.

The patient was prescribed intravenous hydrocortisone 100 mg and intravenous polaramine 5 mg. The skin lesions persisted in abdomen and root of thighs (Figures 3,4). The patient was prescribed subcutaneous epinephrine 0, 4 cc.

A new blood test showed 21.000 leucocytes and the creatinine was elevated at 1, 6 mg/dl. The increase of leukocytes and the elevation of creatinine were considered as an adverse reaction to RCM.

Figure 1: Skin lesions in abdomen.

Figure 2: Skin lesions in abdomen.

Minutes after the administration of epinephrine the urticaria improved.

The abdominal CT scan revealed the presence of an inflammatory process in the right iliac fossa with an oedematous appendix.

The final diagnosis was immediate hypersensitivity reaction and renal toxicity to radiocontrast media, and acute appendicitis.

The patient was operated on of apendicitis. Two months later, in allergist evaluation with allergy tests, prick tests with iodinated contrast media were negative and the intradermal test was negative too.

Discussion

What authors have found in the review of literature is that the pathophysiology of most of immediate hypersensitivity reactions is poorly understood and it´s still under investigation. Immediate hypersensitivity reactions to RCM have traditionally been considered nonallergic; however, the increasingly frequent reporting of positive skin test and basophil activation test results suggest a specific allergic mechanism in some patients. The pathophysiology of IHRs is believed to be non IgE-mediated in the majority of cases, although a small percentage of these reactions may involve IgE. There are now several studies in which RCM- specific IgE antibodies have been demonstrated and it is possible that such reactions were underestimated in the past [2].

RCM is a major cause of hypersensitivity reactions as the medical

García et al. © All rights reserved

Citation: Miranda García M, Chico Civera R and Castell Benito D. Immediate Hypersensitivity Reaction to Radiocontrast Media. Austin J Allergy. 2014;1(3): 3.

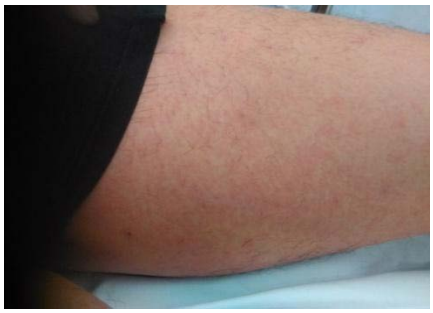

Figure 3: Skin lesions in root of thighs.

Figure 4: Skin lesions in root of thighs.

application of RCM is increasing recently: more than 70 million diagnostic radiographic examinations using RCM are performed worldwide each year, with at least 10 million in the United States alone [3].

Procedures using RCM include myelography, angiography (including cerebral arteriography), venography, urography, retrograde urography, endoscopic retrograde cholangiopancreatography (ERCP), artrography, and CT.

Adverse reactions to RCM are divided into two broad categories: chemotoxic reactions and hypersensitivity reactions. Chemotoxic reactions are related to the chemical properties of radiocontrast agents and are dependent upon dose and infusion rate. These include seizures, arrhythmias, and organ (especially renal) toxicity [4].

Hypersensitivity reactions are idiosyncratic and largely independent of dose and infusion rate [5] and can be further subdivided into immediate and delayed [6].

Immediate hypersensitivity reactions (IHRs) develop within one hour of administration, are seen most often in patients between 20 and 50 years of age [7] and can be clinically identical to IgE-mediated anaphylaxis and equally severe [8]. The majority of patients with immediate reaction present with pruritus and urticaria; sometimes angioedema occurs [9]. Signs and symptoms include: flushing, pruritus, urticaria, angioedema, bronchospasm and wheezing, laryngeal edema and stridor, hypotension and rarely shock or loss of consciousness.

The anaphylaxis symptoms are classified according to severity (Table 1) [10].

Atopic individuals (asthma, allergic rhinitis, atopic dermatitis or food allergies) are three times more likely than nonatopic individuals to have a severe adverse reaction.

All iodinated contrast materials in current use are chemical modifications of a 2,4,6-tri-iodinated benzene ring with different side chains in the 1,3 and 5 positions and different numbers of benzene rings.

The RCM are most commonly categorized by osmolality. High osmolal contrast material (HOCM) agents have osmolalities ≥ 1400 mosm/Kg and low osmolal contrast material (LOCM) agents have osmolalities between 500 and 900 mosm/Kg. The incidence of mild and moderate contrast reactions is higher for HOCM (6%–8%) than for LOCM (0.2%), but the incidence of severe reactions remains similar. Anaphylactoid reactions are more common while using HOCM [11].

The agents are subdivided in four categories based upon the charge of the iodinated molecule and the molecular structure: ionic monomers, ionic dimer (Ioxaglate), nonionic monomers (Iohexol, iopamidol, ioversol, iopromide, ioxilan), nonionic dimer (Iodixanol).

The diagnosis of an IHR is based upon the recognition of characteristic signs and symptoms. The role of skin testing and allergy evaluation for severe IHRs is controversial and it´s evolving. The authors and editors of Up To Date believe that the role of skin testing remains undefined because several important issues have not been adequately resolved.

Ideally, skin testing should be performed within two to six months of the original reaction, as the incidence of positive skin test appears to be lower before and after this time period.

Intradermal skin testing with RCM agents is the method of choice if skin testing is pursued. In contrast, the epicutaneous or prick method of skin testing is not sufficiently sensitive to detect agents causing immediate reactions.

In our case report the skin test was negative. Several groups have reported positive skin test results for patients with severe immediate reactions to eitherionic or non- ionic RCM. Some of these patients were shown to react not only to the skin test of the culprit CM but also to other CM.

Goksel et al. [12] reported positive skin tests results in 2 out of 14 patients with IHR. The frequency of positive skin tests has been investigated in a European multicenter study in patients with RCM hypersensitivity and in 82 controls [13]. The intradermal test (IDT) showed specificity in 96.3% of controls, but was positive in only 26% of patients. Another recent French prospective clinical study on 38 patients with immediate hypersensitivity reactions to RCM as determined by a reaction at the Radiology Department examined

Table 1: Grading system for generalized hypersensitivity reactions.

Grade	Defined by
1—Mild (skin and subcutaneous angioedematissues only)*	Generalized erythema, urticaria, periorbital edema, or angioedema
2—Moderate (features suggesting respiratory, cardiovascular, or gastrointestinal involvement)	Dyspnea, stridor, wheeze, nausea, vomiting, dizziness (presyncope), diaphoresis, chest or throat tightness, or abdominal pain.
3—Severe (hypoxia, hypotension, or neurologic compromise)	Cyanosis or SpO2 ≤ 92% at any stage, hypotension (SBP < 90 mm Hg in adults), confusion, collapse, LOC, or incontinence

SBP, Systolic blood pressure; LOC, loss of consciousness.
*Mild reactions can be further subclassified into those with and without angioedema.

clinical data, serum and plasma analysis of tryptase and histamine as well as skin test reactivity to RCM [14]. In this study employing higher (undiluted) RCM concentrations, positive skin test reactions were even found in 73% of patients. Patients with more severe reactions had more positive skin test reactions and higher plasma histamine and tryptase levels after the reaction.

It has not been established that a negative skin test result can reliably predict that the patient will tolerate the RCM in question, although at present, there is no other way to assess this.

The optimal concentration for intradermal skin testing has not been determined. A 1:10 dilution was recommended by the 2013 European Network on Drug Allergy and European Academy of Allergy and Clinical Immunology (ENDA/EAACI) position paper [15].

Several premedication regimens have demonstrated efficacy in preventing recurrent IHR´s of patients with previous IHR´s. Premedication using prednisone and diphenhydramine reduces the rate of breakthrough reactions from 17 to 60 percent, down to 9 percent [16].

Epinephrine is the drug of choice for anaphylaxis. The usual dosage of epinephrine for adults is 0, 3- 0, 5 mg of a 1:1000 w/v solution given intramuscularly every 10-20 minutes or as necessary. The dose for children is 0, 01 mg/kg to a maximum of 0, 3 mg intramuscularly every 5-30 minutes as necessary.

Conclusions

The pathophysiology of most of immediate hypersensitivity reactions is poorly understood and it´s still under investigation.

Skin tests have been proposed as a useful tool for diagnosis, although their sensitivity and predictive values remain to be determined.

References

1. Lee SY, Lim KW, Chang YS. Radiocontrast media hypersensitivity in the Asia Pacific region. Asia Pac Allergy. Apr 2014; 4: 119–125.
2. Trcka J, Schmidt C, Seitz CS. Anaphylaxis to iodinated contrast material: nonallergic hypersensitivity or IgE-mediated allergy? AJR Am J Roentgenol 2008; 190: 666-670.
3. Christiansen C. X-ray contrast media-an overview- Toxicology 2005; 209: 185-187.
4. Fischer HW, Doust VL. An evaluation of pretesting in the problem of serious and fatal reactions to excretory urography. Radiology 1972; 103: 497-501.
5. Federle MP, Willis LL, Swanson DP. Ionic versus nonionic contrast media: a prospective study of the effect of rapid bolus injection on nausea and anaphylactoid reactions. J Comput Assist Tomogr 1998; 22: 341-345.
6. Brockow K, Christiansen C, Kanny G, Clément O, Barbaud A, et al. Management of hypersensitivity reactions to iodinated contrast media. Allergy 2005; 60: 150-158.
7. Joint Task Force on Practice Parameters, American Academy of Allergy, Asthma and Immunology, American College of Allergy, Asthma and Immunology, Joint Council of Allergy, Asthma and Immunology. The diagnosis and management of anaphylaxis: an updated practice parameter. J Allergy Clin Immunol 2005; 115: S483-S523.
8. Hagan JB. Anaphylactoid and adverse reactions to radiocontrast agents. Immunol Allergy Clin North Am 2004; 24: 507-519.
9. Brockow K, Ring J: Classification and pathophysiology of radiocontrast media hypersensitivity. Chem Immunol Allergy 2010; 95: 157–169.
10. Brown SG. Clinical features and severity grading of anaphylaxis. J Allergy Clin Immunol 2004; 114: 371-376.
11. Cochran ST, Bomyea K, SayreJW. Trends in adverse events after IVadministration of contrast media. AJR Am J Roentgenol. 2001; 176: 1385–1388.
12. Goksel O, Aydin O, Atasoy C, Akyar S, Demirel YS, et al. Hypersensitivity reactions to contrast media: prevalence, risk factors, and the role of skin tests in diagnosis –a cross-sectional survey. Int Arch Allergy Immunol. 2011; 155: 297-305.
13. Brockow K, Romano A, Aberer W. Skin testing in patients with hypersensitivity reactions to iodinated contrast media – a European multicenter study. Allergy 2009; 64: 234–241.
14. Dewachter P, Laroche D, Mouton- Faivre C. Immediate reactions following iodinated contrast media injection: a study of 38 cases. Eur J Radiol 2011; 77: 495–501.
15. Brockow K, Garvey LH, Aberer W. Skin test concentrations for systemically administered drugs – an ENDA/EAACI Drug Allergy Interest Group position paper. Allergy 2013; 68: 702-712.
16. Greenberger PA, Patterson R, Radin RC. Two pretreatment regimens for high-risk patients receiving radiographic contrast media. J Allergy Clin Immunol 1984; 74: 540-543.

Austin J Allergy - Volume 1 Issue 3 - 2014
Submit your Manuscript | www.austinpublishinggroup.com
García et al. © All rights reserved

Citation: Miranda García M, Chico Civera R and Castell Benito D. Immediate Hypersensitivity Reaction to Radiocontrast Media. Austin J Allergy. 2014;1(3): 3.