Long-term Treatment of Severe Recalcitrant Atopic Dermatitis with Omalizumab, an Anti-immunoglobulin E

Sven R. Quist*, Andreas Ambach*, Daniela Göppner, Jennifer Quist, Ingolf Franke, Bernd Bonnekoh and Harald P. M. Gollnick
Department of Dermatology and Venereology, Otto-von-Guericke University, Leipziger Str. 44, DE-39120 Magdeburg, Germany. E-mail: squist@gmx.de
**Both authors contributed equally to the manuscript and should be considered as first authors.*
Accepted May 21, 2012.

Atopic dermatitis (AD) is a multifactorial, predisposed, chronic inflammatory and pruritic skin disease often associated with allergic asthma (AA) and/or rhinoconjunctivitis (AR) (1). Treatment of patients with AD with the humanized antibody omalizumab (Xolair®, Novartis, Nuremberg, Germany), which is also effective in AA, AR, urticaria and mastocytosis (2), has resulted in either improvement or treatment failure (3–5). The underlying mechanism in AD patients with high serum immunoglobulin E (IgE) levels remains unclear (3, 5). We report here a case of long-term treatment of AD with omalizumab.

CASE REPORT

A 53-year-old man presented in June 2005 with chronic and relapsing severe exacerbated AD of the extremities, face, chest and upper back. His lower arms and legs displayed highly pruritic erythematous lichenoid papules in a linear orientation that had been directly induced by scratching (Fig. 1a). His AD had begun in childhood and was further exacerbated at 35 years of age due to the presence of continuous lymphadenopathy and frequent bacterial and viral skin superinfections. He also had early onset allergic rhinoconjunctivitis and severe asthma with forced expiratory volume in one second 25% and lung emphysema characterized by α-1 antitrypsin deficiency. Skin-prick tests and radioallergosorbent testing-confirmed type-I sensitivity against pollen (birch, hazel, alder, mugwort and rye), dust mites, epithelia (from horse, cat and dog), *Pityrosporom*, latex, milk and codfish protein. Specific IgE to relevant allergens represented <1% of the total IgE. AD flared up when exposed to seasonal aeroallergens. Skin-patch tests revealed contact allergies against cocamidopropyl betaine and sorbitan sesquioleate. Ultraviolet (UV) provocation revealed UVA and UVB hypersensitivity. IgE serum levels were persistently elevated (>15,000 kU/l). His family history was positive for asthma but negative for AD. The patient continuously took various anti-histamines, fluticasone/salmeterol and theophylline and applied topical steroids daily.

Years of systemic therapy with prednisolone or cyclosporine had not sustainably improved the patient's condition or prevent flare-ups. Microbiological analysis confirmed repeated superinfections with *Staphylococcus aureus* and/or herpes simplex virus (HSV)-1, which were treated with local antiseptics and/or systemic antibiotics/antivirals. In 2005, dermatohistopathology excluded lichen planus, lichen amyloidosis, other deposition dermatoses, plasmacytoma, IgE-lymphoma, mastocytosis and cutaneous T-cell lymphoma (CTCL). The same analysis re-confirmed AD (Fig. 1b and 1c). Sonography revealed inflammatory, reactive lymph nodes (dermatopathic lymphadenopathy). Increased serum levels of tumour necrosis factor (TNF)-α and a CD4/CD8 ratio of 4 were detected. Serum protein electrophoresis and quantitative measurements excluded monoclonal gammopathy.

Due to insufficient efficacy, cyclosporine treatment was tapered, and extracorporeal photopheresis (ExP) was employed biweekly. After 4 cycles of ExP, the condition of the patient's skin improved significantly. ExP intervals were prolonged for 1 week until cycle 10 and again for 1 week until cycle 19. SCORAD (SCORing Atopic Dermatitis) dropped from 80 to 40 within 8 months (10 ExP-cycles), but no further improvement occurred thereafter. The clinical course and paraclinical parameters are illustrated schematically in Fig. 2.

Therefore, anti-IgE treatment was initiated during the 14th cycle of ExP, with 150 mg omalizumab (Xolair®) subcutaneously (s.c.) every 4 weeks. The dosage was increased to 300 mg s.c. every 2 weeks, when ExP was stopped after 15 months of treat-

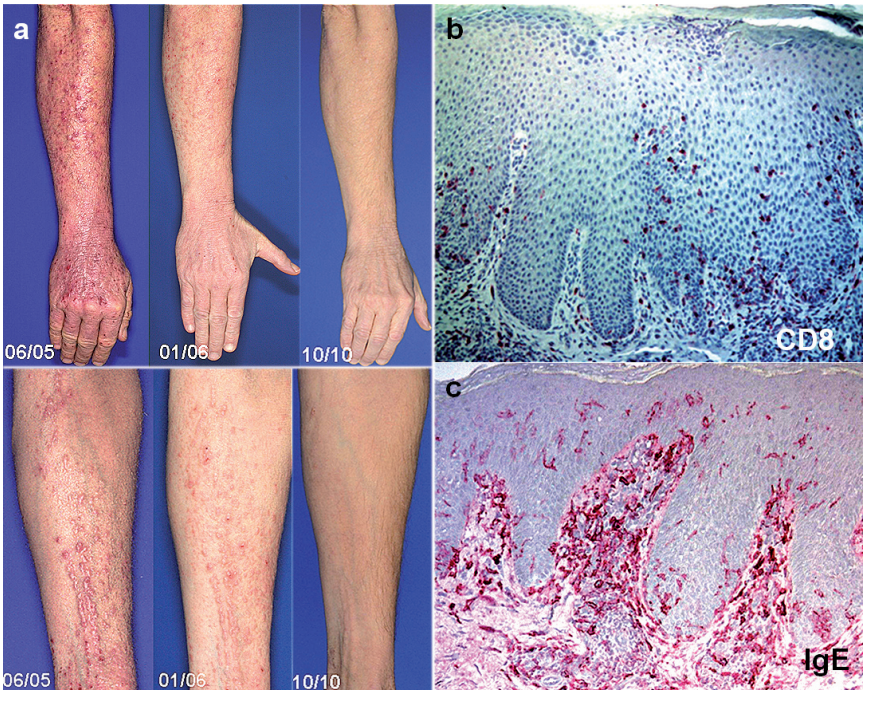

Fig. 1. (a) Highly pruritic lichenoid papules in linear orientation (koebnerization), painful rhagades, excoriations and infiltrated hyperkeratosis of the hands with massive inflammatory swelling (06/05). Improvement was observed after increasing the dose of omalizumab (11/06). Linear lichenoid papules on the forearms disappeared completely after long-term omalizumab treatment (10/10). (b) and (c): Representative examples of a biopsy of the lower ventral arm: immunohistology employing monoclonal antibodies against CD8 (b) and IgE (c). Most of the lymphocytes infiltrating the epidermis expressed CD8; most of the dendritic cells were covered with IgE.

© 2012 The Authors. doi: 10.2340/00015555-1442
Journal Compilation © 2012 Acta Dermato-Venereologica. ISSN 0001-5555

ment, and was further increased to 375 mg/s.c. biweekly 5 months later. This resulted in long-term stabilization and finally complete remission with clearance of the marked lichenoid papules from the extremities (Fig. 1). From January to October 2010, the dosage was reduced to 300 mg s.c. every 2 weeks, followed by a further reduction to 300 mg every 4 weeks in October 2010.

The phase of combined ExP and omalizumab treatment was well tolerated. The flare-up periods induced by aeroallergens disappeared. The last herpes virus superinfection occurred in November 2006. Topical steroid consumption decreased by 90%, so class III steroids were replaced with class II steroids and further substituted with pimecrolimus. The dosage of systemic antihistamines was also reduced 3- to 4-fold.

Serum tryptase levels normalized (from 33.5 to 13.2 µg/l) during treatment (Fig. 2). The levels of eosinophilic cationic protein (ECP, 65.7 µg/l) and blood eosinophils (19%) dropped during ExP, relapsed at the end of ExP and normalized again during anti-IgE therapy (ECP 3.49 µg/l; eosinophils 3%). IgE-serum levels rose after the initiation of omalizumab treatment (due to formation of omalizumab/IgE complexes, which have a slower elimination rate than free IgE) and finally reached a maximum at the end of 2007 (22,357 kU/l). This trend was then dramatically reversed; in November 2010, the lowest IgE-level (10,112 kU/l) in over 15 years was recorded (Fig. 2).

In our patient, ExP was employed as a third-line therapy after severe exacerbations during classic immunosuppressive AD treatment with corticosteroids and/or cyclosporine. SCORAD levels dropped to approximately 50% of initial values within 10 cycles of ExP without further improvement. This case report confirms 2 open trials with 42 ExP-treated AD patients. Only 3 out of 18 AD patients who required ExP treatment >20 weeks showed complete remission. ExP non-responders displayed higher levels of IgE (>10,000 kU/l) (literature reviewed in Table SI available from available from http://www.medicaljournals.se/acta/content/?doi=10.2340/00015555-1442).

DISCUSSION

Fifty-four out of 75 omalizumab-treated AD patients reported in the literature showed a positive clinical response, but only 10 of them achieved complete remission. Among 10 AD patients who were comparable to our case regarding severity and IgE level, 5 benefited from omalizumab therapy. They were treated with 150–450 mg omalizumab biweekly for up to 20 weeks. None of them achieved complete remission. Our patient did not respond to low-dose anti-IgE treatment and failed to display a significant reduction in SCORAD for almost one year. Omalizumab at 300 and 450 mg in a biweekly alteration regimen led to a continuous and long-lasting clinical improvement with a reduced need for systemic or topical medication over the next 5 years. Paraclinical parameters also declined, in contrast to previously reported findings.

The mechanism by which omalizumab modulates skin inflammation remains unclear. In patients with allergic rhinoconjunctivitis and/or asthma, anti-IgE treatment is most effective if allergen-specific IgE levels are < 1% of the total IgE level that is treated with recommended doses (6). In AD, clinical improvement does not seem to completely depend on total IgE levels (7, 8). In our case, ExP, which is known to enhance the regulatory T-lymphocyte network (9), could have suppressed the immune dysregulation. Furthermore, the interference of omalizumab with the IgE receptor systems and/or the immunocomplex-degrading network could have further downregulated the AD immune response including IgE-secreting plasma cells (10). The normalization of serum tryptase indicates the influence of omalizumab on the basophil/mast cell system (2). Furthermore, allergen-specific IgE levels could have been sufficiently inactivated by high doses of anti-IgE treatment.

In conclusion, the combination of ExP and omalizumab may be an interesting option for the treatment of severe, recalcitrant AD in patients with severe asthma, even in those with high levels of serum IgE. Long-term anti-IgE treatment was safe in our patient and may be considered as part of a multi-factorial therapeutic concept.

Conflicts of interest. A.A. received a research grant from Novartis in 2010 and has given invited talks sponsored by this company. The other authors declare no conflicts of interest.

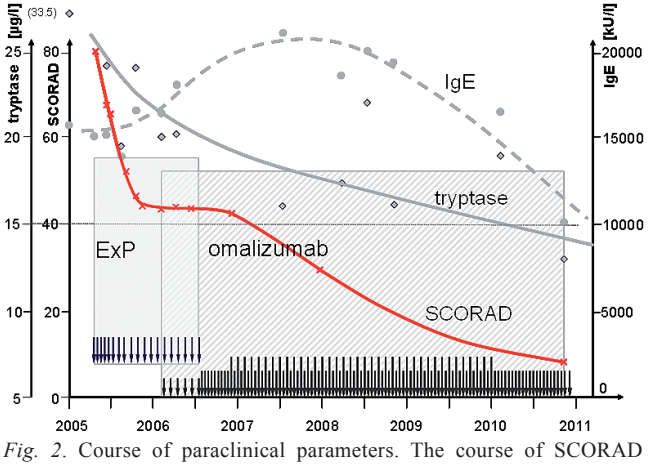

Fig. 2. Course of paraclinical parameters. The course of SCORAD (SCORing Atopic Dermatitis) (*crosses*) compared with the serum levels of immunoglobulin E (IgE) (*circles*) and tryptase (*diamonds*). The arrows and hatched boxes indicate administration of extracorporeal photopheresis (ExP) and omalizumab, respectively.

REFERENCES

1. Bieber T. Atopic dermatitis. N Engl J Med 2008; 358: 1483–1494.
2. Carter MC, Robyn JA, Bressler PB, Walker JC, Shapiro GG, Metcalfe DD. Omalizumab for the treatment of unprovoked anaphylaxis in patients with systemic mastocytosis. J Allergy Clin Immunol 2007; 119: 1550–1551.
3. Belloni B, Ziai M, Lim A, Lemercier B, Sbornik M, Weidinger S, et al. Low-dose anti-IgE therapy in patients with atopic eczema with high serum IgE levels. J Allergy Clin Immunol 2007; 120: 1223–1225.
4. Heil PM, Maurer D, Klein B, Hultsch T, Stingl G. Omalizumab therapy in atopic dermatitis: depletion of IgE does not improve the clinical course – a randomized, placebo-controlled and double blind pilot study. J Dtsch Dermatol Ges 2010; 8: 990–998.
5. Krathen RA, Hsu S. Failure of omalizumab for treatment of severe adult atopic dermatitis. J Am Acad Dermatol 2005; 53: 338–340.

6. Johansson SG, Nopp A, Oman H, Ankerst J, Cardell LO, Gronneberg R, et al. The size of the disease relevant IgE antibody fraction in relation to 'total-IgE' predicts the efficacy of anti-IgE (Xolair) treatment. Allergy 2009; 64: 1472–1477.
7. Vigo PG, Girgis KR, Pfuetze BL, Critchlow ME, Fisher J, Hussain I. Efficacy of anti-IgE therapy in patients with atopic dermatitis. J Am Acad Dermatol 2006; 55: 168–170.
8. Lane JE, Cheyney JM, Lane TN, Kent DE, Cohen DJ. Treatment of recalcitrant atopic dermatitis with omalizumab. J Am Acad Dermatol 2006; 54: 68–72.
9. Xia CQ, Campbell KA, Clare-Salzler MJ. Extracorporeal photopheresis-induced immune tolerance: a focus on modulation of antigen-presenting cells and induction of regulatory T cells by apoptotic cells. Curr Opin Organ Transplant 2009; 14: 338–343.
10. Lowe PJ, Renard D. Omalizumab decreases IgE production in patients with allergic (IgE-mediated) asthma; PKPD analysis of a biomarker, total IgE. Br J Clin Pharmacol 2011; 72: 306–320.
11. Hjuler KP, Vestergaard C, Deleuran M. A retrospective study of six cases of severe recalcitrant atopic dermatitis treated with long-term extracorporeal photopheresis. Acta Derm Venereol 2010; 90: 635–636.
12. Sand M, Bechara FG, Sand D, Radenhausen M, Tomi NS, Altmeyer P, et al. Extracorporeal photopheresis as a treatment for patients with severe, refractory atopic dermatitis. Dermatology 2007; 215: 134–138.
13. Radenhausen M, Michelsen S, Plewig G, Bechara FG, Altmeyer P, Hoffmann K. Bicentre experience in the treatment of severe generalised atopic dermatitis with extracorporeal photochemotherapy. J Dermatol 2004; 31: 961–970.
14. Radenhausen M, von Kobyletzki G, Höxtermann S, Altmeyer P, Hoffmann K. Activation markers in severe atopic dermatitis following extracorporeal photochemotherapy. Acta Derm Venereol 2003; 83: 49–50.
15. Prinz B, Nachbar F, Plewig G. Treatment of severe atopic dermatitis with extracorporeal photopheresis. Arch Dermatol Res 1994; 287: 48–52.
16. Richter HI, Billmann-Eberwein C, Grewe M, Stege H, Berneburg M, Ruzicka T, et al. Successful monotherapy of severe and intractable atopic dermatitis by photopheresis. J Am Acad Dermatol 1998; 38: 585–588.
17. Costa C, Rilliet A, Nicolet M, Saurat JH. Scoring atopic dermatitis: the simpler the better? Acta Derm Venereol 1989; 69: 41–45.