Original Article

Gene Expression Patterns in Distinct Endoscopic Findings for Eosinophilic Gastritis in Children

Masamichi Sato, MD[a,b,*], Tetsuo Shoda, MD, PhD[c,d,*], Hirotaka Shimizu, MD[a], Kanami Orihara, PhD[c,e], Kyoko Futamura, MD, PhD[c], Akio Matsuda, PhD[c], Yoshiyuki Yamada, MD, PhD[f], Rie Irie, MD, PhD[g], Takako Yoshioka, MD, PhD[g], Toshiaki Shimizu, MD, PhD[b], Yukihiro Ohya, MD, PhD[d], Ichiro Nomura, MD, PhD[c,d], Kenji Matsumoto, MD, PhD[c], and Katsuhiro Arai, MD, PhD[a] *Tokyo and Gunma, Japan*

What is already known about this topic? Patients with eosinophilic gastritis (EG), characterized by both gastric eosinophilia and clinical symptoms, also often show variable endoscopic findings. However, a relationship between endoscopic findings and the pathophysiological process responsible for EG remains underinvestigated.

What does this article add to our knowledge? Transcriptome from patients with EG from different groups were enriched in the substantially overlapping genes, despite endoscopic morphological differences such as ulcerative or nodular lesions. This suggests that there are shared allergic inflammatory response pathways.

How does this study impact current management guidelines? Our study showed no major differences in distinct endoscopic findings for EG, from the viewpoint of gene expression patterns. This suggests that these phenotypes may be variations of a single disease.

BACKGROUND: Eosinophilic gastritis (EG) is clinicopathologically characterized by both marked gastric eosinophilia and clinical symptoms. The endoscopic findings in EG vary among patients, leading to clinical confusion. However, little is known about the relationship between precise endoscopic findings and the pathophysiological process responsible for EG.

OBJECTIVE: We aimed to elucidate whether the gross endoscopic findings of EG can be classified into distinct gene expression profiles.

METHODS: We enrolled pediatric patients who underwent gastrointestinal endoscopy for clinical symptoms suggestive of eosinophilic gastrointestinal disorder between 2011 and 2016. EG was diagnosed when gastric eosinophilia was greater than or

[a]Division of Gastroenterology, National Center for Child Health and Development, Tokyo, Japan
[b]Department of Pediatrics, Juntendo University Graduate School of Medicine, Tokyo, Japan
[c]Department of Allergy and Clinical Immunology, National Research Institute for Child Health and Development, Tokyo, Japan
[d]Division of Allergy, National Center for Child Health and Development, Tokyo, Japan
[e]Waseda Institute for Advanced Study, Waseda University, Tokyo, Japan
[f]Division of Allergy and Immunology, Gunma Children's Medical Center, Gunma, Japan
[g]Department of Pathology, National Center for Child Health and Development, Tokyo, Japan

This work was funded by Health and Labor Sciences Research Grants, Research on Intractable Diseases, from the Ministry of Health, Labour and Welfare, Japan (grant no. 12103036 to I.N.), and grants from the Agency for Medical Research and Development, Japan (grant no. 27280401 to I.N. and grant no. 27280301 to K.M.).

Conflicts of interest: T. Shoda has received research support from Grant-in-Aid for Young Scientists (B), Kawano Masanori Memorial Public Interest Incorporated Foundation for Promotion of Pediatrics, and Yakult Bio-Science Foundation. K. Orihara is employed by Waseda University and has received research support from the Japan Society for the Promotion of Science. K. Futamura is employed by the National Research Institute for Child Health and Development. Y. Yamada has received research support from the Ministry of Health, Labour and Welfare, Japan (grant no. H26-Nanchi-Ippan-048 to I.N. and Y.Y.), and Grant-in-Aid for Scientific Research C from the Ministry of Education, Culture, Sports, Science and Technology of Japan (grant nos. 24592702 and 16K11358 to Y.Y.); has received lecture fees from the Japanese Society of Food Allergy and MSD Co Ltd; and has received payment for manuscript preparation from Tokyo Igakusha, Sentan Igaku-sha, Chindan To Chiryou, and Igaku-Shoin. Y. Ohya is employed by the National Center for Child Health and Development; has received research support from the Ministry of Health, Labour and Welfare, the Ministry of Environment, and Japan Agency for Medical Research and Development; has received lecture fees from Maruho, Merck Sharp and Dohme, Kyorin Pharmaceutical, Kyowa Hakko Kirin, Sysmex, Shiseido, and GlaxoSmithKline. I. Nomura has received research support from the Agency for Medical Research and Development, Japan (grant no. 27280401). K. Matsumoto is employed by the National Research Institute for Child Health and Development and has received lecture fees from Merck Sharp and Dohme, Kyorin Pharmaceutical, AstraZeneca, Maruho, Teijin Pharma, and Chugai Pharmaceutical. K. Arai has received research support from the Ministry of Health, Labour and Welfare, Japan (grant no. 12103036 to I.N.), from the Agency for Medical Research and Development, Japan (grant no. 27280401 to I.N. and grant no. 27280301 to K.M.), Japan Agency for Medical Research and Development, and the National Grant-in-Aid for National Center for Child Health and Development (27-12); and has received lecture fees from EA Pharma Co Ltd, Mitsubishi Tanabe Pharma Corporation, Mochida Pharmaceutical Co Ltd, AbbVie GK, Eisai Co Ltd, and Ajinomoto Pharmaceuticals Co Ltd. The rest of the authors declare that they have no relevant conflicts of interest.

Received for publication September 30, 2016; revised February 21, 2017; accepted for publication March 17, 2017.

Available online May 16, 2017.

Corresponding author: Tetsuo Shoda, MD, PhD, Division of Allergy, National Center for Child Health and Development, 2-10-1 Okura, Setagaya-ku, Tokyo 157-8535, Japan. E-mail: shoda-t@ncchd.go.jp or arai-k@ncchd.go.jp.

* These authors contributed equally to this work.

2213-2198

© 2017 American Academy of Allergy, Asthma & Immunology

http://dx.doi.org/10.1016/j.jaip.2017.03.030

Abbreviations used
CCL26- C-C chemokine ligand 26
EG- Eosinophilic gastritis
EGID- Eosinophilic gastrointestinal disorder
GI- Gastrointestinal
GO- Gene ontology
IQR- Interquartile range

equal to 30 eosinophils/hpf. The gene expression profiles of gastric biopsies were assessed using microarray technology. RESULTS: Patients with EG and control subjects (n = 8, each) were examined. On the microarray, 1,999 genes were differentially expressed between EG and the controls (≥2-fold difference, adjusted *P* value < .05), including significant upregulation of eotaxin-3 (*C-C chemokine ligand 26*). The endoscopic findings of patients with EG fell roughly into 2 types, namely, ulcerative and nodular lesions. Despite identifying distinct patterns of gene expression, most differentially regulated genes overlapped between the 2 endoscopic finding types. Several gene ontology terms were enriched in the substantially overlapped genes, but not in each of the distinct genes. CONCLUSIONS: Our results strongly indicate that ulcerative and nodular lesions are a single disease, EG, or a variation thereof, in spite of morphological differences. Our findings may contribute to a better understanding of the pathogenesis of EG, as well as to more accurate diagnosis of this disease. **© 2017 American Academy of Allergy, Asthma & Immunology** **(J Allergy Clin Immunol Pract 2017;5:1639-49)**

Key words: *Children; Endoscopy; Eosinophilic gastritis; Eosinophils; Microarray*

Eosinophilic gastritis (EG) is a member of the spectrum of diseases collectively referred to as eosinophilic gastrointestinal disorders (EGIDs), characterized by massive eosinophilic infiltration into the gastrointestinal (GI) tract.[1-5] According to the recently proposed criteria for EG in 2011,[6] diagnosis of EG requires both clinical symptoms and histological evidence of significant gastric eosinophilia (≥30 eosinophils/hpf), whereas endoscopic findings are not essential. Indeed, the endoscopic findings in EG vary among patients, and are known to include nodularity, erythema, erosion, and ulcerative lesions.[7-10] However, little is known about the relationship between precise endoscopic findings and the pathophysiological process responsible for EG.

Previously, Caldwell et al[11] performed comprehensive mRNA microarray analysis and demonstrated that gastric biopsy specimens of patients with EG showed markedly increased expression of mRNA for eotaxin-3/*C-C chemokine ligand 26* (*CCL26*), which plays a crucial effector role in EG's pathogenesis. Although the endoscopic findings of EG are known to be variable, as described above, 80% of the patients in Caldwell et al's microarray study had EG with nodular lesions.

In this context, to clarify the clinical reason for developing certain endoscopic findings of EG, we investigated whether the gross endoscopic findings of EG can be classified into differential gene expression profiles. In addition, to elucidate the mechanisms involved, we performed microarray analysis under the grouping of endoscopic findings for EG.

METHODS

Study design and population

We prospectively enrolled pediatric patients who underwent upper and/or lower GI endoscopy for clinical symptoms suggestive of EGID at the National Center for Child Health and Development, Tokyo, Japan, between April 2011 and March 2016. Diagnosis of EG was based on the presence of marked, diffuse, eosinophilic infiltrates with greater than or equal to 30 eosinophils/hpf in the gastric antrum and/or body according to the standardized criteria for EG.[12-14] Although evaluation of 5 hpfs is advocated, we defined EG as 30 or more eosinophils in at least 1 hpf as the cutoff point in this study to minimize the number of biopsies for patients' safety reason. Other causes of eosinophilic infiltration, such as *Helicobacter pylori* infection, parasitic infection, and inflammatory bowel disease, were excluded on the basis of the endoscopic, histological, and microbiological findings. Control subjects were those who underwent upper GI endoscopy for a suspected functional GI disorder and had no histological findings consistent with EGID.

Endoscopic and histological evaluation

During the GI endoscopies, multiple mucosal biopsies were obtained from various sections of the upper GI tract (second portion of the duodenum, duodenal bulb, gastric antrum, gastric body, and lower esophagus). Biopsied samples were placed into RNA later® solution (QIAGEN, Valencia, Calif) at room temperature and stored at −80°C until gene expression profiling. All endoscopic images were independently reviewed by 2 gastroenterologists (H.S. and K.A.) and classified as ulcerative or nodular when consensus was achieved.

Regarding histological evaluation, hematoxylin and eosin−stained biopsy slides from all patients were reviewed by 2 board-certified pathologists (R.I. and T.Y.) and results were confirmed when both agreed to them. Biopsy slides were screened with the microscope at low magnification (×100) for the highest eosinophil concentration, and then the eosinophils were counted in 1 to 5 hpfs (×400). The site of eosinophilic infiltration, eosinophilic cryptitis, and architectural distortion were also evaluated as associated findings. In addition, pathology reports and slides were reviewed for any concurrent tissue eosinophilia in the esophagus, duodenum, and colon.

Microarray analysis of gene expression

As described previously,[15] microarray analysis (Agilent Technologies, Santa Clara, Calif) was performed according to the manufacturer's instructions. Briefly, total RNA was extracted using an RNeasy Micro kit (Qiagen) and then evaluated with an Agilent Bioanalyzer and an RNA 6000 Nano kit (Agilent Technologies). The gene expression profiles were assessed using microarray technology with Agilent SurePrint G3 Human GE 8 x 60k. Data analyses, including gene ontology (GO) analysis and gene set enrichment analysis, were performed using GeneSpring software version 12.5 (Agilent Technologies). To normalize variation in the staining intensity between microarrays, the average difference for all genes on a given microarray was divided by the median of all measurements on the microarray. Genes in the EG or control subjects that showed a significant difference in signal intensity compared with the same genes in the controls ($P < .05$, *t* test with false-discovery rate correction) were classified as upregulated or downregulated. Benjamini and Hochberg methods were used for multiple correction tests throughout the microarray analyses. Hierarchical clustering was

TABLE I. Summary of patients' characteristics

Patient no.	Diagnosis	Sex	Age at diagnosis (y)	Symptoms	History of allergy	Blood eosinophil count (/μL)	Total IgE (IU/mL)	Medication at endoscopy	Diet at endoscopy
1	EG	M	13	Abdominal pain, vomiting, diarrhea, anemia	None	650	141	H2RA	Elimination (wheat)
2	EG	F	14	Abdominal pain, vomiting, anemia	FA	660	279	None	None
3	EG	M	13	Abdominal pain, vomiting, anemia	BA, AD, FA	1,650	10,255	PPI	Elimination (peanuts)
4	EG	M	10	Abdominal pain, diarrhea, anemia	BA, AD, FA	1,620	3,537	None	None
5	EG	F	8	Abdominal pain, vomiting, diarrhea	BA, FA	410	65.7	None	None
6	EG	F	10	Abdominal pain, vomiting, diarrhea	BA	300	1,390	LTRA, H1RA	None
7	EG	M	8	Abdominal pain, vomiting, diarrhea	BA, AD, FA	200	1,010	H1RA	Elimination (egg)
8	EG	M	1	Vomiting	AD, FA	2,550	143	None	Elimination (egg, cow's milk)
9	CTRL	M	7	Abdominal pain, diarrhea	BA, FA	170	922	LTRA, H1RA, PPI	None
10	CTRL	M	15	Abdominal pain	BA, FA	550	1,498	PPI, H1RA	None
11	CTRL	M	7	Abdominal pain	BA, AD	450	505	H2RA, H1RA	None
12	CTRL	M	7	Abdominal pain	None	230	NA	PPI, H2RA	None
13	CTRL	M	17	Diarrhea	None	300	NA	None	None
14	CTRL	M	9	Diarrhea	None	450	14.1	None	None
15	CTRL	M	1	Vomiting	AD, FA	100	469	None	Elimination (multiple)
16	CTRL	M	9	Abdominal pain	AD, FA	220	327	H2RA	Elimination (multiple)

AD, Atopic dermatitis; *CTRL*, control; *BA*, bronchial asthma; *F*, female; *FA*, food allergy; *H1RA*, H1 receptor antagonist; *H2RA*, H2 receptor antagonist; *LTRA*, leukotriene receptor antagonist; *M*, male; *NA*, not assessed; *PPI*, proton pump inhibitor.

TABLE II. Endoscopic findings and quantitative evaluation of tissue eosinophils in the GI mucosa

		Endoscopic findings				Histological findings									
						Gastric tissue eosinophil count (eosinophils/hpf)*					Other histologic findings of stomach		Peak tissue eosinophil count (eosinophils/hpf)* of other GI tract		
Patient no.	Diagnosis	Esophagus	Stomach	Duodenum	Colon	Antrum (1)	Antrum (2)	Angularis	Body	Fundus	Eosinophilic cryptitis	Architectual distortion	Esophagus	Duodenum	Colon
1	EG	NA	Nodular lesion	Erosion	–	40	–	–	33	–	–	–	0	23	–
2	EG	NA	Nodular lesion	NA	NA	50	–	–	–	–	–	–	0	1	1
3	EG	NA	Erosion, ulcer	Ulcer	NA	76	–	140	127	135	–	–	11	75	35
4	EG	NA	Nodular lesion	NA	–	170	–	153	166	90	–	–	0	4	–
5	EG	NA	Ulcer	Erosion, ulcer	–	105	–	–	70	–	–	–	0	48	–
6	EG	NA	Ulcer	Edema	NA	165	–	170	160	–	–	–	5	0	2
7	EG	NA	Nodular lesion	Erythema	NA	40	125	133	179	177	+	–	17	14	15
8	EG	Erythema	Erosion, ulcer	Edema, erythema	NA	31	–	–	–	–	–	–	3	35	22
9	CTRL	NA	Hiatal hernia	Erosion	NA	0	–	–	5	–	–	–	0	0	10
10	CTRL	NA	Hiatal hernia	NA	–	7	–	–	12	–	–	–	0	0	–
11	CTRL	NA	NA	NA	–	0	–	–	1	–	–	–	0	5	–
12	CTRL	NA	Erythema	Erythema	–	0	1	–	0	0	–	–	0	6	–
13	CTRL	NA	NA	NA	–	0	–	–	0	–	–	–	0	0	–
14	CTRL	NA	NA	NA	Polyp	2	–	–	3	–	–	–	0	4	0
15	CTRL	NA	NA	NA	NA	0	–	–	0	–	–	–	0	3	6
16	CTRL	NA	Erythema	NA	–	0	–	–	0	–	–	–	0	0	–

CTRL, Control; *NA*, normal appearance.

*The areas of the GI biopsy with the densest eosinophil infiltration were identified, and the number of eosinophils in 400× hpf in these areas were counted.

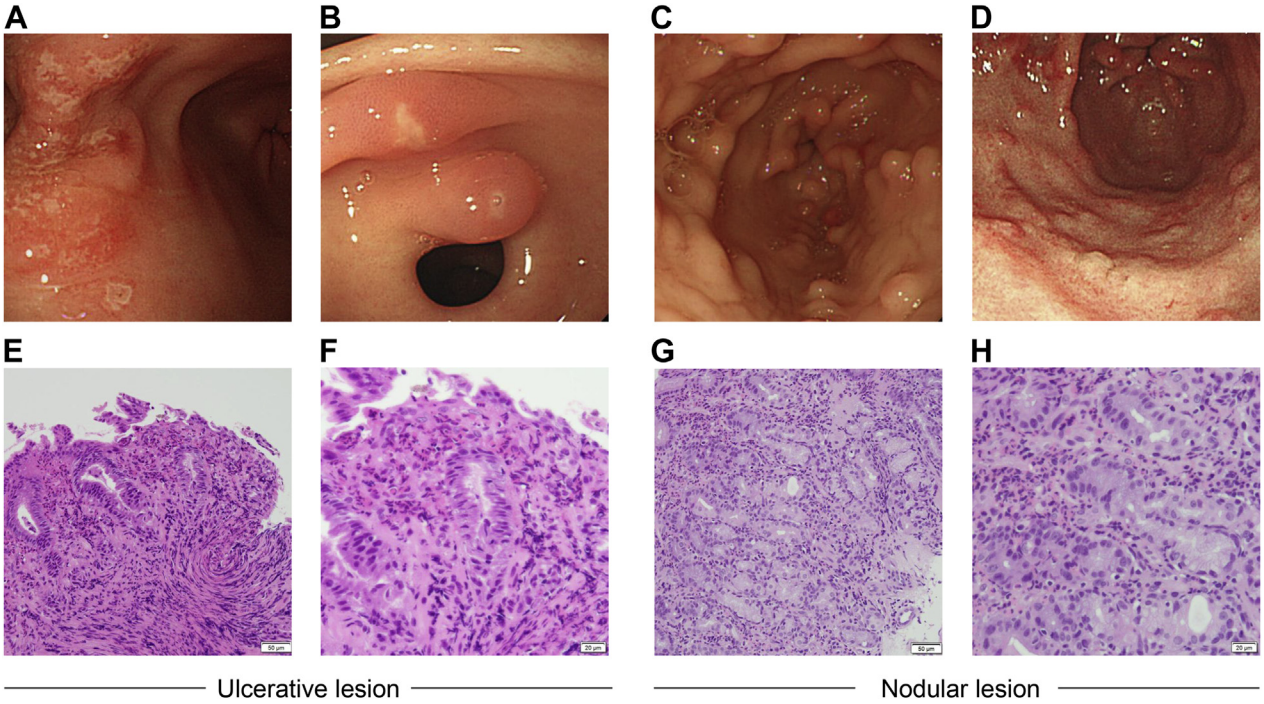

FIGURE 1. Endoscopic and histological findings in patients with EG. **A**, Multiple ulcers over gastric angle (patient no. 3). **B**, Erosive lesions with polypoid change on gastric antrum (patient no. 5). **C**, Marked nodular lesion on gastric antrum (patient no. 2). **D**, Marked nodularity with diffuse erythema over gastric antrum to body (patient no. 7). **E**, **F**, **G**, and **H**, Gastric mucosa of patients with EG (Figure 1, *E* and *F*; patient 3, *G* and *H*; patient 7). Slides were hematoxylin and eosin—stained preparations (*E* and *G*; original magnification ×200, *F* and *H*; original magnification ×400).

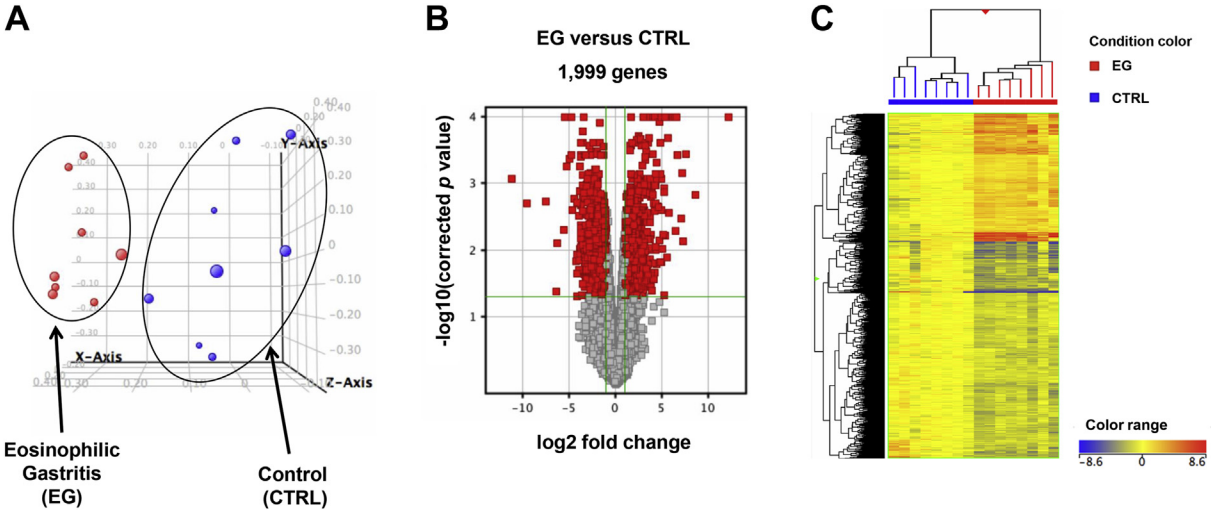

FIGURE 2. Microarray analysis of differentially expressed genes in gastric biopsies. **A**, Unsupervised principal-component analysis showed complete separation of EG specimens and control specimens. **B**, Volcano plot analysis showed that the least stringent criteria identified 1,999 differentially regulated genes ($P < .05$, $\geq$2-fold difference) in patients with EG compared with the controls. **C**, Heat map of 1,999 differentially dysregulated genes' expression profiles ($P < .05$, $\geq$2-fold difference). Clustering analysis within each group was performed; each column represents an individual patient or control.

performed using the gene expression data to contrast the EG and control groups. A gene set enrichment analysis score was estimated for each individual contrast. Gene sets were collected from the MSigDB (version 4.1). A gene set was accepted if it contained between 15 and 1,000 genes. Categories were further filtered on the basis of q value, including only those categories in which at least 3 comparisons had q values of less than .25. Genes differentially expressed between EG and several gastric diseases were compared by systematic analysis using the NextBio search engine (http://www.nextbio.com/b/nextbio.nb).[16]

TABLE III. Gene set enrichment analysis of all entities in EG vs CTRL

Gene set	Total genes	Genes found	*q* value	NES
POSITIVE_REGULATION_OF_PHOSPHATE_METABOLIC_PROCESS	28	23	0.0	2.0
POSITIVE_REGULATION_OF_PHOSPHORYLATION	26	21	0.1	2.0
POSITIVE_REGULATION_OF_PROTEIN_AMINO_ACID_PHOSPHORYLATION	20	16	0.1	1.9
REGULATION_OF_PHOSPHORYLATION	49	44	0.2	1.9
CYTOKINE_AND_CHEMOKINE_MEDIATED_SIGNALING_PATHWAY	23	22	0.2	1.9
POSITIVE_REGULATION_OF_PROTEIN_MODIFICATION_PROCESS	29	25	0.2	1.8
REGULATION_OF_PROTEIN_AMINO_ACID_PHOSPHORYLATION	30	26	0.2	1.8
OXIDOREDUCTASE_ACTIVITY_ACTING_ON_NADH_OR_NADPH	25	24	0.2	1.8
HOMEOSTASIS_OF_NUMBER_OF_CELLS	20	20	0.2	1.8
PEPTIDYL_TYROSINE_MODIFICATION	29	25	0.3	1.8
REGULATION_OF_PROTEIN_MODIFICATION_PROCESS	44	40	0.3	1.8
OXIDOREDUCTASE_ACTIVITY_GO_0016705	38	31	0.3	1.8
POSITIVE_REGULATION_OF_CELLULAR_PROTEIN_METABOLIC_PROCESS	73	65	0.3	1.7

NES, Normalized enrichment score.

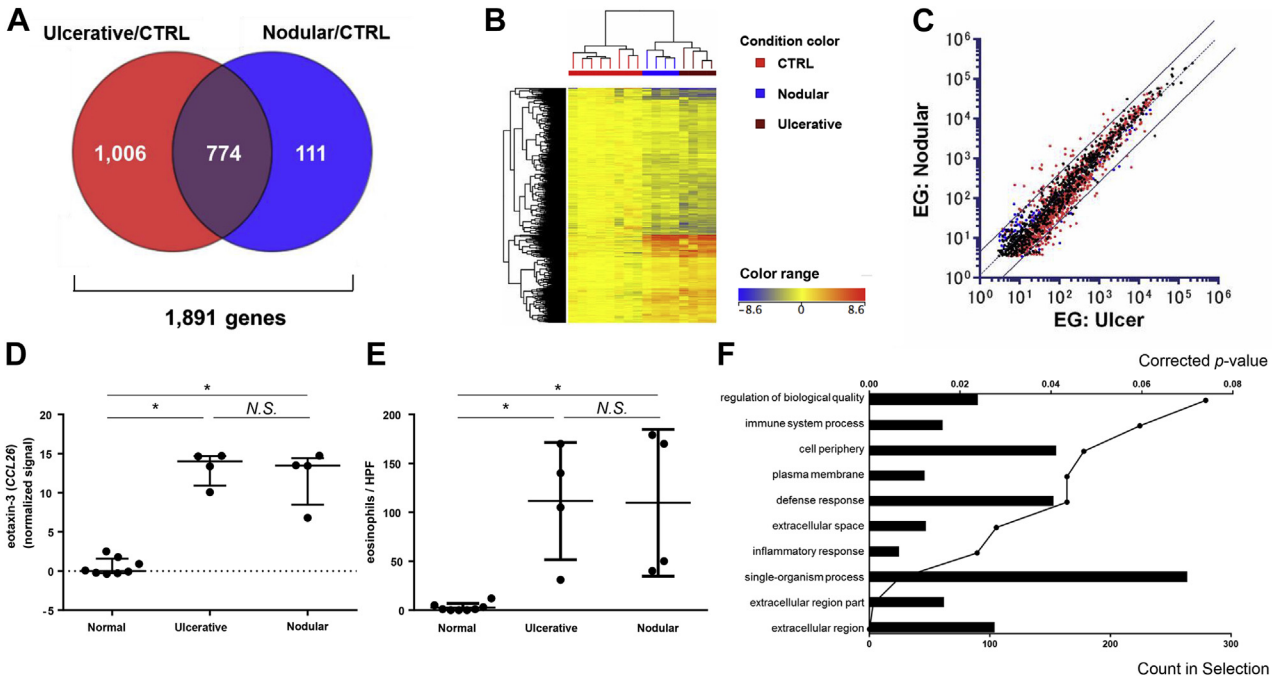

FIGURE 3. Comparison of gene expression profiles in EG as a function of the endoscopic findings. **A**, Venn diagrams comparing the number of genes identified as dysregulated in both ulcerative (ulcer/normal) and nodular (nodular/normal) lesions. **B**, Heat map of 1,891 differentially dysregulated genes' expression profiles ($P < .05$, $\geq$2-fold difference). Clustering analysis for each EG lesion type was performed; each column represents an individual patient or control. **C**, Spearman correlation comparing absolute raw values for the 1,891 differentially dysregulated genes in both ulcerative and nodular lesions. Black symbols, overlapping genes; red symbols, ulcer-distinct genes; blue symbols, nodule-distinct genes. **D** and **E**, Eotaxin-3 (*CCL26*) mRNA expression and tissue eosinophil counts in controls and patients with EG with ulcerative and nodular lesions (*$P < .05$). **F**, GO analysis of overlapping genes. *N.S.*, Not significant.

Statistical analysis

Differences between the study groups were determined using the Kruskal-Wallis test followed by Dunn's multiple comparison test or the Mann Whitney *U* test. Statistical analyses were performed using GraphPad Prism 6 (GraphPad Software, Inc, San Diego, Calif). A *P* value of less than .05 was considered significant.

Ethical issues

This study was performed according to a protocol approved by the Institutional Review Board of National Center for Child Health and Development, Tokyo, Japan (acceptance no. 725). Written informed consent was obtained from the legal guardian, and assent was obtained from each subject when appropriate.

TABLE IV. List of top 20 upregulated and downregulated genes in ulcer-distinct genes and nodule-distinct genes

Probe name	Fold change ulcerative/nodular	Ulcerative (raw signal)	Nodular (raw signal)	CTRL (raw signal)	Gene symbol	Gene name
Ulcer-distinct genes						
A_23_P166408	18.4	2078.7	59.0	41.1	OSM	Oncostatin M
A_23_P38537	17.9	563.9	32.6	31.5	KRT16	Keratin 16
A_32_P87013	16.6	218.2	7.7	14.2	IL8	Interleukin 8
A_32_P62963	15.3	534.5	35.9	19.7	KRT16P2	Keratin 16 pseudogene 2
A_23_P124905	11.8	1769.0	141.5	21.5	NPTX1	Neuronal pentraxin I
A_23_P96158	11.1	205.5	13.1	7.0	KRT17	Keratin 17
A_23_P259071	9.4	3192.1	342.7	471.4	AREG	Amphiregulin
A_23_P106194	8.5	13229.9	1300.9	2612.1	FOS	FBJ murine osteosarcoma viral oncogene homolog
A_33_P3304065	7.9	576.4	20.9	14.7	AQP2	Aquaporin 2 (collecting duct)
A_23_P429998	7.6	693.9	36.7	49.4	FOSB	FBJ murine osteosarcoma viral oncogene homolog B
A_32_P200238	7.1	1168.4	199.5	74.4	UCA1	Urothelial cancer associated 1 (nonprotein coding)
A_33_P3531373	6.6	201.7	40.2	12.2	LOC340340	Hypothetical LOC340340
A_33_P3255964	6.4	1212.6	224.2	80.1	CYMP	Chymosin pseudogene
A_24_P331704	6.0	377.0	68.6	16.8	KRT80	Keratin 80
A_33_P3388391	5.4	1588.2	220.3	71.1	GJB4	Gap junction protein, beta 4, 30.3 kDa
A_23_P110712	5.2	4359.7	726.1	1169.7	DUSP1	Dual specificity phosphatase 1
A_24_P33895	5.1	663.4	83.6	83.9	ATF3	Activating transcription factor 3
A_23_P121120	4.9	51.4	10.8	6.3	GPR87	G protein−coupled receptor 87
A_33_P3300916	4.8	433.6	99.8	98.1	LOC201651	Arylacetamide deacetylase (esterase) pseudogene
A_23_P34915	4.7	16740.4	2194.8	2101.6	ATF3	Activating transcription factor 3
A_24_P11100	−5.3	4.7	22.6	49.1	ZMAT1	Zinc finger, matrin-type 1
A_23_P38735	−5.4	9.9	54.8	100.6	CDH19	Cadherin 19, type 2
A_23_P112982	−5.4	10.9	78.8	348.6	SVOP	SV2-related protein homolog (rat)
A_32_P41604	−5.4	15.9	61.1	166.1	F5	Coagulation factor V (proaccelerin, labile factor)
A_23_P157914	−5.6	3.9	27.5	112.7	MAMDC2	MAM domain containing 2
A_24_P349117	−5.8	7.7	53.6	115.2	GPR158	G protein−coupled receptor 158
A_33_P3363804	−5.9	4.4	25.8	85.8	NCAM1	Neural cell adhesion molecule 1
A_33_P3410351	−6.1	13.4	53.0	58.0	GSTM2	Glutathione S-transferase mu 2 (muscle)
A_33_P3285965	−6.3	20.0	191.5	798.3	NEUROD1	Neurogenic differentiation 1
A_33_P3273684	−6.3	8.6	45.9	100.7	NRXN1	Neurexin 1
A_23_P208030	−6.3	15.4	108.1	462.3	SYT4	Synaptotagmin IV
A_23_P30294	−6.5	7.4	38.4	90.1	CDO1	Cysteine dioxygenase, type I
A_24_P296808	−6.6	25.2	134.0	295.1	PNMAL1	PNMA-like 1
A_23_P252817	−6.7	606.3	6511.9	41574.9	SST	Somatostatin
A_23_P168761	−7.1	99.9	212.7	542.3	PTPRZ1	Protein tyrosine phosphatase, receptor-type, Z polypeptide 1
A_24_P85850	−7.2	4.0	32.6	20.1	BNIPL	BCL2/adenovirus E1B 19kD interacting protein like
A_24_P309521	−7.4	10.1	60.9	42.4	KCNJ5	Potassium inwardly-rectifying channel, subfamily J, member 5
A_32_P29118	−7.6	5.2	37.5	217.6	SEMA3D	Sema domain, immunoglobulin domain (Ig), short basic domain, secreted, (semaphorin) 3D
A_24_P31627	−8.3	6.9	71.6	54.6	KCNB1	Potassium voltage-gated channel, Shab-related subfamily, member 1
A_23_P159952	−11.2	23.5	271.9	1200.9	BEX1	Brain expressed, X-linked 1

(continued)

TABLE IV. *(Continued)*

Probe name	Fold change ulcerative/nodular	Ulcerative (raw signal)	Nodular (raw signal)	CTRL (raw signal)	Gene symbol	Gene name
Nodule-distinct genes						
A_23_P37702	9.1	3268.0	637.9	427.8	TPSAB1	Tryptase alpha/beta 1
A_33_P3382324	7.8	2367.1	524.3	274.9	TPSD1	Tryptase delta 1
A_19_P00322339	5.8	103.9	7.6	4.4	XLOC_008374	
A_23_P2920	5.5	5952.6	5170.9	68.4	SERPINA3	Serpin peptidase inhibitor, clade A (alpha-1 antiproteinase, antitrypsin), member 3
A_24_P940411	4.5	21.7	4.8	6.6	CXorf36	Chromosome X open reading frame 36
A_33_P3343196	3.8	114.1	26.3	6.1	CP	Ceruloplasmin (ferroxidase)
A_32_P75581	3.6	99.6	31.7	12.7	BHLHE22	Basic helix-loop-helix family, member e22
A_23_P139682	3.4	221.6	84.7	67.2	PZP	Pregnancy-zone protein
A_33_P3231739	2.9	17.4	9.8	5.2	ELOVL2	ELOVL fatty acid elongase 2
A_33_P3218832	2.6	191.3	79.3	57.1	RIMS1	Regulating synaptic membrane exocytosis 1
A_23_P17821	2.6	71.9	66.4	10.8	PLA2G3	Phospholipase A2, group III
A_33_P3283824	2.6	54.2	50.4	7.3	SLC39A8	Solute carrier family 39 (zinc transporter), member 8
A_33_P3349912	2.5	172.9	88.3	29.7	RAB44	RAB44, member RAS oncogene family
A_19_P00322058	2.5	152.7	45.1	18.9	XLOC_005465	
A_23_P113748	2.2	48.7	31.4	9.8	ZNF385D	Zinc finger protein 385D
A_24_P12397	2.2	72.3	35.1	27.5	TREM2	Triggering receptor expressed on myeloid cells 2
A_32_P160045	2.2	17.3	6.9	3.7	TCTEX1D1	Tctex1 domain containing 1
A_23_P4592	2.0	129.8	66.1	48.3	SIGLEC6	Sialic acid binding Ig-like lectin 6
A_23_P208182	2.0	112.3	75.4	26.3	SIGLEC10	Sialic acid binding Ig-like lectin 10
A_33_P3320159	2.0	13.1	7.7	3.8	GSDMC	Gasdermin C
A_33_P3262431	−1.8	3.9	11.6	16.7	KREMEN1	Kringle containing transmembrane protein 1
A_33_P3361891	−1.8	40.0	85.5	174.1	TMPRSS7	Transmembrane protease, serine 7
A_33_P3342802	−1.8	6.4	14.4	22.4	LOC649294	Hypothetical LOC649294
A_33_P3888568	−1.8	4.6	10.2	13.9	SNORA70B	Small nucleolar RNA, H/ACA box 70B (retrotransposed)
A_33_P3356696	−1.9	4.6	10.0	16.0	LOC100134409	Double homeobox protein 4-like
A_23_P151975	−1.9	9.9	21.9	33.0	RHCG	Rh family, C glycoprotein
A_32_P110472	−1.9	72.0	137.9	399.4	IYD	Iodotyrosine deiodinase
A_23_P359588	−1.9	15.3	28.9	49.8	PCDHGB4	Protocadherin gamma subfamily B, 4
A_33_P3244574	−1.9	4.5	10.3	14.1	LOC100128675	Hypothetical LOC100128675
A_33_P3255664	−1.9	6.1	15.2	25.5	PBX1	Pre−B-cell leukemia homeobox 1
A_23_P255876	−2.0	5.5	15.4	20.1	DNAI1	Dynein, axonemal, intermediate chain 1
A_24_P49427	−2.1	3.2	8.7	9.2	KIAA1486	KIAA1486
A_23_P122134	−2.1	9.1	21.9	42.1	NMUR2	Neuromedin U receptor 2
A_33_P3257013	−2.5	3.1	11.1	13.5	LOC100132024	Hypothetical protein LOC100132024
A_23_P11644	−2.7	11.5	37.5	96.8	SPRR2D	Small proline-rich protein 2D
A_23_P89587	−2.8	8.8	30.1	21.0	WNT9B	Wingless-type MMTV integration site family, member 9B
A_24_P160696	−3.2	6.0	26.2	45.1	C3orf15	Chromosome 3 open reading frame 15
A_33_P3217357	−3.5	7.7	39.2	110.3	LOC100132501	Hypothetical LOC100132501
A_33_P3239614	−4.1	9.3	40.2	49.5	IYD	Iodotyrosine deiodinase
A_23_P1575	−6.0	7.4	72.2	249.4	TRIM49	Tripartite motif containing 49

CTRL, Control.

RESULTS

Clinical characteristics

Eight children with EG and 8 control subjects were included in this study, and Table I summarizes their clinical characteristics. Their median ages were similar (10 [interquartile range (IQR), 8-13] vs 8 [IQR, 7-10.5] years for control subjects; $P = .53$). The male/female ratio of EG was 5:3, whereas the control subjects were all male. Many of the patients with EG had a history of allergic diseases, including asthma, food allergy, and atopic dermatitis (62.5%, 62.5%, and 50.0%, respectively). The results of laboratory tests are also presented in Table I. The peripheral eosinophil count was increased in all the patients with EG and was significantly higher than in the control subjects (median 655/μL [IQR, 650-1627/μL] vs median 265/μL [IQR, 230-450/μL]; $P = .04$). The total IgE concentration was also higher in the EG group. All patients with EG were positive for multiple serum food-

specific IgEs; however, no offending food(s) was detected by specific food challenge and/or elimination tests.

Endoscopic findings and histological signs

All the patients with EG had endoscopic abnormalities, including gastric mucosal erythema, erosion, and ulcerative or nodular lesions (Table II). Notably, the gross endoscopic findings could be roughly divided into 2 patterns, namely, ulcerative and nodular lesions, and these findings were considered characteristic of patients with EG (Figure 1). All control subjects had unremarkable endoscopic findings.

Table II also shows the highest number of infiltrating eosinophils per hpf in the different GI sections (esophagus, stomach, duodenum, and colon). These eosinophilic infiltrations were noted predominantly in lamina propria. The peak infiltrating eosinophil counts were significantly higher in patients with EG compared with the control subjects (stomach; median 122 [IQR, 47.5-170/hpf] vs median 1 [IQR, 0-3.5/hpf]; $P < .001$).

Microarray analysis of differentially expressed genes in gastric biopsies

Gastric biopsy specimens obtained from each patient with EG (n = 8) were compared with control specimens (n = 8) by whole-genome-wide transcript expression profile analysis (see Table E1 in this article's Online Repository at www.jaci-inpractice.org). Unsupervised principal-component analysis of EG and control samples showed complete separation (Figure 2, *A*). Of the 42,545 transcripts represented on the microarrays, volcano plot analysis showed that the least stringent criteria identified 1,999 differentially regulated genes (≥2-fold difference, adjusted $P < .05$) in the patients with EG compared with the controls (Figure 2, *B*). Although a subset of the patients with EG has associated duodenal or colonic eosinophilia (patient nos. 1, 3, 5, and 8), there were no significant expression differences in these patients compared with patients with EG alone (patient nos. 2, 4, 6, and 7) when we performed a comparison using the same criteria (≥2-fold difference, adjusted $P < .05$). Hierarchical clustering of the signal intensities of the individual genes in each group showed highly similar gene expression patterns among the patients with EG. Of those 1,999 genes, 744 were expressed more abundantly while 1,255 were expressed less abundantly in the patients with EG compared with the control group (Figure 2, *C*; see Table E2 in this article's Online Repository at www.jaci-inpractice.org). In agreement with a previous study on patients with EG in the United States, eotaxin-3 (*CCL26*) was the most upregulated (>4,000 fold) gene. In the EG-related gene signature that we identified, approximately 97% of the genes, including eotaxin-3 (*CCL26*), were distinct from the previously identified gene signatures for eosinophilic esophagitis (see Figure E1 in this article's Online Repository at www.jaci-inpractice.org).[15,17] Moreover, we analyzed all the data at a general level by gene set enrichment analysis for the GO categories, potentially identifying the fundamental processes underpinning EG. This revealed that significantly enriched normalized enrichment score—related GO terms included "cytokine and chemokine mediated signaling pathway" (Table III).

Comparison of gene expression profiles in EG based on the endoscopic findings

We compared the biopsy specimens of patients with EG with ulcerative lesions (n = 4) with those of patients with EG with nodular lesions (n = 4). The comparisons were performed at both the gene expression and GO category levels. As illustrated in the Venn diagram, we identified 1,780 (red circles) and 885 (blue circles) ulcerative and nodular lesions in patients with EG, respectively, that were differentially dysregulated compared with the controls (≥2-fold difference, adjusted $P < .05$) (Figure 3, *A*). The top 20 upregulated and downregulated genes in each group (ulcer- and nodule-distinct genes) are listed in Table IV, and the overlapping genes are listed in Table E3 in this article's Online Repository at www.jaci-inpractice.org. Cluster analysis showed clear separation between the ulcerative, nodular, and control specimens (Figure 3, *B*).

To further discriminate between the groups, the selected 1,891 genes were highlighted in scatter plots, comparing the ulcerative and nodular transcriptomes (Figure 3, *C*). These dysregulated genes showed no major differences, but were slightly shifted to ulcerative lesions, indicating minor differential molecular reactions. Our data also showed that both the eotaxin-3 (*CCL26*) level (Figure 3, *D*) and tissue eosinophil count (Figure 3, *E*) were similar in ulcerative and nodular lesions.

Moreover, GO analysis on the overlapping genes revealed significant enrichment of GO terms, including several ontologies of "basic metabolic processes" and also "inflammatory processes," whereas analysis of each distinct gene revealed no GO terms (Figure 3, *F*; see Table E4 in this article's Online Repository at www.jaci-inpractice.org).

We also compared the overlapping genes that we found in EG to previously published data sets describing gene expression changes in EG in the United States as well as various gastric diseases such as *Helicobacter pylori* gastritis, gastrointestinal stromal tumor, and stomach cancer (see Figure E2 in this article's Online Repository at www.jaci-inpractice.org). When we compared our overlapping genes to the data from the EG study in the United States, we found significantly more numbers of overlaping genes than comparisons with any other gastric diseases.

DISCUSSION

In the present study, we assessed whether the gross endoscopic findings for EG can be classified into distinct gene expression profiles. In cases with gastric eosinophilia, the gross endoscopic findings can be roughly divided into 2 patterns, namely, ulcerative and nodular lesions. Several GO terms, including "inflammatory response," were enriched in the substantially overlapping genes only but not found in each of the distinct genes. This indicates that there are shared allergic inflammatory response pathways between these 2 groups of patients.

Previous studies showed that the endoscopic findings for EG were variable, and were subtle or even normal in some patients.[6,9] The clinical characteristics and histologic findings have shown no significant differences as a function of the endoscopic findings, leading to potential confusion over the clinical diagnosis. In a recent study, the gastric endoscopic findings for 17 patients with EG were classified as follows: normal appearance (3 of 17), nodular lesions (2 of 17), and erythema and erosion (12 of 17).[9] Another study also reported that the most common endoscopic findings were a normal stomach or erythema and gastritis, with or without erosion.[6] Unlike those previous studies, our present study found 2 patterns of gross endoscopic findings for EG, namely, ulcerative and nodular lesions. Several factors may account for this

difference between the studies. One explanation might be a difference in genetic backgrounds, because eosinophilic esophagitis was shown to have different endoscopic findings between racially distinct populations.[18,19]

Our microarray data showed different gene expression profiles between patients with distinct endoscopic findings. We observed a number of genes to be differentially dysregulated between the groups. The top 20 upregulated and downregulated genes in each group (ulcer-distinct genes and nodule-distinct genes) revealed some aspects of this disease. For ulcerative lesions, the genes included oncostatin M, keratin 16, 17, 80, chemokine (C-X-C motif) ligand 8/interleukin 8, and amphiregulin. Oncostatin M and chemokine (C-X-C motif) ligand 8 expression levels were reported to be significantly increased in hypertensive leg ulcer lesions compared with healthy sections from the same donors.[20] Also, upregulated keratin 16 and keratin 17 expression levels were reported in wounds, in both the acute and chronic stages.[21] In addition, amphiregulin is known to be a major growth factor whose expression level increases during wound healing.[22] Similarly, for nodular lesions, distinct dysregulated genes included tryptase alpha/beta 1 and delta 1, also previously identified as a "mast cell transcriptome" in patients with eosinophilic esophagitis.[23] Increased expression levels of tryptases can be seen in other types of polyps.[24,25] In addition, mast cells are present in some eosinophilic inflammations.[24,26] Although the exact roles of these genes in EG are not clear, their expression levels increased specifically in either the ulcerative or nodule lesion group. They were found not to be EG-specific, but rather histological feature-related genes.

Our study revealed that substantially overlapping genes demonstrated large alterations in gene ontologies involved in inflammatory processes. Importantly, the expression profiles of shared genes showed significant increases in eotaxin-3 (*CCL26*), cadherin 26, and Charcot-Leyden crystals, and a significant decrease in interleukin 33, in close agreement with Caldwell et al's report.[11] Moreover, both *IL13* and *IL13RA1* expression levels were increased in both ulcerative (66.5, 2.0-fold increase) and nodular (32.2, 1.5-fold increase) lesions compared with controls (data not shown). However, the common genes showed no similarities with the profiles for *Helicobacter pylori* gastritis,[27] gastrointestinal stromal tumor, or stomach cancer,[28,29] suggesting that these EG transcriptomes are different from the transcriptomes of other diseases.

Despite identifying distinct patterns of gene expression between the 2 EG subtypes, most genes that were differentially regulated compared with the controls were found to overlap in the 2 subtypes of EG. The existence of genes that are differentially regulated between the 2 EG groups might be due, at least in part, to the presence of distinctly different structural cells in the biopsy tissues. Interestingly, GO analysis of the common genes resulted in an enrichment with inflammatory processes, while analyses of the distinct genes from each of the groups led to no specific gene ontology group.

This study has several limitations. First, the small sample size is a major limitation, although we enrolled all patients with gastric eosinophilia treated at our institution over the past 5 years. Racial disparities in symptoms and eosinophil-infiltrated tissues were observed in EGID between whites and Asians.[30] However, EGID is considered to be a rare disease in Japan[31] as well as in the United States, where the estimated prevalence is 6.3/100,000.[32] Thus, to overcome this sample size drawback, a larger multicenter prospective study may be necessary to obtain conclusive results, in future. The second limitation is incomplete or missing clinical information, which lacks uniformity somehow in the laboratory data among patients. Also, data from lower endoscopic findings were not available because of the high risk of the procedure in child patients. Patchy eosinophil distributions in gastric specimens may also have influenced the obtained results. Finally, although experienced gastroenterologists performed endoscopies and biopsies, the number of biopsy samples was limited because of ethical reason in this vulnerable patient population. Further assessment of biopsy samples may strengthen this study conclusion. A recent report documented substantial variability in the numbers and locations of biopsies performed on patients with suspected EG.[33] Formal diagnostic guidelines that include the detailed characteristics of biopsy may be necessary for future studies.

In conclusion, these results strongly indicate that the ulcerative and nodular forms of EG are the same, or at least variations of a single disease, in spite of their morphological differences. Our findings may contribute to a better understanding of the pathogenesis of EG, as well as to more accurate diagnosis of this disease.

Acknowledgments

We express our sincere gratitude to Ms Kazue Takeda, Ms Michiko Yamada, Ms Yoshiko Shimamoto, and Ms Chihiro Usami of the Department of Allergy and Clinical Immunology of National Research Institute for Child Health & Development for their excellent technical and office work. We also thank all the doctors, nurses, and technicians in the Divisions of Allergy and Gastroenterology of the National Center for Child Health and Development for their great clinical skill and invaluable cooperation, and Lawrence W. Stiver (Tokyo, Japan) for proofreading the manuscript.

REFERENCES

1. Talley NJ, Shorter RG, Phillips SF, Zinsmeister AR. Eosinophilic gastroenteritis: a clinicopathological study of patients with disease of the mucosa, muscle layer, and subserosal tissues. Gut 1990;31:54-8.
2. Rothenberg ME. Eosinophilic gastrointestinal disorders (EGID). J Allergy Clin Immunol 2004;113:11-28.
3. Oh HE, Chetty R. Eosinophilic gastroenteritis: a review. J Gastroenterol 2008;43:741-50.
4. Mehta P, Furuta GT. Eosinophils in gastrointestinal disorders: eosinophilic gastrointestinal diseases, celiac disease, inflammatory bowel diseases, and parasitic infections. Immunol Allergy Clin North Am 2015;35:413-37.
5. Kinoshita Y, Ishimura N, Oshima N, Mikami H, Okimoto E, Jiao DJ, et al. Recent progress in the research of eosinophilic esophagitis and gastroenteritis. Digestion 2016;93:7-12.
6. Lwin T, Melton SD, Genta RM. Eosinophilic gastritis: histopathological characterization and quantification of the normal gastric eosinophil content. Mod Pathol 2011;24:556-63.
7. Jimenez-Rivera C, Ngan B, Jackson R, Ahmed N. Gastric pseudopolyps in eosinophilic gastroenteritis. J Pediatr Gastroenterol Nutr 2005;40:83-6.
8. Chehade M, Sicherer SH, Magid MS, Rosenberg HK, Morotti RA. Multiple exudative ulcers and pseudopolyps in allergic eosinophilic gastroenteritis that responded to dietary therapy. J Pediatr Gastroenterol Nutr 2007;45:354-7.
9. Ko HM, Morotti RA, Yershov O, Chehade M. Eosinophilic gastritis in children: clinicopathological correlation, disease course, and response to therapy. Am J Gastroenterol 2014;109:1277-85.
10. Prussin C. Eosinophilic gastroenteritis and related eosinophilic disorders. Gastroenterol Clin North Am 2014;43:317-27.
11. Caldwell JM, Collins MH, Stucke EM, Putnam PE, Franciosi JP, Kushner JP, et al. Histologic eosinophilic gastritis is a systemic disorder associated with

blood and extragastric eosinophilia, TH2 immunity, and a unique gastric transcriptome. J Allergy Clin Immunol 2014;134:1114-24.
12. DeBrosse CW, Case JW, Putnam PE, Collins MH, Rothenberg ME. Quantity and distribution of eosinophils in the gastrointestinal tract of children. Pediatr Dev Pathol 2006;9:210-8.
13. Hurrell JM, Genta RM, Melton SD. Histopathologic diagnosis of eosinophilic conditions in the gastrointestinal tract. Adv Anat Pathol 2011;18:335-48.
14. Collins MH. Histopathologic features of eosinophilic esophagitis and eosinophilic gastrointestinal diseases. Gastroenterol Clin North Am 2014;43:257-68.
15. Shoda T, Morita H, Nomura I, Ishimura N, Ishihara S, Matsuda A, et al. Comparison of gene expression profiles in eosinophilic esophagitis (EoE) between Japan and Western countries. Allergol Int 2015;64:260-5.
16. Kupershmidt I, Su QJ, Grewal A, Sundaresh S, Halperin I, Flynn J, et al. Ontology-based meta-analysis of global collections of high-throughput public data. PLoS One 2010;5:e13066.
17. Blanchard C, Wang N, Stringer KF, Mishra A, Fulkerson PC, Abonia JP, et al. Eotaxin-3 and a uniquely conserved gene-expression profile in eosinophilic esophagitis. J Clin Invest 2006;116:536-47.
18. Bohm M, Malik Z, Sebastiano C, Thomas R, Gaughan J, Kelsen S, et al. Mucosal eosinophilia: prevalence and racial/ethnic differences in symptoms and endoscopic findings in adults over 10 years in an urban hospital. J Clin Gastroenterol 2012;46:567-74.
19. Ishimura N, Shimura S, Jiao D, Mikami H, Okimoto E, Uno G, et al. Clinical features of eosinophilic esophagitis: differences between Asian and Western populations. J Gastroenterol Hepatol 2015;30:71-7.
20. Giot JP, Paris I, Levillain P, Huguier V, Charreau S, Delwail A, et al. Involvement of IL-1 and oncostatin M in acanthosis associated with hypertensive leg ulcer. Am J Pathol 2013;182:806-18.
21. Luo S, Yufit T, Carson P, Fiore D, Falanga J, Lin X, et al. Differential keratin expression during epiboly in a wound model of bioengineered skin and in human chronic wounds. Int J Low Extrem Wounds 2011;10:122-9.
22. Schelfhout VR, Coene ED, Delaey B, Waeytens AA, De Rycke L, Deleu M, et al. The role of heregulin-alpha as a motility factor and amphiregulin as a growth factor in wound healing. J Pathol 2002;198:523-33.
23. Abonia JP, Blanchard C, Butz BB, Rainey HF, Collins MH, Stringer K, et al. Involvement of mast cells in eosinophilic esophagitis. J Allergy Clin Immunol 2010;126:140-9.
24. Butterfield JH, Leiferman KM, Gleich GJ. Nodules, eosinophilia, rheumatism, dermatitis and swelling (NERDS): a novel eosinophilic disorder. Clin Exp Allergy 1993;23:571-80.
25. El-Hamarneh T, Hey-Cunningham AJ, Berbic M, Al-Jefout M, Fraser IS, Black K. Cellular immune environment in endometrial polyps. Fertil Steril 2013;100:1364-72.
26. Groger M, Bernt A, Wolf M, Mack B, Pfrogner E, Becker S, et al. Eosinophils and mast cells: a comparison of nasal mucosa histology and cytology to markers in nasal discharge in patients with chronic sino-nasal diseases. Eur Arch Otorhinolaryngol 2013;270:2667-76.
27. Nookaew I, Thorell K, Worah K, Wang S, Hibberd ML, Sjovall H, et al. Transcriptome signatures in *Helicobacter pylori*-infected mucosa identifies acidic mammalian chitinase loss as a corpus atrophy marker. BMC Med Genomics 2013;6:41.
28. Chen X, Leung SY, Yuen ST, Chu KM, Ji J, Li R, et al. Variation in gene expression patterns in human gastric cancers. Mol Biol Cell 2003;14:3208-15.
29. Cho JY, Lim JY, Cheong JH, Park YY, Yoon SL, Kim SM, et al. Gene expression signature-based prognostic risk score in gastric cancer. Clin Cancer Res 2011;17:1850-7.
30. Ito J, Fujiwara T, Kojima R, Nomura I. Racial differences in eosinophilic gastrointestinal disorders among Caucasian and Asian. Allergol Int 2015;64:253-9.
31. Kinoshita Y, Furuta K, Ishimaura N, Ishihara S, Sato S, Maruyama R, et al. Clinical characteristics of Japanese patients with eosinophilic esophagitis and eosinophilic gastroenteritis. J Gastroenterol 2013;48:333-9.
32. Jensen ET, Martin CF, Kappelman MD, Dellon ES. Prevalence of eosinophilic gastritis, gastroenteritis, and colitis: estimates from a national administrative database. J Pediatr Gastroenterol Nutr 2016;62:36-42.
33. Dellon ES, Collins MH, Bonis PA, Leung J, Capocelli KE, Dohil R, et al. Substantial variability in biopsy practice patterns among gastroenterologists for suspected eosinophilic gastrointestinal disorders. Clin Gastroenterol Hepatol 2016;14:1842-4.

ONLINE REPOSITORY

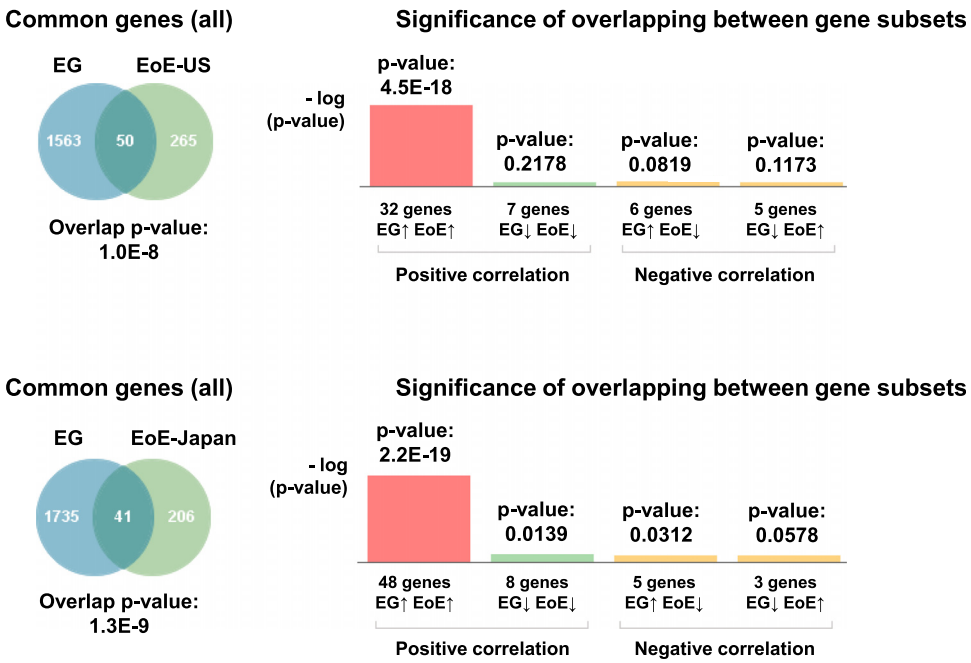

FIGURE E1. Comparison of differentially expressed genes in EG with previously identified gene signature for eosinophilic esophagitis. Upregulated and downregulated genes in patients with EG were extracted and compared with data from esophageal biopsy specimens determined in previous studies in the United States and Japan using the NextBio search engine.

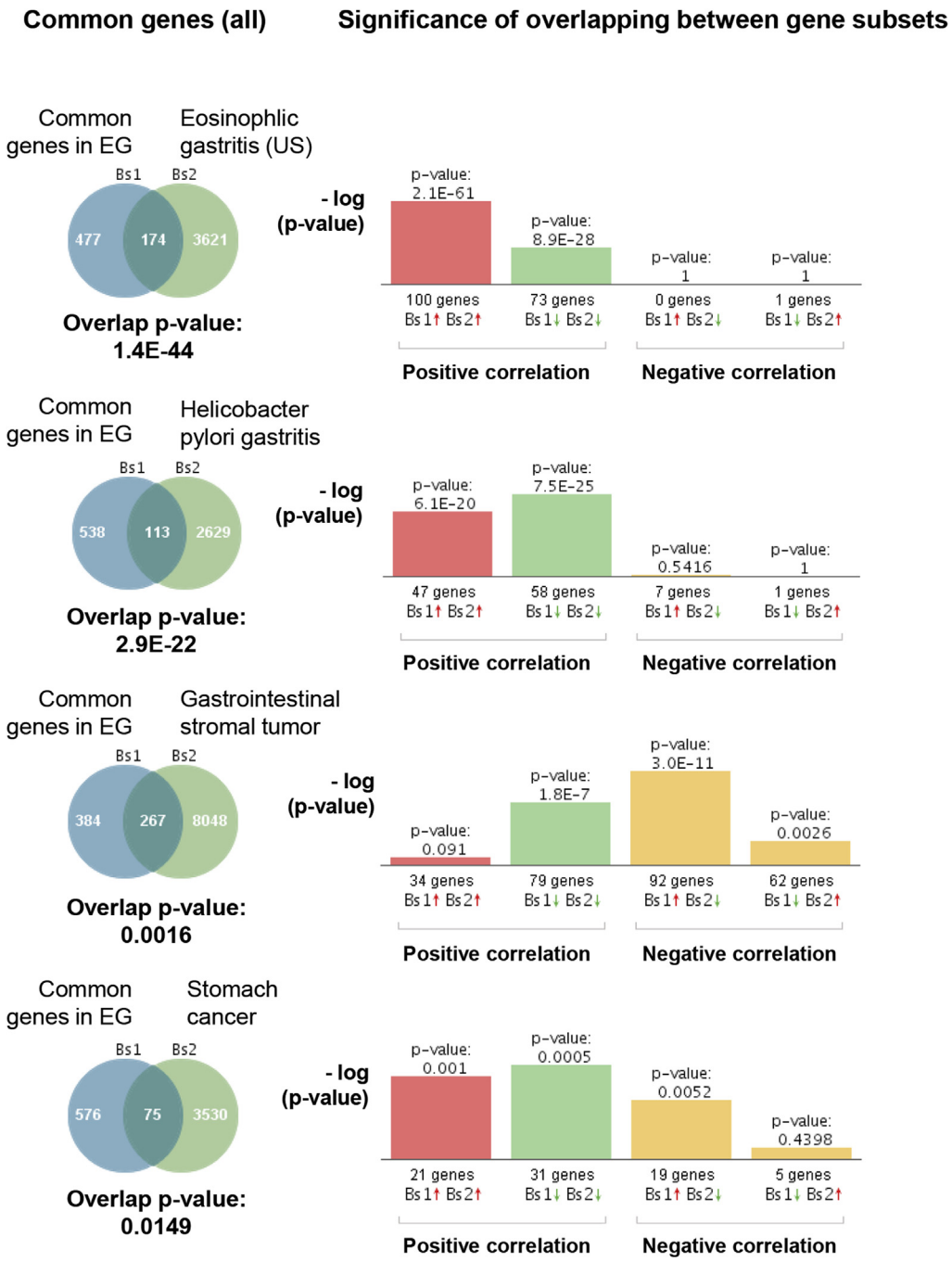

FIGURE E2. Comparison of our overlapping genes to the data for EG with previously published data sets in various gastric diseases. Overlapping genes between ulcerative and nodular lesions were extracted and compared with data from gastric biopsy specimens determined in previous studies using the NextBio search engine.

Reproduced with permission of copyright owner. Further reproduction prohibited without permission.