OPEN ACCESS Freely available online

PLOS | ONE

Mycoplasma pneumoniae CARDS Toxin Exacerbates Ovalbumin-Induced Asthma-Like Inflammation in BALB/c Mice

Jorge L. Medina[1,5], Jacqueline J. Coalson[2], Edward G. Brooks[3,5], Claude Jourdan Le Saux[4], Vicki T. Winter[2], Adriana Chaparro[3,5], Molly F. R. Principe[3], Laura Solis[4], T. R. Kannan[1,5], Joel B. Baseman[1,5], Peter H. Dube[1,5]*

1 Department of Microbiology and Immunology, University of Texas Health Science Center at San Antonio, San Antonio, Texas, United States of America, **2** Department of Pathology, University of Texas Health Science Center at San Antonio, San Antonio, Texas, United States of America, **3** Department of Pediatrics, Division of Allergy and Infectious Diseases, University of Texas Health Science Center at San Antonio, San Antonio, Texas, United States of America, **4** Department of Medicine, Division of Cardiology, University of Texas Health Science Center at San Antonio, San Antonio, Texas, United States of America, **5** Center for Airway Inflammation Research, University of Texas Health Science Center at San Antonio, San Antonio, Texas, United States of America

Abstract

Mycoplasma pneumoniae causes a range of airway and extrapulmonary pathologies in humans. Clinically, *M. pneumoniae* is associated with acute exacerbations of human asthma and a worsening of experimentally induced asthma in mice. Recently, we demonstrated that Community Acquired Respiratory Distress Syndrome (CARDS) toxin, an ADP-ribosylating and vacuolating toxin synthesized by *M. pneumoniae*, is sufficient to induce an asthma-like disease in BALB/cJ mice. To test the potential of CARDS toxin to exacerbate preexisting asthma, we examined inflammatory responses to recombinant CARDS toxin in an ovalbumin (OVA) murine model of asthma. Differences in pulmonary inflammatory responses between treatment groups were analyzed by histology, cell differentials and changes in cytokine and chemokine concentrations. Additionally, assessments of airway hyperreactivity were evaluated through direct pulmonary function measurements. Analysis of histology revealed exaggerated cellular inflammation with a strong eosinophilic component in the CARDS toxin-treated group. Heightened T-helper type-2 inflammatory responses were evidenced by increased expression of IL-4, IL-13, CCL17 and CCL22 corresponding with increased airway hyperreactivity in the CARDS toxin-treated mice. These data demonstrate that CARDS toxin can be a causal factor in the worsening of experimental allergic asthma, highlighting the potential importance of CARDS toxin in the etiology and exacerbation of human asthma.

Citation: Medina JL, Coalson JJ, Brooks EG, Le Saux CJ, Winter VT, et al. (2014) *Mycoplasma pneumoniae* CARDS Toxin Exacerbates Ovalbumin-Induced Asthma-Like Inflammation in BALB/c Mice. PLoS ONE 9(7): e102613. doi:10.1371/journal.pone.0102613

Editor: Hong Wei Chu, National Jewish Health, United States of America

Received February 7, 2014; **Accepted** June 20, 2014; **Published** July 24, 2014

Copyright: © 2014 Medina et al. This is an open-access article distributed under the terms of the Creative Commons Attribution License, which permits unrestricted use, distribution, and reproduction in any medium, provided the original author and source are credited.

Funding: NIH AI 070412, Translational Science Training Fellowship, Bacterial Pathogenesis T-32 Training Grant, the Kleberg Foundation, the Janey Briscoe Center of Excellence in Cardiovascular Research and the Carroll Transplant Fellow Fund. The funders had no role in study design, data collection and analysis, decision to publish, or preparation of the manuscript.

Competing Interests: EGB is a PLOS ONE Editorial Board member. This does not alter the authors' adherence to PLOS ONE Editorial policies and criteria.

* Email: Dube@uthscsa.edu

Introduction

Asthma is a chronic disease characterized by reversible airway obstruction, inflammation, and airway hyperreactivity (AHR) [1]. While the causes of asthma are multi-factorial, asthma exacerbations can be triggered by viral or bacterial infections leading to greater morbidity [2,3,4,5,6,7,8]. *Mycoplasma pneumoniae* is a common human bacterial pathogen that causes acute or chronic respiratory infections and is linked to a variety of extrapulmonary infections or sequelae [2,9,10]. Clinical associations of *M. pneumoniae* infection with asthma exacerbations are increasing as detection methods improve [5,7,11,12,13,14,15], but the molecular mechanisms by which *M. pneumoniae* worsens asthma in humans are not well understood.

Experimental infections of mice with *M. pneumoniae* can mimic many aspects of *M. pneumoniae*-associated pathologies observed during human infection. For example, acute infection with *M. pneumoniae* can lead to pneumonia, increased lymphocytic inflammation, and AHR [11,16]. Additionally, *M. pneumoniae* infection and its impact on pre-existing allergic inflammation have been tested in mouse models of asthma. These studies demonstrate the capacity of *M. pneumoniae* to exacerbate many features associated with allergic inflammation including T-helper type 2 (Th2) responses and AHR [17,18].

Recently, we characterized a *M. pneumoniae*-encoded toxin capable of producing an asthma-like disease in naïve mice [19,20,21,22]. This toxin designated Community Acquired Respiratory Distress Syndrome (CARDS) toxin, has vacuolating and ADP-ribosylating properties causing cytopathic effects both *in vitro* and *in vivo* [20]. We showed that recombinant CARDS toxin (rCARDS toxin) produces a robust lymphocytic and eosinophilic inflammation, leading to an asthma-like disease in naïve mice. rCARDS toxin-induced inflammation is characterized by pulmonary eosinophilia, increased expression of Th2 cytokines and chemokines, mucus metaplasia, AHR, and dependence on $CD4^+$ cells consistent with allergic inflammation [22]. Important-

ly, unlike most mouse models of asthma, this study demonstrated the ability of rCARDS toxin to cause asthma-like disease in naïve mice after a single toxin exposure. Altogether, these data suggest that CARDS toxin is a potent inducer of allergic-type inflammation in mice.

The strongest clinical link between *M. pneumoniae* and asthma is in the acute exacerbation of asthma, with several recent studies demonstrating this correlation [6,14,15,23,24,25]. For example, we reported that *M. pneumoniae* was detected in 52% of the respiratory secretions from a cohort of refractory asthmatics. Among the *M. pneumoniae*-positive refractory asthmatic patients, all tested positive for CARDS toxin by antigen capture indicating the presence of the toxin in the airway and suggesting an important role of CARDS toxin in asthmatic lung disease [14]. Additionally, Wood et al showed a strong correlation between poor asthma control and testing positive for CARDS toxin by antigen capture suggesting that *M. pneumoniae* infection and CARDS toxin can worsen asthma symptom severity and control [15]. In the current study, we evaluated the impact of rCARDS toxin on exacerbations of acute asthmatic responses using the OVA mouse model of asthma.

Materials and Methods

Ethics statement

This study was performed in accordance with animal use protocols approved by the University of Texas Health Science Center at San Antonio (UTHSCSA) Institutional Animal Care and Use Committee.

Animals

5 week old BALB/cJ mice were purchased from Jackson Laboratory (Bar Harbor, ME) and maintained in an AAALAC-approved facility in accordance with Institutional Biosafety Committee and Institutional Animal Care and Use Committee protocols established at UTHSCSA.

Recombinant CARDS toxin

rCARDS toxin was expressed and purified as previously described in detail [20,21] and bioactivity was assessed by its ability to induce vacuoles in HeLa cells [19,20]. The rCARDS toxin carrier fluid (CF) (filter sterilized 50 mM tris buffer with 5% glycerol at pH 7.3) was used as a vehicle control.

OVA treatment and exposure to rCARDS toxin

Mice were sensitized and challenged with OVA using a modified protocol previously described [26]. Briefly, aluminum hydroxide solution (Alum) (Sigma, St. Louis, MO) was diluted in saline to 25% vol:vol and mixed with OVA overnight. 20 μg of OVA adsorbed to Alum in a volume of 100 μL were injected intraperitoneally twice, 2 weeks apart. Mice were subsequently challenged 2 weeks after the last injection with 1% OVA in saline by nebulization for 20 minutes daily for three days. Mice were rested 48 hours prior to intranasal or intratracheal instillation of 700 pmol of rCARDS toxin (OVA + rCARDS toxin group) or CF (OVA group). There were no statistically significant differences detected between instillation protocols (data not shown). Data acquisition was performed 7 days after CARDS toxin treatment, at the peak of CARDS toxin-induced inflammation.

Bronchoalveolar lavage fluid (BALF) and cellular differentials

BALF was obtained as previously described [19,27]. Cells in the BALF were washed and counted before centrifugation onto microscope slides using a cytospin 2 centrifuge (Shandon; Thermo, Waltham, MA). Slides were stained with Wright-Giemsa based stain (Diff-stain; IMEB Inc, San Marcos, CA), and relative numbers of neutrophils, eosinophils, monocytes/macrophages, and lymphocytes were counted.

Cytokine analysis

Enzyme-linked immunosorbent assays (ELISA) were used to determine concentrations of eotaxin-1 and 2, CCL17 and CCL22 in BALF samples according to manufacturer's instructions (R&D Systems, Minneapolis, MN).

Quantitative real-time PCR (qRT-PCR)

RNA was isolated from the lungs of OVA + rCARDS toxin or OVA mice 7 days after rCARDS toxin or CF exposure, using Life Technologies Trizol reagent according to manufacturer's protocols. RNA quality and purity were determined spectrophotometrically; all RNA absorbance ratios were between 1.9 and 2.2. Total RNA was reverse transcribed and subjected to PCR with SYBR-green using an Applied Biosystem's 7900HT thermal cycler. Relative changes in mRNA expression were determined by the $^{\Delta\Delta}$CT method using actin normalization. The following primer pairs were used: 5′-3′ actin forward tggaatcctgtggcatccatgaaac; actin reverse aaaacgcagctcagtaacagtccg; CCL17 forward atgccagagctgctcgag; CCL17 reverse tgccctggacagtcagaaac; CCL22 forward ggtccctatggtgccaatgt; CCL22 reverse acggatgtagtcctggcagc; IL-4 forward cagcaacgaagaacaccacag; IL-4 reverse ccttggaagccctacagacg and IL-13 forward tcacacaagaccagactcccc; IL-13 reverse ccacactccataccatgctgc.

Histopathology and immunohistochemistry (IHC)

Following instillation of rCARDS toxin, lungs were harvested 7 days after exposure. Tissues were fixed in 10% formalin solution and embedded in paraffin, from which 4 μm sections were cut and stained with hematoxylin and eosin (H&E). Eosinophils were detected using a monoclonal antibody against eosinophil major basic protein (MBP) Clone MT-14.7 (Lee Laboratory, Mayo Clinic, Arizona) and evaluated by digital pathology using Aperio Scanscope XT (Aperio, Vista CA). Complete images of lungs were obtained digitally using the Aperio Scanscope XT. All slides were evaluated by a pulmonary pathologist, J.C., who was blinded to toxin-treated and control groups. Slides representative of the spectrum of inflammatory responses were identified for use in pathology scoring analysis as previously described [28,29]. The extent of gross histological changes between experimental groups was evaluated by 4 individuals using the panel of standards, with grade 1 being the least severe and grade 3 the most severe [22,28,29]. Images of the graded standards are presented as Fig S1A-C.

Airway function

Changes in pulmonary function of OVA + rCARDS toxin or OVA mice were assessed using the Flexivent system (SCIREQ, Montréal, Canada) and Flexivent software version 5.2. Pulmonary function parameters of dynamic resistance and dynamic compliance were measured through a dose-response challenge of aerosolized methacholine 7 days after rCARDS toxin instillation as we described previously [22].

Statistical analysis

Experiments were repeated a minimum of 2 times with 3-16 animals, depending on the specific protocol. All results were expressed as the mean ± S.D. Statistical differences were determined using a two-way ANOVA, two-tailed Student *t*-test, or Mann-Whitney U test for normally or non-normally distributed data with GraphPad Prism version 5.04 (GraphPad Software, San Diego CA). Fleiss' kappa test was used to measure agreement within multiple observers' analysis of the panel of standards [30,31]. A p value of <0.05 was considered significant.

Results

rCARDS toxin exacerbates cellular inflammation in OVA model of asthma

We have shown that exposure of naïve BALB/cJ mice to rCARDS toxin resulted in an eosinophilic-rich peribronchiolar and perivascular cellular inflammation, resembling asthma [19,22]. To test the capacity of CARDS toxin to exacerbate preexisting asthma-like inflammation, BALB/cJ mice were treated with OVA and challenged with rCARDS toxin 48 hours after the last OVA challenge, at the peak of OVA-induced allergic inflammation. Lungs were harvested and analyzed 7 days after rCARDS toxin exposure. H&E-stained lung sections revealed increased cellular inflammation in OVA or OVA + rCARDS toxin relative to mock-treated controls (Fig. 1A-B). Animals treated with OVA + rCARDS toxin had a higher average pathological score compared to OVA mice at day 7 (2.65±0.30 vs. 2.05±0.33 respectively ($p = 0.0002$)) suggesting an enhancement of cellular inflammation in the rCARDS toxin-treated mice (Fig 1C). Determination of agreement between investigators blinded to the treatment groups was performed using Fleiss' kappa test [30,31]. This analysis determined a value of $K = 0.67$ indicating substantial agreement amongst the investigators. In total, these data suggest rCARDS toxin is a causal factor in exacerbation of gross histological changes observed in OVA-induced experimental asthma.

rCARDS toxin exacerbates eosinophilic inflammation in OVA model of asthma

Previously, we demonstrated that rCARDS toxin alone induces significant eosinophilia in BALF and lung parenchyma of naïve mice [22]. Additionally, the OVA mouse model of asthma reported to be a well-defined model of allergic airway inflammation that induces significant eosinophilia [32]. We tested the potential of rCARDS toxin to exacerbate eosinophilia in the OVA model of asthma. Mice were analyzed for eosinophil infiltration 7 days after rCARDS or CF treatments, by analyzing BALF, cellular differentials, and histological assessments of lung tissue. OVA + rCARDS toxin-treated mice had significantly increased numbers of eosinophils in the BALF compared to mice treated with OVA alone, (79,500±37,792 vs. 31,933±20,941 eosinophils ($p = 0.0063$)) respectively (Fig. 2A). Peribronchiolar inflammatory lesions in the OVA + rCARDS toxin-treated mice had equivalent eosinophil infiltration compared to OVA mice as analyzed by digital pathology (Fig. 2B-D).

It was reported that the eosinophil chemokine, eotaxin-2, preferentially draws eosinophils into the airway luminal spaces [33]. To test if the increased infiltration of eosinophils into the BALF correlated with differential expression of eotaxin-2, BALF samples from animals in the different treatment groups were analyzed for the presence of eotaxin-1 and 2. Only eotaxin-2 was found to be significantly different between experimental groups, OVA vs. OVA + CARDS, (98.5±55.6 pg/mL vs 548.2±186.6 pg/mL ($p<0.0001$)) respectively (Fig. 2F), whereas there was equivalent expression of eotaxin-1 protein in the lungs of OVA and OVA + rCARDS toxin treated mice (Fig. 2E). These data suggest rCARDS toxin treatment of mice with experimentally induced asthma is able to increase expression of eotaxin-2 and worsen airway eosinophilia.

A histological feature sometimes observed with mouse models of chronic asthma is the development of parenchymal inflammation which can be granulomatous in nature [34]. Although we were using acute OVA sensitization, features of chronic inflammation, including the presence of granulomas, were seen when OVA-

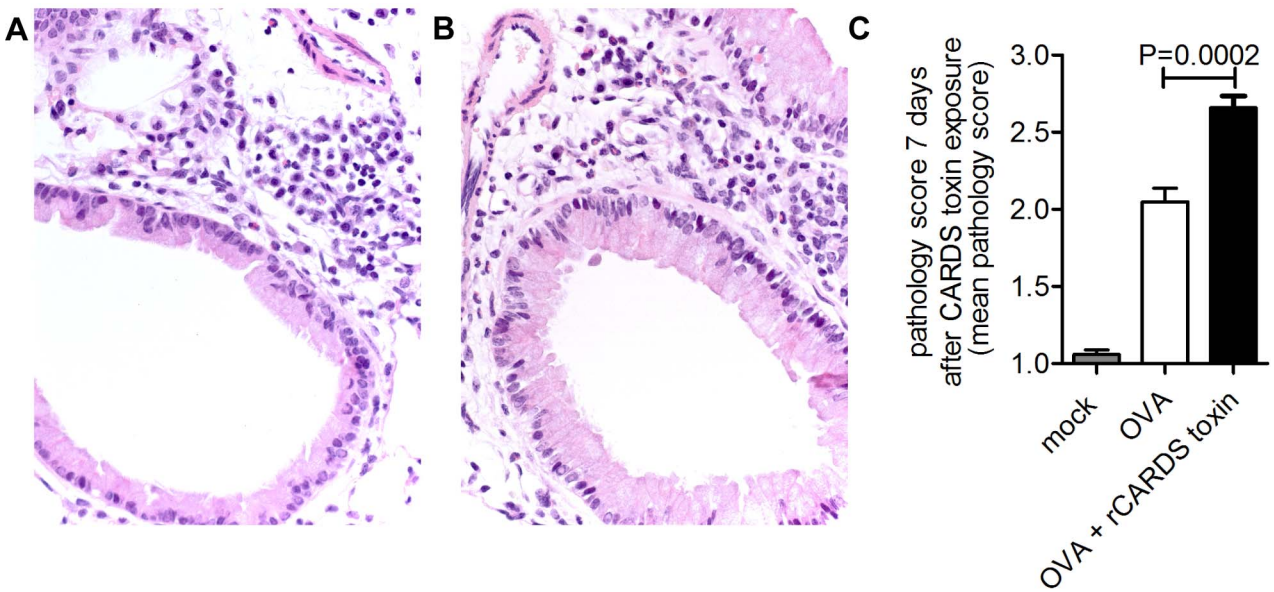

Figure 1. rCARDS toxin exacerbates inflammation associated with OVA treatment. A-B) H&E stained lung sections demonstrating inflammation in OVA (panel A) or OVA + rCARDS toxin (panel B) 40x magnification. C) Quantification of average histological scores from OVA or OVA + rCARDS toxin mice on day 7 ($p = 0.0002$).
doi:10.1371/journal.pone.0102613.g001

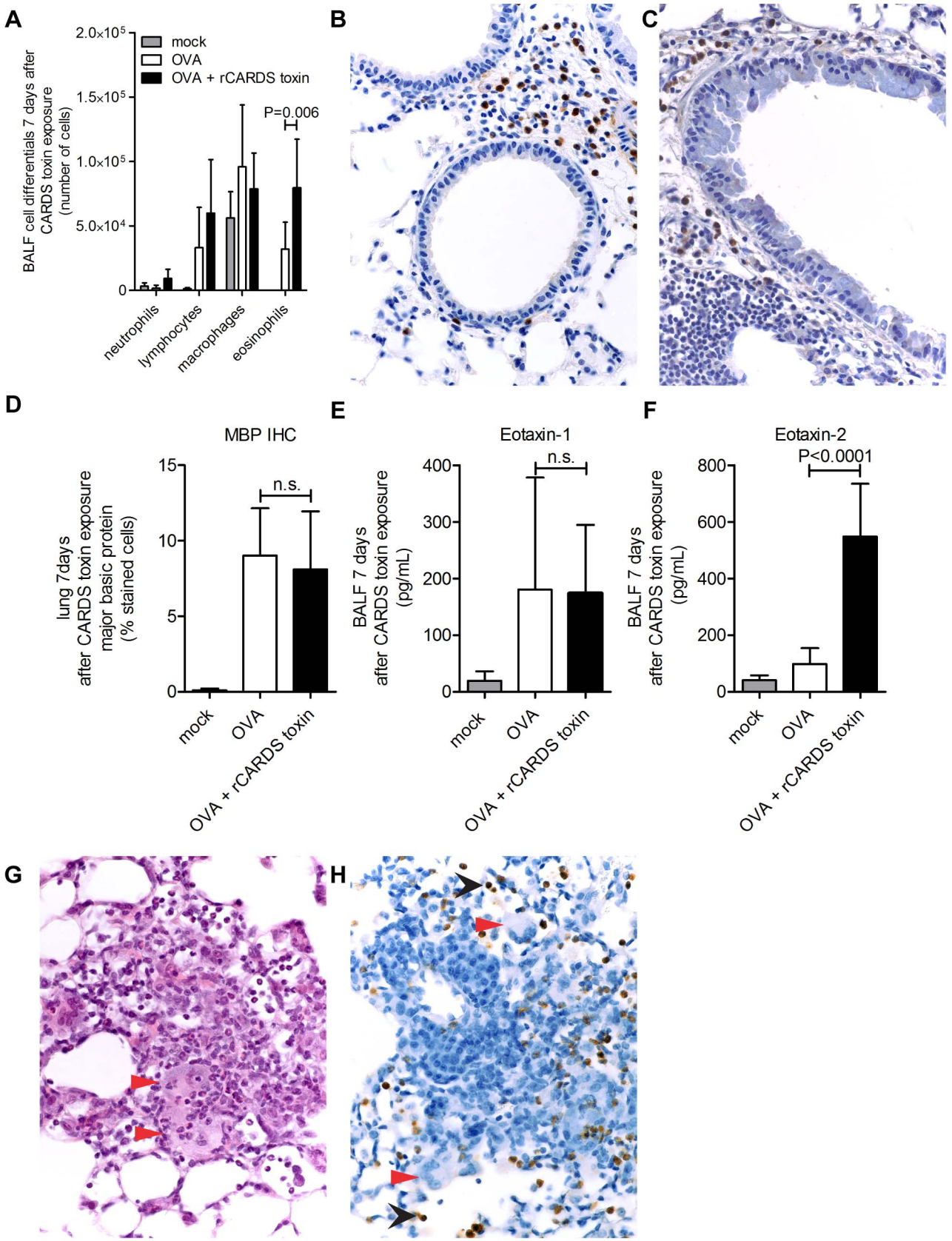

Figure 2. rCARDS toxin exacerbates eosinophilia. A) Cellular differentials from BALF on day 7 after exposure to CF or rCARDS toxin. Increased eosinophilia is seen at day 7 ($p = 0.006$). B-C) Eosinophils at peribronchiolar lesions of OVA (B) or OVA + rCARDS toxin (C) detected by immunohistochemistry with anti-MBP. Brown color depicts positive staining for eosinophil MBP. Original magnification 40x. D) Quantification of

bronchiolar MBP immunohistochemistry stain using Aperio digital pathology system. E) Measurement of eotaxin-1 concentration by ELISA (n.s.). F) Differences in eotaxin-2 concentrations determined by ELISA ($p<0.0001$). G) H&E stain depicting eosinophil-rich granulomas 40x magnification. Red arrows point towards giant cells. H) MBP immunohistochemistry of granulomatous lesion 40x magnification. Black arrows point towards eosinophils and red arrows point towards giant cells.
doi:10.1371/journal.pone.0102613.g002

treated mice were exposed to rCARDS toxin (Fig. 2G-H). These granulomas were rich in eosinophils, a finding also observed, to a lesser extent, in naïve animals treated with rCARDS toxin (unpublished data). Collectively, these data suggest that rCARDS toxin exacerbates OVA-induced allergic inflammation and eosinophilia.

rCARDS toxin exposure leads to increased pulmonary expression of Th2 cytokines and chemokines in OVA-treated mice

We demonstrated that rCARDS toxin exposure induces expression of Th2 cytokines in naïve BALB/cJ mice [22]. IL-4 and IL-13 are two central Th2 effector cytokines upregulated in OVA-induced allergic asthma [35]. To evaluate the impact of CARDS toxin on the expression of Th2 cytokines in a preexisting asthma model, lungs were analyzed for IL-4 and IL-13 mRNA 7 days after exposure to rCARDS toxin and compared to mock-treated controls. We observed approximately 8-fold ($p = 0.003$) and 1.7-fold increases ($p = 0.032$) in IL-4 and IL-13 mRNA expression, respectively, in OVA + rCARDS toxin-exposed mice compared to OVA alone (Fig. 3A & B).

The chemokines CCL17 and CCL22 recruit Th2 T-cells to sites of inflammation [36]. However, lung CCL17 mRNA expression 7 days after CARDS toxin exposure was not significantly different in OVA + rCARDS toxin mice when compared to OVA mice (Fig. 4A). In contrast, there were significantly increased concentrations of CCL17 protein in OVA + rCARDS toxin-treated mice compared to OVA mice (1,791±907.6 pg/mL vs 944.9±632.7 pg/mL, respectively ($p = 0.005$)) (Fig. 4C). CCL22 mRNA expression was increased 2-fold ($p = 0.03$) (Fig. 4B), and CCL22 protein concentrations were increased in the BALF for OVA + rCARDS toxin vs OVA mice (108.5±42.4 pg/mL vs 64.1±30.8 pg/mL, respectively ($p = 0.002$)) (Fig. 4D). In total, these data suggest that Th2 cytokine and chemokine expression is heightened by rCARDS toxin exposure in a model of preexisting allergic inflammation, contributing to exacerbation of Th2-mediated inflammation.

rCARDS toxin exacerbates airway hyperreactivity in OVA-treated mice

Because rCARDS toxin induces AHR in naïve mice, we evaluated the effects of rCARDS toxin on pre-existing hyperreactive airways in the OVA model of asthma. The airway mechanics of OVA or OVA + rCARDS toxin mice were measured via direct pulmonary function 7 days after exposure to rCARDS toxin. As shown in Figure 5 A-B, there was a significant increase in airway resistance ($p<0.0001$) and reduction in lung compliance ($p = 0.0005$) associated with rCARDS toxin exposure in mice with pre-existing allergic inflammation on day 7, indicative of worsened AHR. These data demonstrate that rCARDS toxin is capable of enhancing preexisting airway obstruction and exacerbating AHR in the mouse model of allergic asthma.

Discussion

Mycoplasma pneumoniae is a common human atypical bacterial pathogen that causes up to 40% of community acquired pneumonias and is implicated in exacerbations of human asthma [9]. For example, Lieberman et al used serology to demonstrate acute infection with *M. pneumoniae* in 18% of patients with

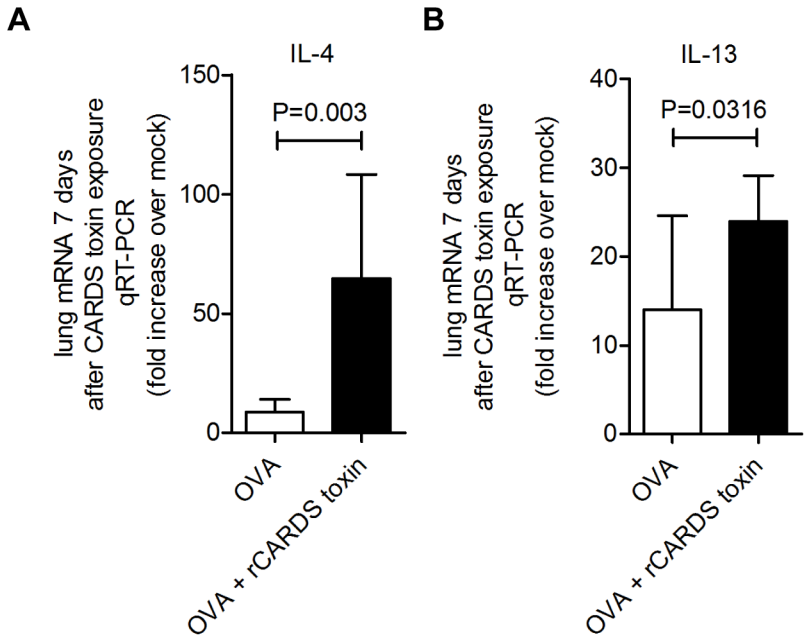

Figure 3. rCARDS toxin increases the induction of Th2 effector cytokines in OVA treated mice. RNA was extracted from lungs of OVA- or OVA + rCARDS toxin-treated mice. qRT-PCR quantification of mRNA induction for A) IL-4 ($p = 0.003$) and B) IL-13 ($p = 0.0316$) 7 days after exposure.
doi:10.1371/journal.pone.0102613.g003

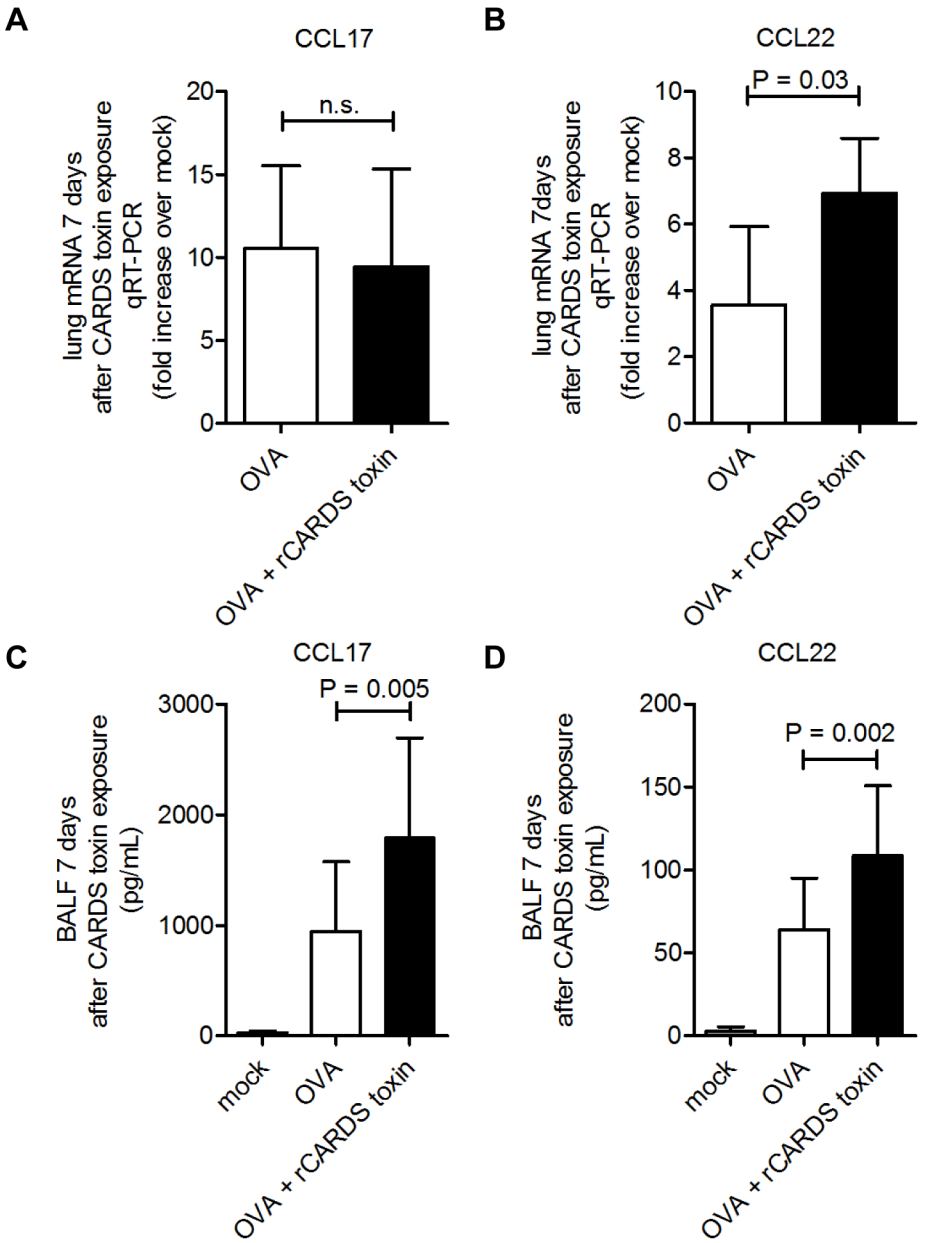

Figure 4. Chemokines CCL17 and CCL22 expression is increased in OVA-treated mice exposed to rCARDS toxin. qRT-PCR quantification of mRNA induction for A) CCL17 and B) CCL22 ($p = 0.03$) 7 days after exposure. Chemokine concentrations were measured by ELISA for C) CCL17. ($p = 0.005$) and D) CCL22 ($p = 0.002$).
doi:10.1371/journal.pone.0102613.g004

asthma exacerbation compared to 3% of a matched control group [6]. Likewise, it was shown that chronic, stable asthma patients who tested positive for *M. pneumoniae* or *Chlamydia pneumoniae* by PCR and were treated with clarithromycin experienced an improvement in airway function, while patients who tested negative for *M. pneumoniae* or *C. pneumoniae* experienced no improvement suggesting a role for these bacteria in disease pathogenesis [5]. While there are many clinical studies implicating *M. pneumoniae* in exacerbations of asthma, the mechanisms responsible for exacerbation of disease are not fully understood [6,14,15,23,24,25].

We demonstrated that rCARDS toxin, an ADP-ribosylating and vacuolating toxin, is sufficient to cause allergic-type inflammation in naïve BALB/cJ mice [22,37]. In the current study, we investigated the impact of rCARDS toxin in exacerbation of allergic inflammation. Exposure to rCARDS toxin was sufficient to significantly increase pulmonary allergic inflammation as manifested by increased cellular inflammation in mice with preexisting OVA-generated experimental asthma. CARDS toxin-mediated exacerbation of disease was accompanied by increased expression of Th2-mediated cytokine and chemokine responses and enhanced AHR.

The inflammation associated with the OVA model of asthma is characterized by the influx of eosinophils and Th2 T-cells and epithelial cell hyperplasia, and is similar in many respects to human allergic asthma. Our findings suggest that CARDS toxin is

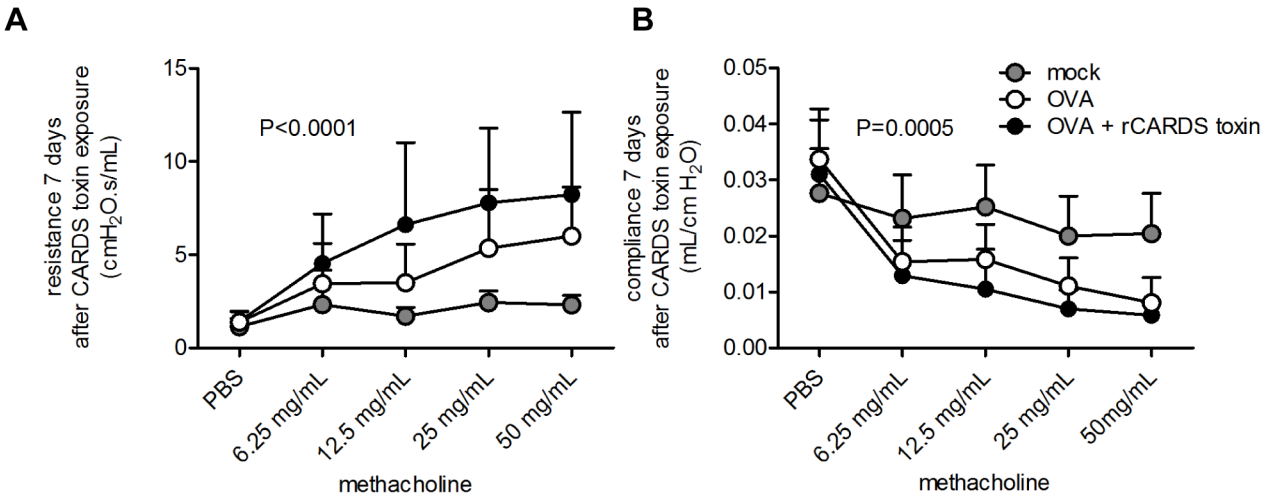

Figure 5. rCARDS toxin exacerbates OVA-induced airway hyperreactivity in BALB/cJ mice. Airway hyperreactivity was directly measured by changes in airway resistance and lung compliance through a methacholine dose curve. (A) Dynamic airway resistance ($p<0.0001$) and (B) Dynamic compliance ($p = 0.0005$) measurements were made 7 days after CARDS toxin exposure and analyzed using 2-way ANOVA.
doi:10.1371/journal.pone.0102613.g005

a significant virulence factor in the exacerbations of OVA-induced inflammation in mice infected with live *M. pneumoniae*, as mycoplasmas synthesize augmented levels of CARDS toxin in the airways [38] and rCARDS toxin alone recapitulates the exaggerated pathologies observed during *M. pneumoniae* infection of OVA-treated mice [17,39]. These data strongly suggest that the exacerbation of allergic inflammation observed with *M. pneumoniae* infection of OVA-treated mice was due in part to the actions of the CARDS toxin. In addition, CARDS toxin is readily detected in *M. pneumoniae*-infected humans and mice [14,15,40]. Previous studies evaluating the potential of *M. pneumoniae* to exacerbate OVA-induced models of asthma demonstrated increased expression of Th2 cytokines and pronounced eosinophilia [18,39]. These studies highlighted the importance of understanding *M. pneumoniae* as a human pathogen, but did not identify a virulence factor(s) responsible for exacerbation of allergic inflammation in OVA models. Our data implicate CARDS toxin as a major virulence factor contributing to the exaggerated inflammatory responses observed when OVA-treated mice are exposed to rCARDS toxin.

rCARDS toxin and OVA treatments are both known to induce a significant eosinophilic inflammation in the lungs of mice [22,32]. Additionally, increased numbers of eosinophils correlated with more severe forms of asthma in humans, such as refractory eosinophilic asthma [41,42,43]. The contributions of eosinophils to the pathology of asthma are not entirely clear, and newer data suggest that these cells are more complex than previously thought [36]. Eosinophils are able to express a variety of inflammatory mediators such as MBP, eosinophil peroxidase, leukotrienes and cytokines, such as IL-4 and IL-13, consistent with the role of eosinophils in allergic inflammation [41]. Eosinophil-derived inflammatory mediators have significant impact on bronchiolar epithelium and airway smooth muscle hyperresponsiveness. In mice, eosinophils are one of the initial cells responding to allergic inflammation, where they can act as antigen-presenting cells and contribute to the recruitment of T-cells to sites of inflammation [44]. The specific role of eosinophils was not investigated in this current study, but we observed increased numbers of eosinophils in the BALF and increased severity of inflammation. Therefore, it is reasonable to consider eosinophils as contributing to the pathology of CARDS toxin-associated exacerbations of asthma in mice. Granulomas with an eosinophilic component were noted in the OVA + rCARDS-treated mice and resembled a human asthmatic pathology, asthmatic granulomatosis, recently observed in severe asthma [45]. Although this is an enticing correlate, it remains unknown if CARDS toxin has a role in asthmatic granulomatosis associated with severe asthma in humans.

Th2 responses and inflammation have direct effects on AHR and airway obstruction. In this study we demonstrate that rCARDS toxin is sufficient to exacerbate these responses in a mouse model of asthma. Recent clinical studies linking *M. pneumoniae* infections with acute exacerbations of asthma detected CARDS toxin in patients, suggesting that CARDS toxin could have a similar impact on human health. CARDS toxin is readily detected in the respiratory secretions of subsets of both children and adults with refractory asthma or acute exacerbations of asthma [14,15]. In these patients, CARDS toxin is measured by PCR or antigen capture in 45% of subjects with refractory asthma compared to 16.5% of normal controls. The importance of these correlations was highlighted by the observation that after 8 weeks of macrolide treatment, a patient's asthma symptoms failed to improve, and CARDS toxin was persistently detected in the sputum of the macrolide-treated patient [14]. Additionally, our recent data show that children with acute or refractory asthma that test positive for *M. pneumoniae* by PCR or CARDS toxin antigen capture, have lower exhaled breath condensate pH, lower quality of life scores, and are less likely to have their asthma under control [15]. Taken together, these data suggest that *M. pneumoniae* and CARDS toxin could impact disease severity in asthmatics.

Data presented in the current study demonstrate increased severity of experimentally induced asthma-associated lung pathologies in BALB/cJ mice following exposure to rCARDS toxin compared to OVA treatment alone. Altogether, these data suggest that CARDS toxin exacerbates OVA-induced asthma in mice [17,18,39]. The identification of CARDS toxin as a key *M. pneumoniae* virulence factor that enhances experimental asthma in mice will facilitate understanding the role of *M. pneumoniae* in human asthma. These findings warrant further studies to

understand the impact of CARDS toxin as a mediator in the exacerbations of human asthma during *M. pneumoniae* infections.

Supporting Information

Figure S1 Panel of standards used in evaluating inflammatory lung pathology. Whole lung H&E sections were evaluated by 4 individuals blinded to experimental treatments. (A-C) Pathology scores of 1-3 were assigned using a panel standards (A = 1, B = 2, C = 3).
(TIF)

Figure S2 Representative H&E image from a lung section of a mock treated animal (40x).
(TIF)

Author Contributions

Conceived and designed the experiments: JLM JJC EGB CJLS PHD. Performed the experiments: JLM EGB VTW AC MFRP LS. Analyzed the data: JLM JJC EGB AC CJLS VTW JJB PHD. Contributed reagents/materials/analysis tools: JLM JJC EGB CJLS VTW AC LS TRK JBB PHD. Wrote the paper: JLM JJC EGB CJLS TRK JBB PHD.

References

1. Lemanske RF Jr, Busse WW (2010) Asthma: clinical expression and molecular mechanisms. J Allergy Clin Immunol 125: S95–102.
2. Blasi F (2004) Atypical pathogens and respiratory tract infections. Eur Respir J 24: 171–181.
3. Johnston SL, Martin RJ (2005) Chlamydophila pneumoniae and Mycoplasma pneumoniae: a role in asthma pathogenesis? Am J Respir Crit Care Med 172: 1078–1089.
4. Kraft M, Cassell GH, Henson JE, Watson H, Williamson J, et al. (1998) Detection of Mycoplasma pneumoniae in the airways of adults with chronic asthma. Am J Respir Crit Care Med 158: 998–1001.
5. Kraft M, Cassell GH, Pak J, Martin RJ (2002) Mycoplasma pneumoniae and Chlamydia pneumoniae in asthma: effect of clarithromycin. Chest 121: 1782–1788.
6. Lieberman D, Printz S, Ben-Yaakov M, Lazarovich Z, Ohana B, et al. (2003) Atypical pathogen infection in adults with acute exacerbation of bronchial asthma. Am J Respir Crit Care Med 167: 406–410.
7. Martin RJ, Kraft M, Chu HW, Berns EA, Cassell GH (2001) A link between chronic asthma and chronic infection. J Allergy Clin Immunol 107: 595–601.
8. Seggev JS, Lis I, Siman-Tov R, Gutman R, Abu-Samara H, et al. (1986) Mycoplasma pneumoniae is a frequent cause of exacerbation of bronchial asthma in adults. Ann Allergy 57: 263–265.
9. Waites KB, Talkington DF (2004) Mycoplasma pneumoniae and its role as a human pathogen. Clin Microbiol Rev 17: 697–728, table of contents.
10. Atkinson TP, Balish MF, Waites KB (2008) Epidemiology, clinical manifestations, pathogenesis and laboratory detection of Mycoplasma pneumoniae infections. FEMS microbiology reviews 32: 956–973.
11. Hardy RD, Jafri HS, Olsen K, Hatfield J, Iglehart J, et al. (2002) Mycoplasma pneumoniae induces chronic respiratory infection, airway hyperreactivity, and pulmonary inflammation: a murine model of infection-associated chronic reactive airway disease. Infect Immun 70: 649–654.
12. Martin RJ, Chu HW, Honour JM, Harbeck RJ (2001) Airway inflammation and bronchial hyperresponsiveness after Mycoplasma pneumoniae infection in a murine model. Am J Respir Cell Mol Biol 24: 577–582.
13. Sutherland ER, Martin RJ (2007) Asthma and atypical bacterial infection. Chest 132: 1962–1966.
14. Peters J, Singh H, Brooks EG, Diaz J, Kannan TR, et al. (2011) Persistence of Community-Acquired Respiratory Distress Syndrome Toxin-Producing Mycoplasma pneumoniae in Refractory Asthma. Chest 140: 401–407.
15. Wood PR, Hill VL, Burks ML, Peters JI, Singh H, et al. (2013) Mycoplasma pneumoniae in children with acute and refractory asthma. Annals of allergy, asthma & immunology: official publication of the American College of Allergy, Asthma, & Immunology 110: 328–334 e321.
16. Fonseca-Aten M, Rios AM, Mejias A, Chavez-Bueno S, Katz K, et al. (2005) Mycoplasma pneumoniae induces host-dependent pulmonary inflammation and airway obstruction in mice. Am J Respir Cell Mol Biol 32: 201–210.
17. Chu HW, Honour JM, Rawlinson CA, Harbeck RJ, Martin RJ (2003) Effects of respiratory Mycoplasma pneumoniae infection on allergen-induced bronchial hyperresponsiveness and lung inflammation in mice. Infect Immun 71: 1520–1526.
18. Wu Q, Martin RJ, LaFasto S, Chu HW (2009) A low dose of Mycoplasma pneumoniae infection enhances an established allergic inflammation in mice: the role of the prostaglandin E2 pathway. Clin Exp Allergy 39: 1754–1763.
19. Hardy RD, Coalson JJ, Peters J, Chaparro A, Techasaensiri C, et al. (2009) Analysis of pulmonary inflammation and function in the mouse and baboon after exposure to Mycoplasma pneumoniae CARDS toxin. PLoS One 4: e7562.
20. Kannan TR, Baseman JB (2006) ADP-ribosylating and vacuolating cytotoxin of Mycoplasma pneumoniae represents unique virulence determinant among bacterial pathogens. Proc Natl Acad Sci U S A 103: 6724–6729.
21. Kannan TR, Provenzano D, Wright JR, Baseman JB (2005) Identification and characterization of human surfactant protein A binding protein of Mycoplasma pneumoniae. Infect Immun 73: 2828–2834.
22. Medina JL, Coalson JJ, Brooks EG, Winter VT, Chaparro A, et al. (2012) Mycoplasma pneumoniae CARDS toxin induces pulmonary eosinophilic and lymphocytic inflammation. Am J Respir Cell Mol Biol 46: 815–822.
23. Cosentini R, Tarsia P, Canetta C, Graziadei G, Brambilla AM, et al. (2008) Severe asthma exacerbation: role of acute Chlamydophila pneumoniae and Mycoplasma pneumoniae infection. Respir Res 9: 48.
24. Biscardi S, Lorrot M, Marc E, Moulin F, Boutonnat-Faucher B, et al. (2004) Mycoplasma pneumoniae and asthma in children. Clinical infectious diseases: an official publication of the Infectious Diseases Society of America 38: 1341–1346.
25. Kraft M, Adler KB, Ingram JL, Crews AL, Atkinson TP, et al. (2008) Mycoplasma pneumoniae induces airway epithelial cell expression of MUC5AC in asthma. The European respiratory journal 31: 43–46.
26. Wu Q, Martin RJ, Lafasto S, Efaw BJ, Rino JG, et al. (2008) Toll-like receptor 2 down-regulation in established mouse allergic lungs contributes to decreased mycoplasma clearance. American journal of respiratory and critical care medicine 177: 720–729.
27. Bubeck SS, Cantwell AM, Dube PH (2007) Delayed inflammatory response to primary pneumonic plague occurs in both outbred and inbred mice. Infect Immun 75: 697–705.
28. Bell RE, Kuehl TJ, Coalson JJ, Ackerman NB Jr, Null DM Jr, et al. (1984) High-frequency ventilation compared to conventional positive-pressure ventilation in the treatment of hyaline membrane disease in primates. Crit Care Med 12: 764-768.
29. Delemos RA, Coalson JJ, Gerstmann DR, Null DM Jr, Ackerman NB, et al. (1987) Ventilatory management of infant baboons with hyaline membrane disease: the use of high frequency ventilation. Pediatr Res 21: 594–602.
30. Rucker G, Schimek-Jasch T, Nestle U (2012) Measuring inter-observer agreement in contour delineation of medical imaging in a dummy run using Fleiss' kappa. Methods of information in medicine 51: 489–494.
31. Fleiss JL (1971) Measuring nominal scale agreement among many raters. Psychological Bulletin 76: 378–382.
32. Gonzalo JA, Lloyd CM, Kremer L, Finger E, Martinez AC, et al. (1996) Eosinophil recruitment to the lung in a murine model of allergic inflammation. The role of T cells, chemokines, and adhesion receptors. The Journal of clinical investigation 98: 2332–2345.
33. Pope SM, Fulkerson PC, Blanchard C, Akei HS, Nikolaidis NM, et al. (2005) Identification of a cooperative mechanism involving interleukin-13 and eotaxin-2 in experimental allergic lung inflammation. J Biol Chem 280: 13952-13961.
34. Kumar RK, Foster PS (2002) Modeling allergic asthma in mice: pitfalls and opportunities. Am J Respir Cell Mol Biol 27: 267–272.
35. Tomkinson A, Duez C, Cieslewicz G, Pratt JC, Joetham A, et al. (2001) A murine IL-4 receptor antagonist that inhibits IL-4- and IL-13-induced responses prevents antigen-induced airway eosinophilia and airway hyperresponsiveness. J Immunol 166: 5792–5800.
36. Jacobsen EA, Ochkur SI, Pero RS, Taranova AG, Protheroe CA, et al. (2008) Allergic pulmonary inflammation in mice is dependent on eosinophil-induced recruitment of effector T cells. J Exp Med 205: 699–710.
37. Johnson C, Kannan TR, Baseman JB (2011) Cellular vacuoles induced by Mycoplasma pneumoniae CARDS toxin originate from Rab9-associated compartments. PLoS One 6: e22877.
38. Kannan TR, Musatovova O, Balasubramanian S, Cagle M, Jordan JL, et al. (2010) Mycoplasma pneumoniae Community Acquired Respiratory Distress Syndrome toxin expression reveals growth phase and infection-dependent regulation. Mol Microbiol 76: 1127–1141.
39. Chu HW, Rino JG, Wexler RB, Campbell K, Harbeck RJ, et al. (2005) Mycoplasma pneumoniae infection increases airway collagen deposition in a murine model of allergic airway inflammation. Am J Physiol Lung Cell Mol Physiol 289: L125–133.
40. Techasaensiri C, Tagliabue C, Cagle M, Iranpour P, Katz K, et al. (2010) Variation in colonization, ADP-ribosylating and vacuolating cytotoxin, and pulmonary disease severity among mycoplasma pneumoniae strains. Am J Respir Crit Care Med 182: 797–804.
41. Rosenberg HF, Dyer KD, Foster PS (2013) Eosinophils: changing perspectives in health and disease. Nature reviews Immunology 13: 9–22.
42. Nair P, Pizzichini MM, Kjarsgaard M, Inman MD, Efthimiadis A, et al. (2009) Mepolizumab for prednisone-dependent asthma with sputum eosinophilia. The New England journal of medicine 360: 985–993.
43. Haldar P, Brightling CE, Hargadon B, Gupta S, Monteiro W, et al. (2009) Mepolizumab and exacerbations of refractory eosinophilic asthma. The New England journal of medicine 360: 973–984.

44. Rose CE Jr, Lannigan JA, Kim P, Lee JJ, Fu SM, et al. (2010) Murine lung eosinophil activation and chemokine production in allergic airway inflammation. Cellular & molecular immunology 7: 361–374.

45. Wenzel SE, Vitari CA, Shende M, Strollo DC, Larkin A, et al. (2012) Asthmatic granulomatosis: a novel disease with asthmatic and granulomatous features. American journal of respiratory and critical care medicine 186: 501–507.

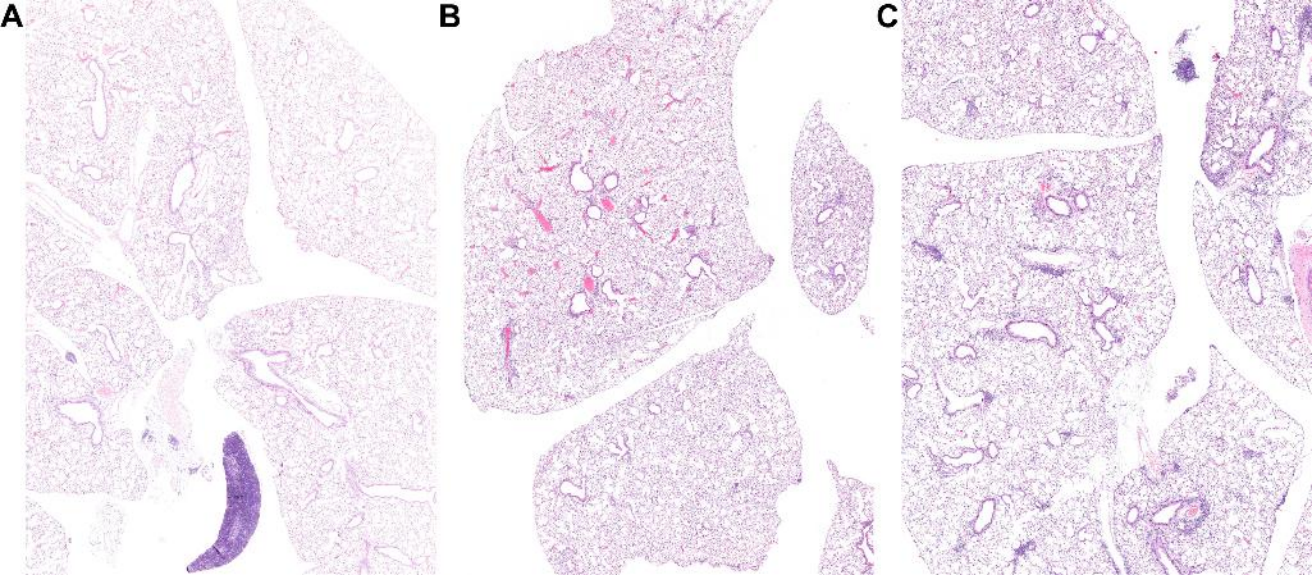
A
B
C
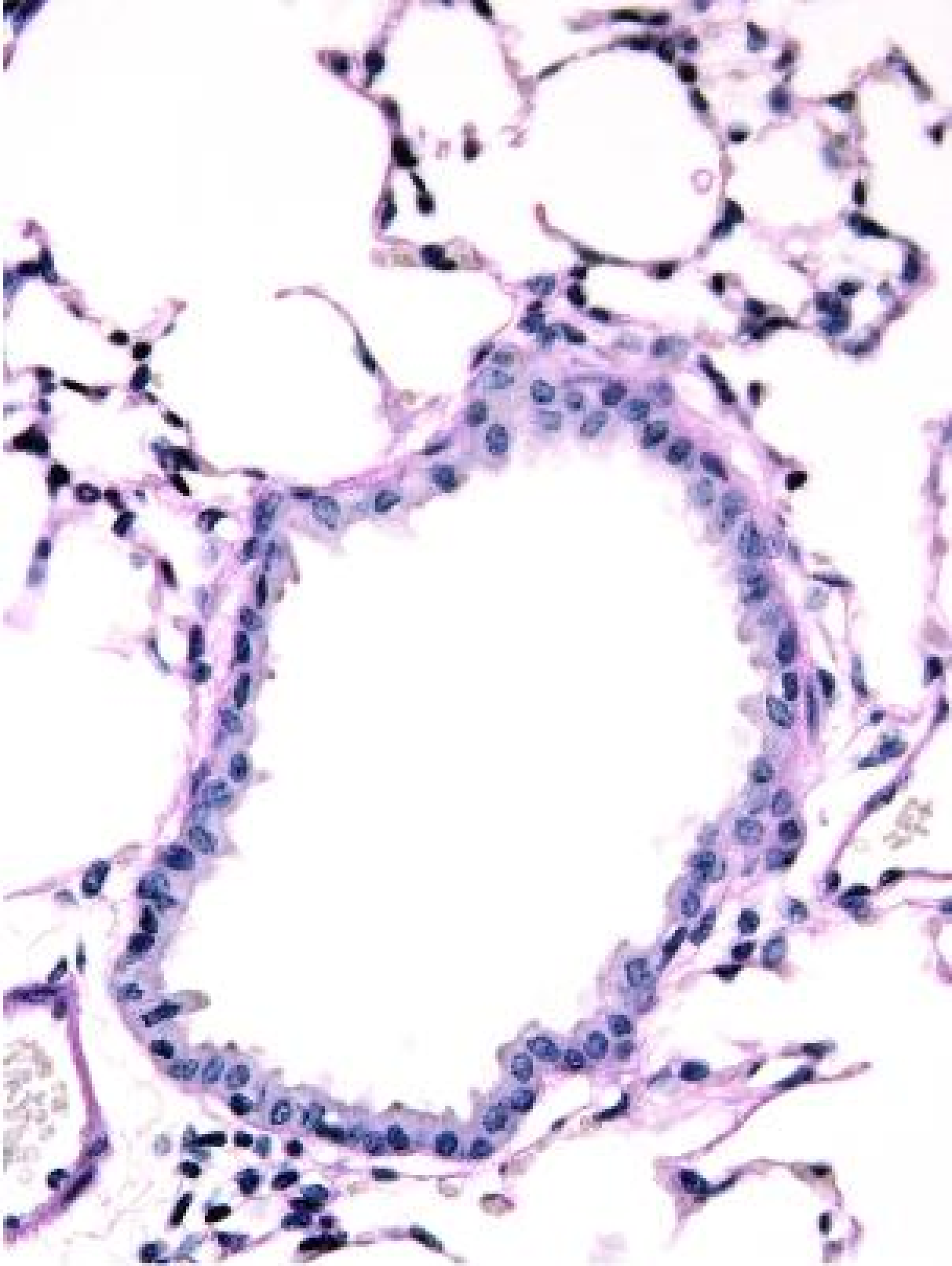
S2