Hindawi Publishing Corporation
Journal of Allergy
Volume 2011, Article ID 169432, 3 pages
doi:10.1155/2011/169432

Review Article

Review of Allergic and Photoallergic Contact Dermatitis from an Ingredient in a Medicament Vehicle Consisting of a Compress, Poultice, Plaster, and Tape

Naoki Oiso and Akira Kawada

Department of Dermatology, Faculty of Medicine, Kinki University, 377-2 Ohno-Higashi, Osaka-Sayama, Osaka 589-8511, Japan

Correspondence should be addressed to Naoki Oiso, naoiso@med.kindai.ac.jp

Received 15 November 2010; Revised 6 January 2011; Accepted 7 February 2011

Academic Editor: Clare M Lloyd

Copyright © 2011 N. Oiso and A. Kawada. This is an open access article distributed under the Creative Commons Attribution License, which permits unrestricted use, distribution, and reproduction in any medium, provided the original work is properly cited.

The topical application of a medicament vehicle consisting of a compress, poultice, plaster, and tape containing a nonsteroidal anti-inflammatory drug or methyl salicylate is prevalent in Japan. The method is effective for conveying ingredients to the muscles via the skin for the relief of muscular pain. However, an ingredient in the occlusive vehicle can cause allergic and photoallergic contact dermatitis. We summarize cases reported over the past decade and discuss the current strategy for diminishing the risk of allergic and photoallergic contact dermatitis.

1. Introduction

The application of a topical medicament consisting of a compress, poultice, plaster, and tape is prevalent in Japan. The occlusive vehicle is effective for conveying ingredients to the muscles via the skin. The vehicle usually contains a nonsteroidal anti-inflammatory drug (NSAID) or methyl salicylate as the effective component. It may also contain dl-camphor for relief of peripheral pain, l-menthol for peripheral cooling, and other ingredients, such as paraben, modified rosin, oxybenzone, and diisopropanolamine. We summarize cases of allergic and photoallergic contact dermatitis from an ingredient that were reported during the last decade [1–15].

2. Allergic and Photoallergic Contact Dermatitis

The occlusive application enhances the penetration of the effective substances. However, increased penetration may provoke allergic and photoallergic contact dermatitis from an ingredient. Allergic and photoallergic sensitization to two or more allergic or photoallergic substances can simultaneously occur [2, 6, 12]. Patch and photopatch testing with all of components is indispensable for precise diagnosis.

The effective components, an NSAID [6] or methyl salicylate [8], have been shown to be allergens. Additives, such as crotamiton [6], diisopropanolamine [6, 10, 15], l-menthol [12, 14], paraben [7], and modified resin [11, 12] also have been shown to be allergens. Benzalkonium chloride usually induces irritant contact dermatitis, but rarely induces allergic contact dermatitis [5, 16–18].

Ingredients such as ketoprofen [1–4, 12] and oxybenzone [2] have been shown to be photoallergens. The most hazardous is ketoprofen because of the highly frequent occurrence of photoallergic contact dermatitis [1–4, 12]. The mouse model of photoallergic contact dermatitis from ketoprofen has been established and the pathogenic mechanism has been investigated [19, 20].

The clinical feature is typically eczematous reactions, pruritic papular, vesicular, and bullous appearance. The size and shape are dictated by those of the applied vehicle, which is generally rectangular. Case 1 was a 68-year-old Japanese woman with a rectangular pruritic erythematous macular area on the right knee (Figure 1) [7]. In Case 1, patch testing showed a positive reaction at day 2 and 4 to the methyl and

Figure 1: A 68-year-old Japanese woman with a rectangular pruritic erythematous macular area on the right knee.

Figure 2: Patch testing for Case 1 showed positive reactions to methyl and propyl paraben at day 4.

propyl paraben contained in the compress that had been used (Figure 2) [7].

Some cases may show a rectangular eruption with a diffuse erythematous [6] or erythema multiform-like generalized reaction [14]. Case 2 was an 87-year-old Japanese male with a rectangular erythema on the bilateral lower back and the buttock and a diffuse erythema on the trunk and extremities caused by allergic contact dermatitis from the diisopropanolamine in the compresses that he used (Figure 3) [15].

Rectangular pruritic erythema may occur only when the lesion is exposed to sunlight. The effective component of the NSAID, such as ketoprofen, causes photoallergic contact dermatitis [1–4, 12, 13]. In such cases, a rectangular-shaped dermatitis with spreading [1] or erythema multiform-like eruption [13] is seen. Photoallergic contact dermatitis can be evoked by exposure to sunlight several weeks later after stopping the use of the occlusive products containing ketoprofen, because even several weeks after discontinuing the use of a poultice containing ketoproten, the skin still contains enough ketoprofen to trigger a reaction [1].

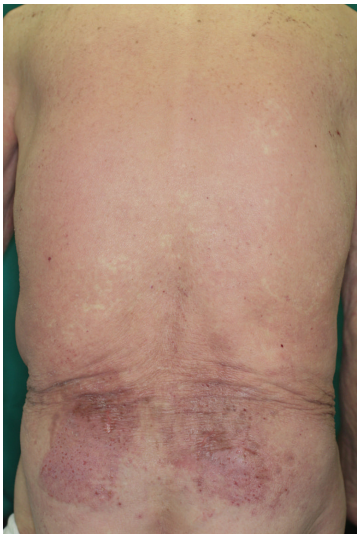

Figure 3: An 87-year-old Japanese male with rectangular erythema on the bilateral lower back and buttocks and a diffuse erythema on the trunk and extremities.

Strategies to diminish the risk of allergic and photoallergic contact dermatitis are promoted. One is the use of a topical cream, gel, or stick containing a low-sensitizing NSAID, such as felbinac [6] or loxoprofen. Another is the use of a topical occlusive medicament containing a low-sensitizing NSAID. However, physicians and pharmacologists must keep in mind that systemic contact and photocontact-type dermatitis may be evoked if a person previously sensitized to an NSAID orally takes the same NSAID [21].

In conclusion, the application of a vehicle consisting of a compress, poultice, plaster, and tape carries a greater risk of sensitization and elicitation of allergic and photoallergic contact dermatitis from an ingredient. For safety, we initially recommend the use of a topical cream, gel, or stick containing a less sensitizing ingredient, and secondarily a topical occlusive medicament containing a less sensitizing NSAID.

Conflict of Interests

None declared.

References

[1] M. Sugiura, R. Hayakawa, Y. Kato, K. Sugiura, and H. Ueda, "4 cases of photocontact dermatitis due to ketoprofen," *Contact Dermatitis*, vol. 43, no. 1, pp. 16–19, 2000.

[2] A. Kawada, Y. Aragane, M. Asai, and T. Tezuka, "Simultaneous photocontact sensitivity to ketoprofen and oxybenzone," *Contact Dermatitis*, vol. 44, no. 6, p. 370, 2001.

[3] M. Sugiyama, T. Nakada, H. Hosaka, H. Sueki, and M. Iijima, "Photocontact dermatitis to ketoprofen," *American Journal of Contact Dermatitis*, vol. 12, no. 3, pp. 180–181, 2001.

[4] T. Matsushita and R. Kamide, "Five cases of photocontact dermatitis due to topical ketoprofen: photopatch testing and cross-reaction study," *Photodermatology Photoimmunology and Photomedicine*, vol. 17, no. 1, pp. 26–31, 2001.

[5] D. A. Wong and A. B. Watson, "Allergic contact dermatitis due to benzalkonium chloride in plaster of Paris," *Australasian Journal of Dermatology*, vol. 42, no. 1, pp. 33–35, 2001.
[6] N. Oiso, K. Fukai, and M. Ishii, "Triple allergic contact sensitivities due to ferbinac, crotamiton and diisopropanolamine," *Contact Dermatitis*, vol. 49, no. 5, pp. 261–263, 2003.
[7] N. Oiso, K. Fukai, and M. Ishii, "Allergic contact dermatitis caused by parabens in a compress," *Contact Dermatitis*, vol. 50, no. 5, p. 317, 2004.
[8] N. Oiso, K. Fukai, and M. Ishii, "Allergic contact dermatitis due to methyl salicylate in a compress," *Contact Dermatitis*, vol. 51, no. 1, pp. 34–35, 2004.
[9] M. Rademaker, "Allergic contact dermatitis to a sanitary pad," *Australasian Journal of Dermatology*, vol. 45, no. 4, pp. 234–235, 2004.
[10] Y. Umebayashi, "Two cases of contact dermatitis due to diisopropanolamine," *Journal of Dermatology*, vol. 32, no. 2, pp. 145–146, 2005.
[11] C. Foti, D. Bonamonte, A. Conserva, C. Casulli, and G. Angelini, "Allergic contact dermatitis to glyceryl-hydrogenated rosinate in a topical plaster," *Contact Dermatitis*, vol. 55, no. 2, pp. 120–121, 2006.
[12] T. Ota, N. Oiso, Y. Iba, T. Narita, S. Kawara, and A. Kawada, "Concomitant development of photoallergic contact dermatitis from ketoprofen and allergic contact dermatitis from menthol and rosin (colophony) in a compress," *Contact Dermatitis*, vol. 56, no. 1, pp. 47–48, 2007.
[13] K. Izu, R. Hino, H. Isoda, D. Nakashima, K. Kabashima, and Y. Tokura, "Photocontact dermatitis to ketoprofen presenting with erythema multiforme," *European Journal of Dermatology*, vol. 18, no. 6, pp. 710–713, 2008.
[14] S. Nakagawa, H. Tagami, and S. Aiba, "Erythema multiforme-like generalized contact dermatitis to l-menthol contained in anti-inflammatory medical compresses as an ingredient," *Contact Dermatitis*, vol. 61, no. 3, pp. 178–179, 2009.
[15] T. Rind, N. Oiso, A. Hirao, and A. Kawada, "Allergic contact dermatitis with diffuse erythematous reaction from Diisopropanolamine in a compress," *Case Reports in Dermatology*, vol. 2, no. 1, pp. 50–54, 2010.
[16] D. A. Basketter, M. Marriott, N. J. Gilmour, and I. R. White, "Strong irritants masquerading as skin allergens: the case of benzalkonium chloride," *Contact Dermatitis*, vol. 50, no. 4, pp. 213–217, 2004.
[17] N. Oiso, K. Fukai, and M. Ishii, "Irritant contact dermatitis from benzalkonium chloride in shampoo," *Contact Dermatitis*, vol. 52, no. 1, p. 54, 2005.
[18] W. Uter, H. Lessmann, J. Geier, and A. Schnuch, "Is the irritant benzalkonium chloride a contact allergen? A contribution to the ongoing debate from a clinical perspective," *Contact Dermatitis*, vol. 58, no. 6, pp. 359–363, 2008.
[19] S. Imai, K. Atarashi, K. Ikesue, K. Akiyama, and Y. Tokura, "Establishment of murine model of allergic photocontact dermatitis to ketoprofen and characterization of pathogenic T cells," *Journal of Dermatological Science*, vol. 41, no. 2, pp. 127–136, 2006.
[20] K. Atarashi, K. Kabashima, K. Akiyama, and Y. Tokura, "Stimulation of Langerhans cells with ketoprofen plus UVA in murine photocontact dermatitis to ketoprofen," *Journal of Dermatological Science*, vol. 47, no. 2, pp. 151–159, 2007.
[21] N. Tanaka, A. Kawada, Y. Ohnishi et al., "Photosensitivity due to doxycycline hydrochloride with an unusual flare," *Contact Dermatitis*, vol. 37, no. 2, pp. 93–94, 1997.