Drug-Induced Hypersensitivity Syndrome Induced by Clindamycin

Yoshitaka Nakamura, Kenya Wakamatsu and Masahiko Muto
Department of Dermatology, Yamaguchi University Graduate School of Medicine, 1-1-1 Minami-Kogushi, Ube, Yamaguchi, Japan. E-mail: naka629@yamaguchi-u.ac.jp
Accepted January 31, 2012.

Drug-induced hypersensitivity syndrome (DIHS), also known as drug rash with eosinophilia and systemic symptoms (DRESS), is a severe, adverse drug reaction characterized by skin rash, fever, lymphadenopathy, hepatitis and haematological abnormalities (1, 2). The presence of human herpes virus (HHV)-6 reactivation is considered to be a diagnostic criterion for DIHS but not for DRESS. The most common causative drugs are carbamazepine, phenytoin, phenobarbital, mexiletine, dapsone, salazosulphapyridine, minocycline and allopurinol (3). We report here a case of DIHS/DRESS caused by clindamycin, which was confirmed using the lymphocyte transformation test (LTT) and patch testing.

CASE REPORT

A 34-year-old Japanese woman was admitted with a generalized eruption and fever. She had undergone resection of a giant cell tumour of the spine and had been prescribed oral clindamycin at 900 mg/day as a prophylactic antibiotic postoperatively. Twenty-three days later, a skin rash appeared and clindamycin was ceased, but the skin rash developed into a generalized maculopapular rash accompanied by oedema. She had not taken clindamycin previously and there was no history of adverse drug reactions. Clindamycin was the only drug administered during the 1-month period before the appearance of the skin eruption.

On physical examination, her temperature was 39.9ºC and facial erythema and oedema were seen with periorbital and perioral sparing (Fig. 1A). A maculopapular eruption was present on the trunk and lower limbs, and purpura was noted (Fig. 1B, C). The mucosa was not affected. She also had cervical and inguinal lymphadenopathy. Laboratory examination revealed the following abnormalities: an elevated C-reactive protein (0.59 mg/dl, normal < 0.2 mg/dl), increased white cell count (10,140 cells/mm^3, normal 4,000–10,000) with increased atypical lymphocytes (41.0%), elevated liver enzymes (aspartate aminotransferase 141 IU/l, normal 11–30 IU/l; alanine transaminase 145 IU/l, normal 5–42 IU/l) and decreased serum IgG (765 mg/dl, normal 870–1700 mg/dl). Serum anti-HHV-6 IgG titre was 1:40. Antibody titres against Epstein-Barr virus (EBV) and cytomegalovirus (CMV) antigen were not increased and blood culture was negative.

Histopathological examination of a skin biopsy from the right upper arm revealed mild liquefaction degeneration, lymphocyte infiltration into the epidermis and a moderate perivascular lymphocytic infiltrate in the upper dermis (Fig. 2).

We diagnosed her condition as DIHS/DRESS based on the diagnostic criteria for DIHS (score of 5 out of 7 points in the Japanese consensus group criteria) (2) and DRESS (defined and used by the International RegiSCAR-group and published by Kardaun et al.) (1). She was treated with intravenous betamethasone, 4 mg/day,

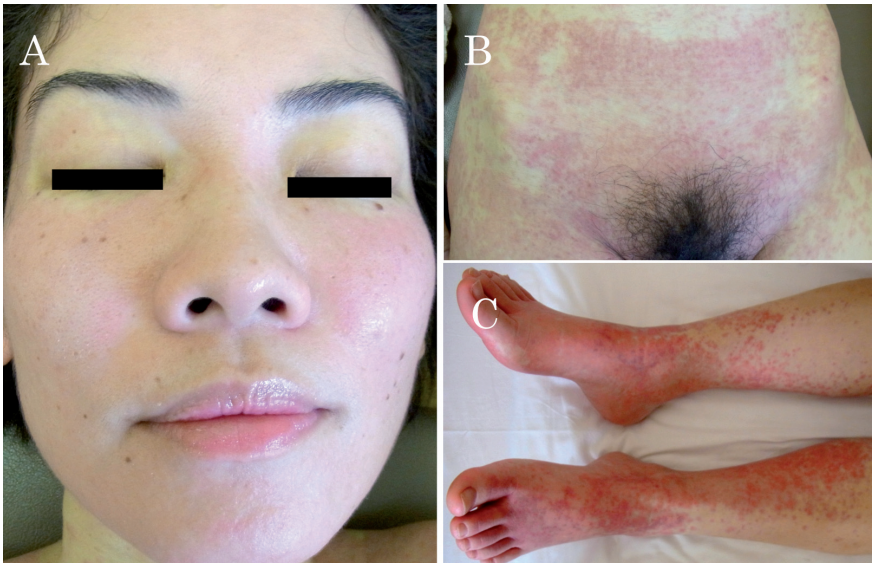

Fig. 1. (A) Facial erythema with oedema and periorbital and perioral sparing. A maculopapular eruption with purpura was present on (B) the trunk, and (C) the lower legs.

© 2012 The Authors. doi: 10.2340/00015555-1363
Journal Compilation © 2012 Acta Dermato-Venereologica. ISSN 0001-5555

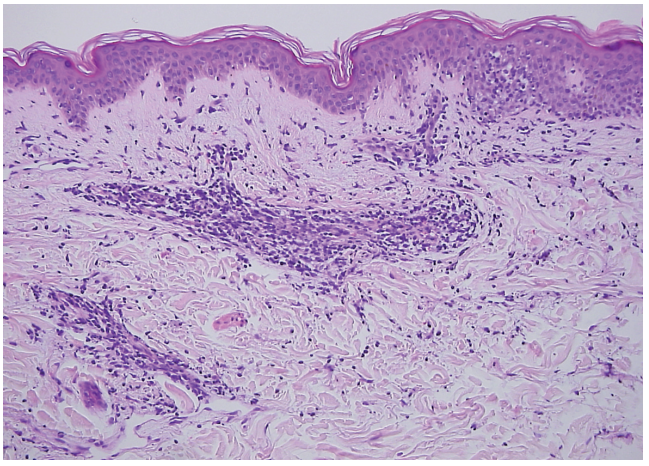

Fig. 2. Histopathological examination of a skin biopsy showed mild liquefaction degeneration, lymphocyte infiltration into the epidermis and a moderate perivascular lymphocytic infiltration in the upper dermis (haematoxylin and eosin, original magnification × 100).

in addition to intravenous immunoglobulin (IVIG), 0.1 g/kg/day, for 3 successive days. The respective serum IgG levels were 1,090 mg/dl, 900 mg/dl and 880 mg/dl at 4, 9 and 15 days after IVIG therapy. Her fever went down and the eruption disappeared completely after 2 and 10 days of treatment, respectively. Liver enzyme levels also returned to normal. Periodic measurements of antibody titres against HHV-6, EBV and CMV antigens were negative.

The LTT using 6 different concentrations of clindamycin (0.32, 1.6, 8, 40, 200 and 1,000 μg/ml) was performed in triplicate. The result of the LTT was positive, with a stimulation index of 17.5 on day 10 after debut of DRESS (>2.0 regarded as positive) at a concentration of 1.6 μg/ml. Patch testing of involved skin with 1% clindamycin in petrolatum on day 42 showed a strong positive reaction (++) at 48 and 72 h according to International Contact Dermatitis Research Group criterion. From these findings, we diagnosed the eruption as DIHS/DRESS caused by clindamycin.

DISCUSSION

Immune responses involving drug-reactive T cells and herpes virus activation have been proposed to be the underlying mechanism of DIHS/DRESS, particularly HHV-6 reactivation (3). In addition, reports have suggested that reactivation of other herpes viruses, such as HHV-7, EBV and CMV, might be involved in the development of DIHS (4). In the present case, we did not find evidence of HHV-6, EBV and CMV reactivation, but there is a possibility that HHV-7 reactivation might have contributed to the development of DIHS/DRESS.

The administration of systemic corticosteroids is the standard therapy for DIHS/DRESS, but it may increase the patient's susceptibility to infections. Our patient had hypogammaglobulinaemia; therefore, she was treated with IVIG in addition to intravenous corticosteroid. Although the exact mechanism is unknown, we expected that IVIG compensates for the decreased immunoglobulin concentration and the therapeutic effect of IVIG in DIHS/DRESS may be partially due to the presence of anti-viral IgG in IVIG (5). In many reports, however, DIHS/DRESS have not been successfully treated with IVIG alone, and the IVIG may have paradoxically exacerbated hypogammaglobulinaemia (indeed, serum IgG levels gradually decreased despite administration of IVIG in this case). We infer, therefore, that IVIG combined with systemic corticosteroids may be a treatment option useful only for patients with DIHS/DRESS with a high risk of infection.

Clindamycin is a lincosamide antibiotic that inhibits bacterial protein synthesis, which is approved for the treatment of anaerobic, streptococcal and staphylococcal infections. The use of clindamycin is increasing in clinical practice because of its tolerability and efficacy with excellent tissue penetration. The greater use of clindamycin may result in an increase in the incidence of clindamycin-related adverse effects, including drug eruptions (6). In our case, the positive patch test and LTT suggest that clindamycin was the causative drug.

The authors declare no conflicts of interest.

REFERENCES

1. Kardaun SH, Sidoroff A, Valeyrie-Allanore L, Halevy S, Davidovici BB, Mockenhaupt M, et al. Variability in the clinical pattern of cutaneous side-effects of drugs with systemic symptoms: does a DRESS syndrome really exist? Br J Dermatol 2007; 156: 609–611.
2. Shiohara T, Iijima M, Ikezawa Z, Hashimoto K. The diagnosis of a DRESS syndrome has been sufficiently established on the basis of typical clinical features and viral reactivations. Br J Dermatol 2007; 156: 1083–1084.
3. Shiohara T, Kano Y. A complex interaction between drug allergy and viral infection. Clinical Rev Allerg Immunol 2007; 33: 124–133.
4. Seishima M, Yamanaka S, Fujisawa, Tohyama M, Hashimoto K. Reactivation of human herpesvirus (HHV) family members other than HHV-6 in drug-induced hypersensitivity syndrome. Br J Dermatol 2006; 155: 344–349.
5. Kano Y, Inaoka M, Sakuma K, Shiohara T. Virus reactivation and intravenous immunoglobulin (IVIG) therapy of drug-induced hypersensitivity syndrome. Toxicology 2005; 209: 165–167.
6. Seitz CS, Bröcker EB, Trautmann A. Allergy diagnostic testing in clindamycin-induced skin reaction. Int Arch Allergy Immunol 2009; 149: 246–250.