Advances in Medical Sciences 64 (2019) 124–130

Contents lists available at ScienceDirect

Advances in Medical Sciences

journal homepage: www.elsevier.com/locate/advms

Review article

Mast cells in mastocytosis and allergy – Important player in metabolic and immunological homeostasis

Joanna Renke[a,b,*], Sabina Kędzierska-Mieszkowska[a], Magdalena Lange[c], Bogusław Nedoszytko[c], Eliza Wasilewska[d], Anna Liberek[e], Marcin Renke[f], Marek Niedoszytko[d], Jacek Witkowski[g], Joanna Skórko-Glonek[a], Barbara Lipińska[a]

[a] Department of General and Medical Biochemistry, University of Gdańsk, Gdańsk, Poland
[b] Outdoor Clinic for Immunological Diseases of Children, Department of Pediatrics, Hematology and Oncology, Medical University of Gdańsk, Gdańsk, Poland
[c] Department of Dermatology, Venerology and Allergology, Medical University of Gdańsk, Gdańsk, Poland
[d] Department of Allergology, Medical University of Gdańsk, Gdańsk, Poland
[e] Faculty of Health Sciences with Subfaculty of Nursing, Medical University of Gdańsk, Gdańsk, Poland
[f] Department of Occupational, Metabolic and Internal Diseases, Medical University of Gdańsk, Gdynia, Poland
[g] Department of Pathophysiology, Medical University of Gdańsk, Gdańsk, Poland

ARTICLE INFO

Keywords:
Mast cells
Mastocytosis
Allergy
Osteoporosis
Immunocompetence

ABSTRACT

The role of mast cell (MC) activity in pathophysiology is complex and challenging and its clinical effects are difficult to predict. Apart from the known role of MCs in basic immunological processes and allergy, underlined is their importance in bone mineralization and in regulation of autoimmune reactions. Mast cell mediators, especially those released from mast cells in degranulation, but also those released constitutively, are important both in metabolic and immunological processes. Mastocytosis is a heterogeneous group of disorders characterized by accumulation of MC in one or more organs. There are scientific data indicating that mastocytosis patients are at increased risk of osteoporosis in the systemic form of the disease and children with cutaneous mastocytosis have a higher rate of hypogammaglobulinemia. Moreover, the origin of osteoporosis in patients with allergy is no longer considered as linked to steroid therapy only, but to the mast cell mediators' activity as well. There are indications that osteoporosis symptoms in this group of patients may develop independently of the cumulative steroids' dose. Thus, the influence of mast cells on metabolic and immunologic processes in allergic patients should be investigated. The assessment of mast cell activity and burden in mastocytosis may be used to guide clinical management of patients with allergy.

1. Introduction

The role of mast cell (MC) activity in multifaceted pathophysiology of many diseases is complex and its clinical effects are difficult to predict. Apart from the known role of MCs in basic immunological processes and allergy, recent studies underline their importance in metabolism, especially in bone mineralization, as well as in the regulation of autoimmune reactions. Mature mast cells are long-lived and tend to have a decreased proliferative capability. Their characteristic feature is the presence of cytoplasmic granules that contain histamine and multitude of other inflammatory mediators [1]. Mast cells play an important physiological role in immune response; however, their abnormal accumulation may result in various forms of mastocytosis [1]. Bone mineralization disturbances, particularly osteoporosis and osteopenia, are common problems of global importance. The clinical signs of osteoporosis, e.g. pathological fractures, usually occur among adults aged 65 years or older [2], but there are groups of patients in whom low bone mineral density and osteoporosis appear much earlier. These processes were once simply thought to involve only osteoblasts and osteoclasts, but currently more complex intercellular interactions are considered, including interactions between the cells of the monocyte-macrophage-osteoclast and mesenchymal stem cells-osteoblast lineages [1,3], and between mast cells and osteoclasts as well [4,5]. Presently available data support the hypothesis that mast cells are partners in the cellular interplay leading to osteoclastic resorption [5]. Moreover, mast cells may play a significant role in the pathogenesis of idiopathic osteoporosis in men [6]. Skeletal involvement is frequently observed in systemic mastocytosis (SM), occurring in about 50% of

* Corresponding author at: Department of General and Medical Biochemistry, University of Gdańsk, 59 Wita Stwosza Str., 80-308, Gdańsk, Poland.
E-mail addresses: jrenke@gumed.edu.pl, joanna.renke@biol.ug.edu.pl (J. Renke).

https://doi.org/10.1016/j.advms.2018.08.013
Received 4 January 2018; Accepted 31 August 2018
1896-1126/ © 2018 Published by Elsevier B.V. on behalf of Medical University of Bialystok.

patients, often asymptomatic [6,7]. Descriptions of bone abnormalities in mastocytosis include both fractures and changes in surrogate markers, i.e. bone mineral density and specific biochemical markers of bone turnover [8]. Furthermore, mast cell degranulation products might also influence the degree of bone mineralization in patients with allergies. Therefore, bone mineralization abnormalities in pathologies due to excessive mast cell activity are worth investigation.

2. Review

2.1. Mastocytosis – general considerations

Mastocytosis is a disease with abnormal growth and accumulation of mast cells, in most patients accompanied by the mast cell mediator-related symptoms [1,7,9–12]. Depending on the form of the disease, MCs accumulate in the skin – mastocytosis in the skin (MIS) or cutaneous mastocytosis (CM) and/or in internal organs – systemic mastocytosis (SM). The term CM is used after negative results of bone marrow analysis and ruling out SM. The MIS description is used where bone marrow biopsy was either not performed or delayed due to various reasons. Most commonly affected are the skin, bone marrow, gastrointestinal tract, liver, spleen and lymph nodes. Mast cell leukemia is the most severe form of the disease. The range of clinical pictures is very wide. Even though mast cells were discovered in the 19th century by Paul Ehrlich and the first known form of the disease was described in 1869 by Nettleship and Tay, the first full classification was published by WHO only in 2001 [13]. The presently used classification is shown in Table 1 [13–15].

Cutaneous lesions in patients with mastocytosis are highly heterogeneous [14]; therefore, there are several clinical types of CM. The WHO classification (Table 1) distinguishes three major manifestations: the maculopapular cutaneous mastocytosis (MPCM), diffuse cutaneous mastocytosis (DCM) and mastocytoma of the skin [10,14]. The MPCM is traditionally described as *urticaria pigmentosa.* CM is diagnosed on the basis of clinical picture after exclusion of SM and usually confirmed by histopathological analysis of a skin sample [10,14]. In the majority of CM patients, irritation of the skin usually leads to a release of mast cell mediators and thus to reddening and urticarial swelling – this reaction is known as the Darier's sign. In these patients, histopathological examination reveals significant accumulation of spindle-shaped and round MCs [10,14].

The diagnosis of SM can be made when the major criterion and one minor criterion or at least three minor criteria are met (Table 2) [15]. Patients with SM often present with skin involvement. The clinical signs of the disease are due to degranulation of mast cells and/or their infiltration into internal organs. First effects of degranulation are very obvious clinically; the symptoms range from localized redness to anaphylactic shock. The long-term results of the MC-derived mediators' presence in extracellular space in the course of mastocytosis are the clinical signs such as abdominal pain, malabsorption, recurrent diarrheas and the above mentioned bone pain, osteoporosis and osteosclerosis [16].

Table 2
World Health Organization (WHO) diagnostic criteria for systemic mastocytosis (SM) [15].
Adapted from: Pardanani A. Systemic mastocytosis in adults: 2017 update on diagnosis, risk stratification and management. Am J Hematol 2016; 91: 1147-59.

Major Criterion
Multifocal, dense infiltrates of mast cells (cells (≥15MC in aggregates) detected in sections of bone marrow and/or other extracellular organs.
Minor Criteria
1) in biopsy sections of bone marrow and/or other extracutaneous organs or at least in bone marrow smears > 25% of the mast cells in the infiltrate are spindle-shaped or have atypical morphology,
2) detection of an activating point mutation at codon 816 of *KIT* in bone marrow, blood or other extracutaneous organ,
3) mast cells in bone marrow, blood or other extracutaneous organ express CD2 and/or CD25 in addition to normal mast cell markers,
4) serum total tryptase persistently exceeds 20 ng/ml, unless there is an associated clonal myeloid disorder)

The diagnosis of SM can be made when the major criterion and one minor criterion or at least three minor criteria are present.

2.1.1. Biological effects of mast cell inflammatory mediators

The MC-derived inflammatory mediators contribute substantially to the clinical symptoms and manifestations of mastocytosis [5]. Clinically, the most significant mediator is histamine, acting through four different receptors and mediating vasopermeability, vasodilation, gastrointestinal and bronchial smooth muscle contraction, gastric acid production, and pruritus. Mast cells have abundant secretory granule proteases, which make up most of the proteins present in mast cells, with tryptase being the major protease [1]. Tryptase, together with chymotryptic proteases, histamine, fibroblast growth factor (FGF) family proteins, receptor activator of nuclear factor-κB ligand (RANKL) and Il-6, is considered to play an important role in bone remodeling [7].

The MC mediators may be performed and stored in granules, ready to be released upon a stimulus in the process of degranulation. Mast cells store high concentrations of mediators by trapping them in anionic gel matrix composed of heparan and chondroitin sulfates [17–19]. Degranulation, a form of regulated exocytosis associated mainly with MCs, refers to the release of large, intracellular granules, full of preformed substances [17,18]. There is a large representation of cytokines among the preformed mediators, e.g. GM-CSF, IL-3, IL-4, IL-6, IL-13, IL-15 (Table 3) [18]. Among them there are also tumor necrosis factor alpha (TNFα) - which induces inflammation, cytokine production and activates endothelium; and released from endothelium transforming growth factor beta1 (TGFβ1) - an anti-inflammatory factor important in bone tissue formation. The mediators are also synthesized *de novo* after the MCs have been stimulated by a relevant signal, for example, after mast cell stimulation by zymosan, viral particles or lipopolysaccharides via various receptors, mostly Toll-like receptors (TLRs), *de novo* synthesis and later release of cytokines, including granulocyte macrophage colony stimulating factor (GM-CSF), interleukin 1 beta (IL-1β) and reactive oxygen species is initiated (Table 3). It should be pointed out that many *de novo* synthesized cytokines and chemokines are

Table 1
Classification of mastocytosis [15].
Adapted from: Pardanani A. Systemic mastocytosis in adults: 2017 update on diagnosis, risk stratification and management. Am J Hematol 2016; 91: 1147-59.

Cutaneous mastocytosis (CM)	Maculopapular cutaneous mastocytosis MPCM Diffuse cutaneous mastocytosis (DCM) Solitary mastocytoma of skin
Indolent systemic mastocytosis (ISM)	
Systemic mastocytosis with AHNMD (Associated Hematologic Non-Mast Cell Disease) (SM-AHNMD)	
Aggressive systemic mastocytosis (ASM)	
Mast cell leukemia (MCL)	
Mast cell sarcoma (MCS)	
Extracutaneous mastocytoma	

Table 3
Examples of stimuli – selective mediator release from mast cells [17].
Adapted from: Moon TC, Befus AD, Kulka M. Mast cell mediators: their differential release and the secretory pathways involved. Front Immunol 2014; 5:569.

Stimulus	Receptor	Mediators and biological effect
Degranulation and *de novo* synthesized mediator release		
Antigen	FcεRI	Histamine - toxic for parasites, increase vessels' permeability, smooth muscle constriction PGD_2, cytokines, chemokines, NO, ROS – proinflammatory/anti-inflammatory action, intercellular communication
Neuropeptides	NKRs	B-hexosaminidase, cytokines, chemokines
Defensins	GPCD	Histamine, cytokines, chemokines, PGD_2, PGE_2, LTC_2
Morphine, codeine	Opioid receptors	B-hexosaminidase, cytokines, chemokines
IgE - monomeric	FcεRI	Cytokines, B-hexosaminidase
Nerve growth factor	Trk receptor	Histamine, PGD_2, PGE_2, cytokines
Substance P, Mast Cell Degranulating Peptide (MCDP)	MRGPRX1	Cytokines, chemokines stored in small and relatively spherical granules, secreted almost immediately after the activation, and causing a transient effect
***De novo* synthesized mediator release without degranulation**		
Zymosan, PGN, LTA	TLR2 Detectin-1 receptor	GM-CSF, Il1β
Viral particles	TLRs	Cytokines
LPS	TLR4, CD14	Cytokines, chemokines
SCF	MAP kinase	Cytokines
Lectins	TIM-3	Cytokines
Degranulation without *de novo* synthesized mediator release		
Complement C3a, C5a	Complement receptors	Histamine
UV radiation		Tryptase
Neither degranulation nor *de novo* synthesized mediator release.		
Mechanical stretch	unknown	Il4 - modulation of inflammatory process and tissue remodeling

FcεRI – receptor for Fc of IgE; NO – nitric oxide; ROS – reactive oxygen species; NKRs – natural killer cells receptors; GPCR - G-protein coupled receptor; PGD_2 – prostaglandin D2; PGE_2 – prostaglandin E2; LTC_2 – leukotriene C2; Trk – tyrosine receptor kinase; MRGPRX1 – Mas-related G-protein coupled receptor member X1; PGN – peptiodoglycan; LTA – lipoteichoic acid; TLR_2 – Toll-like receptor 2; GM-CSF – granulocyte-macrophage colony stimulating factor; Il1β – interleukin 1 β; MAPK – mitogen activated protein kinase; TIM-3 – T-cell immunoglobulin mucin.

released by constitutive exocytosis via secretory vesicles which may also occur in the absence of discernable stimuli and can proceed throughout the lifetime of a cell [17–19]. The mediators are released in different ways – by the above mentioned degranulation and constitutive exocytosis, but also through exosomal secretion from the granules and endosomes or by active transport (e.g. lipid mediators such as prostaglandin D_2 or leukotriene C_4). Different stimuli induce the release of various mediators from different compartments [17–19].

Mast cell activation has typically been measured by monitoring the release of preformed mediators, especially tryptase and histamine (occurring within 15–90 s from the beginning of reaction) or β-hexosaminidase. During the early phase of response, these active substances enable the initiation of leukocyte recruitment to the site of pathogen invasion, activation of inflammatory response and innate immune processes as well as rapid anaphylactic reactions or allergic response [17]. Mast cell degranulation products provide also a long term response through multiple interactions with other cells. The late phase of response is due not only to a continued MC mediator release, but also to the activation of the newly arrived leukocytes and tissue-resident cells [20,21]. Thus, wound healing and tissue remodeling by extracellular matrix production may also be observed as an effect of interactions between mast cells and fibroblasts. Furthermore, the MC mediators may activate osteoblasts [21].

2.2. Mast cell burden impact in allergic diseases

Allergic diseases are the ones for which mast cells are known the best. Mast cells are involved especially in the IgE-mediated hypersensitivity reactions concerning skin, respiratory system and gastrointestinal tract. In the recent years evidence has accumulated that pathophysiological IgE responses vary between individuals. The intensity of the MC secretory response is dependent on the polyclonality of the IgE repertoire, the number of epitopes recognized, their antigen affinity and the distance from each other [22–24]. It was recently found that Mas-related G-protein coupled receptor X2 (MRGPRX2), one of the G-protein-coupled receptors, is selectively and highly expressed by mast cells. This receptor seems to be unique and specific for mast cells, mainly expressed by the skin mast cells where it induces degranulation and release of mediators in a distinct fashion, different from the IgE-specific activation and degranulation [22]. Granules formed due to the MRGPRX2 activation by substance P or other peptides (e.g. somatostatin, angiopeptin, mast cell degranulating peptide (MCDP), host defense peptides and some peptidergic drugs) are small and relatively spherical, secreted almost immediately after the activation, and causing a more transient effect. Conversely, the Fc receptor I-mediated ($Fc_{\varepsilon}RI$) activation causes secretion of the larger and more heterogeneously shaped granules, probably due to granule fusion, whose secretion is delayed but more intense and prolonged [22,25]. The MRGPRX2 may also be involved in several pseudoallergic reactions and/or chronic urticaria [22]. So far, there is no available data concerning the significance of MC activation through MRGPRX2 for bone resorption.

Asthma is a chronic airway inflammation resulting in bronchoconstriction. Mast cells contribute to chronic edema, mucus overproduction, contraction of smooth muscles with final tissue remodeling and fibrosis. Fibrosis may be evoked by the release of tryptase and TGFβ from mast cells, which induces fibroblast proliferation and collagen deposition in the airways [26]. In the pathogenesis of asthma, an interaction between the respiratory tract epithelial cells and MCs seems to be an important issue. This is especially in the context of the Il-33 release from multiple tissue-related cell types, e.g. endothelial cells, smooth muscle cells and fibroblasts, and its MC receptor [27].

Studies performed on the animal models of delayed-type hypersensitivity responses (DTHRs), that resemble atopic dermatitis (AD), indicated a close link between the inflammation and the MC local activity [28]. Typical clinical signs of DTHRs – irritation, edema, vasodilatation and resulting leukocyte recruitment to the area – were due to the MC mediators' activity [28]. Pruritus, one of the typical signs of AD, is due to an increased release of IL-33, IL-31, IL-25, IL-2, histamine, serotonin and tryptase, indirectly augmenting the number of nerve fibers in the skin. The study by Kneilling et al. [28] shows that T cell-

mediated inflammation strictly requires a direct crosstalk between the MC-derived TNF and the TNFR1-expressing endothelial cells.

2.3. Brief overview of mast cells' impact on bone mineralization

Continuous or repetitive release of a vast array of mediators from MCs, both during degranulation and independently of it (i.e. by constitutive exocytosis, exosomal secretion or active transport), may lead to metabolic changes, increasing with the progression of some pathologies. This phenomenon, incontestable in case of mastocytosis, may also be considered in hypersensitivity diseases.

Among metabolic disorders frequently observed during the clinical course of mastocytosis are the intensive osteoporosis and bone remodeling, usually determining poor quality of life. They are reported in up to 30–40% of patients with indolent mastocytosis – SM without myeloproliferation [16,29]. Bone mineral density disturbances observed in SM are: osteopenia (33–60%), diffuse osteoporosis (10–38%) and even osteosclerosis (5.3–10%). The incidence of vertebral fractures in SM varies from 21 to 43% [29]. The imbalance between bone formation and resorption is a result of either mast cell infiltration or the release of mediators by mast cells, especially proinflammatory cytokines, tryptase and other serine proteases, histamine and heparin [29]. Characteristic feature of osteoporosis observed in mastocytosis is its resistance to the standard treatment (Fig. 1) [30]. Due to the action of mast cell mediators, bone mineralization disorders could be expected not only in patients with SM, but in its cutaneous form as well, although the problem has not yet been sufficiently described. In contrast to the general population's epidemiological profile of osteoporosis, in which osteoporosis itself and pathological fractures are found mainly in women, in indolent mastocytosis the fractures are found mainly in men [30]. This may suggest a different pathogenesis of the process and also reminds the epidemiological data concerning osteoporosis of the adult AD patients [31]. The pathophysiology of bone loss in mastocytosis has been deeply investigated [32]. An elevated bone turnover was found in mastocytosis patients by Guillaume et al. [33]. Their study shows that serum levels of bone turnover markers evaluating bone resorption (C-telopeptide, deoxypyridoline), bone formation (bone-specific alkaline phosphatase), and bone remodeling (osteoprotegerin) are significantly higher in all forms of mastocytosis than in the control population [33]. Moreover, in the study of Kushnir-Sukhov et al. [34], in a cohort of patients with mastocytosis a higher bone density was associated with elevated serum tryptase levels, which suggests that the process of bone mineral density regulation in mastocytosis is highly complex (Figs. 2 and 3).

Tryptase, histamine and other MC products may influence the balance between bone-forming osteoblasts and bone-degrading osteoclasts and thus affect bone turnover and formation [32]. Elevated levels of both RANKL – the positive regulator of osteoclasts, and osteoprotegerin (OPG) – the RANKL competitor, have been found in mastocytosis [29,35]. Tryptase may activate osteoblasts and stimulate OPG production, increasing bone turnover and formation [32,34,35]. Histamine, released from mast cells in high amounts, increases bone resorption indirectly, by increasing the expression of RANKL in osteoblasts, and directly, by stimulating the formation and activation of osteoclasts by RANKL [29]. Histamine might also decrease osteogenesis by binding to its osteoblast and osteoclast receptors [32,36]. The observation of the histamine-deficient mice (genetic knock-out) on histamine-free diet revealed the increased bone mineral density (BMD), higher rate of bone formation and decreased number of osteoclasts [37]. Furthermore, after ovariectomy, these mice had the bone loss reduced by 50%. It has been shown that the histamine-deficiency protected the skeleton from osteoporosis by inhibiting osteoclastogenesis and by inducing the calcitriol synthesis. The latter was caused by regulating expression of calcitriol-synthesizing and catabolizing enzymes in the kidney [37]. Therefore, antihistaminics had been proposed especially for the postmenopausal women, also those with SM and mast cells expansion, as a tool worth trying in decreasing the risk of bone loss [37]. An analogous observation was made by Lind et al. [38], who noticed an increased bone mass in female mice lacking a mast cell-restricted chymase Mcpt4. It was also noted that the absence of Mpct4 resulted in the age-dependent upregulation of numerous genes important in bone formation but had no effect on osteoclast activity.

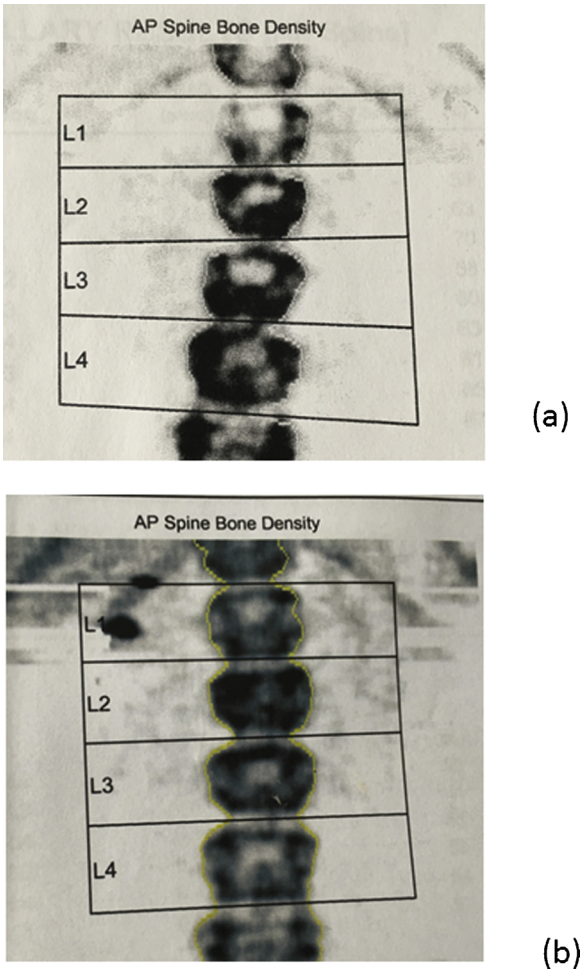

Fig. 1. (a) Densitometry of a 10 year old girl with osteoporosis in the course of indolent systemic mastocytosis, (tryptase levels at the observation time 63–194 ug/l) – mineral bone density measured at L1-L4 region refers to osteoporosis (0.389 - 0.548 g/cm^2 ; Z-score: -2.3 – -2.9 SD; 55–75% of age norm); (b) The same girl's densitometry, significant deterioration observed at the age of 11.5 years – after 1.5 year of intensive treatment - bisphosphonates, vitamin D3 and calcium; mineral bone density measured at L2-L4 region refers to advanced osteoporosis (0.484 g/cm^2; Z-score: -4.2 SD; 54% of age norm).

Another aspect of bone mineralization in the context of mast cells was addressed in the analysis of adults with mastocytosis and connective tissue inflammatory diseases. It was shown that mastocytosis was associated with a higher frequency of inflammatory joint diseases, which is a pro-osteoporotic factor [39]. The phenomenon may reflect possible disorders in regulation of immune response related to many proved interactions between mast cells and regulatory lymphocytes. The resulting inflammatory process is due to either OX40/OX40 L interaction (the latter expressed on MCs), suppression of Il10 production (anti-inflammatory cytokine produced by regulatory B lymphocytes - Bregs) and/or exposure of regulatory T lymphocytes (Tregs) to histamine, which is a typical MC mediator, and resulting decrease in CD25 and Foxp3 expression [40].

An augmented risk of osteopenia and osteoporosis in patients with asthma is mainly ascribed to their treatment with oral and inhaled corticosteroids. There are no available commentaries or research

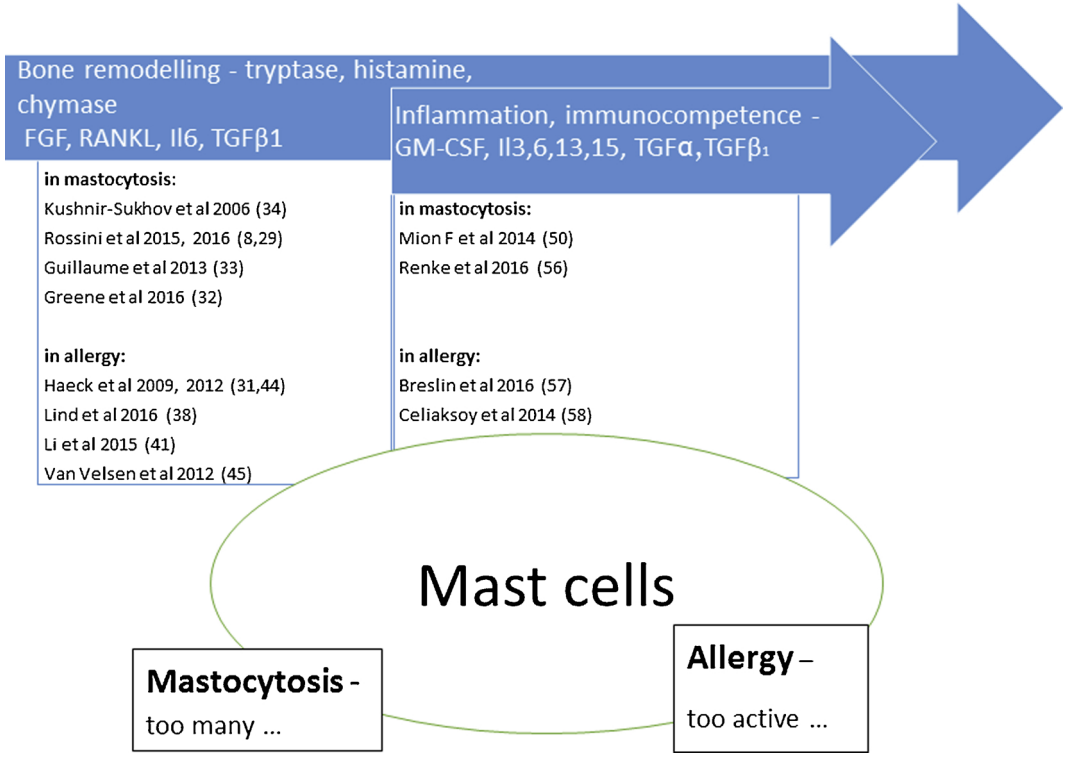

Fig. 2. Scheme of proposed mast cells' influence on metabolism and immunocompetence, with literature data.

concerning the MC role in the pathogenesis of osteoporosis in allergic diseases. Nevertheless, there are several indications that the steroids may not be the only factors involved. Interestingly, in a study on the prevalence of osteopenia and osteoporosis in patients with moderate to severe asthma in Western Canada by Li et al. [41], even though the cumulative systemic steroid dose was much higher in one group, the prevalence of reduced BMD did not differ statistically from the group with a significantly lower cumulative systemic dose.

In another study on the effect of inhaled corticosteroids (ICS) therapy on BMD in asthmatic patients, the reduction of BMD was

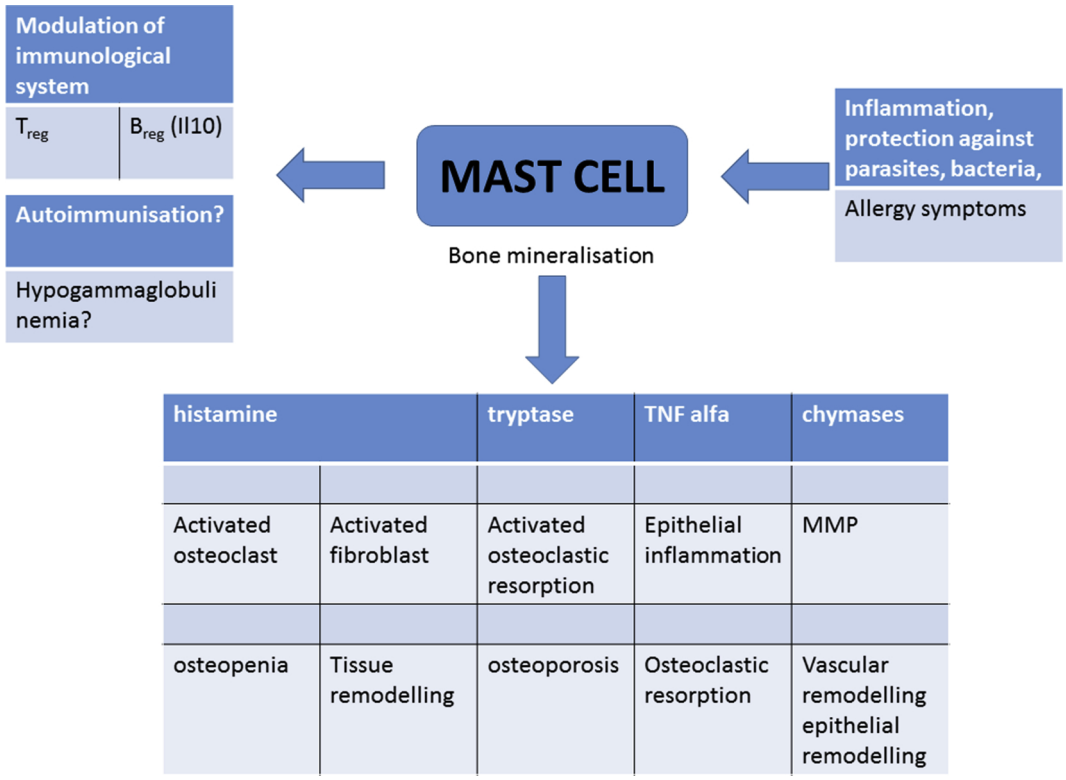

Fig. 3. Scheme of mast cells' activity impact on bone mineralization, inflammation and immunological processes.

significant in the ICS users (median treatment duration 6.5 years) under 50 years of age, but no ICS influence on BMD was found in patients over 50 years of age [42,43].

As the application of oral and topical corticosteroids may cause a risk of BMD disturbances in patients with AD, several studies have been performed [44,45]. The problem of low BMD in adult patients with moderate to severe AD was described by Haeck et al. [44] in a large group of patients. The authors found bone mineralization disturbances in one-third of the predominantly male patients with moderate to severe AD, independently of the cumulative dose of oral and topical corticosteroids. Although the total BMD at baseline in the studied group of AD patients was lower than in the general population, neither Haeck et al. [44] nor Van Velsen et al. [45] documented any further lowering in 2-year and 5-year observations, respectively, of patients intensively treated with topical corticosteroids. In none of these two analyses the activity of MCs and/or mast cell burden were taken into account when considering the final BMD values.

Interesting is the role of TGFβ1 in mast cell regulation and osteogenesis [46,47]. TGFβ1 is an anti-inflammatory factor which is also crucial in apoptosis and tissue formation [46,48].

Analysis of animal model of *fibrodysplasia ossificans* shows that TGFβ1 signal inhibition diminishes differentiation of mesenchymal cells into osteogenesis lineage in this disease [48]. The latest data suggest that TGFβ1 provides broad inhibitory signals to activated mast cells, e.g. suppressing interleukin 33-induced (IL33) mast cell function or IgE-dependent mast cell activation. [49]. In conclusion, it seems that the problem of the MC burden in the context of osteopenia and osteoporosis in the patients with mastocytosis but also in those with asthma or atopic dermatitis should be investigated.

2.4. Immunological effects of mast cells' accumulation

The influence of mast cells on various immunological processes has been widely reviewed recently. Mast cells, well known for their role in allergy and in first line protection against bacteria, fungi and parasites, represent an innate cell subset with important immune modulatory functions and functional plasticity depending on the tissue in which they differentiate [40,50]. Known, but still not fully understood, is their action in regulation of immunological system as modulators of both the effector and regulatory T cells (Treg) as well as regulatory B cells [40,50]. The data published so far are controversial. Experiments on an animal model of autoimmune diabetes have shown that inhibition of inflammatory reaction by Tregs was possible only in cooperation with active MCs [51–53]. An addition of IFNα to the mast cell line isolated from human cord blood made them switch from the TNFα to the IL-10 and TGFβ synthesis and caused a decrease in the OX40 L expression. This compromised their ability to promote CD4+ T-cell expansion and thus increased their tolerogenic potential [54]. On the other hand, Betto et al. [51] proposed that mast cells contribute to autoimmune diabetes in mice by releasing IL-6 and failing to acquire a tolerogenic IL-10+ phenotype; they also are actively recruited into the site of inflammation [51]. Mast cells may also influence the regulatory B cells by promotion of the IL-10-competent (i.e. able to produce IL-10 upon stimulation) B lymphocytes [50,51]. The study on murine model of colitis revealed that in a wild type population during convalescence the number of the B CD19+ and IL-10+ cells increased, while in the mice deprived of mast cells the phenomenon did not appear [50]. Study by Lee et al. [55] provided evidence that the MCs form a link between autoantibodies and inflammatory arthritis. They found that evoking of experimental arthritis by transfer of autoantibody-containing serum was impossible in MC-deficient mice. Furthermore, when the MCs were present, they restored the arthritis susceptibility and rapidly degranulated after serum transfer. The authors suggested that MC may be a cellular target of autoantibodies, the complement network, and Fc receptors in the subsequent development of inflammatory arthritis. Thus, the presented evidence indicates a modulatory role of the MCs in immune response.

There are also indications that MCs may influence immunoglobulin production. A retrospective study of the pediatric population with CM indicated an increased – in comparison to general population – number of patients with various types of hypogammaglobulinemia, especially transient hypogammaglobulinemia of infants (THI) [56]. In the analyzed group of children no cases of serious, life-threatening infections were noted. Children with mastocytosis and immunoglobulin deficiency may be more susceptible to connective tissue inflammatory diseases in the future. There are also literature data describing a coincidence of AD and THI in children. Breslin et al. [57] observed a group of children with severe AD and THI, without serious infections noted, who benefited from intravenous immunoglobulin therapy. Moreover, in another cohort of pediatric patients with AD [58] the incidence of hypogammaglobulinemia G was significantly higher than in a control group; the severity of AD was not dependent on the IgG level. It cannot be excluded that the inhibition of immunoglobulin production might be due to constitutive overproduction of TGFβ1 which inhibits the synthesis of IgG and IgM, as it is suggested in THI, or to elevated number of circulating regulatory T cells [59].

Despite the major advances in understanding the MC biology, the impact of the burden of accumulated mast cells on the development and/or suppressing of inflammatory processes or IgG production in mastocytosis and in allergy patients still needs further analysis.

3. Conclusions

Mastocytosis, considering the proportions, is a perfect clinical model of MC accumulation and thus the basis for further analysis of this problem in patients with allergic diseases. Obtaining new markers of MC burden would help in understanding the mast cells' impact on the development of bone mineralization disturbances, immunoglobulin levels and other not fully explained abnormalities connected with mastocytosis and allergic diseases.

Conflict of interests

The authors declare no conflict of interests.

Financial disclosure

The authors have no funding to disclose.

The author contribution

Study Design: Joanna Renke, Bogusław Nedoszytko, Marek Niedoszytko, Barbara Lipińska.

Data Collection: Joanna Renke, Anna Liberek, Marcin Renke, Sabina Kędzierska – Mieszkowska.

Statistical Analysis: n/a.

Data Interpretation: Joanna Renke, Sabina Kędzierska-Mieszkowska, Anna Liberek, Barbara Lipińska.

Manuscript preparation: Joanna Renke, Eliza Wasilewska, Magdalena Lange, Jacek Witkowski, Barbara Lipińska.

Literature Search: Joanna Renke, Joanna Skórko – Glonek, Barbara Lipińska.

Funds Collection: n/a.

Acknowledgements

We would like to cordially thank prof. Maria C. Castells from Harvard Medical School for suggestions and stimulating discussion.

References

[1] Carter M, Metcalfe D, Hirsh D, Komarow D. Mastocytosis. Immunol Allergy Clin N Am 2014;34:181–96.
[2] Blain H, Masud T, Dargent-Molina P, Martin FC, Rosendahl E, Van der Velde N,

et al. A comprehensive fracture prevention strategy in older adults: the European Union Geriatric Medicine Society (EUGMS) statement. Aging Clin Exp Res 2016;28:797–803.
[3] Loi F, Cordova LA, Pajarinen J, Lin T, Yao Z, Goodman SB. Inflammation, fracture and bone repair. Bone 2016;86:119–30.
[4] Mountziaris PM, Spicer PP, Kasper AG, Mikos AG. Harnessing and modulating inflammation in strategies for bone regeneration. Tissue Eng B Rev 2011;17:393–402.
[5] Fouilloux I, Biosse Duplan M, Baroukh B, Cherruau M, Saffar JL, Lesclous Ph. Mast cell activation and degranulation occur early during induction of periosteal resorption. Bone 2006;38:59–66.
[6] Brumsen C, Papapoulos SE, Lentjes EGWM, Kluin PM, Hamdy NAT. A potential role for the mast cell in the pathogenesis of idiopathic osteoporosis in men. Bone 2002;31:556–61.
[7] Arock M, Akin C, Hermine O, Valent P. Current treatment options in patients with mastocytosis: status in 2015 and future perspectives. Eur J Haematol 2015;94:474–90.
[8] Rossini M, Viapiana O, Adami S, Idolazzi L, Zanotti R, Gatti D. A rapid skeletal turnover in radiographic mimic of osteopetrosis might be secondary to systemic mastocytosis. J Bone Miner Res 2015;30:945.
[9] Akin C, Valent P. Diagnostic criteria and classification of mastocytosis in 2014. Immunol Allergy Clin N Am 2014;34:207–2018.
[10] Lange M, Ługowska-Umer H, Niedoszytko M, Waszą B, Limon J, Żawrocki A, et al. Diagnosis of mastocytosis in children and adults in daily clinical practice. Acta Derm Venerol 2016;96:292–7.
[11] Alvarez-Twose I, Gonzalez de Olano D, Sanchez-Munoz L, Matito A, Esteban-Lopez MI, Vega A, et al. Clinical, biological, and molecular characteristics of clonal mast cells disorders presenting with systemic mast cell activation symptomps. J Allergy Clin Immunol 2010;125:1269–78.
[12] Gulen T, Hagglund H, Dahlen B, Nilsson G. High prevalence of anaphylaxis in patients with mastocytosis – a single centre experience. Clin Exp Allergy 2014;44:121–9.
[13] Valent P, Horny HP, Escribano L, Longley BJ, Li CY, Schwartz LB, et al. Diagnostic criteria and classification of mastocytosis: a consensus proposal. Leuk Res 2001;25:603–25.
[14] Hartmann K, Escribano L, Grattan C, Brockow K, Carter M, Alvarez-Twose I, et al. Cutaneous manifestations in patients with mastocytosis: consensus report of the European Competence Network on Mastocytosis; the American Academy of Allergy, Asthma and Immunology; and the European Academy of Allergology and Clinical Immunology. J Allergy Clin Immunol 2016;137:35–45.
[15] Pardanani A. Systemic mastocytosis in adults: 2017 update on diagnosis, risk stratification and management. Am J Hematol 2016;91:1147–59.
[16] Van Anrooij B, Kluin-Nelemans JC, Safy M, Flokstra-de Blok BM, Oude Elberink JNG. Patient reported disease-specific quality of life and symptom severity in systemic mastocytosis. Allergy 2016;71:1585–93.
[17] Moon TC, Befus AD, Kulka M. Mast cell mediators: their differential release and the secretory pathways involved. Front Immunol 2014;5:569. 10.3389%2Ffimmu.2014.00569.
[18] Wernersson S, Peiler G. Mast cell secretory granules: armed for battle. Nat Rev Immunol 2014;14:478–94.
[19] Lacy P, Stow JL. Cytokine release from innate immune cells: association with diverse membrane trafficking pathways. Blood 2011;118:9–18.
[20] Moon TC, StLaurent CD, Morris KE, Marcet C, Yoshimura T, Sekar Y, et al. Advances in mast cell biology: new understanding of heterogeneity and function. Mucosal Immunol 2010;3:111–28.
[21] Douaiher J, Succar J, Lancerotto L, Gurish MF, Orgill DP, Hamilton MJ, et al. Development of mast cells and importance of their tryptase and chymase serine proteases in inflammation and wound healing. Adv Immunol 2014;122:211–52.
[22] Bulfone-Paus S, Nilsson G, Draber P, Blank U, Levi-Schaffer F. Positive and negative signals in mast cell activation. Trends Immunol 2017;38:657–67.
[23] Christensen LH, Holm J, Lund G, Riise E, Lund K. Several distinct properties of the IgE repertoire determine effector cell degranulation in response to allergen challenge. J Allergy Clin Immunol 2008;122:298–304.
[24] Gadermaier E, Levin M, Flicker S, Ohlin M. The human IgE repertoire. Int Arch Allergy Immunol 2014;163:77–91.
[25] Gaudenzio N, Sibilano R, Marichal T, Starki P, Reber LL, Cenac N, et al. Different activation signals induce distinct mast cell degranulation strategies. J Clin Invest 2016;126:3981–98.
[26] Akers IA, Parsons M, Hill MR, Hollenberg MD, Sanjar S, Laurent GJ, et al. Mast cell tryptase stimulates human lung fibroblast proliferation via protease-activated receptor-2. Am J Physiol Lung Cell Mol Physiol 2000;278:193–201.
[27] Smith DE. Il-33: a tissue derived cytokine pathway involved in allergic inflammation and asthma. Clin Exp Allergy 2009;40:200–8.
[28] Kneilling M, Mailhammer R, Hültner L, Schönberger T, Fuchs K, Schaller M, et al. Direct crosstalk between mast cell-TNF and TNFR1-expressing endothelia mediates local tissue inflammation. Blood 2009;114:1696–706.
[29] Rossini M, Zanotti R, Orsolini G, Tripi G, Viapiana O, Indolazzi L, et al. Prevalence, pathogenesis, and treatment options for mastocytosis-related osteoporosis. Osteoporos Int 2016;27:2411–21.
[30] Van der Veer E, Arends S, van der Hoek S, Versluijs JB, de Monchy JGR, Oude Elbelink JNG, et al. Predictors of new fragility fractures after diagnosis of indolent systemic mastocytosis. J Allergy Clin Immunol 2014;134:1413–21.
[31] Haeck IM, Hamdy NAT, Timmer-de Mik L, Lentjes EGWM, Verhaar HJJ, Knol MJ, et al. Low bone mineral density in adult patients with moderate to severe atopic dermatitis. Br J Dermatol 2009;161:1248–54.
[32] Greene LW, Asadipooya K, Freitas Corradi P, Akin C. Endocrine manifestation of systemic mastocytosis in bone. Rev Endocr Metab Disord 2016;17:419–31.
[33] Guillaume N, Desoutter J, Chandesris O, Merlusca L, Henry I, Georgin-Lavialle S, et al. Bone complications of mastocytosis: a link between clinical and biological characteritics. Am J Med 2013;126:1–7.
[34] Kushnir-Sukhov NM, Brittain E, Reynolds JC, Akin C, Metcalfe DD. Elevated tryptase levels are associated with greater bone density in a cohort of patients with mastocytosis. Int Arch Allergy Immunol 2006;139:265–70.
[35] Rabenhorst A, Christopeit B, Leja S, Gerbaulet A, Kleiner S, Foster A, et al. Serum levels of bone cytokines are increased in indolent systemic mastocytosis associated with osteopenia or osteoporosis. J Allergy Clin Immunol 2013;132:1234–7.
[36] Biosse-Duplan M, Baroukh B, Dy M, De Vernejoul MC, Saffar JL. Histamine promotes osteoclastogenesis through the differential expression of histamine receptors on osteoclasts and osteoblasts. AJP 2009;174:1426–34.
[37] Fitzpatrick LA, Buzas E, Gagne TJ, Nagy A, Horvath C, Ferencz V, et al. Targeted deletion of histidine decarboxylase gene in mice increases bone formation and protects against ovariectomy-induced bone loss. Proc Natl Acad Sci U S A 2003;100:6027–32.
[38] Lind T, Gustafson AM, Calounova G, Hu L, Rasmusson A, Jonsson KB, et al. Increased bone mass in female mice lacking mast cell chymase. PLoS One 2016;11(Dec. (12)). https://doi.org/10.1371/journal.pone.0167964. e0167964.
[39] Bader-Meunier B, Livideanu CB, Larroche C, Durien I, Artru L, Beucher A, et al. Association of mastocytosis with inflammatory joint diseases: a series of 31 patients. Semin Arthritis Rheum 2014;44:362–5.
[40] Mekori Y, Hershko A, Frossi B, Mion F, Pucillo C. Integrating innate and adaptive immune cells: mast cells as crossroads between regulatory and effector B and T cells. Eur J Pharmacol 2016;778:84–9.
[41] Li P, Ghazala L, Wright E, Beach J, Morrish D, Vethanayagam D. Prevalence of osteopenia and osteoporosis in patients with moderate to severe asthma in Western Canada. Clin Invest Med 2015;38:E23–30.
[42] Monadi M, Javadian Y, Cheraghi M, Heidari B, Amiri M. Impact of treatment with inhaled corticosteroids on bone mineral density of patients with asthma: related with age. Osteoporos Int 2015;26:2013–8.
[43] Sutter SA, Stein EM. The skeletal effects of inhaled glucocorticoids. Curr Osteoporos Rep 2016;14:106–13.
[44] Haeck I, van Velsen S, de Bruin-Weller M, Bruijnzeel-Koomen C. Bone mineral density in patients with atopic dermatitis. Chem Immunol Allergy 2012;96:96–9.
[45] Van Velsen S, Haeck IM, Knol MJ, Lam MGEH, Bruinzeel-Koomen CAFM. Two-year assessment of effect of topical corticosteroids on bone mineral density in adults with moderate to severe atopic dermatitis. J Am Acad Dermatol 2012;66:691–3.
[46] Kim HS, Yun JW, Shin TH, Lee SH, Lee BC, Yu KR, et al. Human umbilical cord blood mesenchymal stem cell – derived PGE2 and TGF-β1 alleviate atopic dermatitis by reducing mast cell degranulation. Stem Cells 2015;33:1254–66.
[47] Fernando J, Faber TW, Pullen NA, Falanga YT, Kolawole EM, Oskeritzian CA, et al. Genotype – dependent effects of TGF-β1 on mast cell function: targeting the Stat5 pathway. J Immunol 2013;191:4505–13.
[48] Micha D, Voermans E, Eekhoff M, van Essen HW, Zandieh-Doulabi B, Netelenbos C, et al. Inhibition of TGFβ signaling decreases osteogenic differentiation of fibrodysplasia ossificans progressive fibroblasts in a novel in vitro model of the disease. Bone 2016;84:169–80.
[49] Ndaw VS, Abebayehu D, Spence AJ, Paez PA, Kolawole EM, Taruselli MT, et al. TGF-β1 suppresses IL-33-Induced mast cell function. J Immunol 2017;199:866–73.
[50] Mion F, D'Inca F, Danelli L, Toffoletto B, Guarnotta C, Frossi B, et al. Mast cells control the expansion and differentiation of Il-10 competent B cells. J Immunol 2014;193:4568–79.
[51] Betto E, Usulli V, Mandelli A, Badami E, Sorini C, Capolla S, et al. Mast cells contribute to autoimmune diabetes by releasing interleukin-6 and failing to acquire tolerogenic Il-10^{+} phenotype. Clin Immunol 2017;178:29–38.
[52] Gri G, Frossi B, D'Inca F, Danelli L, Betto E, Mion F, et al. Mast cell: an emerging partner in immune interaction. Front Immunol 2012;3(May):120. https://doi.org/10.3389/fimmu.2012.00120.
[53] Carlos D, Yaochite JN, Rocha FA, Toso VD, Malmegrim KC, Ramos SG, et al. Mast cells control insulitis and increase Treg cells to confer protection against STZ-induced type 1 diabetes in mice. Eur J Immunol 2015;45:2873–85.
[54] Fujita T, Kambe N, Uchiyama T, Hori T. Type I interferons attenuate T cell activating functions of human mast cells by decreasing TNF-alpha production and OX40 ligand expression while increasing IL-10 production. J Clin Immunol 2006;26:512–8.
[55] Lee D, Friend D, Gurish M, Benoist C, Mathis D, Brenner M. Mast cells: a cellular link between autoantibodies and inflammatory arthritis. Science 2002;297:1689–92.
[56] Renke J, Lange M, Dawicka J, Adamkiewicz-Drożyńska E. Hypogammaglobulinemias in infants and toddlers with mastocytosis-a new aspect to analyse? Pediatr Allergy Immunol 2016;27:331–2.
[57] Breslin ME, Lin JH, Roberts R, Lim KJ, Stiehm ER. Transient hypogammaglobulinemia and severe atopic dermatitis: open – label treatment with immunoglobulin in a case series. Allergy Rhinol (Providence) 2016;7:69–73.
[58] Celiaksoy MH, Topal E, Sancak R, Catal F, Sogut A. Relationship between hypogammaglobulinemia and severity of atopic dermatitis. Ann Allergy Asthma Immunol 2014;113:467–9.
[59] Rutkowska M, Trzyna E, Lenart M, Szaflarska A, Pituch-Noworolska A, Kobylarz K, et al. The elevated number of circulating regulatory T cells in patients with transient hypogammaglobulinemia of infancy is not associated with any abnormalities in the genes encoding the TGF-β receptors. Clin Immunol 2013;149:83–5.